HOKKAIDO UNIVERSITY

| | |
|---|---|
| Title | A Rare Case of a Symptomatic Tumor Found in the Groin Area : An Atypical Location Unexposed to the Known Causes |
| Author(s) | Toyonaga, Ellen; Hata, Hiroo; Nakayama, Chihiro; Homma, Erina; Miyashita, Toshiyuki; Shimizu, Hiroshi |
| Citation | Case Reports in Oncology, 8(3), 536-539<br>https://doi.org/10.1159/000442148 |
| Issue Date | 2015-11 |
| Doc URL | http://hdl.handle.net/2115/67609 |
| Rights | The final, published version of this article is available at http://www.karger.com/?doi=10.1159/000442148 |
| Rights(URL) | https://creativecommons.org/licenses/by-nc/4.0/ |
| Type | article |
| File Information | 442148.pdf |

Instructions for use

Hokkaido University Collection of Scholarly and Academic Papers : HUSCAP

Case Reports in Oncology

Case Rep Oncol 2015;8:536–539

DOI: 10.1159/000442148
Published online: November 27, 2015

© 2015 The Author(s)
Published by S. Karger AG, Basel

1662–6575/15/0083–0536$39.50/0
www.karger.com/cro

Karger Open access

This article is licensed under the Creative Commons Attribution-NonCommercial 4.0 International License (CC BY-NC) (http://www.karger.com/Services/OpenAccessLicense). Usage and distribution for commercial purposes requires written permission.

# A Rare Case of a Symptomatic Tumor Found in the Groin Area: An Atypical Location Unexposed to the Known Causes

Ellen Toyonaga[a] Hiroo Hata[a] Chihiro Nakayama[a] Erina Homma[a]
Toshiyuki Miyashita[b] Hiroshi Shimizu[a]

[a]Department of Dermatology, Hokkaido University Graduate School of Medicine, Sapporo, and [b]Department of Molecular Genetics, Kitasato University, School of Medicine, Kanagawa, Japan

**Key Words**
Nevoid basal cell carcinoma syndrome · Gorlin syndrome · PTCH · Basal cell carcinoma · Groin area

**Abstract**
Nevoid basal cell carcinoma syndrome (NBCCS), also known as Gorlin syndrome, is a rare hereditary condition characterized by a wide range of developmental abnormalities and a predisposition to neoplasms. The syndrome consists of early-onset and/or multiple BCC. Herein we report a rare NBCCS case in which the first BCC onset occurred in the groin area. To the best of our knowledge, there have been no reports of first-onset BCC in the groin area in an NBCCS patient of any race.

© 2015 The Author(s)
Published by S. Karger AG, Basel

## Case Presentation

A 41-year-old female was referred to our hospital with a nodule on her left groin area that was suspected of being basal cell carcinoma (BCC), based on a previous skin biopsy. The lesion had appeared 3 years earlier and had gradually enlarged. Physical examination revealed a hard, dome-shaped nodule of normal skin color to reddish color on the left groin area. The nodule was 2 cm in diameter. Ulceration with crust was observed at the center of the nodule (fig. 1a). Detailed medical history analysis revealed a history of excisions of mul-

KARGER 125 YEARS

Hiroo Hata, MD, PhD
Department of Dermatology
Hokkaido University Graduate School of Medicine
North 15, West 7, Kita-ku, Sapporo 060-8638 (Japan)
E-Mail hata07jp@yahoo.co.jp

Downloaded by:
Hokkaido Daigaku
133.87.70.39 - 11/13/2017 3:27:08 AM

tiple ondontogenic keratocysts from the mandible, and at age 16, falx cerebri and tentorium cerebelli calcification. Multiple palmar and plantar pits were seen.

We suspected nevoid basal carcinoma syndrome (NBCCS; Gorlin syndrome) and performed mutation detection. Mutation analysis of genomic DNA demonstrated the patient to be heterozygous for the mutation c.1364dupT (p.T456NfsX41) in *PTCH1*, a gene that functions in tumor suppression. The groin region had not been exposed to radiation or arsenic ingestion. She had no history of BCC.

Surgical excision was performed. The histopathologic findings under hematoxylin-eosin stain showed alveolar structures of various sizes, with basaloid tumor cells (fig. 1b). Characteristic peripheral palisading patterns were observed as well (fig. 1c). The histopathology was consistent with BCC.

## Discussion

NBCCS, also known as Gorlin syndrome, was first reported in 1894 and was clearly defined in 1960 by Gorlin and Goltz [1]. NBCCS is a rare hereditary condition characterized by a wide range of developmental abnormalities and a predisposition to neoplasms. The gene responsible for NBCCS is the gene *PTCH*, which is on chromosome 9q22.3–q31 [2]. This inherited gene is a human tumor suppressor gene, and mutation in this gene increases the risk of BCC. The syndrome consists of early-onset and/or multiple BCCs, keratocysts of the jaw, palmar and plantar pits, calcified dural folds, hamartomas, various neoplasms, and skeleton anomalies such as bifid ribs and macrocephaly. As shown in table 1, the incidence varies widely among ethnic groups: 80% of Caucasian NBCCS patients manifest BCC, whereas only 38% of African patients manifest BCC [3]. Japanese NBCCS patients have an even lower frequency of BCC than those groups (table 1). BCCs, whose number can vary from a few to hundreds, usually first appear between puberty and age 35; however, cases have been reported in patients as young as age 3 or 4. In Japanese NBCCS patients, the age of onset for BCC is much higher than in Caucasians [4]. BCC of the perianal and genital regions is rare, occurring at these sites in less than 1% of all BCCs. The frequency of BCC in the groin area is even rarer in patients with NBCCS.

There has been only one previous report of an NBCCS patient with a BCC in the groin area [5]. However, in that case, the patient previously had more than 15 BCCs, so the BCC in the groin area was not the first onset.

Herein we reported a rare NBCCS case in which the first BCC onset occurred in the groin area. To the best of our knowledge, there have been no reports of first-onset BCC in the groin area in an NBCCS patient of any race. In conclusion, long-term follow-up, complete and comprehensive skin examination, including non-sun-exposed areas, even if a detailed history reveals no arsenic ingestion or radiation exposure to these areas, is strongly recommended for NBCCS patients.

## Statement of Ethics

The study was conducted according to The Declaration of Helsinki Principles. The patient gave written informed consent.



Downloaded by:
Hokkaido Daigaku
133.87.70.39 - 11/13/2017 3:27:08 AM

## Disclosure Statement

The authors have no conflicts of interest to declare.

## References

1 Gorlin RJ, Goltz RW: Multiple nevoid basal-cell epithelioma, jaw cysts and bifid rib. A syndrome. N Engl J Med 1960;262:908–912.
2 Farndon PA, Del Mastro RG, Evans DG, et al: Location of gene for Gorlin syndrome. Lancet 1992;339:581–582.
3 Gorlin RJ: Nevoid basal cell carcinoma syndrome. Dermatol Clin 1995;13:113–125.
4 Gloster HM Jr, Brodland DG: The epidemiology of skin cancer. Dermatol Surg 1996;22:217–226.
5 Giuliani M, Di Stefano L, Zoccali G, et al: Gorlin syndrome associated with basal cell carcinoma of the vulva: a case report. Eur J Gynaecol Oncol 2006;27:519–522.
6 Kimonis VE, Goldstein AM, Pastakia B, et al: Clinical manifestations in 105 persons with nevoid basal cell carcinoma syndrome. Am J Med Genet 1997;69:299–308.
7 Shanley S, Ratcliffe J, Hockey A, et al: Nevoid basal cell carcinoma syndrome: review of 118 affected individuals. Am J Med Gene. 1994;50:282–290.
8 Evans DG, Ladusans EJ, Rimmer S, et al. Complications of the naevoid basal cell carcinoma syndrome: results of a population based study. J Med Gene. 1993;30:460–464.
9 Endo M, Fujii K, Sugita K, et al. Nationwide survey of nevoid basal cell carcinoma syndrome in Japan revealing the low frequency of basal cell carcinoma. Am J Med Genet 2012;158A:351–357.

**Table 1.** Intercountry comparison of BCCs in NBCCS patients

| Authors | Country | Race | Patients, n | Main location | Mean age at first onset, years | Age at first onset, years | Frequency in patients over age 20, % | Frequency in patients over age 40, % |
|---|---|---|---|---|---|---|---|---|
| Kimonis et al. [6], 1997 | USA | Caucasian | 90 | face | 21.5 | 3–53 | 90 | 97 |
| | | African-American | 13 | not described | | | 20 | not described |
| | | Mexican/Asian | 2 | not described | | | not described | not described |
| Shanley et al. [7], 1994 | Australia | Australian | 118 | not described | 20.3 | not described | 85 | 95 |
| Evans et al. [8], 1993 | UK | Caucasian | 84 | face | not described | not described | 73 | 90 |
| Endo et al. [9], 2012 | Japan | Japanese | 157 | not described | 37.4 | 4–69 | 51.4 | 71.7 |



Downloaded by:
Hokkaido Daigaku
133.87.70.39 - 11/13/2017 3:27:08 AM

Case Rep Oncol 2015;8:536–539
DOI: 10.1159/000442148
© 2015 The Author(s). Published by S. Karger AG, Basel
www.karger.com/cro



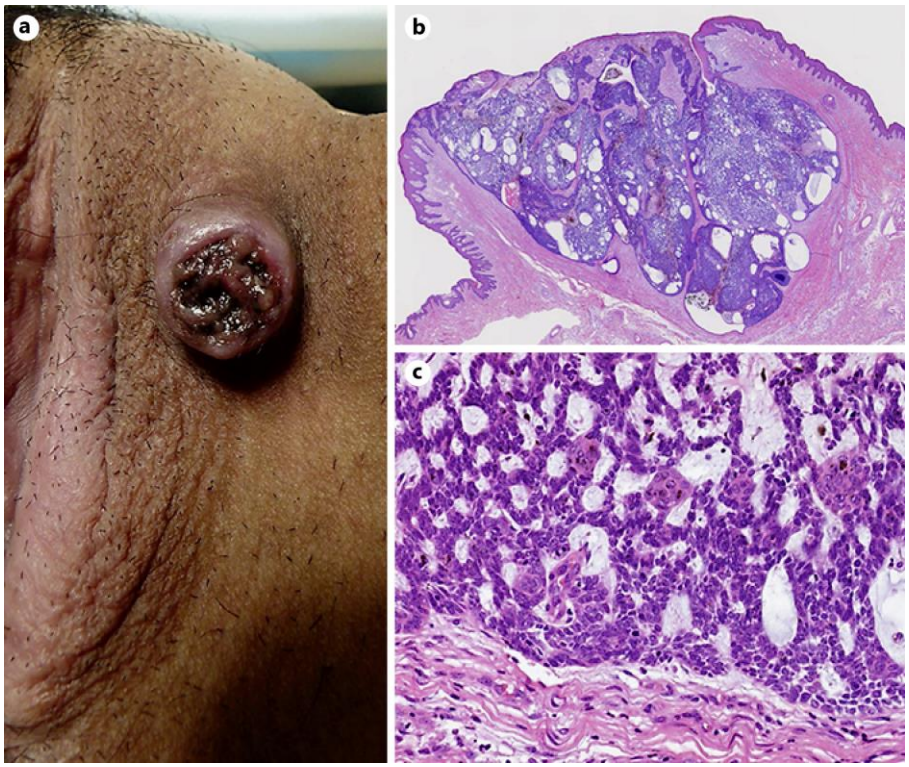


**Fig. 1.** **a** The lesion on the left groin: a dome-shaped nodule of normal skin color to reddish color with ulceration at the center. **b** Histopathologic examination under hematoxylin-eosin stain shows alveolar structures of various sizes with basaloid tumor cells (original magnification ×4). **c** Peripheral palisading patterns and clefting (hematoxylin-eosin staining; original magnification ×200).



Downloaded by:
Hokkaido Daigaku
133.87.70.39 - 11/13/2017 3:27:08 AM