Incidence of anterior disc displacement without reduction of the temporomandibular joint in patients with dentofacial deformity

Kazuhiro Ooi[1,4], Nobuo Inoue[2], Kazuhiro Matsushita[1], Hiro-o Yamaguchi[1], Tadashi Mikoya[1], Kazuyuki Minowa[3], Shuichi Kawashiri[4], Satoshi Nishikata[5], Kanchu Tei[1]

[1] Oral and Maxillofacial Surgery, Department of Oral Patho-biological Science, Graduate School of Dental Medicine, Hokkaido University, Kita 13 Nishi 7 kita-ku, Sapporo, Hokkaido 060-8586, Japan

[2] Gerodontology, Department of Oral Health Science, Graduate School of Dental Medicine, Hokkaido University, Kita 13 Nishi 7 kita-ku, Sapporo, Hokkaido 060-8586, Japan

[3] Dental Radiology, Department of Oral Health Science, Graduate School of Dental Medicine, Hokkaido University, Kita 13 Nishi 7 kita-ku, Sapporo, Hokkaido 060-8586, Japan

[4] Department of Oral and Maxillofacial Surgery, Graduate School of Medical Science, Kanazawa University, 13-1 Takaramachi, Kanazawa, Ishikawa, 920-8641, Japan

[5] Oral and Maxillofacial Surgery, Sapporo Higashi Tokushukai Hospital, 3-1 Kita 33 Higashi 14 higashi-ku, Sapporo, Hokkaido 060-0033, Japan

Correspondence:
Kazuhiro Ooi: Oral and Maxillofacial Surgery, Department of Oral Patho-biological Science, Graduate School of Dental Medicine, Hokkaido University, Kita 13 Nishi 7 kita-ku, Sapporo 060-8586, Japan.
Tel: +81-11-706 4283; FAX: +81-11-706 4283
E-mail: ooi@den.hokudai.ac.jp

Funding : Not to declare

Key words: anterior disc displacement without reduction; dentofacial deformity; magnetic resonance imaging; anterior open bite; mandibular asymmetry

Short title : ADDwoR of TMJ in dentofacial deformity

Abstract

This study aimed to investigate the incidence of anterior disc displacement without reduction (ADDwoR) of the temporomandibular joint (TMJ) in patients with dentofacial deformity. Eighty-eight female patients (176 joints) with Skeletal Class III and 33 female patients (66 joints) with Skeletal Class II malocclusion with or without anterior open bite and asymmetry were evaluated. Magnetic resonance imaging (MRI) of the TMJ was used for diagnosis of ADDwoR. Statistical analysis was performed to examine the relationship between ADDwoR and skeletal structure. ADDwoR was present in 37 (56.1%) of the 66 joints in class II compared to 34 (19.3%) of the 176 joints in class III ($p < 0.05$). In class III, ADDwoR was significantly more common in joints with mandibular asymmetry (24 (32.4%) of 74) than in joints with open bite (9 (14.5%) of 62) and joints with open bite and without mandibular asymmetry (1 (2.6%) of 38). In class II, ADDwoR was significantly less common in joints with mandibular asymmetry and without open bite (1 (12.5%) of 8). ADDwoR was only observed on the deviated side in

both class III and class II with mandibular asymmetry. The prevalence of ADDwoR was quite different according to dentofacial morphology.

INTRODUCTION

Dentofacial morphology and symptoms of temporomandibular disorder are thought to be related. Recent reports have shown that symptoms of temporomandibular disorder are highly associated with mandibular asymmetry[1], open bite[2], and Skeletal Class II malocclusion[3], and less common with Skeletal Class III malocclusion[2]. However, these reports are only based on the relationship between subjective symptoms of temporomandibular disorder and dentofacial morphology. Few objective studies using MR imaging have been done.

Recently, we reported that anterior disc displacement without reduction (ADDwoR) and bone changes of the mandibular condylar head were significantly more common in patients with skeletal open bite than in volunteers without dentofacial deformity[4]. This shows that skeletal open bite is one of the factors associated with the incidence of ADDwoR and bone changes of the mandibular condylar head. However, bone changes of the mandibular condylar head are thought to generally occur secondary to ADDwoR[5], but they can occur without ADDwoR. In the former, mandibular condylar resorption occurs following ramus height decreases; if this change is unilateral, it can cause facial

asymmetry, and if it is bilateral, it can cause open bite. In the latter, bone changes occur at a stage of development of the mandibular condylar head, and disc displacement is thought to occur after mandibular condylar resorption, but the details are unknown.

In this way, ADDwoR with dentofacial deformity is a very important factor to understand the development and function of the mandible. However, the incidence of ADDwoR in dentofacial deformity has not been sufficiently investigated. Therefore, an objective imaging study was performed to determine the relationship between the incidence of ADDwoR and dentofacial structure with dentofacial deformity.

MATERIALS AND METHODS

The subjects in this study were 121 women with dentofacial deformity, including 88 with Skeletal class III malocclusion (176 joints) and 33 with Skeletal class II malocclusion (66 joints) with or without mandibular asymmetry and open bite, who underwent orthognathic surgery at Hokkaido University Hospital, Sapporo, Japan. The median age at the time of surgery was 25 years (range, 14-48 years). None of the patients had previously been diagnosed with juvenile rheumatoid arthritis. Patients with

sagittal skeletal deformities were included in this study. Mandibular asymmetry was defined as >2 mm deviation between the menton and facial midline, and open bite was defined as <0 mm overbite. No men were included in this study to avoid skewing the cephalometric measurements by sex-related differences. The subjects included some women with clinically detectable TMJ signs and symptoms (capsular pain, joint sounds, masticatory muscle tenderness) and some without symptoms. The TMJs of patients with dentofacial deformity were examined using MR imaging to assess the position of the disc before the start of orthodontic treatment. Tesla 3.0 MRI machine was used. The position of the disc was examined using sagittal and coronal slices and T1-weighted or proton-density MR imaging with the mouth closed and open. The slice thickness was 3 mm, and the slice gap was 0.5 mm on all MR images. The bilateral surface coil for TMJ was used. On PDWI, TR (repetition time) was 1300 msec, and TE (echo time) was 30 msec. On T1WI, TR (repetition time) was 700 msec, and TE (echo time) was 15 msec. Pixel size on both PDWI and T1WI was 512×192. Software processing of the MR images was not performed after the MRI had been completed. Results of MRI were classified as with or without ADDwoR by Radiologist who trained as an MRI specialist. Subjects were divided into the Skeletal class III group with mandibular asymmetry or

open bite and the Skeletal class II group with mandibular asymmetry or open bite. ADDwoR was considered present if the disk was displaced anteriorly relative to the posterior slope of the articular eminence and the head of the condyle, but without reduction of the disk on mouth opening (Fig.1). The prevalence of ADDwoR was examined in each group, and statistical analysis was performed using the Chi-squared test. P values of less than 0.05 were considered significant.

This study comply with the principles stated in the Declaration of Helsinki Ethical Principles for Medical Research Involving Human Subjects, adopted by the 18th World Medical Assembly, Helsinki, Finland, June 1964, and as amended most recently by the 64th World Medical Assembly, Fontaleza, Brazil, October 2013.

The work has been approved by Hokkaido University Research Ethical Committee (Ref. No. 010-0285).

RESULTS

Prevalence of ADDwoR in patients with Skeletal Class III and Class II

ADDwoR was observed in 34 (19.3%) of 176 joints in Skeletal Class III and in 37

(56.1%) of 66 joints in Skeletal Class II.; the difference was significant (Fig 2).

Prevalence of ADDwoR in patients with Skeletal class III malocclusion and Skeletal class II malocclusion according to with or without open bite and facial asymmetry

ADDwoR was significantly more common in Skeletal Class III with mandibular asymmetry (24 (32.4%) of 74 joints) than in Skeletal Class III with open bite (9 (14.5%) of 62 joints). ADDwoR was observed in 14 (50.0%) of 28 joints in Skeletal Class II with mandibular asymmetry and in 25 (59.5%) of 42 joints in Skeletal Class II with open bite; the difference was not significant (Table 1).

Prevalence of ADDwoR in patients with Skeletal class III malocclusion according to with or without open bite and mandibular asymmetry

ADDwoR was observed in 9 (14.1%) of 64 joints without open bite and asymmetry, 1 (2.6%) of 38 joints with open bite and without mandibular asymmetry, 16 (32.0%) of 50 joints with mandibular asymmetry and without open bite, and 8 (33.0%) of 24 joints with open bite and mandibular asymmetry. ADDwoR was observed only on the deviated

side in mandibular symmetry (Table 2).

Prevalence of ADDwoR in patients with Skeletal class II malocclusion according to with or without open bite and mandibular asymmetry

ADDwoR was observed in 11 (68.7%) of 16 joints both without open bite and mandibular asymmetry, 12 (54.5%) of 22 joints with open bite and mandibular asymmetry, 1 (12.5%) of 8 joints with mandibular asymmetry and without open bite, and 13 (65.0%) of 20 joints both with open bite and mandibular asymmetry. ADDwoR was only observed on the deviated side in mandibular asymmetry (Table 3).

DISCUSSION

It has been reported that symptoms of temporomandibular disorders are more frequent in patients with open bite and mandibular asymmetry, however these symptoms are less in patients with mandibular protrusion than in persons with normal occlusion[6]. Temporomandibular disorder has been found to be more common with open bite, mandibular asymmetry, and mandibular retrusion than with other dentofacial

deformities[7]. On the other hand, it has also been reported that there is no significant relationship between dentofacial deformity and temporomandibular disorder, though 62.8% of patients with dentofacial deformities had symptoms of temporomandibular disorder before orthognathic surgery[8]. One study found no relationship between cephalometric analysis and temporomandibular disorder[9]. Further, in patients with dentofacial deformities who underwent temporomandibular joint arthrography, 57% of patients had anterior disc displacement and 53% had temporomandibular joint pain, but there were no relationships among anterior disc displacement, clinical symptoms, and dentofacial morphology[10]. In contrast, anterior disc displacement was reported to be more common on the deviated side of temporomandibular joints with mandibular asymmetry on MR imaging[11]. A decreased posterior facial height and backward position and rotation of the mandible are principal characteristics associated with TMJ disk displacement[12,13]. Thus, opinions about the association between temporomandibular disorder and dentofacial deformity are divided.

Recently, we reported that anterior disc displacement was more common with open bite than in volunteers without dentofacial deformity, and bony changes were more common than with closed lock in patients with temporomandibular joint disorder[4]. We

want to verify prevalence of ADDwoR between ClassⅢ and ClassⅡ, because this previous study was predominantly ClassⅡ. Since the incidence of temporomandibular disorder is low in patients with mandibular protrusion[2] and high in patients with mandibular retrusion[3], ADDwoR was 3 times more common in patients with mandibular retrusion than in patients with mandibular protrusion in this study. In the present study, Skeletal Class III and II groups were divided into those with or without open bite or mandibular asymmetry, because it is thought that the rate of temporomandibular disorder is generally high with open bite and mandibular asymmetry. The prevalence of ADDwoR was almost 2 times higher with mandibular asymmetry than with open bite in Skeletal Class III, but there was no significant difference in Skeletal Class II. This result indicates that the association of ADDWoR with mandibular asymmetry is stronger in Skeletal Class III than in Skeletal Class II. In the Class III patient, the open bite and the development of asymmetry is related to the excessive growth pattern of the condyles and the facial morphology[14]. Open bites in Class III patients are more commonly associated with accelerated condylar and mandibular growth and high occlusal plane angle facial mophologies. Class III patients with low occlusal plane angle facial morphologies do not commonly demonstrate an

open bite. Mandibular asymmetry in Class III patients is almost always related to excessive or accelerated growth of the condyle and mandible on the non-deviated side, that over-loads the contralateral (deviated) side that can cause the anterior disc dislocation[15]. Thus, Class III's with open bites and asymmetries are commonly associated with accelerated growth of the condyles. In the Class II patients, open bites and asymmetries are commonly related to TMJ pathologies that are causing condylar resorption (the opposite of what causes the open bites and asymmetries in the Class III patients). The most common causes of condylar resorption in the Class II patient are: 1. Adolescent internal condylar resorption (AICR) where articular discs are anteriorly displaced (and commonly non-reducing) by the nature of the TMJ pathology. 2. Reactive arthritis with or without anteriorly disc dislocation. 3. Connective tissue autoimmune diseases[14,15]. Thus, the development of the open bite and asymmetry in Class III patients has a totally different TMJ etiology as compared to the Class II patients.

Furthermore, Skeletal Class III and Skeletal Class II were classified into 4 groups to determine the incidence of ADDwoR in this study. With mandibular asymmetry, the prevalence of ADDwoR was only observed at deviated side. The prevalence of

ADDwoR in Skeletal Class III with open bite alone was only 2.6%, and half that rate was seen without both open bite and mandibular asymmetry**.** This incidence is extremely low because the incidence of ADDwoR in volunteers without dentofacial deformity was reported to be 7%[11]. This suggests that the prevalence of ADDwoR in Skeletal Class III associated only with open bite is extremely small. Given this, it is desirable to investigate the details of the temporomandibular joint in dentofacial morphology to determine the etiology of overgrowth of the mandible. It would be expected that skeletal Class III patients with or without ADDwoR associated only with anterior open bite is extremely small. Symmetric prognathic cases rarely have anteriorly displaced discs; however, in the Class III asymmetry case, where the condyle on the non-deviated side overgrows creating the asymmetry, increases the loading on the opposite joint that contributes to the anteriorly displacement of the disc on the contralateral side. However, in the Class II patient with asymmetry, the ADDwoR is involved with the condyle on the deviated side that may be undergoing unilateral condylar resorption causing a shift of the mandible in the Class II patient, frequently related to AICR versus reactive arthritis versus connective tissue autoimmune disease[16].

In Skeletal Class II, the prevalence of ADDwoR with mandibular asymmetry alone

was 12.5%, with no bilateral cases. However, it was observed in 54.5% to 68.7% of the other 3 groups, with bilateral cases found in Skeletal Class III. These results indicate that the process of ADDwoR expression differs between Skeletal Class III and Skeletal Class II. An investigation of more detailed temporomandibular joints in Skeletal Class II associated only with mandibular asymmetry would be useful in the future. Skeletal Class III and Skeletal Class II had ADDwoR only on the deviated side with mandibular asymmetry. These results suggest that unilateral over-development of the condyle/mandible in Class III patients and unilateral condylar resorption in Class II patients is strongly associated with ADDwoR.

It is known that condylar cartilage is important as the starting point of mandibular bone development, and endochondral ossification, which was observed mainly on the mandibular condyle, is important for the development of mandibular bone. Whether mandibular bone formation on the displacement side decreases because a disorder occurs in the cartilage of the condyle due to anterior disc displacement or mandibular asymmetry occurs first is unknown**,** but these results mean that it is important to elucidate these clinical conditions, whether they occur at the same time because anterior disc displacement occurs continuously after the abnormality has occurred or in the

formation of the condyle. It would be desirable to follow-up the temporomandibular joints of young patients with mandibular asymmetry and anterior disc displacement in the future.

The degenerative change of the mandibular condyle is thought to have a close relationship to ADDwoR[17], but ADDwoR without degenerative change of the mandibular condyle has also been reported[3]. Katzberg et al[18] and Kurt et al[19] reported vertical shortening of ramus height by regressive change, and that growth suppression of the mandibular condyle with progression of the temporomandibular disorder may cause open bite. Chen et al[3] reported that condylar degenerative changes may lead to deformities of the jaw, in turn resulting in decreased vertical dimensions of the proximal mandibular segments and open bite. We assume that probably most of these patients are Class II's with either AICR, reactive arthritis, or CT/AI. We reported that bone changes occurred in 79% of temporomandibular joints with ADDwoR and open bite, ADDwoR appeared and increased the mandibular plane angle, bone changes developed and increased the ramus plane angle, and some patients with skeletal open bite showed worn facets and no protuberances on the incisal edges[20]. These results suggest that clockwise rotation occurred, resulting in mandibular condylar resorption for various reasons in

ADDwoR in patients who had dental articulation contact of the incisal edges in both the maxilla and mandible. Vertical malocclusion develops as a result of the interaction of many different etiologic factors, including thumb and finger sucking, lip and tongue habits, airway obstruction, and true skeletal growth abnormalities[21]. However, this is not clear, since mandibular condylar resorption with progression of temporomandibular disorder is one of the causes of open bite when looking at the present and previous results. We need to investigate more to pediatric patients because the onset of "vertical malocclusion" in teenage and adult patients, is more likely associated in Class II patients with condylar resorption. In a study using a three-dimensional finite element model of mandibular bone including the temporomandibular joint, compression stress in the posterior region and tensile stress in the frontal region at the temporomandibular joint increased according to the mandibular plane angle or the gonial angle[22]. These reports suggest that it can become one of the factors in which some dentofacial morphologies cause temporomandibular disorders**.** It seems reasonable to suggest that skeletal Class II profiles and hyperdivergent growth patterns are likely associated with an increased frequency of TMJ disc displacement and degenerative disorders[23]. In the present study, it was found that the expression of ADDwoR was very different with

differences in dentofacial morphology. These results show that dentofacial morphology is closely associated with anterior disc displacement, and that the state of the temporomandibular joint is extremely important in the development of dentofacial structure. In the future, it is particularly necessary to investigate the kind of change that occurs over the long term in dentofacial morphology by observing the temporomandibular joints of patients with open bite and mandibular asymmetry and temporomandibular disorders to better determine the relationships with temporomandibular disorder or the development of dentofacial structure.

Conflict of interest

We declare that we have no conflicts of interest.

Role of the funding source

There was no source of funding for this research.

Ethical approval

Approval was given by Hokkaido University Hospital Ethics Committee (Ref. No 010-0285)

Patient consent

Not required.

References

1. Fushima K, Akimoto S, Takamoto T, Kamei T, Satoh S, Suzuki Y. Incidence of Temporomandibular Joint Disorders in Patients with Malocclusion. *J Jpn Soc TMJ* 1989;**1**:40-50.
2. Fujisaki T, Katoh Y, Fujita Y, Sakamoto M, Kamata S, Igarashi K, Hiyama S, Kuroda T. TMJ dysfunction questionnaire on patients with malocclusion. *J Jpn Soc TMJ* 1993;**5**:320-30.
3. Chen YJ, Shih TT, Wang JS, Wang HY, Shiau YY. Magnetic resonance images of the temporomandibular joints of patients with acquired open bite. *Oral Surg Oral Med Oral Pathol Oral Radiol Endod* 2005;**99**:734-42.
4. Yura S, Ooi K, Kadowaki S, Totsuka Y, Inoue N. Magnetic resonance imaging of the temporomandibular joint in patients with skeletal open bite and subjects without dentofacial abnormalities. *Br J Oral Maxillofac Surg* 2010;**48**:459-61
5. Wilkes CH. Internal derangements of the temporomandibular joint. Pathological variations. *Arch Otolarryngol Head Neck Surg.* 1989 ;115 : 469-77.
6. McNamara JA Jr, Seligman DA, Okeson JP. Occlusion, Orthodontic Treatment and temporomandibular disorders : a review. *J Orofac Pain* 1995 ; 9: 73-90.
7. Yoshida N, Itoh R, Saitoh T, Ota F, Hirose T, Matsumoto K. Clinical evaluation of incidence of temporomandibular symptoms in patient of jaw deformity *J Jpn Soc Orthod* 2000;**1**:64-71.
8. Laskin DM, Ryan WA, Greene CS. Incidence of temporomandiblar symptoms in patients with major skeletal malocculusions －A survey of oral and maxillofacial surgery training programs. *Oral Surg Oral Med Oral Pathol* 1986;**61**:537-41.
9. Jeon DM, Jung WS, Mah SJ, Kim TW, Ahn SJ. The effects of TMJ symptoms on skeletal morphology in orthodontic patients with TMJ disc displacement. *Acta Odontol Scand* 2014;**72**:776-82.
10. Dahlberg G, Petersson A, Westesson PL, Eriksson L. Disc Displacement and temporomandiblar joint symptoms in orthognathic surgery patients. *Oral Surg Oral Med Oral Pathol* 1995;**76**:237-77.
11. Yura S, Inoue N, Kurihashi K, Izumiyama Y, Asada N, Mabuchi A,Oda M, Kadowaki S, Yamaguchi H, Totsuka Y. Relation between disc displacement of the temporomandibular joint and skeletal structure in patients with jaw deformity.

J Jpn Oral Maxillo Fac Surg 2001;**47**:105-8.

12 Ahn SJ, Baek SH, Kim TW, Nahm DS. Discrimination of internal derangement of temporomandibular joint by lateral cephalometric analysis. *Am J Orthod Dentofacial Orthop* 2006;**130**:331–9.

13 Bertram S, Moriggl A, Neunteufel N, Rudisch A, Emshoff R. Lateral cephalometric analysis of mandibular morphology: discrimination among subjects with and without temporomandibular joint disk displacement and osteoarthrosis. *J Oral Rehabil* 2012;**39**:93–9.

14 Wolford LM, Morales-Ryan CA, Garcia-Morales P, Perez D: Surgical Management of Mandibular Condylar Hyperplasia Type 1. *Bayl Univ Med Cent Proc* 2009; **22**:321-9.

15 Wolford LM, Movahed R, Perez D: A Classification System for Conditions Causing Condylar Hyperplasia. *J Oral Maxillofac Surg* 2014;**72**:567-95.

16 Wolford LM, Goncalves JR: Condylar Resorption of the Temporomandibular Joint: How Do We Treat It? *Oral and Maxillofacial Surgery Clinics of North America* 2015; **27**:47-67.

17. Gidarakou IK, Tallents RH, Stein S, Kyrkanides S, Moss ME. Comparison of skeletal and dental morphology in asymptomatic volunteers and symptomatic patients with unilateral disk displacement with reduction. *Angle Orthod* 2004 ; **74**: 212-9.

18. Katzberg R.W, Tallents R.H, Hayakawa K, Miller T.L, Goske M.J, Wood B.P. Internal derangements of the temporomandiblar joint. Findings in the pediatric age group. *Radiology* 1985;**154**:125-8.

19.Kurt S, Steven P, Pollei, Clyde H.Wilkes. Pediatric internal derangements of the temporomandiblar joint : Effect on facial development. *Am J Orthod Dentfac Orthp* 1993;**104**:51-9.

20. Ooi K, Yura S, Inoue N, Totsuka Y. Factors related to the incidence of anterior disc displacement without reduction and bony changes of the temporomandibular joint in patients with anterior open bite. *Oral Maxillofac Surg* 2014;**18**:397-401.

21. Ngan P, Fields HW. Open bite: a review of etiology and management. *Pediatr Dent* 1997;**19**:91-8.

22.Tanaka E. Stress Distributions in the TMJ during Clenching. *J Osaka Dent* 1993 ; **38**:131-60.

23 Manfredini D, Segù M, Arveda N, Lombardo L, Siciliani G, Alessandro Rossi, Guarda-Nardini L. Temporomandibular Joint Disorders in Patients With Different Facial Morphology. A Systematic Review of the Literature *J Oral Maxillofac Surg* 2016 ;**74** :29-46.

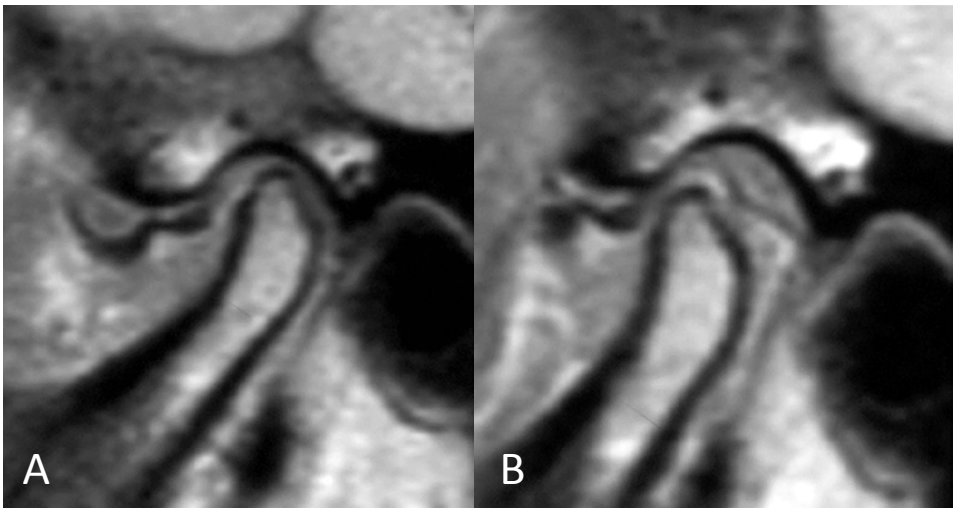

Fig 1. MR images of Anteriorly Displaced Discs without Reduction (ADDwoR). (A: mouth closed, B: mouth open)
ADDwoR was considered present if the disk was displaced anteriorly relative to the posterior slope of the articular eminence and the head of the condyle, but without reduction of the disk on mouth opening.

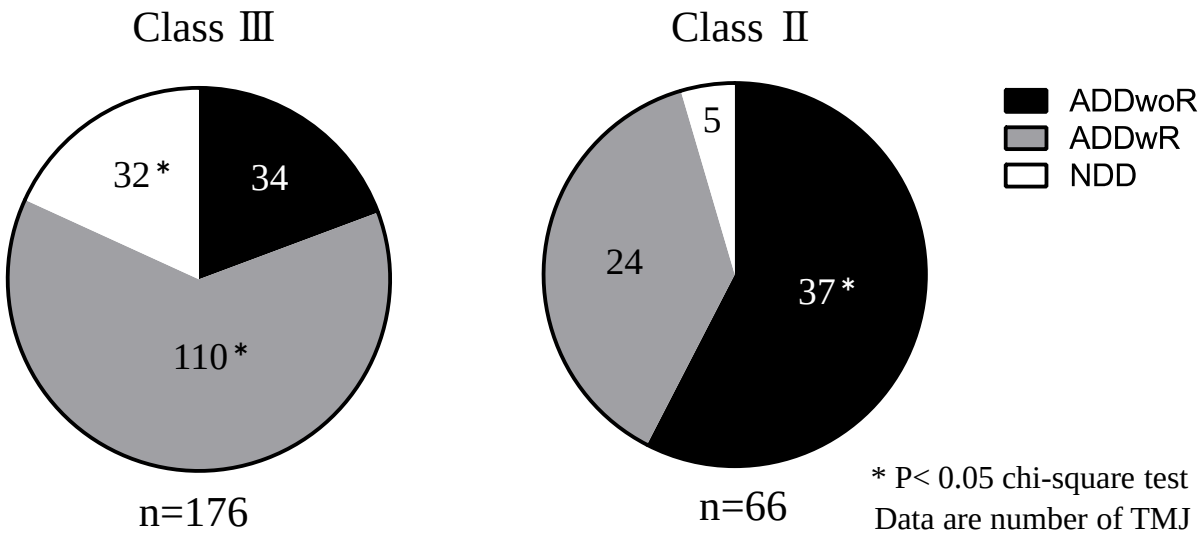

Fig. 2. Prevalence of TMJs with ADDwoR in patients with Skeletal class Ⅲ and Ⅱ

ADDwoR: Anteriorly Displaced Discs without Reduction
ADDwR: Anteriorly Displaced Discs with Reduction
NDD: Non-Displaced Discs

Table 1. Prevalence of joints with ADDwoR in patients with Skeletal class Ⅲ and Ⅱ according to with or without open bite and mandibular asymmetry.

	Class Ⅲ			Class Ⅱ		
	OB (n=62)	MA (n=74)	P value	OB (n=42)	MA (n=28)	P value
ADDwoR	9 (14.5)	24 (32.4)	0.0152 *	25 (59.5)	14 (50.0)	0.4319
ADDwR	41 (66.1)	42 (56.8)	0.2643	12 (28.6)	13 (46.4)	0.1266
NDD	12 (19.4)	8 (10.8)	0.1612	5(11.9)	1 (3.6)	0.2224

* P< 0.05 chi-square test
Data are number of TMJ (%).

ADDwoR: Anteriorly Displaced Discs without Reduction
ADDwR: Anteriorly Displaced Discs with Reduction
NDD: Non-Displaced Discs
OB: open bite MA: mandibular asymmetry

Table 2. Prevalence of TMJs with ADDwoR in patients with Skeletal class Ⅲ according to with or without open bite and mandibular asymmetry.

	ADDwoR (n=TMJ)	bilateral			unilateral				
		ADDwoR	ADDwR	NDD	ADDwoR/ ADDwR	ADDwoR/ NDD	ADDwR/ NDD	ADDwoR	
								DS	NDS
OB/MA(−/−) (n=32)	9 / 64 (14.1)	3	18	7	3	0	1		
OB/MA(+/−) (n=19)	1 / 38 (2.6)*	0	13	4	1	0	1		
OB/MA(−/+) (n=25)	16 / 50 (32.0)	4	10	2	8	0	1	8	0
OB/MA(+/+) (n=12)	8 / 24 (33.0)	2	5	1	3	1	0	4	0

Data are number of patients (%).

ADDwoR: Anteriorly Displaced Discs without Reduction
ADDwR: Anteriorly Displaced Discs with Reduction
NDD: Non-Displaced Discs
OB: open bite MA: mandibular asymmetry
DS: deviated side NDS: non-deviated side
(+) : with (−) : without

* P< 0.05

Table 3. Prevalence of TMJs with ADDwoR in patients with Skeletal class Ⅱ according to with or without open bite and mandibular asymmetry.

	ADDwoR (n=TMJ)	bilateral			unilateral				
		ADDwoR	ADDwR	NDD	ADDwoR/ ADDwR	ADDwoR/ NDD	ADDwR/ NDD	ADDwoR	
								DS	NDS
OB/MA(−/−) (n=8)	11/ 16 (68.7)	5	2	0	1	0	0		
OB/MA(+/−) (n=11)	12 / 22 (54.5)	5	2	1	2	0	0		
OB/MA(−/+) (n=4)	1/ 8 (12.5)*	0	3	0	1	0	0	1	0
OB/MA(+/+) (n=10)	13 / 20 (65.0)	3	0	0	6	1	0	7	0

Data are number of patients (%).

ADDwoR: Anteriorly Displaced Discs without Reduction
ADDwR: Anteriorly Displaced Discs with Reduction
NDD: Non-Displaced Discs
OB: open bite MA: mandibular asymmetry
DS: deviated side NDS: non-deviated side
(+) : with (−) : without

* P< 0.05