Japanese Perspective in Surgery for Thoracoabdominal Aortic Aneurysms

Norihiko Shiiya, MD, PhD[1)], Naoki Washiyama, MD, PhD[1)], Kazumasa Tsuda, MD[1)], Ken Yamanaka, MD[1)], Daisuke Takahashi, MD[1)], Katsushi Yamashita, MD, PhD[1)], Kayoko Natsume, MD[1)], Yuki Takeuchi, MD[1)], Suguru Kubota, MD, PhD[2)], Yoshiro Matsui, MD, PhD[2)]

1) First Department of Surgery, Hamamatsu University School of Medicine

2) Department of Cardiovascular and Thoracic Surgery, Hokkaido University Graduate School of Medicine

Correspondence

First Department of Surgery, Hamamatsu University School of Medicine

1-20-1, Handayama, Higashi-ku, Hamamatsu 431-3192, Japan

TEL +81-53-435-2276, FAX +81-53-435-2272

E-mail shiyanor@hama-med.ac.jp

Keywords: thoracoabdominal aortic aneurysm, spinal cord protection, open surgical repair

Abstract

Objective

Operative mortality and morbidity after thoracoabdominal aortic surgery remain high. We report our strategy and outcomes, especially those of spinal cord protection.

Methods

Outcomes of 178 patients (age: 26 to 88 years) who underwent thoracoabdominal aortic replacement were retrospectively analyzed. Sixty-five had aortic dissection, 14 had infected aneurysms and 22 presented with rupture. Operations were non-elective in 24 and redo through re-thoracotomy in 21. Extent of replacement was Crawford-I in 39, II in 26, III in 78 and IV in 35. Staged repair was recently preferred, which resulted in decrease in extent II repair and increase in redo since 2009. Operations were performed under distal aortic perfusion and multi-segmental sequential repair to maximize collateral blood flow, and deep hypothermic circulatory arrest was preserved for those requiring open aortic anastomosis (n=20). A total of 166 separate grafts were used for intercostal reconstruction in 88 patients, which was guided by preoperative feeding artery localization. Their patency was studied by postoperative MD-CT in 74 patients for 145 grafts.

Results

There were 3.9% hospital mortality and 5.1% spinal cord injury. Preoperative feeding artery localization resulted in reduced number of reconstruction and improved patency, and grafts

connecting to the feeding artery was patent in 92%. Results of redo operations were not different (no mortality and spinal cord injury) from the de novo operations.

Conclusions

Our concept of spinal cord protection, which was based on selective intercostal reconstruction while maximizing spinal cord collateral blood flow, seems justified.

Introduction

Despite the advance in cardiovascular surgery, operative mortality and morbidity after thoracoabdominal aortic surgery remain high. Although Coselli and colleagues[1] have reported excellent outcomes in 3309 patients, there were 7.5% operative deaths, 5.4% permanent ischemic spinal cord injury and 5.7% permanent renal failure even by this most experienced group. In the 2014 annual nationwide survey by the Japanese Association for Thoracic Surgery[2], there were 633 thoracoabdominal aortic operations in Japan, with 10.7% hospital mortality rate. To improve the outcomes, reducing blood loss and protecting vital organs, especially the spinal cord, are pivotal. We report our strategy and outcomes of open surgical repair for the thoracoabdominal aortic aneurysms.

Subjects and Methods

Outcomes of 178 patients who underwent thoracoabdominal aortic replacement under supervision of the first author at two institutions (August 1994-January 2009 at Hokkaido University Hospital, n=132, and March 2009-May 2017 at Hamamatsu University Hospital, n=46) were retrospectively reviewed. There were 125 men and 53 women, with the age ranging from 26 to 88 (median 70) years old. Sixty-five had aortic dissection, 14 had infected aneurysms and 22 presented with rupture. Operations were non-elective in 24. Seventy-five patients had a history of previous aortic operation; ascending aorta to aortic arch in 38, descending aorta in 15, thoracic endovascular aortic repair in 2, thoracoabdominal aorta in 6 and infrarenal abdominal aorta in 25. Twenty-one of them underwent

surgery through a re-thoracotomy. Extent of replacement was Crawford-I in 39, II in 26, III in 78 (extensive 41, localized Safi V 37) and IV in 35.

Operative technique

For the extent I or II repair, pleural cavity was entered through the fifth intercostal space. Incision was extended into the fourth interspace dorsally and sixth anteriorly with division of costal margin at sixth. Recently axillo-lateral incision[3] has been introduced instead of posterolateral thoracotomy to better expose the aortic arch and preserve the thoracodorsal artery as a potential collateral source to the spinal cord[4]. Care was taken not to manipulate the lung during heparinization, and separate bronchial intubation was used to maintain the left lung deflated until heparin was reversed. Abdominal aorta was exposed through a total retroperitoneal approach with circumferential division of the diaphragm. For reconstruction of the visceral and renal arteries, a Dacron prosthesis provided with four side-arm grafts was used.

Circulatory adjuncts

Femoro-femoral partial cardiopulmonary bypass with a closed-loop circuit incorporating a soft reservoir bag was used for distal aortic perfusion with reduced heparin dosage[5, 6]. Deep hypothermic total cardiopulmonary bypass was preserved for those requiring open aortic anastomosis (n=20). Visceral and renal arteries were selectively perfused through a side-arm of the circuit when necessary.

Spinal cord protection strategy

Neurophysiological monitoring by evoked spinal cord potentials[7] (until January 2009, n=53) or transcranial myogenic motor evoked potentials (TC-MEP) (since April 2006, n=53), cerebrospinal fluid drainage (CSFD, since August 1996, n=122) and continuous naloxone infusion (1μg/kg/hour, since April 1999, n=137) were used. Preoperative multi-detector row computed tomography (MD-CT) to identify the spinal cord feeding artery was introduced in September 2001[8], which was available in 116 patients. To maximize the collateral blood flow during reconstruction of the spinal cord feeding arteries, site of cross-clamping and sequence and location of intercostal reconstruction were determined preoperatively according to the information of spinal cord blood supply by MD-CT. The purpose of neurophysiological monitoring has thus changed from intraoperative feeding artery identification[7] to assessment of the adequacy of collateral blood flow. Maintaining blood flow to the neighboring intercostal arteries was considered mandatory during reconstruction of a solitary hairpin shaped feeding artery[9]. This was achieved by preceding reconstruction of a proximal intercostal artery by segmental cross-clamping while the critical artery was perfused through distal aortic perfusion[10]. Separate tube grafts were used for intercostal reconstruction in most cases. To improve the patency of reconstruction, a larger size (12-mm) graft was recently preferred (**Figure 1**). They were sutured to the aortic wall first, and were connected to the main graft afterward to make its length shortest. Staged repair, where extent II repair was converted to the descending thoracic

replacement followed by extent III/IV repair, has been preferred since 2009 to allow extra-thoracic collateral pathway development[11].

Patency of separate tube graft reconstruction of the intercostal arteries

A total of 166 intercostal arteries were reconstructed with the separate tube graft technique in 88 patients. Number of reconstructed tube grafts per patient was compared between those with and without preoperative MD-CT for spinal cord feeding artery localization. Patency of reconstructed intercostal arteries was studied by postoperative MD-CT in 74 patients for 145 grafts according to the availability and findings of preoperative MD-CT.

Statistical analysis

Data were presented as mean ± standard deviation of the mean. An IBM SPSS Statistics 22 software (IBM Inc., Chicago, IL) was used for all statistical analyses. Pearson's $\chi 2$ test was used for comparison of nominal variables and t-test for continuous variables. A p-value less than 0.05 was considered significant.

Results

One patient (0.6%) died within 30-days after surgery due to rupture of a remote penetrating ulcer. Six other patients died during their hospital stay with a hospital mortality rate of 3.9% (7/178). Three of them had infected aneurysms, developed paraplegia, and the cause of death was infection. Ischemic spinal cord injury occurred in nine patients (5.1%) and all of them were immediate. Four of

them were paraplegia (2.2%), and all these four had infected aneurysms, including the three who died in the hospital. No surviving patient required new postoperative permanent hemodialysis.

Since the introduction of staged repair strategy in 2009, extent II repair has become rare (n=1/46), while completion of entire thoracoabdominal aortic replacement after previous descending thoracic aortic replacement has increased from 5/132 to 6/46 (p=0.025). Homologous transfusion was not required in 37% in the latter period. Results of the downstream operations after previous descending thoracic replacement was not different (no mortality, no spinal cord injury) from the de novo operation.

Patency of reconstructed intercostal arteries

Overall patency of separate graft reconstruction of intercostal arteries was 70%. Introduction of preoperative MD-CT for identification of the feeding artery resulted in reduced number of intercostal reconstruction and improved patency, so that the number of patent arteries per patient was not different (**Table 1**). Patency was 92% for the feeding arteries, which was better than that that in patients without preoperative information (**Table 2**).

Discussion

Since the introduction of collateral network concept by Griepp and colleagues[12], the main focus of spinal cord protection during aortic surgery has moved from identification and reconstruction of the spinal cord feeding arteries to maximizing collateral blood flow. Indeed, Acher and

colleagues[13] have already reported excellent results in their pioneering work in 1990's using rapid intercostal closure to avoid steal phenomenon, continuous naloxone infusion and CSFD. The lower incidence of spinal cord injury after thoracic endovascular aortic repair (TEVAR) may also support this concept, because no intercostal artery is reattached during TEVAR but pulsatile blood flow, which is proved important in maintaining collateral pressure[14], is maintained throughout the procedure both proximally and distally to the repair site.

Without intercostal reconstruction, however, delayed onset injury is a problem, which accounts for 85% of paraplegia in a series by Etz and colleagues[15] and is due to reduced flow reserve that lasts for 72 hours in their experimental model[16]. This is why maintenance of high blood pressure and CSFD for 72 hours after surgery are generally recommended. The most effective method to maintain flow reserve, however, is intercostal reconstruction. The present result with no delayed onset injury supports this concept. Risk of immediate injury due to extra time of aortic crossclamping for intercostal reconstruction should then be weighed against the risk of delayed onset injury. Our concept is to use the collateral network to avoid ischemia during intercostal reconstruction.

Presence of rich collateral network has already been reported back in 1980[17], but the efforts to maximize collateral blood flow by the use of distal aortic perfusion, CSFD and meticulous control of back-bleeding did not reduce the incidence of paralysis until recently. This may be explained by the anatomy of spinal cord blood supply. Svensson and colleagues[18] have reported that narrowing of

the anterior spinal artery just above its junction with the hairpin-shaped great radicular artery prevent the blood flow of lower thoracic spinal cord from being increased by distal aortic perfusion. This means that anatomy of spinal cord blood supply cannot be explained by the commonly used single water tank model in most cases in which a solitary hair-pin shaped spinal cord feeding artery is present, but may better be explained by the model of three tanks connected through a narrow canal (**Figure 2**). Collateral blood flow through the paraspinous network may frequently be insufficient despite CSFD and back-bleeding control because distal aortic perfusion is usually non-pulsatile and low-pressure. Therefore spinal cord injury may develop when aortic crossclamping is prolonged.

To overcome this, we Japanese surgeons have focused on the communication between neighboring intercostal arteries as an effective collateral source even through non-pulsatile low-pressure perfusion. We started using the multi-segmental sequential intercostal reconstruction to maintain blood flow to the neighboring intercostal arteries during reconstruction of a supposed feeding artery[10], which was based on the finding that no spinal cord injury occurred when two or less segments were clamped simultaneously[19]. In our previous study[10], introduction of this technique resulted in decreased incidence of intraoperatively detected spinal cord ischemia from 90% to 27% in 43 extent I or II repair. In addition, we[9] have also reported that, among the 30 patients in whom a feeding artery was involved in the extent of repair, neurological monitoring detected ischemia in 11 (37%), and blocking back-bleeding was effective in reversing ischemia in 8

of them, which means that collateral flow was not sufficient in only 10% (3/30) in this strategy.

In the multi-segmental sequential repair technique, intercostal reconstruction with the patch technique is difficult because of the proximity of the distal clamp, and separate tube grafts have preferably been used. In this technique, patency has always been a concern. In the present study, although overall patency was low, 92% of the grafts connecting to the feeding artery remained patent, and occlusion of the graft did not result in paralysis. Higher patency for the feeding artery may be explained by higher flow. Of course this result is biased because greater care was taken in reconstructing those connecting to the feeding artery. Nevertheless, it shows that carefully reconstructed grafts connecting to the spinal cord feeders remain patent in most cases, and occlusion of the unnecessary grafts does not lead to paralysis.

Conclusions

Our strategy for open thoracoabdominal aortic aneurysm repair has been successful in achieving reduced mortality and morbidity. The concept of spinal cord protection, which was based on selective intercostal reconstruction while maximizing spinal cord collateral blood flow, seems justified.

Conflict of interest: The authors have declared that no conflict of interest exists.

References

1. Coselli JS, LeMaire SA, Preventza O, de la Cruz KI, Cooley DA, Price MD et al. Outcomes of 3309 thoracoabdominal aortic aneurysm repairs. J Thorac Cardiovasc Surg 2016;151:1323-37.

2. Committee for Scientific Affairs JATS, Masuda M, Okumura M, Doki Y, Endo S, Hirata Y et al. Thoracic and cardiovascular surgery in Japan during 2014 : Annual report by The Japanese Association for Thoracic Surgery. Gen Thorac Cardiovasc Surg 2016;64:665-97.

3. Inoue Y, Minatoya K, Oda T, Seike Y, Tanaka H, Sasaki H. Novel surgical incision for treatment of extensive aortic aneurysm: a case of straight incision with rib-cross (SIRC) approach. Gen Thorac Cardiovasc Surg 2016;64:55-7.

4. Yoshioka K, Tanaka R, Kamada T, Abiko A. Three-dimensional demonstration of the collateral circulation to the artery of Adamkiewicz via the thoracodorsal artery with multi-slice computed tomography angiography. Eur J Cardiothorac Surg 2010;37:1234.

5. Shiiya N, Matsuzaki K, Kunihara T, Yasuda K. Use of a soft reservoir bag in a fully heparin-coated closed-loop cardiopulmonary bypass system for distal aortic perfusion during aortic surgery. J Artif Organs 2005;8:85-90.

6. Shiiya N, Matsuzaki K, Kunihara T, Sugiki H. Heparin reduction with the use of cardiotomy suction is associated with hyperfibrinolysis during distal aortic perfusion with a heparin-coated semi-closed cardiopulmonary bypass system. J Artif Organs 2006;9:214-9.

7. Shiiya N, Yasuda K, Matsui Y, Sakuma M, Sasaki S. Spinal cord protection during thoracoabdominal aortic aneurysm repair: results of selective reconstruction of the critical segmental arteries guided by evoked spinal cord potential monitoring. J Vasc Surg 1995;21:970-5.

8. Maruyama R, Kamishima T, Shiiya N, Asano T, Matsuzaki K, Miyasaka K et al. MDCT scan visualizes the Adamkiewicz artery. Ann Thorac Surg 2003;76:1308.

9. Shiiya N, Wakasa S, Matsui K, Sugiki T, Shingu Y, Yamakawa T et al. Anatomical pattern of feeding artery and mechanism of intraoperative spinal cord ischemia. Ann Thorac Surg 2009;88:768-71; discussion 72.

10. Shiiya N, Kunihara T, Matsuzaki K, Yasuda K. Evolving strategy and results of spinal cord protection in type I and II thoracoabdominal aortic aneurysm repair. Ann Thorac Cardiovasc Surg 2005;11:178-85.

11. Etz CD, Zoli S, Mueller CS, Bodian CA, Di Luozzo G, Lazala R et al. Staged repair significantly reduces paraplegia rate after extensive thoracoabdominal aortic aneurysm repair. J Thorac Cardiovasc Surg 2010;139:1464-72.

12. Griepp RB, Griepp EB. Spinal cord perfusion and protection during descending thoracic and thoracoabdominal aortic surgery: the collateral network concept. Ann Thorac Surg 2007;83:S865-9; discussion S90-2.

13. Acher CW, Wynn MM. Thoracoabdominal aortic aneurysm. How we do it. Cardiovasc Surg

1999;7:593-6.

14. Etz CD, Di Luozzo G, Zoli S, Lazala R, Plestis KA, Bodian CA et al. Direct spinal cord perfusion pressure monitoring in extensive distal aortic aneurysm repair. Ann Thorac Surg 2009;87:1764-73; discussion 73-4.

15. Etz CD, Luehr M, Kari FA, Bodian CA, Smego D, Plestis KA et al. Paraplegia after extensive thoracic and thoracoabdominal aortic aneurysm repair: does critical spinal cord ischemia occur postoperatively? J Thorac Cardiovasc Surg 2008;135:324-30.

16. Etz CD, Homann TM, Luehr M, Kari FA, Weisz DJ, Kleinman G et al. Spinal cord blood flow and ischemic injury after experimental sacrifice of thoracic and abdominal segmental arteries. Eur J Cardiothorac Surg 2008;33:1030-8.

17. Dommisse GF. The arteries, arterioles, and capillaries of the spinal cord. Surgical guidelines in the prevention of postoperative paraplegia. Ann R Coll Surg Engl 1980;62:369-76.

18. Svensson LG, Rickards E, Coull A, Rogers G, Fimmel CJ, Hinder RA. Relationship of spinal cord blood flow to vascular anatomy during thoracic aortic cross-clamping and shunting. J Thorac Cardiovasc Surg 1986;91:71-8.

19. Shiiya N, Matsui Y, Murashita T, Sasaki S, Sakuma M, Yasuda K. Effects of multiple small segmental resection and hypothermia with regard to causes of spinal cord injury and selection of reconstruction methods in thoracoabdominal aortic aneurysms. Jpn J Vasc Surg 1997;6:531-36;

article in Japanese.

Table 1

Number and patency of separate tube graft reconstruction of the intercostal arteries according to the availability of preoperative spinal cord feeding artery localization

MD-CT for feeding artery localization	Not available	Available	P-value
Number of aortic segments repaired	9.3±3.6	9.6±2.7	0.681
Number of reconstructed grafts	2.4±1.2	1.6±0.7	0.001
Number of patent grafts	1.6±1.1	1.2±0.8	0.127
Patency	61% (42/69)	78% (59/76)	0.028

MD-CT: Multi-detector row computed tomography

Table 2

Patency of separate tube graft reconstruction of the intercostal arteries according to the availability and findings of preoperative spinal cord feeding artery localization

MD-CT finding	Patency
Arteries feeding the spinal cord	92% (23/25)
Arteries unrelated to spinal cord blood supply	69% (24/35)
Feeding artery not identified	75% (12/16)
MD-CT not available	61% (42/69)

p=0.034

MD-CT: Multi-detector row computed tomography

Figure legends

Figure 1 3D computed tomography showing the patency of a 12-mm graft for intercostal reconstruction.

Note that the diameter to length ratio of the graft is nearly one, so that vortical flow within the graft is maintained and reaches the orifice of intercostal artery.

Figure 2 A proposed model of spinal cord blood supply.

A model of three tanks connected through a narrow canal can explain why distal aortic perfusion is frequently insufficient despite high blood pressure and cerebrospinal fluid drainage.

Figure 1

Figure 2

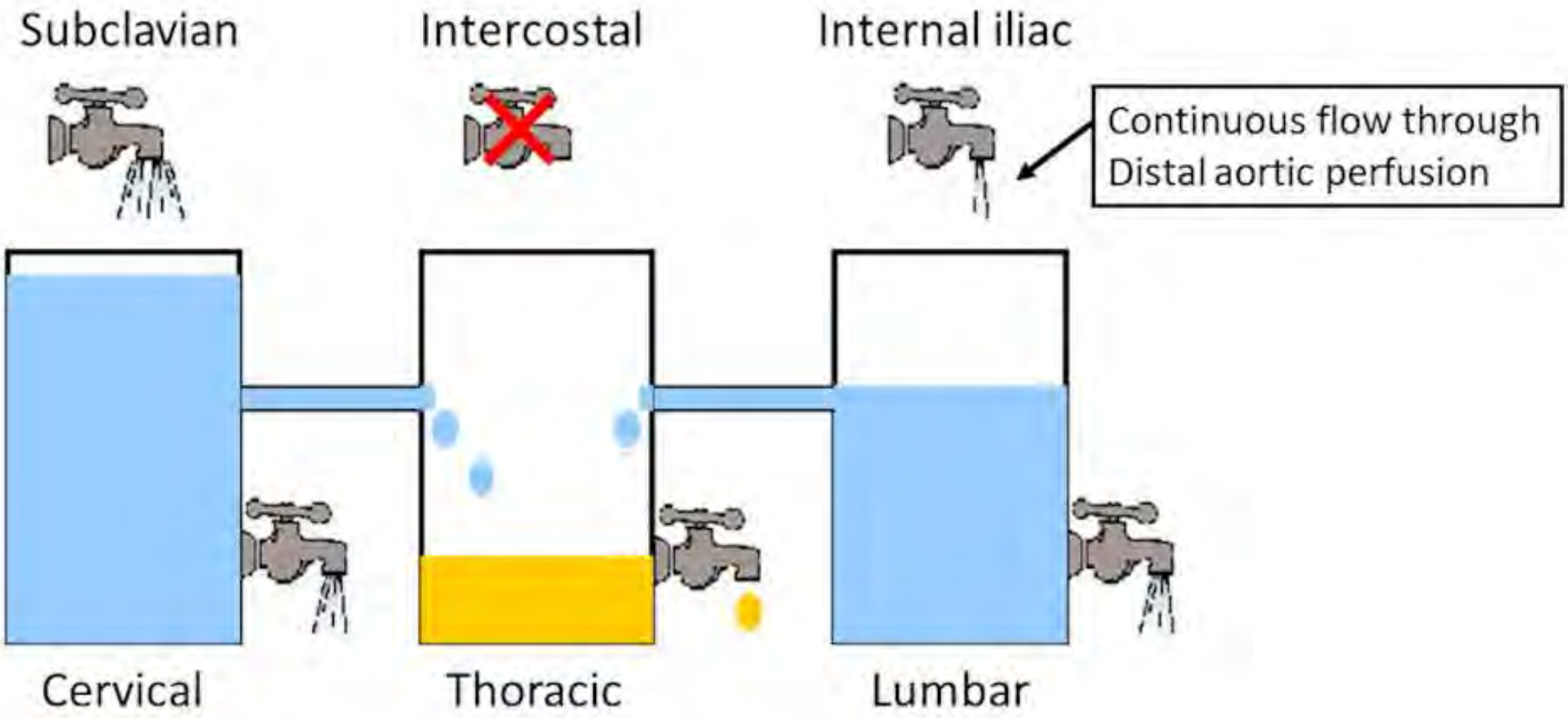
Subclavian
Intercostal
Internal iliac
Continuous flow through
Distal aortic perfusion
Cervical
Thoracic
Lumbar