Title:

Modified "Dredging Method" for complicated solid/multicystic ameloblastoma in the mandible: Report of a case treated by fractionated enucleation

Author names and affiliations:

Yoichi Ohiro[a]*, Tamaki Yamada[a], Wataru Kakuguchi [a], Ichizo Kobayashi[b], Tetsuya Kitamura[c] and Kanchu Tei[a]

[a] Department of Oral and Maxillofacial Surgery, [c] Department of Oral Pathology and Biology, Faculty of Dental Medicine and Graduate School of Dental Medicine, Hokkaido University

Kita13 Nishi7, Kita-ku, Sapporo 060-8586, Japan

[b] Department of Oral Surgery, JR Sapporo Hospital

Kita3 Higashi1, Chuou-ku, Sapporo, 060-0033, Japan

*Corresponding author:

Tel.: +81 11 706 4283; Fax: +81 11 706 4283.

E-mail address: yohiro@den.hokudai.ac.jp (Y. Ohiro)

Abstract

The purpose of this paper is to describe the treatment procedures for a solid/multicystic ameloblastoma which was treated with the “Dredging Method” modified by fractionated enucleation adopted to avoid the pathologic fracture because of the complicated expansive nature in the mandible. Ameloblastoma is defined as a benign epithelial odontogenic tumor with progressive growth potential. Currently employed surgical treatment as curative treatment is resection with adequate margins because of the characteristics of high recurrence rates with conservative treatment. In this article, a 38-year-old male with swelling on the right mandible was referred to our hospital. Image analysis showed an expansile partially honeycombed multilocular radiolucent lesion from the body to the ascending ramus of the mandible. A follicular ameloblastoma was diagnosed by the biopsy. The paper also details the management of the ameloblastoma with the “Dredging Method” to remove the tumor completely and maintain the form and function of the mandible and the 13-year follow-up post treatment.

Keywords

ameloblastoma, Dredging method, conservative treatment, pathologic fracture

1. Introduction

The prognosis of ameloblastoma depends on the kind of treatment and conservative treatments result in a high recurrence rates [1-3]. Current recommended surgery is resection with adequate margins [4-9], however the treatment of a characteristic slow and painlessly growing ameloblastoma involves extensive loss of the mandible. The loss of jaw bone support induces many adverse effects with loss of oral function and deformities even after reconstruction. To improve on these complications and further to remove the tumor completely, the “Dredging

Method" was established as an alternative conservative treatment in 1973 [10]. We report a case of a partially honeycombed multilocular ameloblastoma. Following the standard "Dredging Method", pathologic fracture was anticipated during the operation, but here the authors successfully treated the patient with the "Dredging Method" modified by fractionated enucleation.

2. Case Report

A 38-year-old male patient was referred to the Department of Oral and maxillofacial Surgery, Hokkaido University in January 2003. The chief complaint of the patient was swelling in the right mandibular body. Hypoesthesia of the mental nerve was not determined. Intraoral palpation showed a swelling with poorly defined boundaries from the right first premolar to the ascending ramus. On the body of the mandible, the obvious fluctuation was palpated. A panoramic radiograph and computed tomography (CT) image showed a large multilocular radiolucent lesion with well circumscribed borders in the body of the mandible and a slightly obscure honeycombed lesion at an angle to the ascending ramus of the mandible (Fig. 1A and 1B). The wisdom tooth was involved in the lesion. The clinical diagnosis was a benign tumor of the mandible. A biopsy and deflation was performed simultaneously under local anesthesia. A follicular ameloblastoma was diagnosed from the biopsy specimens (Fig. 1C and 1D).

Hemimandibulectomy and reconstruction with a fibular flap was determined to need to be performed as a radical treatment. The patient did not accept this treatment plan, because of the decline of the oral function and facial deformity due to the loss of occlusion and continuity of the jaw even after the reconstruction. As an alternative treatment, the "Dredging Method" was accepted by the patient (Fig. 2). Following the original method, pathologic fracture was considered to easily occur because of the thinning of the remaining bone of the mandible if all of the tumor was enucleated in one operation. We then considered employing fractionated

enucleation with a modified “Dredging Method” and in this revised treatment plan, the tumor would be removed with fractionation by 3 times of enucleation to avoid any pathologic fracture (Fig. 3A). Two months after the deflation, the tumor in the ascending ramus was completely removed with a part of the surrounding bone (Fig. 3A,a and 3B). The inferior alveolar neurovascular bundle was sacrificed because of its involvement in the solid tumor. The periosteum around the lesion was treated in a manner to ensure that it would be preserved. The wound was deflated expecting the decompression of the lesion and the surrounding bone. The patient was instructed to eat only soft food, such as steamed rice or noodles to avoid any need for excess biting forces until the completion of all of the surgical treatments. Enucleation of the tumor in the angle of the mandible was performed 3 months after the first operation (Fig 3A,b). Scar tissue covering the bony cavity in the ascending ramus and adjacent newly formed bone were also removed to be able to identify the presence of remaining tumor parts in the histopathological examination. To remove the tumor completely, impacted wisdom tooth and second molar were extracted. The wound was maintained as deflated. Three months after the second operation, enucleation of the tumor in the body of the mandible was performed (Fig 3A,c). Scar tissue covering the bony cavity in the ascending ramus and the angle with the adjacent bone was again removed. First molar was removed and apicoectomy was performed for the premolars to ensure complete removal of the tumor. The patient received a further 4 dredging treatments at three month intervals (Fig 4). In each operation, the removed scar tissue and adjacent newly formed bone were used to establish the presence of remaining tumor cells in the histopathological examination. In the last three dredging treatments, no tumor cells were found in the specimens. The bony cavity was finally filled by newly formed bone. A panoramic radiograph and CT showed the restoration of the jaw form and no signs of recurrence of the tumor (Fig. 5). During the treatment, no surgical fractures were found and the patient has undergone regular checkups for 13 years after the last treatment.

3. Discussion

Ameloblastoma is one of the most common types of odontogenic tumors with a wide variety of clinical features, and histological patterns. Ameloblastoma is slowly growing histologically benign tumors, mostly affecting the mandible in a wide age range of patients [1-3]. Although it is a benign tumor, inadequate treatment results in high recurrence rates because of the characteristics of the local invasion [1,3]. To ensure the prognosis, radical surgery which includes the excision with adequate margins rather than conservative enucleation or curettage is recommended [4-9]. Resection of the mandible, including the condyle causes a number of complications such as dysfunction, deformities, and psychological distress, even if reconstruction surgery is performed.

To avoid these complications, our department has established the "Dredging Method" in 1973 to treat odontogenic tumors of the mandible (Fig. 2) [10]. "Dredging Methods" include surgical procedures with enucleation after deflation or only enucleation followed by repeated dredging treatments. Deflation is applied to large cystic ameloblastoma to ensure the formation of a bony outline. Enucleation is performed after the formation of a bony outline in cystic or solid ameloblastoma. Dredging is performed at 2 to 3 month intervals to accelerate the new bone formation by removing the scar tissue which has grown to cover the bony cavity. During the dredging, some part of new bone is also removed with the scar tissue to determine the presence of remaining tumor cells histopathologically. All of the above procedures are completed in the deflated wound with irrigation by the patients to maintain the wound as clean. Eventually the bony cavity is assumed to become filled with newly formed bone. Continuous regular follow-up is also important to be able to detect recurrences early. In the "Dredging Method", these procedures ensure the elimination of the ameloblastoma and maintenance of the form and function of the mandible.

In this article, a modified “Dredging Method” was applied to a complicated solid/multicystic type of ameloblastoma and the treatment and follow-up is detailed. In the original “Dredging Method”, the tumor is to be removed with the surrounding healthy bone after deflation in cystic lesions or enucleation in solid lesions. If we applied this original method in the present case, fractures could be expected to easily occur after the enucleation of the whole of the lesion especially in the ascending ramus containing a honeycombed lesion. Pathologic fractures related to treatment of benign lesions of the jaw have been reported [11,12]. To avoid such fractures we developed the modified “Dredging Method” reported here which includes the fractionated enucleation of large ameloblastoma (Fig 3A). In this procedure, no fracture or recurrence of a tumor were observed in 13 years of follow-up. It is well known that the recurrence of ameloblastoma may occur more than 25 years after treatment, and this makes it desirable to apply the “Dredging Method” with patients who are strongly motivated for a long term follow-up. The reported modified “Dredging Method” to remove the tumor completely and maintain the form and function of the mandible was applied safely and effectively for an extensive and complicated ameloblastoma without pathologic fracture.

Ethical approval

A written informed consent was given and signed by the parent.

Conflict of interest

Authors have no conflict of interest to declare.

References

[1] Gardner DG. Some current concepts on the pathology of ameloblastomas. Oral Surg Oral Med Oral Pathol Oral Radiol Endod 1996;82:660-9.

[2] Vered M, Muller S, Heikinheimo K, Odell EW, Tilakaratne WM. Ameloblastoma. In: El-Naggar AK, Chan JKC, Grandis JR, Takata T, Slootweg PJ, editors. WHO Classification of Head and Neck Tumours (4th edition). Lyon: IARC Press; 2017. p215-8

[3] Reichart PA, Philipsen HP, Sonner S. Ameloblastoma: biological profile of 3677 cases. Eur J Cancer B Oral Oncol 1995;31B:86-99.

[4] Pogrel MA, Montes DM. Is there a role for enucleation in the management of ameloblastoma? Int J Oral Maxillofac Surg 2009;38:807-12.

[5] Antonoglou GN, Sándor GK. Recurrence rates of intraosseous ameloblastomas of the jaws: a systematic review of conservative versus aggressive treatment approaches and meta-analysis of non-randomized studies. J Craniomaxillofac Surg 2015;43:149-57.

[6] Lau SL, Samman N. Recurrence related to treatment modalities of unicystic ameloblastoma: a systematic review. Int J Oral Maxillofac Surg 2006;35:681-90.

[7] Laborde A, Nicot R, Wojcik T, Ferri J, Raoul G. Ameloblastoma of the jaws:Management and recurrence rate. Eur Ann Otorhinolaryngol Head Neck Dis 2017;134:7-11.

[8] Haq J, Siddiqui S, McGurk M. Argument for the conservative management of mandibular ameloblastomas. Br J Oral Maxillofac Surg 2016;54:1001-1005.

[9] Almeida Rde A, Andrade ES, Barbalho JC, Vajgel A, Vasconcelos BC. Recurrence rate following treatment for primary multicystic ameloblastoma: systematic review and meta-analysis. Int J Oral Maxillofac Surg 2016;45:359-67.

[10] Kawamura M, Inoue N, Kobayashi I, Ahmed M. “Dredging Method”-A New Approach for the Treatment of Ameloblastoma. Asian J Oral Maxillofac Surg 1991;3:81-8

[11] Salmassy DA, Pogrel MA. Liquid nitrogen cryosurgery and immediate bone grafting in

the management of aggressive primary jaw lesions. J Oral Maxillofac Surg 1995;53:784-90.

[12] Carneiro JT Jr, Carreira AS, Félix VB, da Silva Tabosa AK. Pathologic fracture of jaw in unicystic ameloblastoma treated with marsupialization. J Craniofac Surg 2012;23:e537-9.

Figure legends

Fig. 1. Multilocular radiolucent lesion in right mandibular body and honeycombed lesion in the ramus was identified in the panoramic radiograph (A) and in the computed tomography (CT) images (B). The pathological findings showed that the large cyst was lined by ameloblastic epithelium from a cystic lesion in the mandibular body (C) and the tumor showed a mainly follicular pattern from the mandibular ramus (D), original magnification X 50.

Fig. 2. Outline of the concept of the treatment of the "Dredging Method" (quoted from [10] with modifications).

(A) Treatment protocol for a mainly cystic ameloblastoma. Deflation and enucleation is followed by dredging. For a multicystic ameloblastoma, removal of the intercystic septum is applied in the deflation procedure. (B) Enucleation is followed by dredging for solid ameloblastoma. (C) For ameloblastoma including honeycombed portions, procedure (A) or (B) is applied for the cystic or solid portion, while marginal resection is performed for the honeycombed portion.

Fig. 3. (A) The strategy of the operation to avoid the pathologic fractures during (a) 1st enucleation of the mandibular ramus, (b) 2nd enucleation of the mandibular angle, (c) 3rd enucleation of the mandibular body, (d) 3 times dredging across all of the area inside the dotted line. (B) Intraoperative view 2 months after the deflation. The tumor in the ramus and surrounding bone were fully removed.

Fig. 4. A panoramic radiograph at (A) 3 months after the 3rd enucleation and (B) at 3 months after the last dredging.

Fig. 5. (A and B) CT images 11 years after the last dredging and (C) panoramic radiograph 13 years after the last dredging show restoration of the mandibular shape and bone formation.

Fig. 1

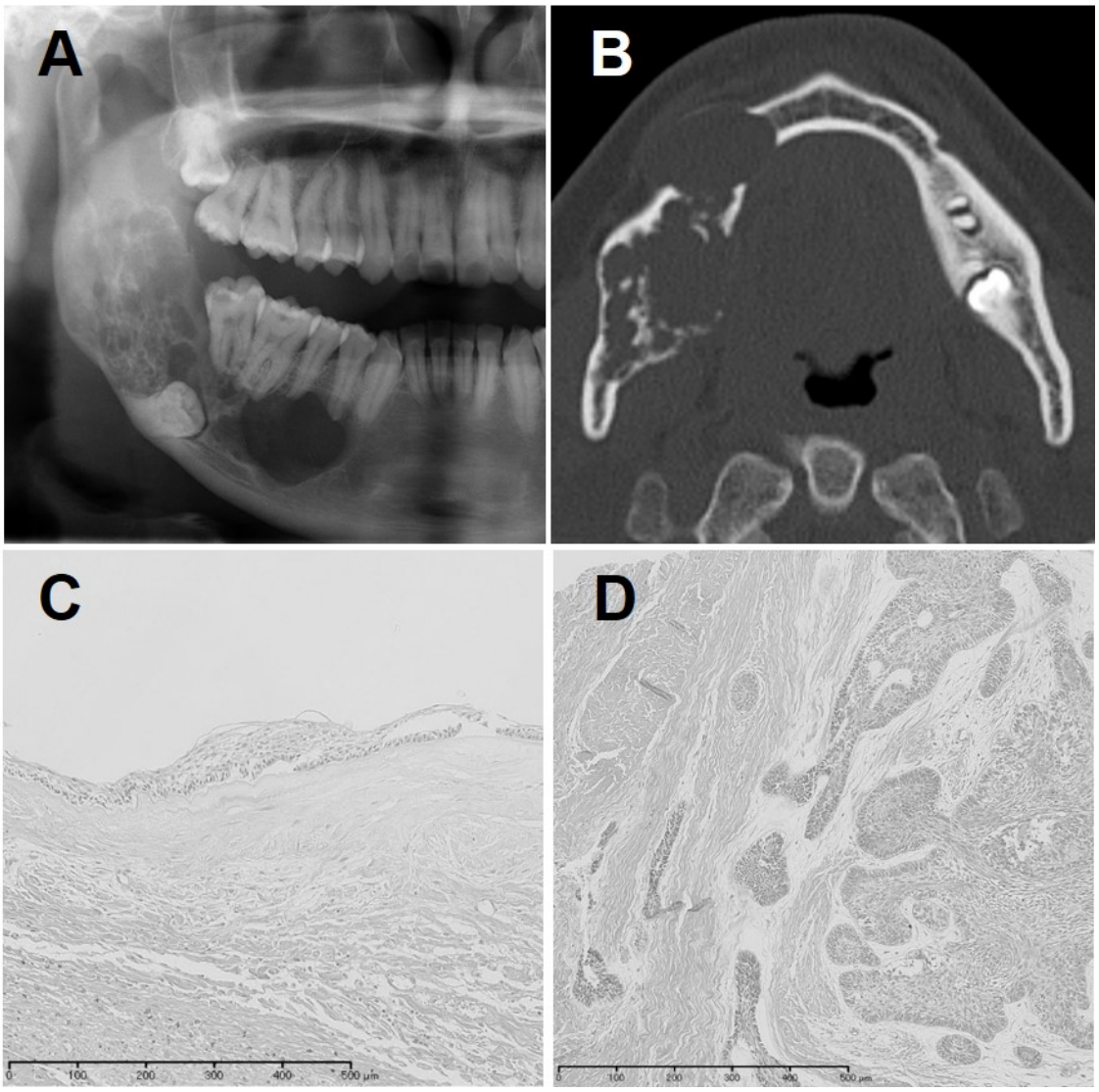

Fig. 2

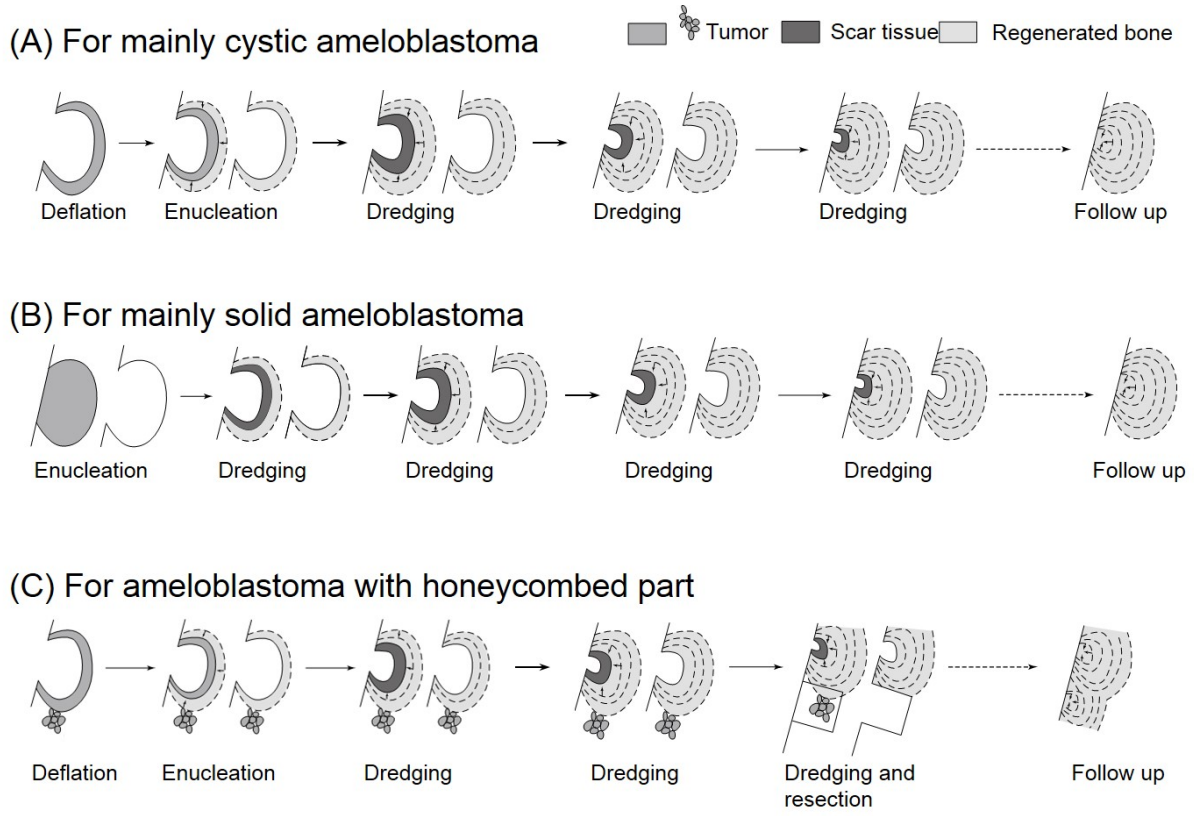
(A) For mainly cystic ameloblastoma
Tumor
Scar tissue
Regenerated bone
Deflation
Enucleation
Dredging
Dredging
Dredging
Follow up
(B) For mainly solid ameloblastoma
Enucleation
Dredging
Dredging
Dredging
Dredging
Follow up
(C) For ameloblastoma with honeycombed part
Deflation
Enucleation
Dredging
Dredging
Dredging and resection
Follow up

Fig. 3

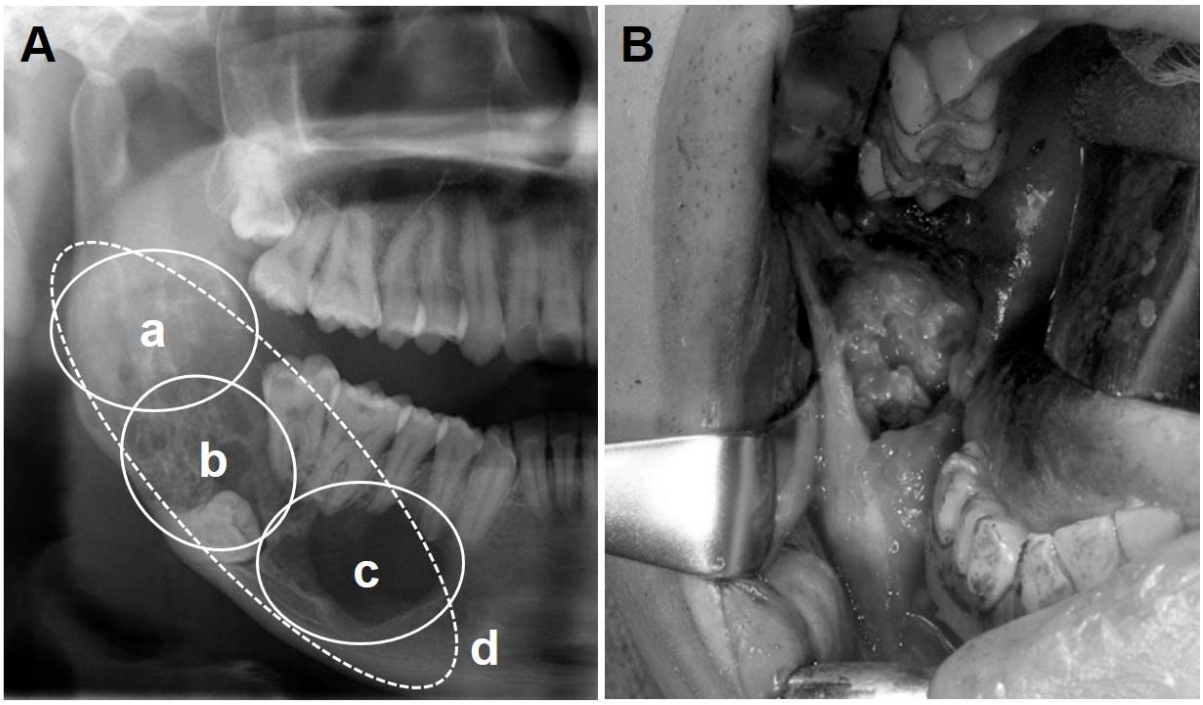

Fig. 4

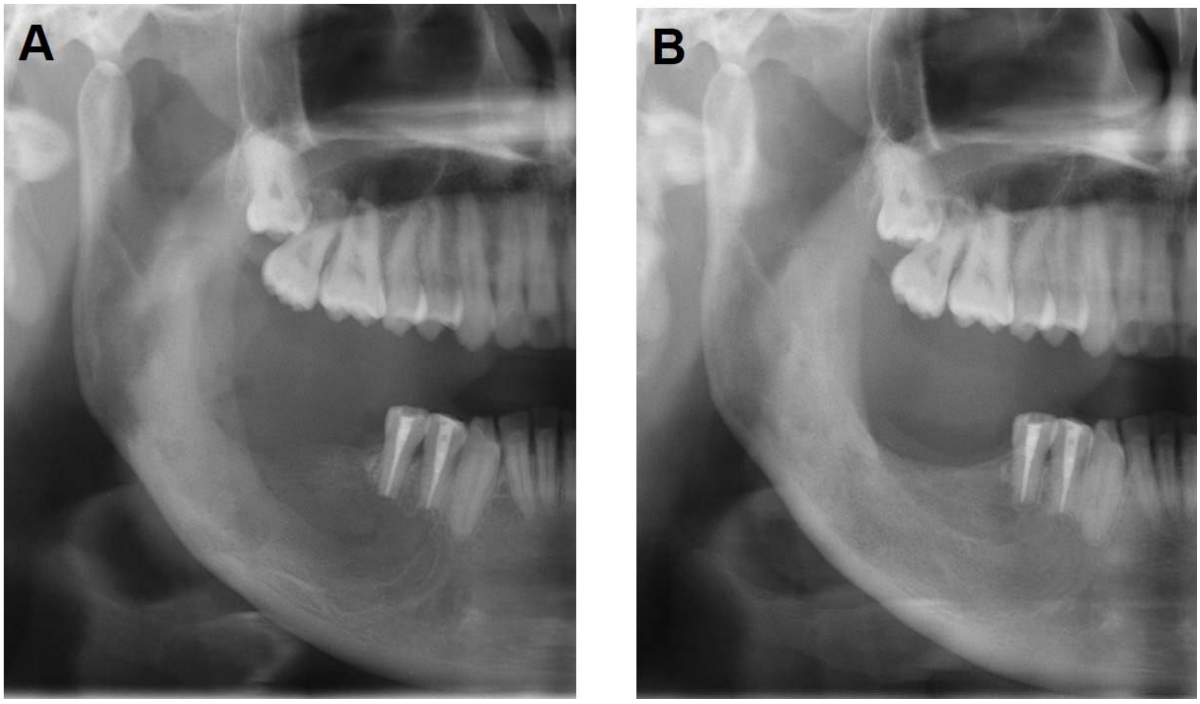

Fig. 5