Short- and long-term outcomes of a novel transpapillary dilation technique using a diathermic catheter for severe benign bile duct stricture: a retrospective cohort study

Shin Kato[1], Masaki Kuwatani[1], Kazumichi Kawakubo[1], Ryo Sugiura[1], Koji Hirata[1], Masahito Nakajima[1], Hajime Hirata[1], Hiroshi Kawakami[2], and Naoya Sakamoto[1]

[1] Department of Gastroenterology and Hepatology, Hokkaido University, Graduate School of Medicine, Sapporo, Japan

[2] Department of Gastroenterology, Miyazaki University, School of Medicine, Miyazaki, Japan

Corresponding author: Masaki Kuwatani.

Department of Gastroenterology and Hepatology, Hokkaido University, Graduate School of Medicine, Sapporo, Japan

Kita15 Nishi7, Kita-ku, Sapporo, Japan, 060-8638

Phone: +81-11-716-1161

e-mail: mkuwatan@med.hokudai.ac.jp

Conflict of Interest statement: No potential conflict of interest relevant to this article was reported.

Abstract

Background and study aim

Endoscopic dilation for severe benign biliary stricture using mechanical dilation devices is occasionally ineffective. Hence, diathermic dilation has recently been gaining attention as a salvage technique for severe benign biliary stricture. We evaluated the short- and long-term outcomes of diathermic dilation for severe benign biliary stricture that could not be dilated using the conventional mechanical dilation procedures.

Methods

This retrospective cohort study enrolled 13 consecutive cases with severe benign biliary stricture that underwent diathermic dilation using 6-Fr diathermic catheter as a salvage procedure. Short-term outcomes (such as the success rate of diathermic dilation and stent placement and occurrence of adverse events) and long-term outcomes (such as the recurrence of bile duct stricture and achievement of stent-free state) were analyzed.

Results

Diathermic dilation was successful in 13 cases (100%), whereas stent was successfully placed in 12 cases (92.3%) following diathermy. Adverse events occurred in 2 cases (15.4%): a mild haemobilia and a mild cholangitis. The recurrence of bile duct stricture was observed in 5 cases (41.7%) in the 1115-day median follow-up period (range: 406–

2547). Finally, 8 cases achieved stent-free state (61.5%) and have remained stent-free without any episode of cholangitis and abnormal liver function test.

Conclusion

Diathermic dilation using 6-Fr diathermic catheter is a promising salvage procedure for severe benign biliary stricture. The potential effect and safety of diathermic dilation as the first-line procedure for benign biliary stricture should be evaluated in a randomized controlled trial.

Introduction

Benign biliary stricture (BBS) could occur due to inflammation following surgery including living donor liver transplantation (LDLT) and hepatectomy, as well as due to intrahepatic bile duct stone, IgG4-related cholangitis, and primary sclerosing cholangitis [1]. BBS could occasionally lead to acute cholangitis; therefore, proper stricture dilation and drainage are essential.

In cases that necessitate drainage for stricture, endoscopic transpapillary biliary drainage is a primary option, because a long-term follow-up study has revealed that endoscopic retrograde dilation and drainage are safe, effective, less invasive and repeatable in comparison with other approaches such as surgery and percutaneous intervention [2]. Because passing the delivery system of the stent through the stricture could be difficult, stricture dilation is occasionally required before placing the stent for drainage. Standard endoscopic techniques for biliary stricture include the use of a balloon or a bougie catheter [1]. However, these conventional dilation techniques are occasionally ineffective for severe stricture.

Recently, a dilation technique using a diathermic catheter for severe BBS is gaining attention. Although it appears to be a promising salvage procedure, limited researches have investigated this topic and research regarding to the long-term outcomes following

diathermic dilation is lacking.

In the present study, we investigated the short-term outcomes of diathermic dilation for BBS as well as the long-term outcomes such as the recurrence of bile duct stricture during the long observational period and the achievement of stent-free state following diathermic dilation.

Method

<Study design>

This single-center, retrospective cohort study evaluated the short- and long-term outcomes of transpapillary diathermic dilation for severe BBS that were not successfully dilated using the conventional dilation method. Data on consecutive patients with BBS who underwent transpapillary dilation of the biliary stricture at the Hokkaido University Hospital was retrospectively collected from our prospectively collected database and the hospital medical records. Written informed consent was obtained from all patients before procedure. The present study was conducted according to the Helsinki Declaration and was approved by the institutional review board of the Hokkaido University Hospital (No. 016-0280).

<Cases and study setting>

The cases with BBS, enrolled between January 2012 and December 2017 at Hokkaido

University Hospital, who required diathermic dilation but in whom performing conventional dilation technique using tapered catheter, biliary dilation catheter (BDC), dilation balloon, and screw drill was difficult were included in the present study. The exclusion criteria for this study were as follows: 1) patients with surgically altered anatomy (Roux-en-Y, Billroth-II or status post pancreaticoduodenectomy), 2) patients with bleeding diathesis, 3) patients who were lost within 365 days during the follow-up period, and 4) patients with biliary stricture due to malignancy.

<Endoscopic procedure>

Following fluoroscopic confirmation of the existence of bile duct stricture, we attempted to pass the standard ERCP catheter (MTW ERCP catheter; MTW Endoskopie Manufaktur, Wesel, Germany) through the stricture. Strictures wherein the passage of a standard catheter was found to be difficult were considered as severe strictures, and conventional dilation techniques were performed in the following manner. First, a tapered ERCP catheter (PR110Q; Olympus, Tokyo, Japan) was inserted for dilation. For cases wherein passing the tapered catheter were unsuccessful, we attempted to dilate the stricture using a 4-Fr (1.3 mm)–6-Fr (2.0 mm) BDC (Soephendra biliary dilatation catheter; Cook Japan, Tokyo, Japan). Further, for cases wherein dilation using BDC was difficult, a 7-Fr (2.3 mm) Soephendra stent retriever (SSR) (Cook Japan, Tokyo, Japan)

as a screw drill or balloon catheter (Hurricane ™RX, Boston Scientific Japan, Tokyo, Japan) was used for performing the dilation. For cases wherein dilation using all of the above-mentioned conventional procedures was unsuccessful, a diathermic catheter was used for performing the dilation.

A wire-guided 6-Fr diathermic catheter (Cyst Gastro-set; Endo-Flex Gmbh, Voerde, Germany) (Fig. 1) was used for diathermic dilation. Diathermic catheter was inserted under fluoroscopic guidance. After reaching the stricture, diathermy was performed using electrosurgical generator (ESG-100; Olympus Medical Systems, Tokyo, Japan). The power of generator was set at 30-W, pulse cut slow-mode that is similar to the setting of endoscopic sphincterotomy. One to several diathermic pulsations were applied until the diathermic catheter passed through the stricture. After obtaining the dilation using diathermy, plastic stent (PS), removable metal stent (MS), or endoscopic nasobiliary drainage tube (ENBD) was placed.

<Evaluation of the outcomes>

We evaluated the characteristics of patients and procedure, success rate of diathermic dilation (passage of diathermic catheter via stricture) and of stent placement following diathermy, occurrence of adverse events, recurrence of bile duct stricture, and achievement of stent-free state. All procedures were performed in hospital admission at

least 2 days after the procedure to monitor the occurrence of an early adverse event. Laboratory data, including complete blood count, liver function test (LFT), and C-reactive protein, were obtained 16–24 h after the procedure. Adverse events and severity were defined based on the lexicon by the American Society of Gastrointestinal Endoscopy (ASGE) [3]. Cases with successful diathermic dilation and stent placement were included in the long-term analysis. All cases were followed-up in the outpatient department for up to 72 months. Laboratory data were observed every 1–4 months at the outpatient department. The recurrence of stricture was defined as the stricture that required re-dilation procedure in the process of stent exchange or necessitated re-stenting because of abnormal LFT, elevated total bilirubin, and cholangitis.

Results

Between January 2012 and December 2017, 2286 cases of therapeutic ERCPs were performed at our institution. During this period, 156 cases required endoscopic transpapillary biliary drainage for BBS. Among these, 25 cases underwent transpapillary dilation for the biliary stricture. After passing the guidewire through the stricture, conventional dilation techniques were successful in 12 cases; 13 cases in which the procedure was unsuccessful underwent diathermic dilation. Table 1 presents the patient

characteristics. Median patient age was 63 years (range: 39–82). Most common etiology of stricture was postoperative biliary stricture (9/13, 69.2%). Strictures were located in the hilar to intrahepatic bile duct in 11 cases, and in the distal bile duct in 2 cases. Median stricture length was 7 mm (range: 3–19). Table 2 describes the procedure characteristics. Before diathermic dilation, all cases showed dilation using BDC, whereas 2 cases each showed additional dilation using balloon and SSR. Median total duration of diathermy was 4 s (range: 2–15), and each pulsation of diathermy lasted for 2.7 s.

Diathermic dilation of the stricture was successful in all 13 cases (100%), whereas stent placement following diathermic dilation was successful in 12 cases (92.3%). A 7-Fr PS was placed in 6 cases and a removable fully covered MS was placed in 1 case, whereas ENBD was placed in 5 cases because of cholangitis (4 cases) or hemobilia (1 case). All ENBDs were replaced to PS after the symptoms improved. The one unsuccessful case showed severe B2 ischemic stricture status post-LDLT. Although diathermic catheter passed through the stricture on applying pulsations twice (overall 4 s), stent delivery failed to pass through the stricture. Despite adding one-time diathermy, stent placement could not be achieved.

Adverse events occurred in 2 cases (15.4%). One patient with B3 stricture due to LDLT showed bleeding and hemobilia after pulsations were applied twice (overall 4 s).

Hemostasis was spontaneously achieved, and no intervention was necessary. The other patient with B5 stricture due to hepatectomy developed cholangitis after pulsation was applied once (5 s) and improved on administration of conservative therapy using antibiotics. In both cases, the severity was classified as mild depending on the lexicon of ASGE[3].

All 12 cases with successful stent placement following diathermic dilation were enrolled in the long-term follow-up. Median follow-up period was 1115 days (range: 406–2547). The recurrence of stricture was observed in 5 cases (41.7%). Figure 2 shows the patency rate in the follow-up period. The time to re-stricture ranged between 33 and 964 days. Finally, 8 cases achieved a stent-free state (61.5%) and were followed-up for 437 to 2175 days (median 1141.5 days) after achieving stent-free state without any episode of cholangitis and abnormal LFTs. Figure 3 reveals one of the cases that achieved stent-free state following diathermic dilation and stent placement. In this case of a 47-year-old man with severe benign stricture on the right hepatic duct following cholecystectomy (Fig. 3A), we attempted to place a double 7-Fr PS for dilation; however, the second stent failed to pass through the stricture. Diathermic dilation (pulsation applied once for 3 s) was applied (Fig. 3B) and placement of the second stent was performed smoothly (Fig. 3C). The follow-up cholangiography performed after 1 year revealed that the stricture was

improved, and a stent-free state was achieved (Fig. 3D). This patient is presently fine and has shown no event for 1948 days after the stent removal.

Discussion

In the present study, we found that diathermic dilation using a 6-Fr diathermic catheter was efficacious and a safe procedure for cases of severe BBS wherein every conventional dilation method was ineffective.

The effect of conventional dilation using BDC for biliary stricture has been established and confirmed [4,5]. Although dilation using BDC is safe, the method is sometimes ineffective for cases with severe strictures because of the thick tip of the catheter head. Several studies have mentioned the use of balloon and screw drill for severe BBS [6-10]. Inoue et al. have reported excellent therapeutic success rate (96%) of biliary stricture dilation using SSR [10], and Cantwell et al. have demonstrated satisfactory percutaneous dilation success rate (100%) for BBS using dilation balloon [7]. However, these results depended on the initial stricture condition that rarely includes severe strictures, which necessitates second-line or salvage dilation procedure. Passage through severe stricture was occasionally unsuccessful using these devices.

Recently, diathermic dilation for BBS has been mentioned in a few reports [11-13]. We

and another researcher [13] have described satisfactory technical success and safety of diathermic dilation. Our study demonstrated that the success rate of diathermic dilation was 100% (13/13) and stent placement following dilation was successful in 12 cases (92.3%); this satisfactory short-term outcome is consistent with the previous studies.

Furthermore, the present study includes the analysis of long-term outcomes following diathermic dilation for BBS, which is yet to be reported. The recurrence of stricture was observed in 5 cases (41.7%) during the follow-up period from 406 to 2547 days, whereas 8 cases (61.5%) achieved a long-term stent-free state. According to our results, diathermic dilation for severe BBS is considered an effective salvage procedure from the perspective of short- as well as long-term outcomes. The satisfactory outcomes following diathermic dilation depend on the burning effect on the bile duct wall. Kawakami et al. have reported that the burning effect caused by diathermy was efficacious for hyperplastic tissues surrounding the MS [14]. Permanent tissue degeneration using diathermy could lead to better achievement of stricture dilation and long-term patency in comparison to mechanical dilation technique, although the burning effect could induce the risk of vessel injury proximal to the diathermic lesion as well as of hemobilia [15].

Adverse events occurred in 2 cases (15.4%): mild cholangitis and mild hemobilia. Hemobilia is considered to be a sensitive adverse event associated with diathermic

dilation and has rarely been observed in conventional dilation method. This is because the effect of long-duration diathermy could affect and penetrate the focal bile duct wall as well as the tissues surrounding the bile duct wall. Particularly, diathermy for intrahepatic bile duct could lead to vessel injury and liver parenchyma via the burning effect [15]. Therefore, prolonged pulsations and multiple diathermic dilations for strictures should be avoided to prevent severe damage to the bile duct wall. Although the incidence of adverse events in our research was similar to another report [13] and appears to be safe, the evaluation for accumulated cases is mandatory to confirm the safety of this procedure.

The present study has several limitations. First, this is a retrospective, single-center, observational research involving limited number of cases. Currently, diathermic dilation is accepted as only a salvage procedure because of the lack of information regarding the risk of adverse events associated with the burning effect. However, prospective observational studies enrolling a greater number of cases should be performed. Second, although our research demonstrated the efficacy of diathermic dilation as a salvage procedure, it does not mention potential effect and safety of this technique as an initial dilation technique or as the second-line procedure for BBS. Diathermic dilation could be a promising first-line dilation technique if the safety of this procedure is confirmed in the

randomized controlled setting and supported by the results of experimental models. Third, we evaluated the outcomes only in the cases with BBS, without including cases with malignant biliary stricture. We also have reported the outcome of diathermic biliary dilation for 16 cases that included 13 cases with malignant biliary stricture and have demonstrated satisfactory outcomes [12]. The evaluation of the long-term outcomes following diathermic dilation for malignant biliary stricture should be analyzed in a larger accumulated case series.

In conclusion, this research presented that diathermic dilation using 6-Fr diathermic catheter is a promising salvage procedure for cases with severe BBS wherein the conventional dilation technique has been ineffective.

References

1. Deviere J. Benign Biliary Strictures and Leaks. Gastrointestinal endoscopy clinics of North America 2015; 25: 713-723
2. Kuroda Y, Tsuyuguchi T, Sakai Y et al. Long-term follow-up evaluation for more than 10 years after endoscopic treatment for postoperative bile duct strictures. Surgical endoscopy 2010; 24: 834-840
3. Cotton PB, Eisen GM, Aabakken L et al. A lexicon for endoscopic adverse events: report of an ASGE workshop. Gastrointestinal endoscopy 2010; 71: 446-454
4. Faigel DO, Ginsberg GG, Kochman ML. Innovative use of the Soehendra stent retriever for biliary stricture recannalization. Gastrointestinal endoscopy 1996; 44: 635
5. Baron TH, Morgan DE. Dilation of a difficult benign pancreatic duct stricture using the Soehendra stent extractor. Gastrointestinal endoscopy 1997; 46: 178-180
6. Ponsioen CY, Arnelo U, Bergquist A et al. No Superiority of Stents vs Balloon Dilatation for Dominant Strictures in Patients With Primary Sclerosing Cholangitis. Gastroenterology 2018; 155: 752-759.e755
7. Cantwell CP, Pena CS, Gervais DA et al. Thirty years' experience with balloon

dilation of benign postoperative biliary strictures: long-term outcomes. Radiology 2008; 249: 1050-1057

8. de Moura EG, Furuya CK, Jr., Mestieri LH et al. Biliary stenosis extreme endoscopy treatment-very large balloon dilation: a new concept. Gastrointestinal endoscopy 2015; 81: 227-228

9. Mohamed E, Kroner PT, Kumar U et al. Use of a Soehendra stent retriever in dilation of an anastomotic biliary stricture in a post-liver transplant patient. Endoscopy 2016; 48 Suppl 1 UCTN: E35-36

10. Inoue T, Ibusuki M, Kitano R et al. Severe Biliary Stricture Dilation Using the Soehendra Stent Retriever with a Short-Type Balloon Enteroscope in Patients with Surgically Altered Anatomies. Journal of gastrointestinal surgery : official journal of the Society for Surgery of the Alimentary Tract 2018, DOI: 10.1007/s11605-018-3977-5:

11. Kawakami H, Kuwatani M, Eto K et al. Resolution of a refractory severe biliary stricture using a diathermic sheath. Endoscopy 2012; 44 Suppl 2 UCTN: E119-120

12. Kawakami H, Kuwatani M, Kawakubo K et al. Transpapillary dilation of refractory severe biliary stricture or main pancreatic duct by using a wire-guided

diathermic dilator (with video). Gastrointestinal endoscopy 2014; 79: 338-343

13. Puri R, Bhatia S, Bansal RK et al. Endoscopic management of difficult benign biliary and pancreatic strictures using a wire-guided cystotome: experience with 25 cases. Endoscopy international open 2018; 6: E797-e800

14. Kawakami H, Kubota Y, Ban T. Rescue antegrade diathermic dilation of hyperplastic tissue at partially covered metallic stent after EUS-guided hepaticogastrostomy. Endoscopy 2017; 49: E285-e287

15. Umeda J, Itoi T, Tsuchiya T et al. A newly designed plastic stent for EUS-guided hepaticogastrostomy: a prospective preliminary feasibility study (with videos). Gastrointestinal endoscopy 2015; 82: 390-396.e392

Figure legends

Fig.1. A wire-guided 6-Fr diathermic catheter (Cyst Gastro-set; Endo-Flex Gmbh, Voerde, Germany)

Fig. 2. The patency rate in the follow-up period

Fig. 3. One case that achieved stent-free state following diathermic dilation and stent placement. (A) Cholangiogram showing severe benign stricture on the right hepatic duct following cholecystectomy. (B) Fluoroscopic and endoscopic images showing diathermic dilation of the stricture. (C) Fluoroscopic image showing placement of the second stent after diathermic dilation. (D) Cholangiogram showing improvement of the severe stricture.

Table 1. Patient characteristics

No.	Age	Sex	Etiology	Location	Length (mm)
1	47	Male	POBS	Bl	18
2	47	Male	POBS	Br	7
3	63	Male	Inflammation	Bi	3
4	47	Male	POBS	Br	7
5	65	Female	POBS	Bra	12
6	76	Female	POBS	B4	6
7	82	Female	Inflammation	Bra	6
8	63	Male	POBS	B2	9
9	54	Female	Ischemic BS	Bi,Bm	4
10	75	Female	Inflammation	Brp	19
11	67	Male	POBS	B2	4
12	67	Male	POBS	B3	4
13	39	Male	POBS	Brp	9

POBS, postoperative biliary stricture; BS, biliary stricture; Bl, left hepatic duct; Br, right hepatic duct; Bi, inferior extrahepatic bile duct; Bm, middle extrahepatic bile duct; Bra, root of duct of right anterior segment; Brp, root of duct of right posterior segment

Table 2. Procedure characteristics

No.	Age	Sex	Location	Pre-dilation	Dilator	Power	Each diathermy (second)	Total time (second)
1	47	M	Bl	SBDC, SSR	6Fr	30W	3sec*1	3
2	47	M	Br	SBDC	6Fr	30W	2sec*1	2
3	63	M	Bi	SBDC	6Fr	30W	2sec*1	2
4	47	M	Br	SBDC	6Fr	30W	3sec*1	3
5	65	F	Bra	SBDC	6Fr	30W	5sec*1	5
6	76	F	B4	SBDC, balloon	6Fr	30W	2sec*1, 3sec*1	5
7	82	F	Bra	SBDC	6Fr	30W	5sec*1	5
8	63	M	B2	SBDC	6Fr	30W	4sec*1	4
9	54	F	Bi,Bm	SBDC	6Fr	30W	2sec*2	4
10	75	F	Brp	SBDC	6Fr	30W	2sec*1 1sec*1	3
11	67	M	B2	SBDC	6Fr	30W	2sec*2	4
12	67	M	B3	SBDC	6Fr	30W	2sec*2	4

13	39	M	Brp	SBDC, balloon, SSR	6, 8.5Fr	30W	3sec*5	15

Bl, left hepatic duct; Br, right hepatic duct; Bi, inferior extrahepatic bile duct; Bm, middle extrahepatic bile duct; Bra, root of duct of right anterior segment; Brp, root of duct of right posterior segment; SBDC, Soehendra biliary dilation catheter; SSR, Soehendra stent retriever



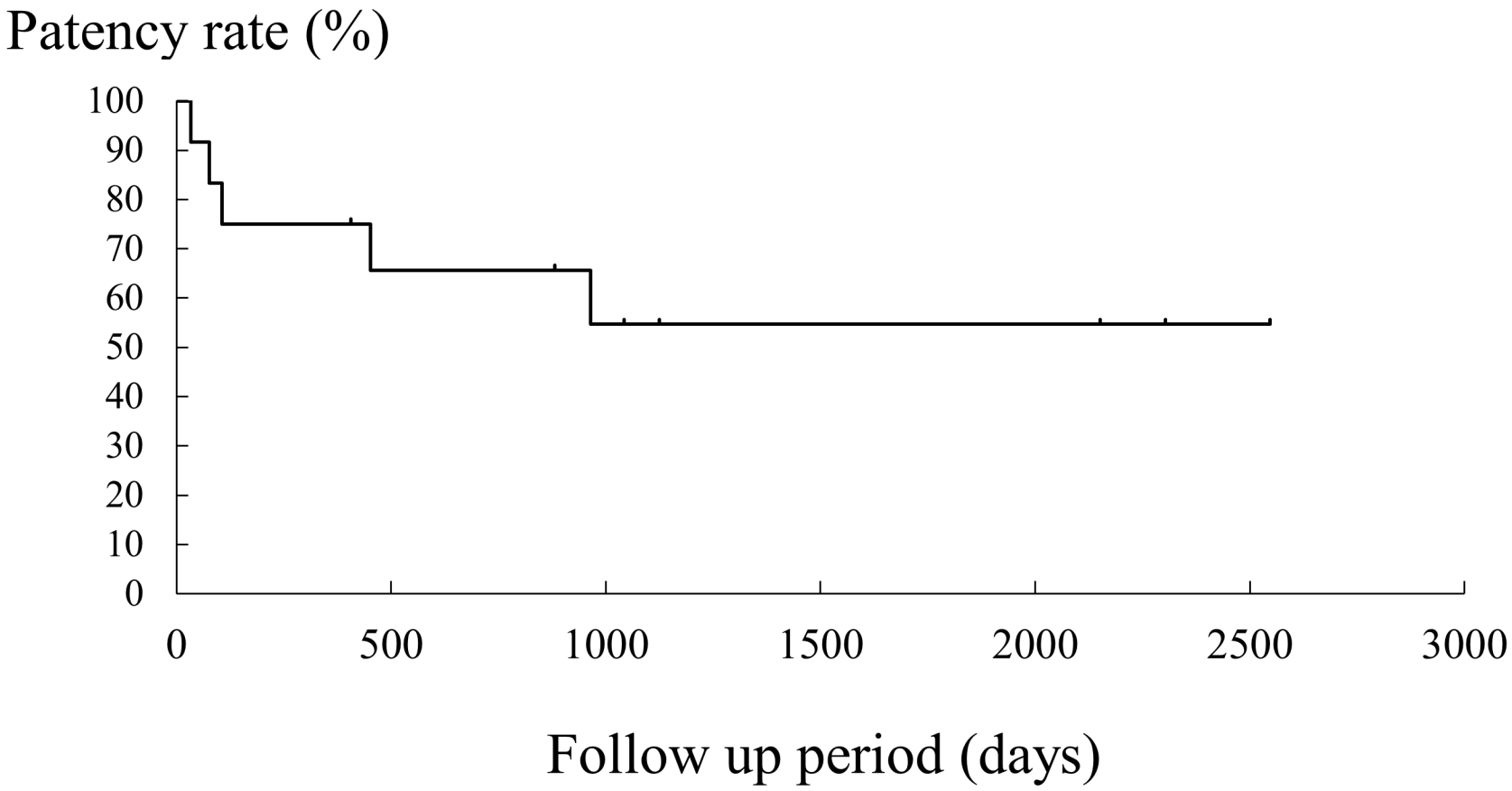
Patency rate (%)
100
90
80
70
60
50
40
30
20
10
0
0
500
1000
1500
2000
2500
3000
Follow up period (days)

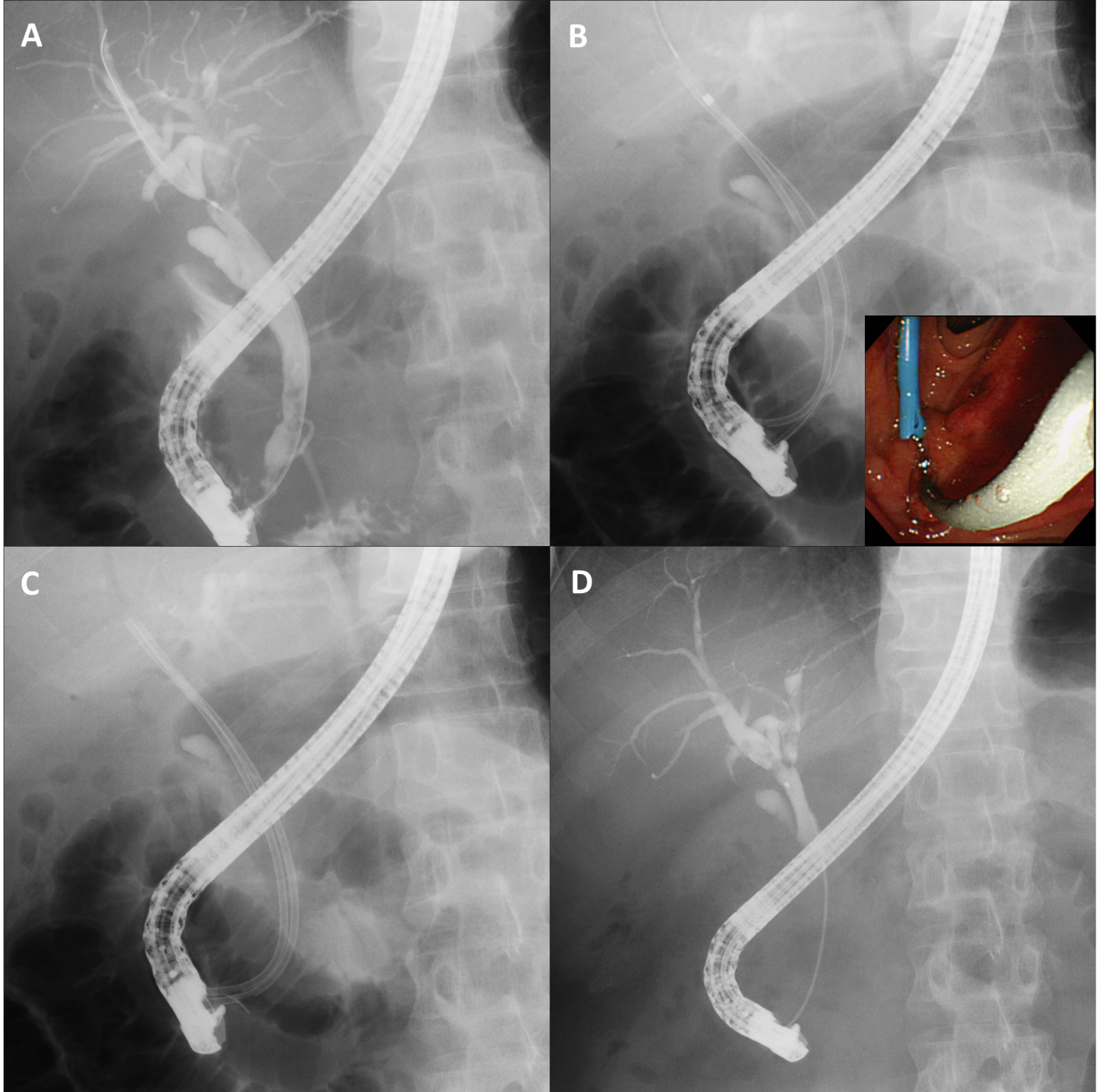
A
B
C
D

Table 1

Patient characteristics

No.	Age	Sex	Etiology	Location	Length (mm)
1	46	M	s/p cholecystectomy	Left hepatic duct	18
2	47	M	s/p GB bed resection	Right hepatic duct	7
3	63	M	Stone	Common bile duct	3
4	47	M	s/p GB bed resection	Right hepatic duct	7
5	65	F	s/p caudal lobectomy	Anterior hepatic duct	12
6	76	F	Ischemic IHBD s/o stricture s/p PD	B4	6
7	82	F	Unknown (no evidence of malignancy)	Anterior hepatic duct	6
8	63	M	s/p right hepatic trisegmentectomy	B2	9
9	54	F	Ischemic BS s/p CPA	Common bile duct	4
10	75	F	Stone (Mirrizi syndrome)	Posterior hepatic duct	19
11	67	M	s/p LDLT†	B2	4
12	67	M	s/p LDLT†	B3	4
13	39	M	s/p left hepatic trisegmentectomy	Posterior hepatic duct	9

† Living donor liver transplantation

Table 2

Procedure characteristics

No.	Pre-dilation	diathermy	Total	Stent	Repeat ERCP after diathermic dilation	Stent Free	Percutaneous approach
1	SBDC†, SSR‡	3sec*1	3	ENBD 6Fr	1.PS exchange (7Fr)⇒ 2.PS exchange (8.5Fr)	Yes	
2	SBDC†	2sec*1	2	PS 7Fr	Re-diathermic dilation (see No.4)	Yes	
3	SBDC†	2sec*1	2	PS 7Fr		Yes	
4	SBDC†	3sec*1	3	PS 7Fr double	1. PS exchange (7Fr) double⇒ 2. PS exchange (7Fr) double	Yes	
5	SBDC†	5sec*1	5	ENBD 6Fr	1. PS exchange (7Fr) double	Yes	
6	SBDC†, balloon	2sec*1, 3sec*1	5	PS 7Fr	1.balloon, SBDC†, PS exchange (7Fr) double⇒ 2. PS exchange (7Fr) double		
7	SBDC†	5sec*1	5	PS 8.5Fr	1. PS exchange (8.5Fr)		
8	SBDC†	4sec*1	4	PS 7Fr			Yes
9	SBDC†	2sec*2	4	ENBD 5Fr	1. FCMS § (10*60mm) ⇒2. FCMS § (10*60mm)	Yes	
10	SBDC†	2sec*1 1sec*1	3	ENBD 5Fr*2	1. SBDC, PS (8.5Fr) double	Yes	Yes
11	SBDC†	2sec*2	4	NA			
12	SBDC†	2sec*2	4	ENBD 6Fr	1. PS exchange (8.5Fr)	Yes	
13	SBDC†, balloon, SSR ‡	3sec*5	15	FCMS § 10*60	1. FCMS § (60mm)⇒2. PS(8.5Fr)⇒PS(7Fr)⇒PS(7Fr)		

†Soehendra biliary dilation catheter, ‡Soehendra stent retriever