Cardiac sarcoidosis mimicking myocardial infarction: a comprehensive evaluation using computed tomography and positron emission tomography

Short title: Cardiac sarcoidosis mimicking myocardial infarction

Tadao Aikawa, MD, PhD;[1] Kazuhiro Koyanagawa, MD;[1] Noriko Oyama-Manabe, MD, PhD;[2] and Toshihisa Anzai, MD, PhD[1]

[1]Department of Cardiovascular Medicine, Hokkaido University Hospital, Kita-14, Nishi-5, Kita-ku, Sapporo 060-8648, Japan; [2]Department of Diagnostic and Interventional Radiology, Hokkaido University Hospital, Kita-14, Nishi-5, Kita-ku, Sapporo 060-8648, Japan

Address for Correspondence:
Dr. Tadao Aikawa
Department of Cardiovascular Medicine
Hokkaido University Hospital
Kita-14, Nishi-5, Kita-ku, Sapporo 060-8648, Japan
Tel.: +81-11-706-6973, Fax: +81-11-706-7874,
Email: aikawatadao@med.hokudai.ac.jp

Keywords: cardiac sarcoidosis, computed tomography, delayed enhancement, ^{18}F-fluorodeoxyglucose positron emission tomography

Word counts: 299

A 66-year-old woman presented with increasing shortness of breath on exertion and several near syncopal episodes. Electrocardiography showed poor R progression in the precordial leads and negative T-waves in leads II, III, aVF, and V4-6 (**Figure 1A**), indicating previous myocardial infarction. Echocardiography showed a left ventricular apical aneurysm (**Figure 1B**). Contrast-enhanced computed tomography (CT) revealed non-significant coronary artery stenoses in all coronary arteries (**Figure 1C**) and bilateral hilar lymphadenopathy (**Figure 1D, arrows**). Fifteen minutes after contrast injection, cardiac CT showed transmural delayed enhancement with intramural thrombus at the left ventricular apical wall (**Figure 1E, red arrow; Video 1**) and subendocardial and subepicardial delayed enhancement in the interventricular septum and left ventricular free wall (**Figure 1E, yellow arrows**), which were consistent with cardiovascular magnetic resonance imaging (MRI) (**Figure 1F, red and yellow arrows; Video 2-3**); meanwhile, cardiovascular MRI also showed hyperenhancement in the right ventricular apex (**Figure 1F, blue arrow**). Subsequent ^{18}F-fluorodeoxyglucose (FDG) positron emission tomography (PET) revealed abnormal FDG uptakes located in the same areas (**Figure 1G-H**). The histological diagnosis of sarcoidosis was confirmed by skin biopsy. She was also diagnosed with sick sinus syndrome and was started with prednisolone 30 mg daily and anticoagulation therapy after implantable cardioverter defibrillator implantation. Three month later, the intramural thrombus and myocardial FDG uptake were decreased (**Figure 1I, Video 4**).

Contrast-enhanced CT can detect coronary artery disease, systemic disease, and cardiomyopathy on delayed phase as a "one-stop shop,"[1] which may be more useful in combination with FDG PET, particularly in patients with suspected sarcoidosis. This case also illustrates that delayed-enhanced CT has the potential to be used as an alternative to cardiovascular MRI in patients with MRI-incompatible devices.

Acknowledgments

This work was supported in part by JSPS KAKENHI (grant number 17K10349).

Conflict of Interest

None.

Reference

1. Schuleri KH, George RT, Lardo AC. Applications of cardiac multidetector CT beyond coronary angiography. Nat Rev Cardiol 2009;6:699-710.

Figure legends

Figure 1. **A** Electrocardiography showed poor R progression in the precordial leads and negative T-waves in leads II, III, aVF, and V4-6. **B** Echocardiography showed a left ventricular apical aneurysm. **C-D** Contrast-enhanced computed tomography (CT) revealed non-significant coronary artery stenoses in all coronary arteries (**C**) and bilateral hilar lymphadenopathy (**D**, *arrows*). **E** Delayed contrast-enhanced CT at 15 minutes after contrast injection showed transmural enhancement with intramural thrombus at the left ventricular apical wall (*red arrow*) and subendocardial and subepicardial enhancement in the interventricular septum and left ventricular free wall (*yellow arrows*). **F** Cardiovascular magnetic resonance imaging (MRI) showed hyperenhancement in the right ventricular apex (*blue arrow*) in addition to a similar distribution of hyperenhanced myocardium in CT (*red and yellow arrows*). **G-H** ^{18}F-fluorodeoxyglucose (FDG) positron emission tomography (PET) showed abnormal FDG uptakes located in the same areas. **I** Three month after steroid and anticoagulation therapy following implantable cardioverter defibrillator implantation, the intramural thrombus and myocardial FDG uptake were decreased.

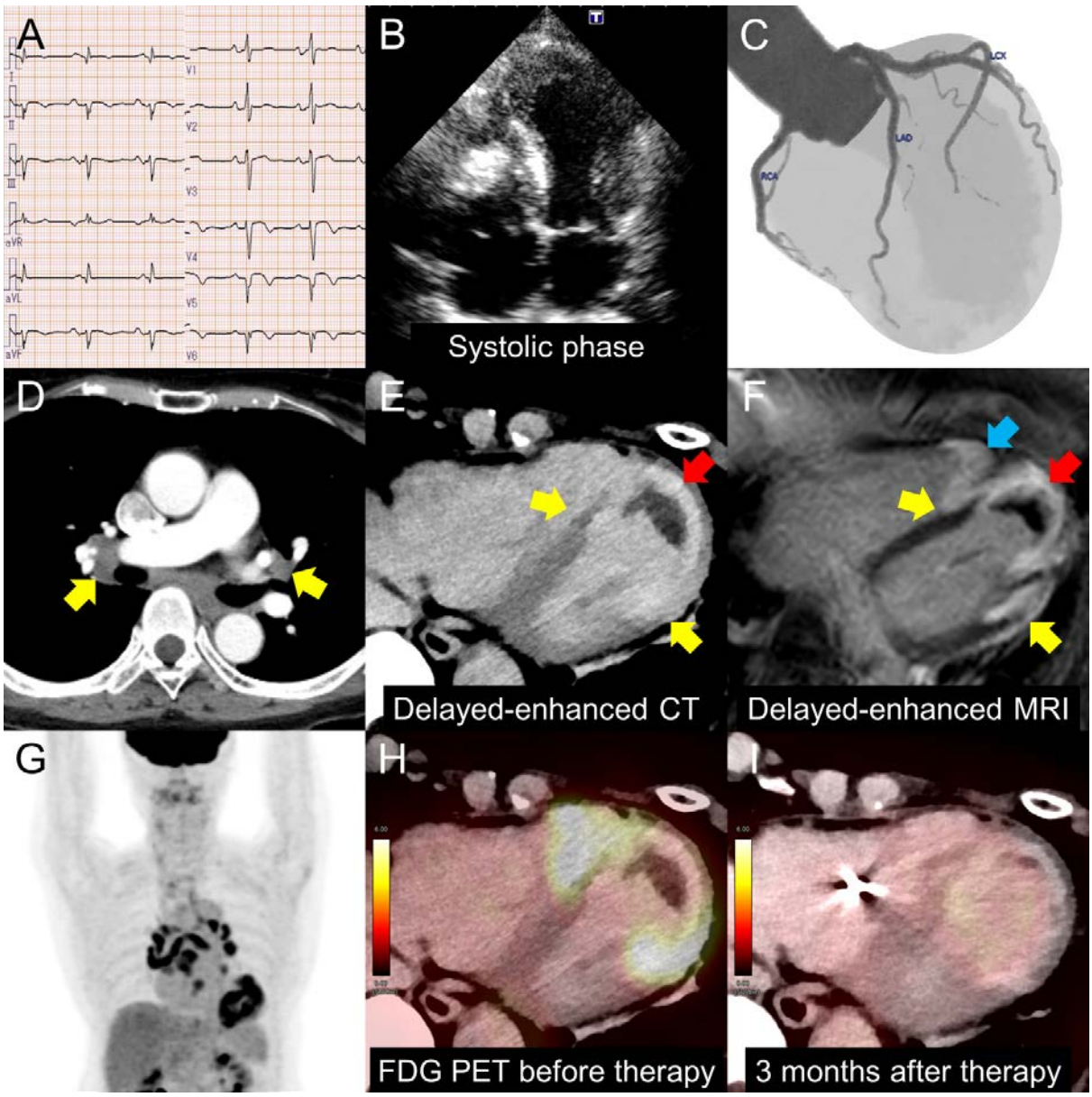
A
B
Systolic phase
C
LCX
LAD
RCA
D
E
Delayed-enhanced CT
F
Delayed-enhanced MRI
G
H
FDG PET before therapy
I
3 months after therapy