# 学　位　論　文

# Diagnosis and Characterization of Endoscopic Findings in XIAP Deficiency

(XIAP 欠損症の診断と内視鏡所見の特徴に関する研究)

2022 年 3 月

北海道大学

シャイマ セイド モハメド アリ アブドラブ

Shimaa Said Mohamed Ali Abdrabou

# 学　位　論　文

# Diagnosis and Characterization of Endoscopic Findings in XIAP Deficiency

(XIAP 欠損症の診断と内視鏡所見の特徴に関する研究)

2022 年 3 月

北海道大学

シャイマ セイド モハメド アリ アブドラブ

Shimaa Said Mohamed Ali Abdrabou

# Table of contents

## 1. List of Publications

1. Sbihi Z, Tanita K, Bachelet C, Bole C, Jabot-Hanin F, Tores F, Le Loch M, Khodr R, Hoshino A, Lenoir C, Oleastro M, Villa M, Spossito L, Prieto E, Danielian S, Picard C, Taga T, **Abdrabou SS**, Isoda T, Yamada M, Palma A, Kanegane H, Latour S. Identification of germline non-coding deletions in XIAP gene causing XIAP deficiency reveals a key promoter sequence. J. Clin. Immunol. (**In press**)
2. **Abdrabou SS**, Toita N, Ichihara S, Tozawa Y, Takahashi M, Fujiwara S, Ashida T, Osamu Ohara O, Ariga T, Manabe A, Konno M, Yamada M. Absent XIAP expression in T cell blasts and causal XIAP mutations including non-coding deletion. Pediatr Int. 2021 Jun 18. Doi: 10.1111/ped.14892 (**Epub ahead of print**)
3. Tozawa Y, **Abdrabou SS**, Nogawa-Chida N, Nishiuchi R., Ishida T, Suzuki Y, Sano H, Kobayashi R, Kishimoto K, Ohara O, Imai K., Naruto T., Kobayashi K, Ariga T, Yamada M. A deep intronic mutation of c.1166-285 T > G in SLC46A1 is shared by four unrelated Japanese patients with hereditary folate malabsorption (HFM). Clin Immunol, 2019 Nov; 208:108256. (**Equal contribution**)
4. Ueki M, Yamada M, Ito K, Tozawa Y, Morino S, Horikoshi Y, Takada H, **Abdrabou SS**, Takezaki S, Kobayashi I, Ariga T. A heterozygous dominant-negative mutation in the coiled-coil domain of STAT1 is the cause of autosomal-dominant Mendelian susceptibility to mycobacterial diseases. Clin Immunol, 174 (2017) 24–31.

## 2. List of Presentations

1. Yamada M, Yodo H, Kawasaki Y, Nagamori T, **Abdrabou SS**, Hiroshi H, Ariga T, Nobuta T, Tozawa Y, Ueki M, Takezaki S, Manabe A. Primary Immunodeficiency Database in Hokkaido (PID). The 3rd annual meeting of the Japanese Society for Immunodeficiency and auto Inflammatory diseases, Tokyo, 2020 (**Oral presentation)**
2. 戸澤雄介, **Abdrabou Shimaa**, 野川奈津子, 西内律雄, 石田敏章, 佐野秀 樹, 鈴木雄一, 小林良二, 小原收, 成戸卓也, 今井耕輔, 小林邦彦, 有賀正, 山田雅文 新たに診断した残存活性を有する遺伝性葉酸吸収不全症例と既報 3 症例と の比較検討 第 2 回日本免疫不全・自己炎症学会総会・学術集会, 2019, 東京(**Oral presentation)**
3. Toita N, **Abdrabou SS**, Ichihara S, Tozawa Y, Takahashi M, Fujiwara S, Ashida T, Ohara O, Ariga T, Manabe A, Konno M, Yamada M, Kanegane H. Clinical and Endoscopic Features of XIAP Deficiency Mimicking Refractory Crohn's Disease in Pediatric Patients. 5th annual meeting of American society for digestive disease, San Diego, U.S.A, 2019 **(Poster presentation)**

4. Toita N, **Abdrabou SS**, Ichihara S, Yusuke Tozawa Y, Takahashi M, Fujiwara S, Ashida T, Ohara O, Ariga T, Manabe A, Konno M, Yamada M, Kanegane H. Clinical and Endoscopic Features of XIAP Deficiency Mimicking Refractory Crohn's Disease in Pediatric Patients. 14th annual congress of European Crohn's and colitis organization, Copenhagen, Denmark, 2019 **(Poster presentation)**
5. **Abdrabou SS**, Tozawa Y, Ohara O, Sasahara Y, Uchida T, Takahashi M, Fujiwara S, Toita N, Yamada M. Screening of monogenic IBD in Hokkaido, Japan led to the diagnosis of 4 patients with XIAP deficiency and one with late-onset IPEX syndrome. The 9th Asian congress of Pediatric Infectious Diseases, Fukuoka, 2018 (**Oral presentation)**
6. **Abdrabou SS**, Tozawa Y, Ohara O, Sasahara Y, Uchida T, Takahashi M, Fujiwara S, Toita N, Yamada M. Screening of monogenic IBD in Hokkaido, Japan led to the diagnosis of 4 patients with XIAP deficiency and one with late-onset IPEX syndrome without AIE-75 autoantibodies. 18th Biennial Meeting of the European Society for Immunodeficiencies, Lisbon, Portugal, 2018. **(Poster presentation)**
7. **Abdrabou SS**, Yamada M, Tozawa Y, Ueki M, Takezaki S, Ariga T, Atsushi S, Fujiwara S, Takahashi M, Konno M, Sugita J, Katsura T, Ushida T, Kanako T, Ohara O: Three patients with XIAP deficiency in Hokkaido who presented with recurrent HLH and refractory IBD. 1st Japanese Society for Immunodeficiency and Autoinflammatory Diseases (JSIAD), International section, Tokyo, 2017. **(Oral presentation)**
8. Tozawa Y, Yamada M, **Abdrabou SS**, Nishiuchi R, Nogawa N, Kobayashi R, Ohara O, Kobayashi K, and Ariga T. The same deep intronic mutation of c.1166-285T>G in SLC46A1is responsible for hereditary folate malabsorption in two unrelated Japanese patients. The Meeting of the European Society for Immunodeficiencies, Edinburg, UK, 2017 (**Poster presentation)**
9. 戸澤雄介，山田雅文，西内律雄，**Abdrabou Shimaa**，野川奈津子，小林良 二，小原收，小林邦彦，有賀正 先天性葉酸吸収不全症の 2 例 第 49 回日本小児感染症学会総会・学術集会，2017，金沢 (**Poster presentation)**
10. Ueki M, Yamada M, Fujita H, Miyake N, Watanabe M, Tozawa Y, **Abdrabou SS**, Takezaki S, Kobayashi I, Hatakeyama S, Matsumoto N, Iwai K, Ariga T. A Novel autoinflammatory Disease Associated with Hyperactivation of NF-kB Signaling. The 17th European Society for Immunodeficiencies, Barcelona, Spain, 2016. (**Poster presentation)**

# Summary

## Background and Objectives

Inflammatory bowel disease (IBD) is a diverse group of disorders with multifactorial etiology. Recent studies have reported increasing numbers of monogenic IBD caused by mutations in various genes including *XIAP, IL10R, FOXP3, CTLA4, LRBA, CYBB, WASP, IKBKG*, especially in very early-onset IBD (VEO-IBD) and refractory IBD. For the diagnosis of monogenic IBD, whole exome sequence analysis (WES) and panel sequence analysis of various genes responsible for IBD are widely available. However, the proportion of monogenic IBD in VEO-IBD varies between centers and cohorts and ranges from 5-31%. Furthermore, deep intronic mutations and mutations only affecting untranslated regions (UTR) are difficult to identify with DNA sequencing analysis, which could be associated with undiagnosed monogenic IBD. X-linked inhibitor of apoptosis protein (XIAP) deficiency is one of inborn errors of immunity characterized by recurrent hemophagocytic lymphohistiocytosis (HLH) and IBD. This disorder is especially one of the monogenic causes of refractory IBD mimicking Crohn's disease (CD). Hematopoietic stem cell transplantation (HSCT) is the only curative therapy of XIAP deficiency and is especially required in patients complicated with refractory IBD or HLH. Although variants in *XIAP* were demonstrated in about 4% of male patients with pediatric-onset CD, there could be still underdiagnosed patients. IBD phenotype in XIAP deficiency is hypothesized to be caused by impaired NOD2 signaling resulting in granulomatous colitis and perianal disease mimicking Crohn's disease. However, specific clinical characteristics of IBD in XIAP deficiency, including endoscopic findings are poorly understood. Therefore, we tried to establish simple and accurate methods for the diagnosis of XIAP deficiency based on genetic and protein expression studies and to investigate endoscopic findings shared by patients with this disease.

## Materials and Methods

Four unrelated Japanese male patients with IBD and histories of HLH were studied for the diagnosis of XIAP deficiency. XIAP expression was studied in isolated peripheral blood mononuclear cells (PBMC) and in phytohemagglutinin (PHA)-stimulated T cell blasts from patients and controls as follows: fresh peripheral heparinized blood samples were drawn from the patients and controls, PBMC were isolated and PHA-stimulated T cell blasts were obtained. Then, SDS-PAGE, and Western blot analysis of XIAP expression were performed with cytoplasmic extract. Anti-XIAP antibody and anti-actin antibody were used as primary

antibodies. The rest of PBMC was used for RNA isolation, cDNA synthesis, and subsequent TOPO-TA cloning. DNA was extracted from the patients and controls' granulocytes. PCR and RT-PCR primers sets were designed to cover full-length *XIAP* gene coding, non-coding exons and to determine the deletion breakpoints in 5'UTR of Patient 4. Parallelly, we retrospectively evaluated endoscopic findings of four patients with XIAP deficiency and those of 127 pediatric-onset conventional CD patients.

**Results**

These four patients were diagnosed with XIAP deficiency based on the absent XIAP expression in cultured T-cell blasts. Sequence analysis of the responsible gene, *XIAP*, demonstrated two distinct novel nonsense mutations of p.Gln114X and p.Glu25X, and a previously reported nonsense mutation of p.Arg381X. Although no mutations in the coding region were detected in the fourth patient, further studies demonstrated a novel 2199 bp deletion encompassing non-coding exon 1, presumably affecting transcription/stability but also translation of *XIAP* mRNA possibly due to the lack of internal ribosomal entry sites sequences. Patient 4's mother was shown to be an asymptomatic heterozygous carrier of the deletion while his brother did not have this deletion. These four patients shared endoscopic findings of wide and longitudinal ulcers with straight and non-raised edge with "scooped-out appearance" in the colon, which was not observed in other 127 pediatric-onset conventional CD patients, indicating this finding could be specific to XIAP deficiency. All of the patients eventually underwent hematopoietic stem cell transplantation, leading to complete or partial remission of IBD.

**Discussion**

One of the concerns to identify genetic causes accurately is whether some disease-causing mutations located deep within introns or UTR were overlooked in some cases, since detection and validation of these mutations are challenging. The deletion mutation encompassing non-coding exon 1 (5'UTR) of *XIAP* observed in Patient 4 is one of the cases unidentified by panel sequence analysis or WES focusing only on coding exons and exon-intron boundaries. In Patient 4, absent XIAP expression in Western blot analysis of T-cell blasts led to the diagnosis of XIAP deficiency. Therefore, this analysis should be considered as one of the first screening methods for the diagnosis of this disease especially in shipped patients' samples with increased apoptotic conditions and in limited samples from neonates or infants,

since T-cell blasts can be easily obtained from small amount regardless of the conditions of blood and patients.

To the best of our knowledge, there have been no reports of a deletion mutation affecting only non-coding exon 1 (5'UTR) of *XIAP*, while gross deletion mutations encompassing coding exons of 1-2, 1-4, 1-6, and 4-6 have been reported.
Electrophoresis of RT-PCR products in this patient showed a faint but detectable band in contrast with complete absence of XIAP expression at protein levels. Our additional studies with a French group indicated an active promoter region in 5'UTR determined by gene reporter expression assays in HEK 293 cell lines (under minor revision). And about translation, there are some previous findings that XIAP mRNA is controlled at the translational level, specifically through an internal ribosome-entry site (IRES) residing at 5'UTR. Therefore, complete absence of XIAP expression at protein levels in Patient 4 could be attributable to abrogated translation in addition to impaired transcription or stability of *XIAP* mRNA due to the deletion of 5'UTR.

One of the challenges is to differentiate XIAP deficiency from conventional CD, which would facilitate early HSCT to avoid life-threatening events like HLH and the occurrence of refractory IBD. Therefore, we retrospectively evaluated endoscopic findings of the four patients with XIAP deficiency and those of 127 patients with pediatric-onset conventional CD. And we detected an endoscopic finding exclusively observed in XIAP deficiency: multiple wide and longitudinal ulcers with straight and non-raised edge. We named "scooped-out appearance", since the ulcer bed looked like a track scooped out by a spoon. Although multiple longitudinal ulcers are also observed in conventional CD, their ulcers are mostly narrow and sharp, and their ulcer edges were irregular shaped and slightly raised. This endoscopic finding has not been reported from elsewhere, but needs to be reproduced with more patients. All patients underwent allogeneic HSCT, which led to a-complete remission of IBD in P1, P2, and P3 while P4 showed partial remission of IBD due to mixed chimeric state.

**Conclusion**

Four patients were diagnosed with XIAP deficiency who had presented for 3-10 years with refractory IBD mimicking CD. We report three distinct novel mutations in *XIAP* gene including one in XIAP 5'UTR. Collectively, panel sequence analysis of sequence analysis

including *XIAP* and XIAP expression in T-cell blasts should be performed for the early and accurate diagnosis of XIAP deficiency especially in patients with refractory IBD with HLH, and splenomegaly. Endoscopic findings of multiple wide and longitudinal ulcers with scooped-out appearance could also a clue to the diagnosis of XIAP deficiency. Further studies including more patients with XIAP deficiency are necessary to determine whether this endoscopic finding is specific to XIAP deficiency.

# List of Abbreviations

| | |
|---|---|
| **5-ASA** | 5-aminosalicylic acid |
| **ADA** | Adalimumab |
| **AZA** | Azathioprine |
| **C** | Control |
| **CD** | Crohn's disease |
| **CsA** | Cyclosporine A |
| **CT** | Computerized topography |
| **EBV** | Epstein-Barr virus |
| **GAPDH** | Glyceraldehyde-3-phosphate dehydrogenase |
| **HLH** | Hemophagocytic lymphohistiocytosis |
| **HSCT** | Hematopoietic stem cell transplantation |
| **IBD** | Inflammatory bowel disease |
| **IFX** | Infliximab |
| **IL18** | Interleukin 18 |
| **mPSL** | Methylprednisolone |
| **NOD2** | Nucleotide-binding oligomerization domain-containing protein 2 |
| **PBMC** | Peripheral blood mononuclear cells |
| **PHA** | Phytohemagglutinin |
| **PSL** | Prednisolone |
| **P** | Patient |
| **sIL2** | Soluble interleukin 2 |
| **TAC** | Tacrolimus |
| **UST** | Ustekinumab |

| | |
|---|---|
| **UTR** | Untranslated regions |
| **XIAP** | X-linked inhibitor of apoptosis protein |
| **VEO-IBD** | Very early-onset IBD |
| **WES** | Whole exome sequence |

# 1. Introduction

## 1.1 Inflammatory bowel disease (IBD) and monogenic IBD

Inflammatory bowel disease (IBD) is a diverse group of disorders with multifactorial etiology affecting the intestines including Crohn's disease (CD) and ulcerative colitis (UC) (Hendrickson et al., 2002). CD can affect people at any age. However, most of cases are diagnosed in adolescents and young adults at the age of 15-35 years. Approximately 10 percent of cases are under the age of 18 years (Ponder and Long, 2013).

While monogenic IBD exhibits IBD symptoms mimicking CD or US due to single genetic abnormality. Recent studies have reported increasing numbers of monogenic IBD caused by mutations in various genes including *XIAP, IL10R, FOXP3, CTLA4, LRBA, CYBB, WASP, IKBKG,* etc. especially in very early-onset IBD (VEO-IBD) (Nameirakpam et al., 2020; Pazmandi and Kalinichenko, 2019).

For the diagnosis of monogenic IBD, whole exome sequence analysis (WES) and panel sequence analysis of various genes responsible for IBD are recently available. However, the proportion of monogenic IBD in VEO-IBD varies between centers and cohorts and ranges from 5-31% (Pazmandi and Kalinichenko, 2019). Furthermore, deep intronic mutations and mutations only affecting untranslated regions (UTR) are difficult to be identified with DNA sequence analysis, which could be associated with undiagnosed monogenic IBD.

## 1.2 X-linked inhibitor of apoptosis protein (XIAP) deficiency

X-linked inhibitor of apoptosis protein (XIAP) deficiency is one of the inborn errors of immunity (IEI) classified as X-linked lymphoproliferative disease type 2. It has a wide range of clinical presentations including IBD, hemophagocytic lymphohistiocytosis (HLH) often triggered by EBV infection, splenomegaly, and hypogammaglobulinemia (Table 1) (Pachlopnik Schmid et al., 2011; Sylvain and Aguilar, 2015; Aguilar et al., 2014; Rigaud et al., 2006; Speckmann et al., 2013). Although occurrence of variants in *XIAP* was demonstrated in about four percent of male patients with pediatric-onset CD (Zeissig et al., 2015), it is still underdiagnosed. Therefore, it is important to focus more on XIAP deficiency in these patients.

**Table 1:** Manifestations of XIAP deficiency

| Manifestations | (%) |
|---|---|
| HLH without EBV | 76 |
| HLH with EBV | 83 |
| Splenomegaly | 87 |
| IBD | 26 |
| Hypo- or dys-gammaglobulinemia | 33 |
| Lymphoma | 0 |

### *1.2.1 XIAP structure and molecular basis*

XIAP is one of the inhibitors of apoptosis (IAP) family members.

*XIAP* mutations were firstly observed in 12 boys with HLH from three unrelated families (Rigaud et al., 2006; Zhizhuo et al., 2012).

*XIAP* consists of three BIR domains (BIR1, BIR2 and BIR3) which provide protein to protein interactions. It consists also of one ubiquitin binding domain (UBD) and a C-terminal RING domain with ubiquitin protein ligase (E3) activity. *XIAP* consists of seven exons in which untranslated regions (UTR) represents the non-coding exon 1 (Rigaud et al., 2006) (Figure 1) (Hans D. Ochs 2014)**.**

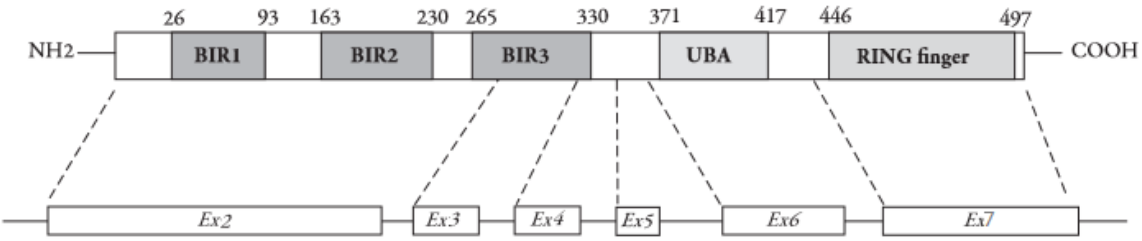


**Figure 1.** *XIAP* gene structure and organization

XIAP protein is ubiquitously expressed. It has comparable expression in all hematopoietic cells. Also, it is significantly expressed in small intestines, colon, liver, and spleen (Rigaud et al., 2006).

### 1.2.2 XIAP functions and its possible relations with HLH and IBD

It was reported that XIAP is a potent physiological inhibitor to apoptosis, and it plays a potent inhibitory role in programmed cell death. That could be through the inhibition of caspases 3, 7, and 9 in activated T cells promoting their survival and expansion (Eckelman et al., 2006). XIAP was also involved in the inhibitory signaling of the inflammasomes (Wan-Chen Hsieh et al., 2014). In case of XIAP deficiency, loss of antiapoptotic function and more activation of caspases leading to increased cell death with accumulation of infectious pathogens. In addition, uncontrolled inflammasomes cause more production of proinflammatory cytokines such as IL1β and IL18. All of these dysregulated responses could be associated with chronic inflammation, HLH, splenomegaly, and IBD in XIP deficiency. (Yabal et al., 2014; Sylvain and Aguilar, 2015).

XIAP is also associated with proinflammatory response via NOD-like receptor (NOD) signalling pathway (Krieg et al., 2009). IBD phenotype in XIAP deficiency is hypothesized to be caused by impaired NOD2 signaling resulting in granulomatous colitis and perianal disease mimicking Crohn's disease (Aguilar et al., 2014; Pachlopnik Schmid et al., 2011). However, specific clinical characteristics of the colon disease, including endoscopic findings in patients with XIAP deficiency are poorly understood.

Hematopoietic stem cell transplantation (HSCT) is the only curative therapy and is especially required in patients with refractory IBD or HLH (Aguilar et al., 2014; Ono et al., 2017).

In this study, four male patients with refractory IBD and recurrent HLH were diagnosed with XIAP deficiency based on the absent XIAP expression in T cell blasts. Although no mutations were detected in one patient, further studies demonstrated a novel 2199 bp deletion encompassing non-coding exon 1, presumably affecting transcription and stability of *XIAP* mRNA. We also clarified the endoscopic findings of multiple wide and longitudinal ulcers with scooped-out appearance in the colon shared by the four patients,

which may be specific to XIAP deficiency.  Therefore, these endoscopic findings could also be the clues to the diagnosis of XIAP deficiency.

# 2. Materials and Methods

Written informed consent was obtained from the four patients, their family members, and controls under a protocol for genetic studies and registry of primary immunodeficiency disease, autoinflammatory disease, and early-onset inflammatory bowel disease (No. R1-01 approved by Hokkaido University), which had been approval by the Institutional Review Board (IRB) of Tokyo Medical Dental University as a central review institute (No. G2019-004).

## 2.1 Patients

Patients 1-4 were born to unrelated non-consanguineous healthy Japanese parents. All of the patients shared the clinical manifestations of refractory IBD and recurrent HLH and had been diagnosed with refractory CD for years. Summary of the four patients were shown in Table 2.

**Patient 1:** He had a past history of HLH at the age of 1 year which resolved with steroid and additional therapies. At the age of 8 years, he developed pancytopenia due to parvovirus B19 infection. He presented with fever, diarrhea, and anal abscess at the age of 11 years and was diagnosed with CD based on the endoscopic and histopathological findings. At the age of 12 years, he suffered from HLH associated with EBV infection. He was treated with 5-aminosalicylic acid (5-ASA) and prednisolone (PSL) with total parenteral nutrition (TPN), which induced remission. He remained in remission for one year, but subsequent recurrence of symptoms could not be prevented by the addition of azathioprine (AZA). Methylprednisolone (mPSL) pulse therapy, tacrolimus (TAC), and adalimumab (ADA) provided partial improvement. He was hospitalized 6 times during the next 6 years due to recurrence of IBD. Then he was referred to our hospital and was suspected of having XIAP deficiency at the age of 17 years based on recurrent HLH, refractory IBD, and splenomegaly

on abdominal CT scan (Figure 2A).

**Patient 2**: He had a recurrent fever since the age of 6 months. He developed persistent perianal abscess and bloody diarrhea at the age of 8 years and was diagnosed with CD based on the endoscopic and histopathological findings. His clinical course was severe and refractory to treatment with 5-ASA, PSL, mPSL pulse, AZA, TAC, cyclosporine A (CsA), and ADA. He remained on steroids and was TPN-dependent and was hospitalized for the next 3 years. At the age of 9 years, he developed fever, rash, and cervical lymph nodes swelling and elevated serum ferritin of 40790 ng/ml. He was diagnosed with HLH, which resolved following the treatment with dexamethasone palmitate, intravenous immunoglobulin, and thrombomodulin α. Then he was referred to our hospital and was suspected of having XIAP deficiency at the age of 11 years based on refractory IBD and a history of HLH.

**Patient 3**: His initial symptoms were abdominal pain, diarrhea, and fever at the age of 11 years, and then he was diagnosed with CD based on the endoscopic and histopathological findings. Response to immunosuppressive or biologic therapies with AZA, TAC, infliximab (IFX), ADA, and ustekinumab (UST) was poor. He suffered from recurrent episodes of IBD 6 times, and was hospitalized every occasion during 6 years. He subsequently developed perianal ulcers with persistent fistula and seton rubber was installed for long-term drainage. He then developed catheter-related blood stream infection (CRBSI) and disseminated intravascular coagulation (DIC) after adalimumab and ustekinumab administration. He also developed HLH twice during seven years of IBD therapy. He had a past history of congenital biliary dilatation with pancreaticobiliary maljunction which required operations of at the age of 3 years. He was referred to our hospital and was suspected of having XIAP deficiency at the age of 17 years based on the refractory course of IBD and recurrent HLH.

**Patient 4**: He was admitted to **A** hospital because of prolonged fever of unknown origin at the age of 2 months. Although fever spontaneously regressed without any treatment, he

subsequently had recurrent fever with thrombocytopenia and hyperferritinemia. At one year and 7 months of age, he was hospitalized in **B** hospital since he suffered from EBV-associated HLH. Because of persistent fever for a month and decrease of platelet counts of 50,000 /μl, prednisolone (PSL) therapy was initiated and improved the clinical conditions. At the age of one year and 9 months, he was hospitalized and diagnosed with EBV-associated HLH. At 8 years of age, he complained of persistent diarrhea and abdominal pain, and was diagnosed with CD based on the endoscopic findings at **C** hospital. Since IBD was active and refractory to various treatment, he underwent left hemicolectomy at the age of 10 years. At 13 years of age, the residual colon was resected, and stoma was installed. Three months later, he developed pyoderma and gangrene around the stoma. At the age of 15 years, he developed proctitis of the residual ileum and underwent reconstruction of the rectum. He also developed refractory anal fistula (Figure 2B). Then he was referred to our hospital at the age of 17 years. Laboratory examination showed highly elevated serum IL18 level (18,000 pg/ml) (normal range: 0-300 pg/ml). Abdominal CT scan showed splenomegaly. He was suspected of having XIAP deficiency at the age of 17 years based on the refractory course of IBD, recurrent HLH, and splenomegaly.

**A** **B**

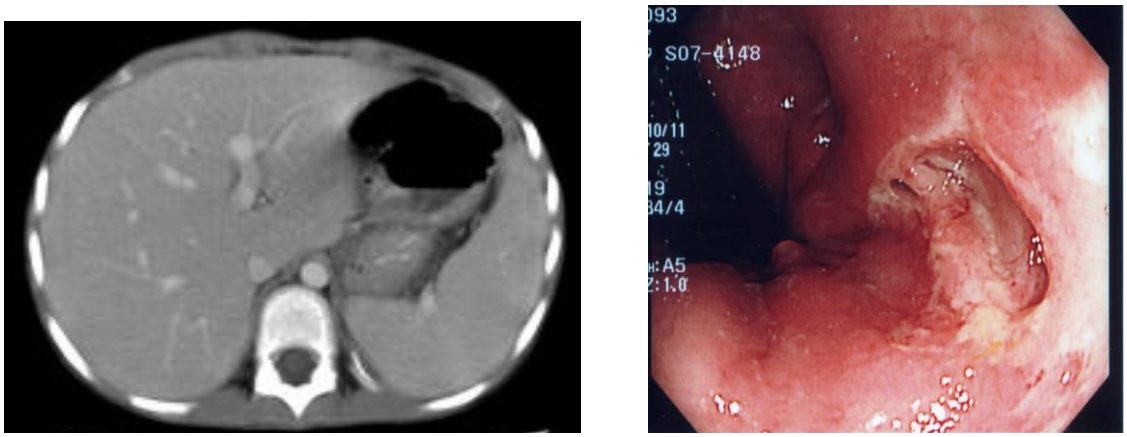


**Figure 2 A,** Abdominal CT scan showed splenomegaly in Patient 1. **B,** Colonoscopy showed perianal ulcers and anal fistula in Patient 4.

**Table 2.** Clinical features and *XIAP* mutations in the four patients with XIAP deficiency

| Patient | 1 | 2 | 3 | 4 |
|---|---|---|---|---|
| Current age | 20 y | 14 y | 20 y | 21 y |
| Age at diagnosis of XIAP deficiency | 17 y | 11 y | 17 y | 17 y |
| Past history (age) | Pancytopenia due to Parvovirus B19 (8 y) | (-) | Congenital biliary dilatation | (-) |
| Age at IBD onset | 11 y | 8 y | 11 y | 8 y |
| Symptoms at IBD onset | Perianal abscess, fever, bloody diarrhea | Perianal abscess, bloody diarrhea | Fever, anemia, diarrhea | Fever, bloody diarrhea, anal fistula |
| IBD treatments | 5-ASA, PSL, AZA, TAC, mPSL pulse, ADA | 5-ASA, PSL, AZA, TAC, mPSL pulse, GMA, ADA, CsA | 5-ASA, AZA, IFX, GMA, TAC, ADA, UST | 5-ASA, PSL, TAC, IFX |
| Nutritional support | Repetitive TPN and ED | Repetitive TPN and ED | Repetitive TPN and ED | Repetitive TPN and ED |
| Surgery | (-) | (-) | (-) | Left colectomy→ total colectomy and stoma |
| Complications | Refractory anal fistula, erythema nodosum | Refractory anal fistula, acute pancreatitis | Perianal abscess, refractory anal fistula | Refractory anal fistula, pyoderma gangrenosum |
| Age at HLH onset | 1y (EBV) | 9 y | 11 y | 1y (EBV) |
| Total flairs of HLH (times) | 4 | 2 | 2 | 2 |
| Splenomegaly | (+) | (-) | (-) | (+) |
| Mutations | c.340C>T, p.Gln114X | c.1141C>T, p.Arg381X | c.73G>T, p.Glu25X | Deletion of non-coding exon 1 |
| XIAP expression in T cell blasts | Absent | Absent | Absent | Absent |
| Allogeneic HSCT | (+) | (+) | (+) | (+) |

HLH, hemophagocytic lymphohistiocytosis; IBD, inflammatory bowel disease;5-ASA, 5-aminosalicylate; PSL, prednisolone; mPSL, methylprednisolone; AZA, azathioprine; IFX, infliximab; ADA, adalimumab; TAC, tacrolimus; CsA, cyclosporine A; UST, ustekinumab; GMA, granulocyte, and monocyte adsorptive apheresis; TPN, total parenteral nutrition; ED, elemental diet; HSCT, hematopoietic stem cell transplantation; +, yes or positive; -, no or negative; y, years

## 2.2 Preparation of cytoplasmic extract, SDS-PAGE, and Western blot analysis of XIAP expression in PBMC and T cell blasts

XIAP expression was studied in isolated peripheral blood mononuclear cells (PBMC) and in PHA-stimulated T cell blasts from patients and Controls as the following:

### *2.2.1 Isolation of PBMC and establishment of PHA-stimulated T cell blasts*

Fresh peripheral heparinized blood samples were drawn from the patients and controls. PBMC were isolated using a density gradient centrifugation HistopaQue ®-1077 buffer (Sigma-Aldrich, St. Louis, MO). The samples were mixed with the same volume of normal saline. Seven to eight ml of the diluted blood sample was carefully layered onto the HistopaQue media, then they were centrifuged at 1500 rpm for 30 min at room temperature (22-23°C). PBMC layers were transferred into 15 ml test tubes and mixed with 4-5 ml of 1x PBS (137mM NaCl, 8.1 mM Na2PO4, 2.7 mM KCl and 1.5mM $KH2PO_4$). The mixtures were centrifuged at 2000 rpm for 10 min at 4°C. The cells were washed twice with 1x PBS, centrifuged at 2000 rpm for 5 min at 4°C.

For obtaining T cell blasts, PBMC (1x10^6 cells/ml) were incubated in RPMI-1640 media containing 10% FBS and penicillin /streptomycin (100 µg/ml). PHA was added to the cells with a final concentration of 1 µg/ml on the first day. Recombinant human IL-2 was added to the media 48 hrs later with a final concentration of 10 µg/ml and was added every two days.

### *2.2.2 Cell lysates*

PBMC and PHA-stimulated T cell blasts were collected, washed with 1x PBS, and centrifuged at 2000 rpm for 5 min at 4°C. Two volumes of ELB-Cytoplasmic extraction buffer (5M NaCl,1M HEPES pH 7.9) (GIBCO BRL), 10% Nonidet P-40,0.5M EDTA, $H_2O$) (Nacalai Tesque, Kyoto, Japan) with 4% Complete, protein inhibitor cocktail tablets (Roche, Mannheim, Germany) ,1 mM activated Na3VO4 and 1 mM NaF were added to cell pellets and mixed well. The samples were incubated on ice for 30 min with intermittent vortex regularly and then

centrifuged at 15,000 rpm for 5 min at 4°C. The supernatant was saved as cytoplasmic extract. One µl of each protein sample was mixed with 1 ml of diluted Bio-RAD reagent (protein assay, Bio-RAD, Hercules, CA) and incubated for 10 min at room temperature. Then the protein concentrations were measured by DU series spectrophotometer (BECKMAN). Protein concentrations of cytoplasmic extract from T cell blasts in P1, P2, P3, P4, C1, C2, P4's mother, and his brother was 8.27, 12.32, 9.52, 11.93, 9.83, 10.2, 8.5, and 7 µg/ml respectively. Protein concentration of PBMC was 11, 16.8 and 12 µg/ml in P4, C1, and C2 respectively.

### *2.2.3 SDS- PAGE*

4x SDS buffer (8% sodium dodecyl sulfate, 20% glycerol, 250mM Tris-HCL (PH6.8) with (20% volume of 2-mercaptoethaol and bromophenol blue) was mixed with each cytoplasmic extract samples. The samples were boiled for 4 min, spun down at maximum speed for 5 min at the room temperature. Forty ug of each sample were loaded into 10% SDS-PAGE gels with precision plus protein standards Kaleidoscope marker (Bio-RAD). Gel electrophoresis was run in 1x SDS-PAGE gel running buffer (Tris 3.03 g, glycine 14.4 g, SDS 1g to total 1000 ml D.W) using Bio-RAD Mini PROTEAN-3-Cell apparatus, (U.S.A). The gels were transferred to Immobilon transfer membranes, PVDF (Merck KGA, Darmstadt, Germany) using ATTO Blotting system and transferring buffer (Tris 5.8 g, glycine 2.9 g, SDS 0.37 g, MEOH 200 µl /1000 µl) for 1h. Blocking was done using 1x TBST (1M Tris (pH 8.0), 5 M NaCl, Tween 20 and DDW) containing 5% skim milk for an hour at the room temperature. The membranes were incubated with anti-XIAP antibody (XIAP 3B6, rabbit monoclonal antibody, IgG) (Cell Signaling Technology, U.S.A) after 1:1000 dilution in 1x TBST with 5% skim milk overnight on an orbital shaker at 4°C. After the membranes were washed three times with 1x TBST buffer for 15 min, they were incubated with secondary antibody, HRP monkey anti-rabbit IgG (polyclone 4064, BioLegend), for 1h at the room temperature. After they were washed three times with 1x TBST buffer, they were stained with Pierce™ Western blotting substrate (Thermo

Scientific U.S.A) and ECL Select™ Detection Reagent, Italy) and analyzed with UV Fujifilm thermal system. The membranes were submerged in stripping buffer (2-mercaptoethaol 0.7 ml, 10% SDS 20 ml, 1M Tris /73 ml DDW) and incubated at 60°C for 40 min, then washed 3 times with 1x TBST. Actin expression was used as a loading control. Actin antibody (BioLegend, San Diego, CA) was used as a primary antibody while HRP goat anti-mouse IgG, BioLegend) was used as a secondary antibody.

## 2.3 DNA and total RNA isolation, cDNA synthesis, RT-PCR, and TOPO-TA cloning

### *2.3.1 Total RNA isolation*

One ml of Trizol reagent (Invitrogen) were mixed with each PBMC pellets and incubated for 5 min at room temperature. Two hundred µl of chloroform were added to each sample and mixed well. The tubes were centrifuged at maximum speed for 15 min at 4°C. Supernatants were carefully transferred to Eppendorf tubes, and 500 µl of 2-propanol was added to each tube and mixed well. The samples were centrifuged at maximum speed for 10 min at 4°C. One volume (1000 µl) of 75% of ET-OH was added after the supernatants were decanted. The tubes were vortexed and centrifuged at maximum speed for 10 min at 4°C. The supernatant was decanted. Then the tubes were vacuumed dry for 5-10 min to get rid of ethanol. Thirty-two µl of RNAase free water was added to elute total RNA with incubation at heat block 65° C for 10 min. The total RNA concentration was measured by Nanodrop Lite Spectrophotometer (Thermo Scientific).

### *2.3.2 cDNA synthesis*

The total RNA was used as a template to produces complementary DNA (cDNA) with the use of Prime Script Reverse Transcript (RT) Takara kits (TAKARA Bio.INC, Japan). Two µg of RNA were mixed with 8 µl of 1.5 x prime scripts buffer, 2 µl of oligoEnzyme, 2 µl of oligo dt primer and 2 µl of random 6 mers, and RNAase free DW were added to 40 µl final volume.

PCR conditions: the samples were incubated at 37°C for 15 min then 85° C for 5 sec.

### *2.3.3 Reverse Transcription (RT)-PCR*

RT-PCR was done using P4 and C cDNA and *XIAP* primers RTF/RTR (exons 2-7) or RT2F/RTR (exons 4-7). GAPDH cDNA was amplified with GAPDHF/GAPDHR primers to study the quality and estimate the amount of cDNA (Table 3). PCR conditions: denaturation at 94° C for 30 sec, annealing at 58 °C for 30 sec, extension time at 72° C for 1 min and 30 sec.

**Table 3.** Sequence of RT- PCR primers for amplifying *XIAP* gene

| **Name** | **Forward primers from 5' to 3'** | **Reverse primers from 5' to 3'** |
|---|---|---|
| RT- FL | CGAAAGGTGGACAAGTCCTAT | CGAAAGGTGGACAAGTCCTAT |
| RT2F | GCTCACCTAACCCCAAGAGAG | |
| RT3F | GCTCACCTAACCCCAAGAGAG | |
| GAPDH | GTCTTCACCACCATGGAGAAGGCT | CATGCCAGTGAGCTTCCCGTTCA |

### *2.3.4 TOPO-TA Cloning*

Repetitive RT-PCRs were done to amplify full-length *XIAP* in P4's cDNA. PCR products were collected for TOPO-TA cloning. For preparation of TOPO-TA cloning reaction using TOPO cloning kit (PCR®II-TOPO®, Invitrogen), 3 µl of PCR product, 1 µl salt solution and 1 µl of TOPO vector (Figure 3) were mixed gently, incubated for 5 min at room temperature, and 2 µl was used for one shot chemical transformation into competent cells (Top10F') (Invitrogen) according to the company's instructions. Then the samples were cultured on LB agar plates with kanamycin. After overnight incubation at 37°, each colony was examined by colony PCR using M13R and T7 (TOPO vector Primers) or *XIAP* full length RT-PCR specific primers. When the correct size was detected, we started overnight culturing the clones in LB

media with kanamycin antibiotic. QIAprep Spin Mini-prep Kit® (QIAGEN, Germantown, MD) was used for plasmids purification from the competent cells. Sequence analysis was requested using M13R and T7 primers.

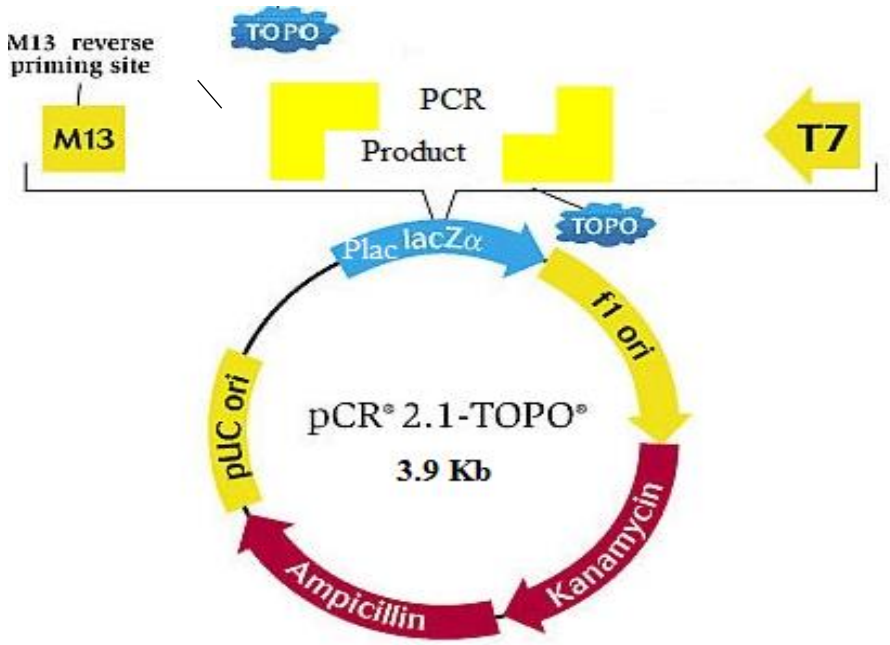


**Figure 3.** PCR2.1-TOPO vector

**Vector primers design**

| | **Primer sequence** |
|---|---|
| M13R | TAAAACGACGGCCAG |
| T7 | TAATACGACTCACTATAGGG |

***2.3.5 DNA extraction***

DNA was extracted from granulocytes, which were obtained after isolation of PBMC using a density gradient centrifugation method. We added one volume of 1x PBS and natural

cellulose buffers to the pellets and waited for 30 min at room temperature. The supernatants were saved to new 15 ml capped tubes, and centrifuge at 2000 rpm for 5 min at 4°C. RBCs were lysed by adding equivalent amount of DDW and 1.8% of NaCl solution. Then the samples were centrifuged at 2000 g for 5 min at 4°C. The pellets after hemolysis were obtained for DNA extract using SepaGene® extraction kits (Eidia, Tokyo, Japan) according to the company's instructions. Genomic DNA was amplified by PCR using synthetic oligonucleotide primers designed to cover coding and non-coding exons of *XIAP* gene (Table 4).

**Table 4.** Sequence of PCR primers covering *XIAP* exons

| Exon | Forward primers from 5' to 3' | Reverse primers from 5' to 3' |
|---|---|---|
| 401 ex1 | GCTAGGTCAGCTTCTCGGTTC | AGAAACCCGGAGTCGTGAAA |
| 167 ex1 | ACACTTCGGGTTTCACGACT | GAAGTGGAGGGGAAAAGAAGA |
| Ex2a | GAATGTTTCTAGCGGTCGTG | TTCCTCGGGTATATGGTGTCTG |
| Ex2b | TGCCACGCAGTCTACAAATTC | GGGGCTAAGGGCATCATTTAC |
| Ex3 | GATGTGAATTTGAATGTCTT | GCCAAGATTGCACCACTGCA |
| Ex4 | GACAGTGGGATAGGGAATTG | CATCTTTAAAGCCCATCATAC |
| Ex5 | GAAGGGATTAGATTAGATAATC | CAGGAGTTTGAGACCAGCCTGG |
| Ex6 | CTTCCCAAAGCAGCTTTGCTTTGC | CTTGCTCCATCTTGTCCCATCC |

401 ex1 and 167 ex1: Non-coding exons 1 of *XIAP* transcriptional variants, NM_001204401.1 and NM_001167.3, respectively

### *2.3.6 PCR amplification for determining deletion breakpoints in Patient 4*

To narrow down the deletion breakpoints, P4's and C's DNA was amplified by PCR using primers as shown in Table 5. PCR condition; denaturation at 94° C for 30 sec, annealing at

58° C for 30 sec, extension time at 72° C for 1 min. The PCR products were run in 1% gel electrophoresis in submarine electrophoresis system (Mupid-2 plus, ADVANCE) after mixing with loading buffer (TAKARA, Japan) and direct Midori Green (Nippon Genetics). FAS-Digi apparatus with digital Cam (PENTEX) were used for DNA detection while 1kb and 100 bp DNA marker were used to determine the correct band.

**Table 5.** PCR primers for determining deletion breakpoints

| No | Forward primers from 5' to 3' | No | Reverse primers from 5'to 3' |
|---|---|---|---|
| F1 | GTCTCGATCTCCTGACCTCGT | R1 | TTCATCTCCATGCTCTGAA |
| F2 | ATCCAGGGTATGACCAGCATT | R2 | GCACAAGGACAGAAAGAGGA |
| F3 | ACACTTCGGGTTTCACGACT | R3 | ATTGTGTGGGAAGGTGTGAA |
| F4 | GTCTCGATCTCCTGACCTCGT | R4 | GATTACAGACATGAGCCACAGC |
| F5 | GCTGAACGCAACATTCAAC | R5 | AGTTGGAATCATCCAATGCAC |
| F6 | CGTTGGGTACCACAGTACAGG | R6 | TGGGTGACACAGCAAGACAAT |
| F7 | GTCTTGCTCCTGACCTCATGT | R7 | CTCACACTTGTAATCCCAGCA |
| BPF | CAAGAAAACAACGGTGCTTAAA | BPR | GGGAGGCTGAGTAGCTTGAAC |

BPF and BPR; Forward and reverse primers to determine the deletion breakpoints respectively

### *2.3.5 Sequence analysis and nucleotide database*

We obtained sequence of *XIAP* gene through UCSC, https://genome.ucsc.edu/index.html and Ensembl database (http//www.ensemb1.org/). The reported mutations of *XIAP* gene were checked at (http://www.ncbi.nlm.nih.gov/). Each purified bands from gel electrophoresis for *XIAP* exons were asked for sequencing at FASMAC, Japan (http://www.fasmac.co.jp/)

# 3. Results

### 3.1 XIAP expression in T cell blasts was absent in all of the four patients with XIAP deficiency

XIAP expression was firstly studied in PBMC isolated from the four patients. Although it seems to be reduced in Patients 1-4, multiple bands obscured specific XIAP expression. In contrast, Western blot analysis in T cell blasts demonstrated a single band in controls and completely absent XIAP expression in all of the four patients (Figure 4).

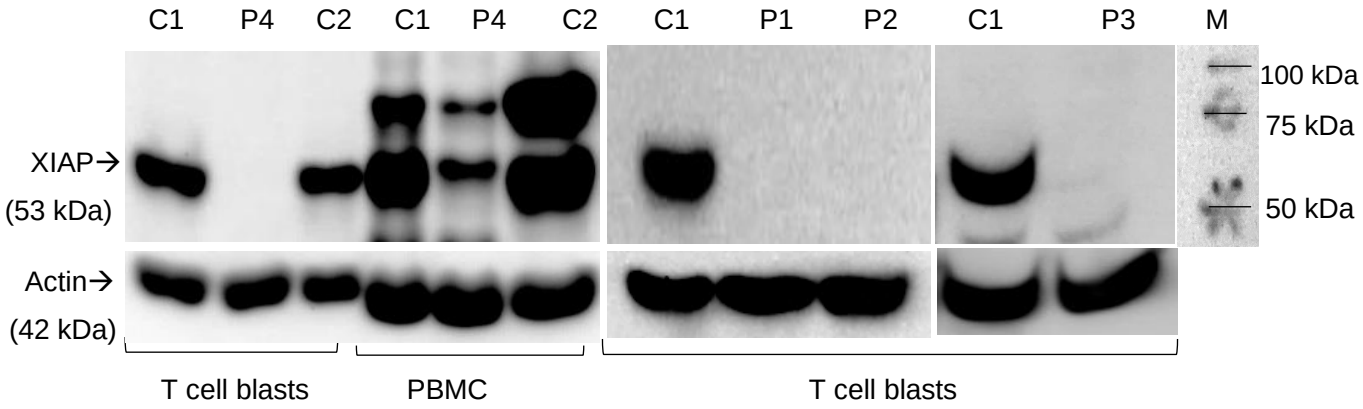


**Figure 4**. Western blot analysis of XIAP expression in T cell blasts from four patients with XIAP deficiency and in PBMC from Patient 4 is shown.

P1, Patient 1; P2, Patient 2; P3, Patient 3; P4, Patient 4; C1, Control 1; C2, Control 2, M, Marker (after long time exposure).

### 3.2 Sequence analysis demonstrated distinct XIAP mutations in Patients 1-3 but not in Patient 4

Sequence analysis of each coding exon and exon-intron boundary of the responsible gene, *XIAP*, was performed based on the absent XIAP expression in T-cell blasts. This study demonstrated two novel nonsense mutations of c.340C>T, p.Gln114X in Patient 1 and c.73G>T, p.Glu25X in Patient 3, and a previously reported nonsense mutation of c.1141C>T, p.Arg381X in Patient 2 (Speckman et al., 2013) (Figure 5). However, Patient 4 had no mutations detected despite the absent XIAP expression. Based on these results, Patient 4 was indicated to have a mutation outside of coding exons or exon-intron boundaries.

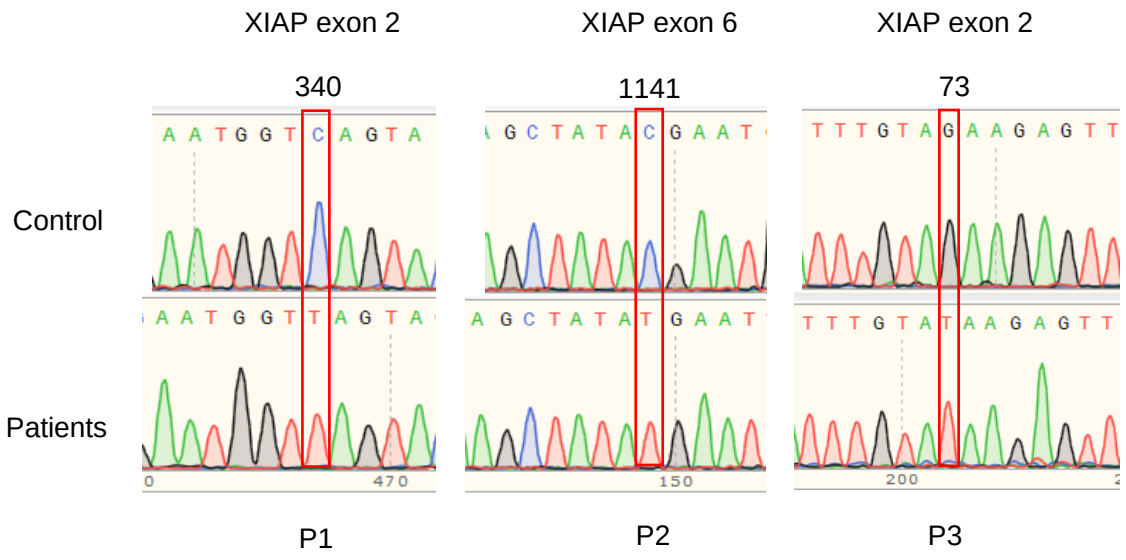


**Figure 5**. Sequence analysis of *XIAP* in Patients 1-3 is shown. P1, Patient 1; P2, Patient 2; P3, Patient 3.

### 3.3 XIAP RT-PCR products were faint but had wild-type coding sequences in Patient 4

Gel electrophoresis of RT-PCR products showed a faint band with primers amplifying coding cDNA from exons 2 to 7 of *XIAP* in Patient 4 (Figure 6). Sequence analysis of the TOPO-TA clones from the band demonstrated wild-type sequences, indicating no splicing defects. Based on this result, we proceeded to study non-coding exon 1 of *XIAP* at DNA levels.

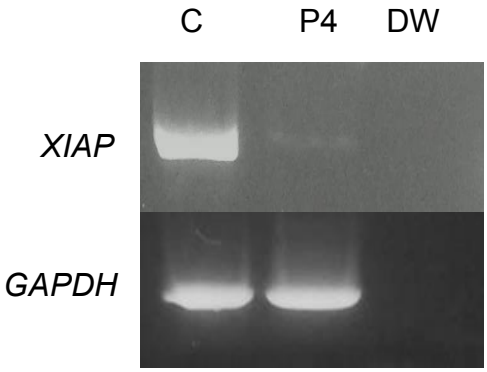


**Figure 6.** Agarose gel electrophoresis of *XIAP* and *GAPDH* RT-PCR in Patient 4 is shown

### 3.4 Deletion encompasses non-coding exon 1 of XIAP gene in Patient 4

There are two transcriptional variants of *XIAP* gene, NM_001204401.1 and NM_001167.3, and the only difference of them is the position of non-coding exon 1 (http://ensembl.org/). Gel electrophoresis of PCR products with primers of 401ex1F/401ex1R and 167ex1F/167ex1R amplifying exon 1 of NM_001204401.1 and NM_001167.3 respectively showed no amplification, indicating Patient 4 has a deletion encompassing non-coding exon 1 from both of transcriptional variants (Figure 7A).

### 3.5 The deletion is 2199 bp long and is encompassing exon 1 from the two transcriptional variants of NM_001204401.1 and NM_001167.3

Since Patient 4 was shown to have deletion encompassing non-coding exon 1 of both transcriptional variants of NM_001204401.1 and NM_001167.3 in *XIAP*, we further narrowed down the deletion breakpoints of *XIAP* with PCR-based studies as described previously (Yamada et al., 2010). The 5'and 3' deletion breakpoints were determined by the following 3 steps based on PCR as illustrated in Figure 7B. The 1st step was to study the presence/absence of the adjacent detected/undetected regions on each end of the deletion with PCR using a primer pair of F1-R1 and F2-R2, respectively. The 2nd step was to study the presence/absence of sequences between these adjacent detected/undetected regions on each end using F3-R3 primers to narrow down the extent of the deletions. Based on this result, subsequent primers (F4-R4, F5-R5, etc.) were designed to further narrow down the breakpoints. The 3rd step was to directly sequence the PCR products amplified with a pair of 5' forward (BPF) and 3' reverse (BPR) primers, and we finally amplified PCR products spanning the deleted regions and determined the deletion breakpoints (Figure 7C).

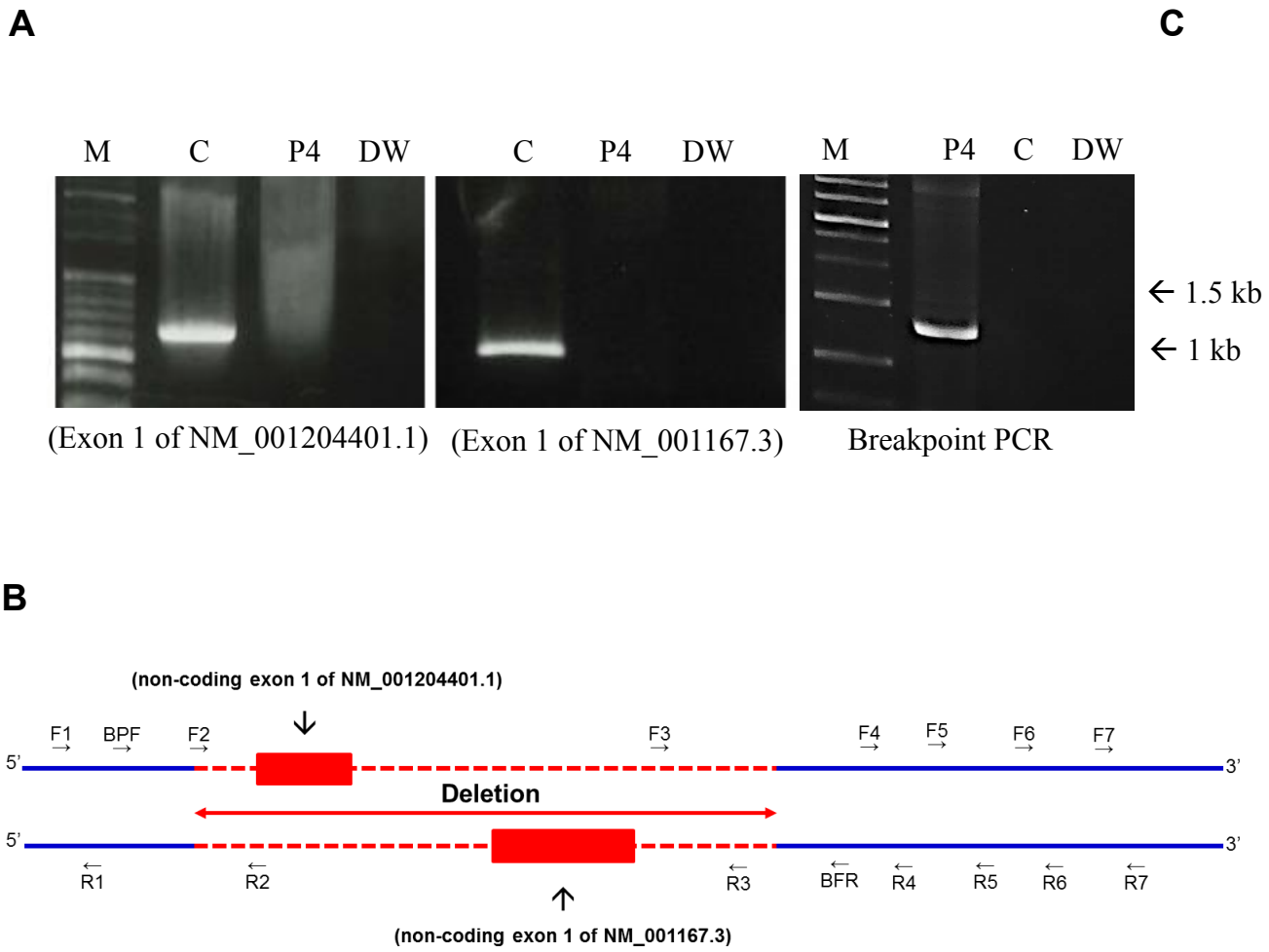


**Figure 7.**

**A.** Agarose gel electrophoresis of PCR amplifying *XIAP* non-coding exon 1 of NM_001204401.1 and NM_001167.3 in Patient 4 is shown. P4, Patient 4; C, Control; M, Marker.

**B.** Schematic representation of PCR-based determination of the deletion break- points of *XIAP* in Patient 4. The horizontal solid/dotted lines indicate the present/absent genomic regions. F: forward primer, R: reverse primer.

**C.** Agarose gel electrophoresis of *XIAP* breakpoint PCR is shown.

Sequence analysis of the PCR products demonstrated the breakpoints of the deletion are chrX: 123859525 and chrX: 123861724 in UCSC genome browser (GRch38/hg38 Assembly 2013 for chrX) (https://genome.ucsc.edu/index.html) (Figure 8A, B). The deletion is 2,199 bp long and is encompassing exon 1 from the two transcript variants of NM_001204401.1 and NM_001167.3. Patient 4's mother was shown to be an asymptomatic heterozygous carrier of the deletion while his brother did not have this deletion (Figure 8A).

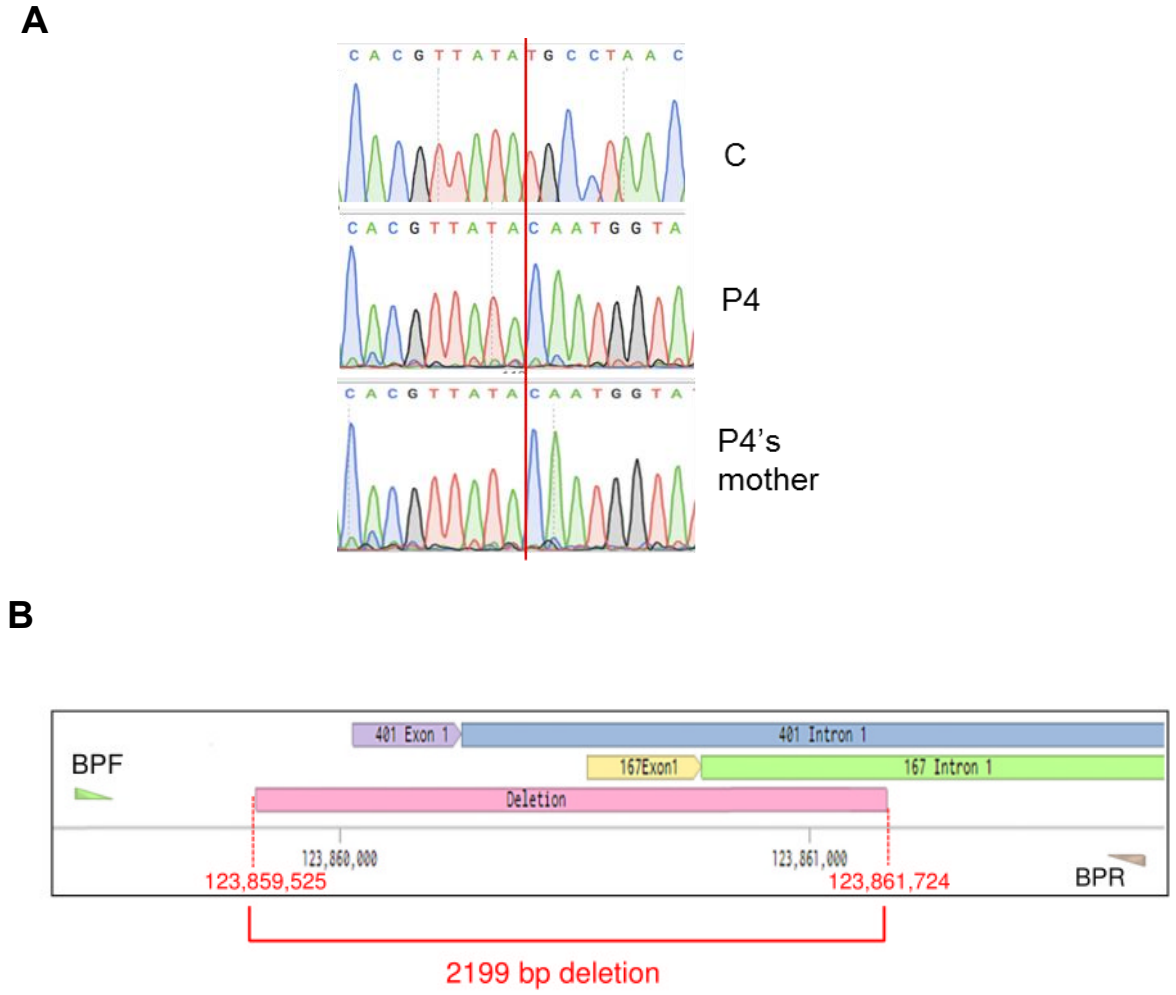


**Figure 8.**

**A.** Sequence analysis of the breakpoints of the deletion in Patient 4 (P4) is shown. The red bar indicated the deletion breakpoints.

**B.** Schematic representation of non-coding exon 1 from the two transcriptional variants of *XIAP*, NM_001204401.1 and NM_001167.3, and the deletion breakpoints in P4 are shown.

### 3.6 Endoscopic findings in these four patients shared multiple wide and longitudinal ulcers with" scooped-out appearance" in the colon

Endoscopic and histopathological findings in each patient were shown in Table 6 and Figure 9.

**Patient 1:** Initial esophagogastroduodenoscopy (EGD) and colonoscopy during the onset of IBD at the age of 11 years showed duodenal ulcers and skip lesions of multiple ulcers from the terminal ileum to the entire colon associated with perianal abscess. Histopathological study showed epithelioid granulomas and active chronic colitis. Repeated colonoscopy performed during exacerbation of IBD at the age of 15 years demonstrated multiple wide and longitudinal ulcers with straight and non-raised edge which we named "scooped-out appearance".

**Patient 2:** Initial EGD and colonoscopy at the age of 8 years demonstrated gastric ulcers, anal fistula, and multiple wide and longitudinal ulcers in with scooped-out appearance in the distal colon. Histopathologically, there was moderate to severe interstitial mononuclear cell infiltration associated with cryptitis and crypt abscesses, although there were no epithelioid granulomas.

**Patient 3:** Initial EGD and colonoscopy at the age of 11 demonstrated multiple ulcers from the end of the ileum to the entire colon in addition to multiple gastroduodenal ulcers. Colonoscopy performed during exacerbation of IBD at the age of 14 years demonstrated multiple wide and longitudinal ulcers in the distal colon. Histopathologically, there was moderate to severe interstitial mononuclear cell infiltration associated with cryptitis and crypt abscesses, although there were no epithelioid granulomas.

**Patient 4:** Colonoscopy at the age of 9 years demonstrated multiple wide and longitudinal ulcers with scooped-out appearance in the colon and perianal abscess. Histopathologically, there were epithelioid granulomas and moderate to severe mononuclear cell infiltration associated with moderate neutrophilic cryptitis and spotty crypt abscess.

All of the four patients shared wide and longitudinal ulcers with straight and non-raised edge, and ileocolonic and perianal disease. In Paris classification, it is L3 and p (Levine et al., 2011). We retrospectively evaluated endoscopic findings in 127 patients with pediatric-onset conventional CD, but none of them showed the scooped-out appearance. Histopathologically, all of the four patients with XIAP deficiency were revealed to have severe mononuclear cell infiltration and moderate to severe neutrophil cryptitis often with crypt abscess. Mildly increased apoptosis was observed in all of the patients except Patient 3, and epithelioid granulomas were additionally observed in two of the four patients as shown in Table 7, and Figure 10.

**Table 6.** Endoscopic findings of the four patients with XIAP deficiency

**-Macroscopic findings**

| **Patient** | **1** | 2 | 3 | 4 |
|---|---|---|---|---|
| Diagnosis of IBD | CD | CD | CD | CD |
| IBD localization | Colon, distal ileum, duodenum | Colon, distal ileum, stomach, duodenum | Colon, distal ileum, stomach, duodenum | Colon |
| Esophagogastroduodenoscopy | Duodenal ulcers | Gastroduodenal ulcers | Multiple gastroduodenal ulcers | (-) |
| Colonoscopic findings of wide and longitudinal ulcers with scooped-out appearance (age) | (+) (15 y) | (+) (8y) | (+) (14y) | (+) (8y) |
| Paris classification | A1b, L3, L4a, B1, p, G0 | A1a, L3, L4a, B1, p, G0 | A1b, L3, L4a, B1, p, G1 | A1a, L3, L, B1, p, G0 |

**-Histopathological findings**

| **Patient** | **1** | **2** | **3** | **4** |
|---|---|---|---|---|
| Diagnosis of IBD | CD | CD | CD | CD |
| Epithelioid granuloma | (+) | (-) | (-) | (+) |
| Interstitial plasmacytic infiltration | Severe | Moderate～severe | Moderate～severe | Moderate～severe |
| Eosinophilic infiltration | Mild | Mild | Mild | Mild |
| Intracryptal lymphocytic infiltration | (+) | (-) | (-) | (-) |
| Neutrophilic cryptitis | (+) | Moderate～severe | (-) | Moderate |
| Neutrophilic crypt abscess | Mild | Severe | (-) | Mild |
| Basal plasmacytosis | Moderate | Mild | Mild | Mild |
| Flattening of villi of the ileum end | Severe | Mild | Mild | (-) |

CD, Crohn's disease; Paris classification: A1a and A1b mean age at diagnosis of CD <10y and 10-<17y, respectively. L3: ileocolonic location, B1: nonstricturing and nonpenetrating, p: perianal disease modifier, G0 and G1 mean no evidence of growth delay and growth delay, respectively; +, yes or positive; ¬, no or negative; y, years

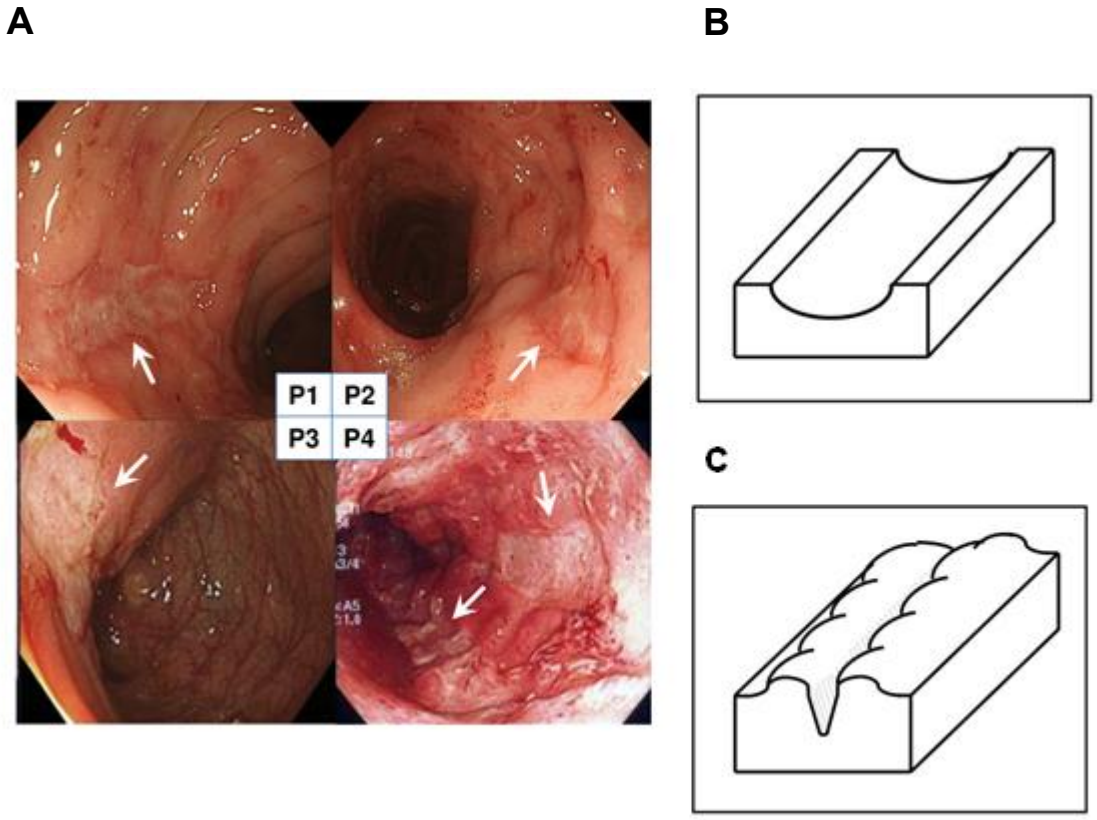


**Figure 9.** The four patients with XIAP deficiency shared the endoscopic findings of multiple wide and longitudinal ulcers with scooped-out appearance in the colon.

P1, Patient 1; P2, Patient 2; P3, Patient 3; P4, Patient 4.

**A.** Endoscopic pictures of P1, Patient 1; P2, Patient 2; P3, Patient 3; P4, Patient 4

**B.** Schematic representation of the endoscopic findings in the four patients with XIAP deficiency: wide and longitudinal ulcers with straight and non-raised edge, which we named scooped-out appearance

**C.** Schematic representation of the endoscopic findings observed in most cases of CD: narrow and longitudinal ulcers with irregular and raised edge

**Table 7**. Grading of histopathological findings in our patients with XIAP deficiency

| Patient | Previous diagnosis | Affected site or IBD site | Active inflammation | Eosinophilic infiltration | Apoptosis | Cryptitis | Crypt abscess | Basal plasmacytosis | Villous flattening | Granuloma |
|---|---|---|---|---|---|---|---|---|---|---|
| P1 | CD | Duodenum | 1 | 0 | 1 | 0 | 0 | 0 | 1 | 0 |
| | | Distal ileum | 3 | 0 | 0 | 1 | 0 | 3 | 3 | 1 |
| | | Sigmoid colon | 2 | 1 | 0 | 1 | 0 | 2 | | 0 |
| P2 | CD | Distal ileum | 2 | 1 | 0 | 0 | 0 | 1 | 1 | 0 |
| | | Cecum | 2 | 0 | 1 | 3 | 3 | 0 | | 0 |
| | | Ascending colon | 3 | 0 | 1 | 3 | 1 | 1 | | 0 |
| | | Sigmoid colon | 3 | 1 | 1 | 3 | 2 | 2 | | 0 |
| | | Rectum | 3 | 0 | 1 | 3 | 2 | 1 | | 0 |
| P3 | CD | Esophagus | 1 | 1 | | | | | | |
| | | Stomach | 2 | 0 | 0 | 1 | 0 | 1 | 0 | 0 |
| | | Duodenum | 3 | 1 | 0 | 1 | 0 | 2 | 2 | 0 |
| | | Ileum | 2 | 1 | 0 | 1 | 0 | 1 | 1 | 0 |
| | | Transverse colon | 3 | 0 | 0 | 0 | 0 | 0 | | 0 |
| P4 | CD | Descending colon | 3 | 1 | 1 | 2 | 1 | 1 | | 1 |
| | | Sigmoid colon | 2 | 1 | 0 | 2 | 0 | 0 | | 0 |

P1, Patient 1; P2, Patient 2; P3, Patient 3; P4, Patient 4; 0, no or absent; 1, mild; 2, moderate; 3, severe

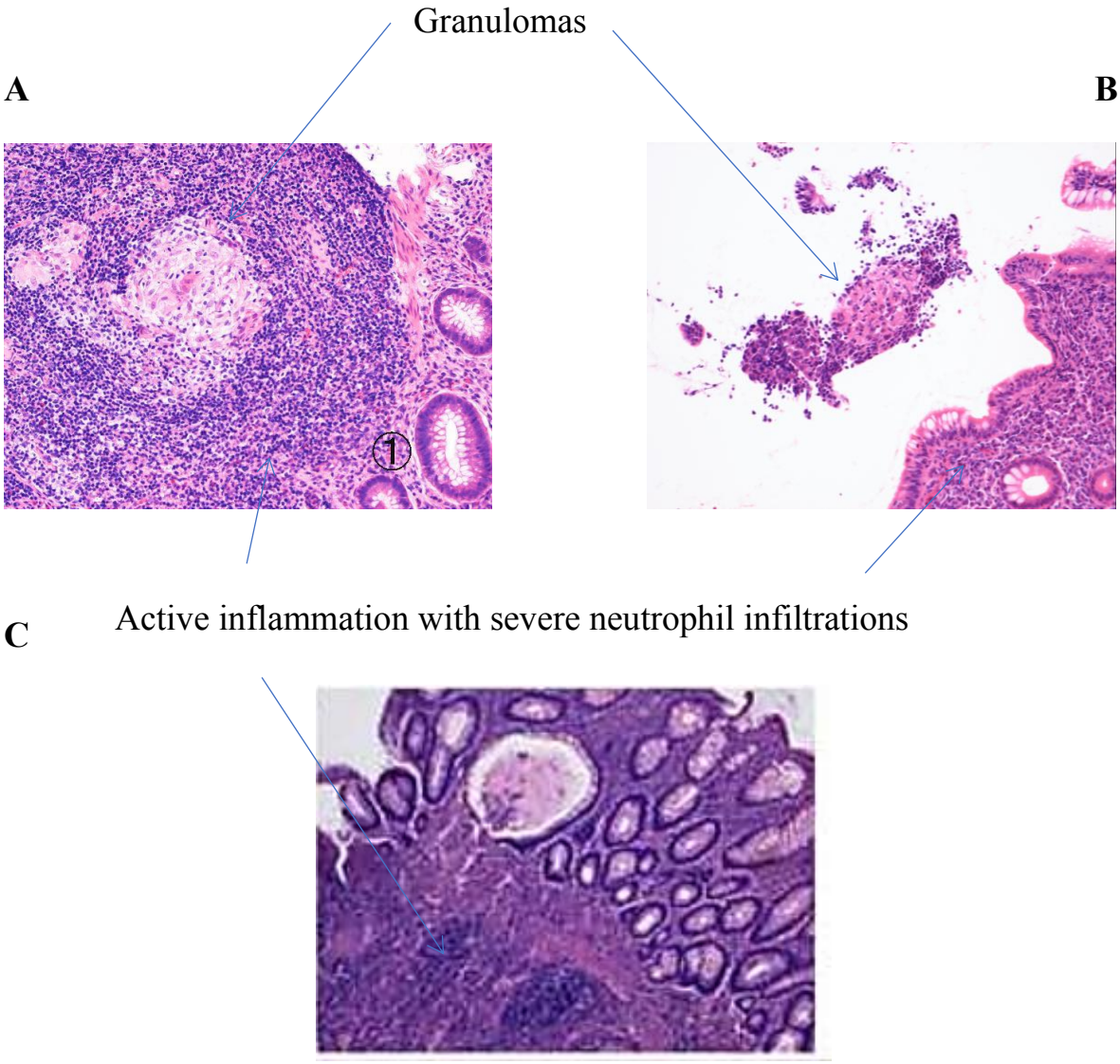


**Figure 10.** **A, B, & C**, Histopathological findings in colonic tissues in our patients with XIAP deficiency (hematoxylin and eosin stain [HES] x 200), Patient 4, Patient 1, and Patient 3 respectively.

# 4. Discussion

## 4.1 Summary of this study

Four unrelated Japanese patients were diagnosed with XIAP deficiency who had presented with refractory IBD and recurrent HLH for 3-10 years. Based on the absent XIAP expression in T-cell blasts from these patients, we studied the responsible gene, *XIAP*, and identified four distinct mutations: a previously reported nonsense mutation of c.1 141C>T, p.Arg381X and two novel nonsense mutations of c.340C>T, p.Gln114X and c.73G>T, p.Glu25X, and additionally a novel deletion mutation encompassing non-coding exon 1 (5'UTR) of *XIAP*. They all showed endoscopic findings of multiple wide and longitudinal ulcers with scooped-out appearance in the colon.

## 4.2 Diagnosis of XIAP deficiency based on T cell blast studies

Panel sequence analysis and whole exome sequence analysis (WES) are widely used to detect monogenic IBD. Crowley et al. recently reported 40 rare variants in 21 genes including 5 variants in *XIAP* gene were associated with IBD among 31 of 1005 children, which occurred in 7.8% of VEO-IBD and 2.3% of later pediatric-onset IBD (Crowley et al., 2020). However, the proportion of monogenic IBD in VEO-IBD varies between centers and cohorts and ranges from 5-31% (Pazmandi and Kalinichenko, 2019), and most of them lacked functional and protein expression studies. One of the concerns to identify genetic causes accurately is whether some disease-causing mutations located deep within introns or UTR were overlooked in some cases, since detection and validation of these mutations are challenging. The deletion mutation encompassing non-coding exon 1 (5'UTR) of *XIAP* observed in Patient 4 is one of the cases unidentified by panel sequence analysis or WES focusing only on coding exons and exon-intron boundaries. In Patient 4 with 5'UTR deletion mutation, absent XIAP expression in Western blot analysis of T-cell blasts led to the diagnosis of XIAP deficiency. Therefore, this analysis should be considered as one of the first screening methods for early and accurate diagnosis of this disease. Since T-cell blasts can be easily obtained from small amount regardless of the conditions of blood and patients.

## 4.3 Deletion of 5'UTR

To the best of our knowledge, there have been no reports of a deletion mutation affecting only non-coding exon 1 (5'UTR) of *XIAP*, while gross deletion mutations encompassing coding exons of 1-2, 1-4, 1-6, and 4-6 have been reported (Kelsen et al., 2015).

Electrophoresis of RT-PCR products in Patient 4 showed a faint but detectable band in contrast with complete absence of XIAP expression at protein levels (Figure 4, 5). We recently collaborated with a French group to determine 2 additional patients with XIAP deficiency who had 5'UTR deletion in *XIAP* gene. All of the deletions in 3 patients shared a common region of 839 bp which contains an active promoter determined by gene reporter expression assays in HEK cell lines and CRISPR-Cas9 genome editing in primary T cells (in press). And about translation, there are some previous findings that XIAP mRNA is controlled at the translational level, specifically through an internal ribosome-entry site (IRES) residing at 5'UTR (Riley et al., 2010). Therefore, complete absence of XIAP expression at protein levels in Patient 4 could be attributable to abrogated translation in addition to impaired transcription or stability of *XIAP* mRNA due to the deletion of 5'UTR.

### 4.4 Correlation of genotype and XIAP protein expression with IBD phenotype

So far only Speckman et al. reported neither genotype nor XIAP protein expression was clearly correlated with clinical phenotype in 17 patients with XIAP deficiency. However, it is of note that whereas patients with HLH had variable XIAP expression from reduced to normal, all 4 patients with IBD had reduced or deficient XIAP expression, indicating a possible correlation of genotype and XIAP protein expression with IBD phenotype (Speckman et al., 2013). In this study, our patients with completely absent expression of XIAP developed refractory IBD, supporting this possibility. Further studies are necessary to determine the molecular contribution of XIAP to the IBD phenotype.

### 4.5 Endoscopic findings and possible mechanisms causing IBD in XIAP deficiency

The onset of IBD in XIAP deficiency is often during adolescence or even in adulthood (Speckman et al., 2013; Aguilar et al., 2014), however in our four patients with the onset of IBD older than 8 years of age. Therefore, we encourage considering XIAP deficiency in any male patients with pediatric-onset refractory CD, especially those associated with HLH flairs. One of the characteristic findings in XIAP deficiency is refractory IBD associated with intractable anal fistula due to transmural inflammation (Nameirakpam et al., 2020; Worthey et al., 2013) which was observed in all of the four patients at the time of diagnosis or during relapse of IBD (Table 2). XIAP protein is associated with proinflammatory response via the NOD signaling pathway and plays a crucial role in regulating apoptosis (Krieg et al., 2009) IBD phenotype in XIAP deficiency is hypothesized to be caused by impaired NOD2 signaling resulting in granulomatous colitis and perianal disease mimicking CD (Aguilar et

al., 2014; Pachlopnik Schmid et al., 2011) However, it is not easy to differentiate XIAP deficiency from CD based on endoscopic findings. Therefore, one of the challenges is to differentiate XIAP deficiency from conventional CD which would facilitate early HSCT to avoid life-threatening events like HLH and the occurrence of refractory IBD. The endoscopic findings in patients with XIAP deficiency are poorly understood as well. Based on our diagnosis of this disease, we retrospectively evaluated endoscopic findings of the four patients with XIAP deficiency and those of 127 patients with pediatric-onset conventional CD including 58 patients previously reported (Konno et al., 2015). And we detected an endoscopic finding exclusively observed in our patients with XIAP deficiency: multiple wide and longitudinal ulcers with straight and non-raised edge. We named "scooped-out appearance", since the ulcer bed looked like a track scooped out by a spoon (Figure 9A, B). Although multiple longitudinal ulcers are also observed in conventional CD, their ulcers are mostly narrow and sharp, and their ulcer edges are irregular shaped and slightly raised (Lee and Lee, 2016) as represented by the schema shown in Figure 9C. Additionally, discrete ulcers with non-raised, non-edematous edge and normal-appearing surrounding mucosa are observed in intestinal Behcet disease but are distinct from longitudinal ulcers observed in our patients with XIAP deficiency. This endoscopic finding has not been reported from elsewhere, but needs to be reproduced with more patients because of the limited patients in this study. Histopathological findings of mononuclear cell infiltration and neutrophil cryptitis often with crypt abscess observed in our patients indicated severe active inflammation (Table 7)**,** which might be one of the contributing factors to the formation of wide and longitudinal ulcers with scooped-out appearance.

### 4.6 Treatment, prognosis and out come

Although some patients with XIAP deficiency were alive and well under minimal supportive treatment and reached adulthood beyond their fourth decade (Speckmann et al., 2013), this disease is associated with a lethal outcome in more than 20% of cases (Aguilar et al., 2014). HSCT is the only curative therapy and is recently performed especially required in patients with refractory IBD or HLH with improved survival (Ono et al., 2017; Marsh et al., 2013). All of our patients underwent allogeneic HSCT, which led to a complete remission of IBD in P1, P2, and P3 while P4 showed partial remission of IBD due to mixed chimeric state (Ono et al., 2021).

# 5. Conclusion

Four patients were diagnosed with XIAP deficiency who had presented for 3-10 years with refractory IBD-like features mimicking CD. We report three distinct novel mutations in *XIAP* gene including one in XIAP 5'UTR. Collectively, panel sequence analysis of sequence analysis including *XIAP* and XIAP expression in T-cell blasts should be performed for the early and accurate diagnosis of XIAP deficiency especially in patients with refractory IBD with HLH, and splenomegaly. Endoscopic findings of multiple wide and longitudinal ulcers with scooped-out appearance could also a clue to the diagnosis of XIAP deficiency. Further studies including more patients with XIAP deficiency are necessary to determine whether this endoscopic finding is specific to XIAP deficiency.

# Acknowledgements

After God Almighty to whom I'm indebted with everything in my life; I'd like to sincerely extend my gratitude and utmost respect to **Prof. Atsushi Manabe,** the chief of Pediatrics Department, Faculty of Medicine and Graduate School of Medicine, Hokkaido University for his dedicated supervision, expert advice, incredible scientific knowledge, kindness, and encouragement during my research.

Extending my deepest gratitude to my instructor **Prof. Masafumi Yamada**, Department of Pediatrics, Faculty of Medicine and Graduate School of Medicine, Hokkaido University, for his valuable advice, great contributions in teaching that helped me to grow as a researcher and I came to know many techniques and skills, research plan designing, guidance in writing papers, incredible scientific knowledge, patience, and great efforts to finish this work. I'm feeling lucky to be one of this team.

I'd like to thank **Prof. Tadashi Ariga** and **Dr. Yusuke Tozawa**, Department of Pediatrics, Graduate School of Medicine, Hokkaido University; **Prof. Mutsuko Konno**, **Drs. Nariaki Toita, Michiko Takahashi,** and **Shin-ichi Fujiwara**, Department of Pediatrics, Sapporo Kosei General Hospital; **Dr. Shin Ishihara**, Department of Surgical Pathology, Sapporo Kosei General Hospital; **Prof. Osamu Ohara**, Department of Applied Genomics, Kazusa DNA Research Institute; **Dr. Toshifumi Ashida**, IBD center, Sapporo Higashi Tokushukai Hospital for their great contribution to this work.

Special thanks to our kind and helpful secretaries for their great help during my study and to Department of Pediatrics, Hokkaido University hospital, all medical staffs as well as patients, and their families for their cooperation in this study.

Deep thanks to **Hokkaido University** for their support with tuition fee exemption which helped me to continue my study as a self-supported student, I really appreciate their role.

Great gratitude to **the soul of my father**, I know he is now happy with me for achieving a lot of his dreams. Deep and warm thanks to my lovely family in Egypt**, my mother and my sisters** for their encouragement and support since I have been abroad.

Last but not least to my children **Login, Ahmed, Lena, and little Hana** for studying with me and disturbing me all the time (honestly, they are bearing a lot), and my beloved husband, **Dr. Mohamed Shehata** for his encouragement, advice, taking care of our children during my urgent lab work in weekend or holidays, and late night, providing me the best atmosphere to learn, provide me his own blood samples during practice and my studies.

Thanks to you all……

*Shimaa Abdrabou*

# Disclosure of Conflict of Interest

The author has no potential or financial conflicts of interest to disclose.

# References


Aguilar, C., Lenoir, C., Lambert, N., Begue, B., Brousse, N., Canioni, D., Berrebi, D., Roy, M., Gerart, S., Chapel, H., *et al.* (2014). Characterization of Crohn disease in X-linked inhibitor of apoptosis-deficient male patients and female symptomatic carriers. J. Allergy Clin. Immunol. *134*, 1131-1141 e1139.

Crowley, E., Warner, N., Pan, J., Khalouei, S., Elkadri, A., Fiedler, K., Foong, J., Turinsky, A.L., Bronte-Tinkew, D., Zhang, S., *et al.* (2020). Prevalence and Clinical Features of Inflammatory Bowel Diseases Associated With Monogenic Variants, Identified by Whole-Exome Sequencing in 1000 Children at a Single Center. Gastroenterology *158*, 2208-2220.

Eckelman, B.P., Salvesen, G.S., and Scott, F.L. (2006). Human inhibitor of apoptosis proteins: why XIAP is the black sheep of the family. EMBO Reports *7*, 988-994.

Hans, D. O., Smith, C. I., and Jennifer, M. P. (2015). Primary-Immunodeficiency-Diseases_-A-Molecular-and-Genetic-Approach-Oxford-University. Oxford University Press, 930.

Hendrickson, B.A., Gokhale, R., and Cho, J.H. (2002). Clinical Aspects and Pathophysiology of Inflammatory Bowel Disease. Clin. Microbiol. Rev. *15*, 79-94.

Kelsen, J.R., Dawany, N., Martinez, A., Grochowski, C.M., Maurer, K., Rappaport, E., Piccoli, D.A., Baldassano, R.N., Mamula, P., Sullivan, K.E., *et al.* (2015). Erratum to: A de novo whole gene deletion of XIAP detected by exome sequencing analysis in very early onset inflammatory bowel disease: a case report. BMC. gastroenterology *15*, 179.

Konno, M., Takahashi, M., Toita, N., Fujiwara, S., and Nojima, M. (2015). Long-term therapeutic effectiveness of maintenance enteral nutrition for Crohn's disease. Pediatr Int. *57*, 276-280.

Krieg, A., Correa, R.G., Garrison, J.B., Le Negrate, G., Welsh, K., Huang, Z., Knoefel, W.T., and Reed, J.C. (2009). XIAP mediates NOD signaling via interaction with RIP2. Proc. Natl. Acad. Sci. U. S. A. *106*, 14524-14529.

Lee, J.M., and Lee, K.M. (2016). Endoscopic Diagnosis and Differentiation of Inflammatory Bowel Disease. Clin. Endosc. *49*, 370-375.

Levine, A., Griffiths, A., Markowitz, J., Wilson, D.C., Turner, D., Russell, R.K., Fell, J., Ruemmele, F.M., Walters, T., Sherlock, M., *et al.* (2011). Pediatric modification of the Montreal classification for inflammatory bowel disease: the Paris classification. Inflamm. Bowel Dis. *17*, 1314-1321.

Marsh, R. A., Rao, K., Satwani, P., Lehmberg, K., Muller, I., Li, D., Kim, M. O., Fischer, A., Latour, S., Sedlacek, P., *et al*. (2013). Allogeneic hematopoietic cell transplantation for XIAP deficiency: an international survey reveals poor outcomes. Blood *121*, 877-883.

Nameirakpam, J., Rikhi, R., Rawat, S.S., Sharma, J., and Suri, D. (2020). Genetics on early onset inflammatory bowel disease: An update. Genes Dis. *7*, 93-106.

Ono, S., Okano, T., Hoshino, A., Yanagimachi, M., Hamamoto, K., Nakazawa, Y., Imamura, T., Onuma, M., Niizuma, H., Sasahara, Y., *et al.* (2017). Hematopoietic Stem Cell Transplantation for XIAP Deficiency in Japan. J. Clin. Immunol. *37*, 85-91.

Ono, S., Takeshita, K., Kiridoshi, Y., Kato, M., Kamiya, T., Hoshino, A., Yanagimachi, M., Arai, K., Takeuchi, I., Toita, N., et al. (2021). Hematopoietic Cell Transplantation Rescues Inflammatory Bowel Disease and Dysbiosis of Gut Microbiota in XIAP Deficiency. J. Allergy Clin. Immunol. Pract. *10*, 3767-3780.

Pachlopnik Schmid, J., Canioni, D., Moshous, D., Touzot, F., Mahlaoui, N., Hauck, F., Kanegane, H., Lopez-Granados, E., Mejstrikova, E., Pellier, I., *et al.* (2011). Clinical similarities and differences of patients with X-linked lymphoproliferative syndrome type 1 (XLP-1/SAP deficiency) versus type 2 (XLP-2/XIAP deficiency). Blood *117*, 1522-1529.

Pazmandi, J., and Kalinichenko, A. (2019). Early-onset inflammatory bowel disease as a model disease to identify key regulators of immune homeostasis mechanisms. Immunol. Rev. *287*, 162-185.

Ponder, A., and Long, M.D. (2013). A clinical review of recent findings in the epidemiology of inflammatory bowel disease. Clin. Epidemiol. *5*, 237-247.

Rigaud, S., Fondaneche, M.C., Lambert, N., Pasquier, B., Mateo, V., Soulas, P., Galicier, L., Le Deist, F., Rieux-Laucat, F., Revy, P., *et al.* (2006). XIAP deficiency in humans causes an X-linked lymphoproliferative syndrome. Nature *444*, 110-114.

Riley, A., Jordan, L.E., and Holcik, M. (2010). Distinct 5' UTRs regulate XIAP expression under normal growth conditions and during cellular stress. Nucleic Acids Res. *38*, 4665-4674.

Speckmann, C., Lehmberg, K., Albert, M.H., Damgaard, R.B., Fritsch, M., Gyrd-Hansen, M., Rensing-Ehl, A., Vraetz, T., Grimbacher, B., Salzer, U., *et al.* (2013). X-linked inhibitor of apoptosis (XIAP) deficiency: the spectrum of presenting manifestations beyond hemophagocytic lymphohistiocytosis. Clin. Immunol. (Orlando, Fla) *149*, 133-141.

Sylvain, L., and Aguilar, C. (2015). XIAP deficiency syndrome in humans. Semin. Cell Dev. Biol. *39*, 115-23.

Wan-Chen Hsieh, Y.-T.C., Hsuan Chiang, Shu-Ching Hsu, Shi-Chuen Miaw, and Ming-Zong Lai (2014). Inability to resolve specific infection generates innate immunodeficiency syndrome in Xiap-/- mice. Blood *124*, 2847-2857.

Yabal, M., Muller, N., Adler, H., Knies, N., Gross, C.J., Damgaard, R.B., Kanegane, H., Ringelhan, M., Kaufmann, T., Heikenwalder, M., *et al.* (2014). XIAP restricts TNF- and RIP3-dependent cell death and inflammasome activation. Cell reports *7*, 1796-1808.

Yamada M., Arai T., Oishi T., Hatano N., Kobayashi I., Kubota M., Suzuki N., Yoda M., Kawamura N., and Ariga T. (2010). Determination of the deletion breakpoints in two patients with contiguous gene syndrome encompassing CYBB gene. Eur. J. Med. Genet. *53*, 383-8.

Zeissig, Y., Petersen, BS., Milutinovic, S., Esther Bosse, E., Mayr, G., Peuker, K., Hartwig, J., Keller, A., Martina Kohl, M., Laass, M. *et al.* (2015 ). XIAP variants in male Crohn's disease. Gut. *64*, 66-76.

Zhizhuo, H., Junmei, X., Yuelin, S., Qiang, Q., Chunyan, L., Zhengde, X., and Kunling, S. (2012). Screening the PRF1, UNC13D, STX11, SH2D1A, XIAP, and ITK gene mutations in Chinese children with Epstein-Barr virus-associated hemophagocytic lymphohistiocytosis. Pediatr. blood & cancer *58*, 410-414.