Peri-operative management of multiple tooth extractions in a patient with congenital hypofibrinogenemia receiving anticoagulant therapy

Short title: Extraction in congenital hypofibrinogenemia

Wataru Kakuguchi [ab*], Yoshiyuki Nakamichi[ab], Kazue Kasahara [a], Masaaki Horikawa[a] , Yoichi Ohiro[b]

[a] *Department of Oral and Maxillofacial Surgery, Hokkaido Chuo Rosai Hospital, 16-5, 4-Jo East, Iwamizawa, Japan.*
[b] *Department of Oral and Maxillofacial Surgery, Division of Oral Pathobiological Science, Faculty of Dental Medicine and Graduate School of Dental Medicine, Hokkaido University, North13 West7, Kita-ku, Sapporo, Japan.*

Conflict of interest

None.

Acknowledgments

We would like to thank Editage (www.editage.com) for English language editing.

Correspondence to:
Wataru Kakuguchi
Department of Oral and Maxillofacial Surgery, Hokkaido Chuo Rosai Hospital, 4-Jo, East 16-5, Iwamizawa, Japan
Phone: 81-136-22-1300
Fax: 81-1136-22-1300
Department of Oral and Maxillofacial Surgery, Division of Oral Pathobiological Science
Faculty of Dental Medicine and Graduate School of Dental Medicine, Hokkaido University
North 13 West 7, Kita-ku 060-8586, Sapporo, Japan
Phone: 81-11-706-4283
Fax: 81-11-706-4283

E-mail: wkakugu@den.hokudai.ac.jp

Peri-operative management of multiple tooth extractions in a patient with congenital hypofibrinogenemia receiving anticoagulant therapy

Abstract

Congenital fibrinogen disorder is rare and is responsible for the difficulty in achieving hemostasis following surgery. A 75-year-old man was referred to our hospital for the management of gingival hemorrhage. He had a medical history of congenital hypofibrinogenemia, right internal carotid stenosis, hypertension, brain infarction, and Alzheimer's disease. A diagnosis of gingival hemorrhage due to periodontitis of the maxillary left second molar and severe periodontitis necessitating extraction in the maxillary second molars bilaterally, mandibular left second molar, and mandibular right first and third molars was made. A pre-operative hematological examination revealed a fibrinogen level of 53.7 mg/dL. Fibrinogen (3 g) was administered, and reached a concentration of 92.8 mg/dL before the surgery. Several episodes of post-operative hemorrhages in the sockets were managed with local hemostatic treatment and splint adjustment. Fibrinogen levels were maintained at 72.5–92.8 mg/dL, until hemostasis was achieved. This case report illustrates the appropriate management of patients with congenital hypofibrinogenemia requiring extraction of multiple teeth.

Keywords: fibrinogenemia, tooth extraction, fibrinogen, hemorrhage

1. Introduction

Fibrinogen is an important protein for both primary and secondary hemostasis; it promotes clot formation, platelet aggregation, and fibrinolysis [1-2]. Congenital fibrinogen disorder is a rare disease [3], and can be classified into four types: afibrinogenemia, hypofibrinogenemia, dysfibrinogenemia, and hypodysfibrinogenemia [4]. Fibrinogen concentrations in the plasma typically range from approximately 200 to 450 mg/dL [1-2]. Hemostatic complications are evident at fibrinogen concentrations of less than 100 mg/dL [1]. A proportion of patients with congenital fibrinogen disorder are at a risk of arterial and venous thrombosis; therefore, anticoagulant or antiplatelet agent administration is recommended [3]. However, at the same time, such medications exacerbate the difficulties in achieving adequate hemostasis of the extraction socket.

In this case report, we describe the peri-operative management of multiple tooth extractions in a patient with congenital hypofibrinogenemia who was administered anticoagulant therapy.

2. Case report

A 75-year-old man was referred to our hospital in 2019 for the management of hemorrhage localized to the lateral gingiva of the maxillary left second molar. He had a medical history of congenital hypofibrinogenemia, right internal carotid stenosis, hypertension, brain infarction, and Alzheimer's disease. The patient and his family had undergone hematological examination in 1988 since his sister had presented with abnormal uterine bleeding during menstruation, which was caused by hypofibrinogenemia; the patient was diagnosed with congenital hypofibrinogenemia. No notable hemorrhage episodes with the exception of difficulty in hemostasis following primary tooth extraction during childhood were recorded. His prescribed medications included warfarin, aspirin, calcium channel blocker, angiotensin II receptor blocker, proton pump inhibitor, and yokukansan. The performance status (PS) was class 3 and the activity of daily living (ADL) was assigned as 59-point score of the functional independence measure (FIM). His extraoral findings were unremarkable. Pocket depths of up to 11 mm, and second or third degree tooth mobility were observed in the maxillary second molars bilaterally, mandibular left second molar, and mandibular right first and third molars. Horizontal and/or vertical resorption of the maxillary and mandibular alveolar bone was detected on the panoramic radiograph (Fig. 1, 2).

A hematological examination revealed a prothrombin time-international normalized ratio (PT-INR), activated partial thromboplastin time (APTT), and fibrinogen level of 2.63, 47.4 s, and 71.9 mg/dL, respectively (Table 1). A diagnosis of gingival hemorrhage due to periodontitis of the maxillary left second molar and severe periodontitis necessitating extraction in the maxillary second molars bilaterally, mandibular left second molar, and mandibular right first and third molars was made. A maxillary impression was taken for the fabrication of a hemostasis splint (Erkodur), with a thickness of 1.0 mm. The splint was not worn because of hemostasis due to pressure at the time of impression. Amoxicillin (750 mg/day) was prescribed for 3 days, and periodontal treatment was subsequently continued.

Edoxaban tosylate hydrate was substituted (by the primary care physician) for warfarin and aspirin, to facilitate easier management due to the lack of dose adjustment according to routine hematological examination 2 months following the first visit. Extraction was planned 5 months following the first visit owing to personal circumstances of the patient and his family. All extractions were planned under intravenous sedation with midazolam followed by in-hospital post-operative management. A pre-operative hematological examination revealed a PT-INR, APTT, and fibrinogen level of 2.13, 49.6 s, and 53.7 mg/dL, respectively (Table 1). Amoxicillin (750 mg/day) was prescribed 3

days before surgery to treat the periodontal infection of the gingiva of the maxillary left second molar. The patient's body weight at the time of admission was 49 kg. Fibrinogen (3 g) was administered to attain a plasma concentration of approximately 100 mg/dL at 5 hours before the surgery; a concentration of 92.8 mg/dL was confirmed 1 hour prior to surgery.

Local anesthetic (2% lidocaine, 1:80000 epinephrine) was administered prior to tooth extraction. Total 5.5 mg of midazolam was administered and minimal to moderate sedation depth was maintained according to the sedation level of American society of anesthesiologists. An absorbable hemostat was inserted into the sockets following tooth extraction, and the wounds were sutured with 5-0 nylon. Maxillary and mandibular splints (with a soft reline material) were fitted to achieve hemostasis. Postoperative amoxicillin (750 mg/day) was prescribed, and the patient's diet was limited to soft foods. A prescribed acetaminophen (400mg) was not used because the patient did not complain of postoperative pain. Hemorrhage was observed in the maxillary right second molar and mandibular right third molar sockets after dinner; this was managed by placing another suture (with local anesthesia), inserting an additional absorbable hemostat, and splint adjustment. His sisters observed him at his bedside following the surgery to prevent inadvertent splint removal by himself.

On post-operative day (POD) 1, a diagnosis of aspiration pneumonia was made based on the following signs: a body temperature of 38.5°C, crackles, right mid-lung lobe opacity visible on the chest radiograph, and increase in both white blood cell and C-reactive protein levels on hematological examination (Table 1, fig. 3). An intravenous infusion of piperacillin-tazobactam (4.5 g) was subsequently administered every 8 hours for 6 days. An intravenous infusion of acetaminophen (500mg) was administered for antipyretic only once. On the same day, hemorrhage was observed in the maxillary right second molar socket; this was stopped by adjusting the splint. As the fit of both splints was poor, impressions were retaken for the maxillary and mandibular arches. New maxillary and mandibular splints were fitted on POD 2. However, the mandibular splint was removed due to hemostasis of the mandibular sockets on the morning of POD 4; another episode of hemorrhage was observed in the mandibular right third molar socket after dinner. This was managed by the insertion of an additional absorbable hemostat, suture placement with local anesthesia, and splint reinsertion. All the sutures were removed on POD 7 (Fig.4). The mandibular and maxillary splints were removed on POD 11 and POD 14, respectively. The patient was discharged on POD 17, and followed up with continuous periodontal treatment and oral hygiene maintenance. Healing was uneventful at 20 months post-surgery (Fig. 5).

3. Discussion

The severity of congenital hypofibrinogenemia depends on the functional fibrinogen levels, which may be categorized as mild (100–150 mg/dL), moderate (50–100 mg/dL), or severe (less than 50 mg/dL) [4]. Fibrinogen levels greater than 100 mg/dL are adequate to prevent spontaneous hemorrhage, as well as hemorrhage induced by surgery, trauma, or pregnancy. However, fibrinogen levels below 100 mg/dL are associated with an increased hemorrhage risk and severity [1].

Congenital afibrinogenemia, congenital hypofibrinogenemia, and dysfibrinogenemia are associated with a high risk of arterial and venous thrombotic events; indeed, congenital dysfibrinogenemia has been reported to account for 20–30% of arterial and venous thrombotic events [5-7]. The reason for this could be that the circulating thrombin concentrations and thrombin activity are increased in fibrinogen deficiency [8]. Therefore, anticoagulant therapy is recommended for the prevention of thrombosis in these patients.

Fibrinogen replacement may be provided via fibrinogen concentrate, cryoprecipitate, and fresh frozen plasma, and has a half-life of approximately 3–5 days [1]. An initial fibrinogen supplementation of 1–2 g may suffice for hemorrhage related to low fibrinogen

concentration or function [1]. However, a recent European guideline recommended an initial fibrinogen supplementation of 3–4 g for cases of major hemorrhage [9]. One proposed formula for determining the required fibrinogen supplement dose is as follows: {target level (g/L) – baseline (g/L)} x 0.043 x body weight (kg) [3]. However, in the present case, fibrinogen (3 g) administration was only able to increase the plasma concentration to 40 mg/dL, which was unexpected. Thus, fibrinogen might be destroyed during supplementation or fibrinogen antibody was produced during initial fibrinogen supplementation for the patient.

Several studies have provided guidelines for fibrinogen supplementation for surgical procedures. One study recommended a fibrinogen target level of > 50 mg/dL for minor surgery [2], and > 100 mg/dL for major surgery, until the completion of healing [2]. Another study recommended a fibrinogen target level of 50–70 mg/dL (1–5 days) or 100 mg/dL (1–2 days) for less severe hemorrhage, and 100 mg/dL (1–7 days) for minor surgery [10].

Few studies have reported tooth extraction among patients with congenital fibrinogen disorder. One case report described the extraction of bilateral mandibular molars in a patient with afibrinogenemia, and the administration of 20 U cryoprecipitate [11], which is equivalent to 3–4 g of fibrinogen concentrate [9]. The author advised that the desired fibrinogen level in such cases would be at least 100 mg/dL [11]. In the current case, the

patient was treated with edoxaban tosylate hydrate. Therefore, hemostasis was difficult, and required suture placement, absorbable hemostat insertion, and hemostasis splint setting. Nevertheless, the fibrinogen concentration was maintained between 72.5 and 92.8 mg/dL until POD 6.

Fibrinogen levels may be elevated by factors such as an inflammatory condition, age, pregnancy, obesity, and smoking [12]. In the acute phase of inflammation, fibrinogen levels may increase 2- to 20-fold via the action of interleukin-6, and reach a peak elevation by 5 days [13]. Fibrinogen gradually returns to baseline levels following the resolution of inflammation. In the current case, the fibrinogen level decreased from 71.9 mg/dL (at the first visit) to 53.9 mg/dL (at the preoperative examination) due to the reduction in severity of periodontitis via periodontal therapy and antibiotic administration. The patient's fibrinogen level at baseline was approximately 53 mg/dL, which corresponded to the most severe form of congenital hypofibrinogenemia. Therefore, it is important to re-evaluate the fibrinogen levels and consider fibrinogen supplementation following the provision of periodontal therapy to reduce inflammation.

Intra venous sedation (IVS) with midazolam decreased the swallowing reflex, resulting in aspiration pneumonia. Additionally, the pneumonia was related to aspiration of the post-operative hemorrhage in this case. Increased intraoral hemorrhage on IVS

may cause suffocation. The intraoperative aspiration and the suffocation by hemorrhage could be prevented by general anesthesia. Since the patient had a significant medical history, low PS, and low FIM score, general anesthesia was not considered suitable for the patient.

Moreover, less than 63-point FIM score increases the mortality rate in elderly patients who had critical disease managed in an intermediate care unit [14].

Written consent for the treatment procedures and permission for the use of data and images contained within this report were obtained from the patient's sister; the patient was incapable of providing consent due to Alzheimer's disease.

4. Conclusion

This case report illustrated the peri-operative management of a patient with hypofibrinogenemia, who required multiple tooth extractions. Although the patient was on anticoagulant therapy, hemostasis was successfully achieved by fibrinogen replacement (approximately 100 mg/dL), suture placement, absorbable hemostat placement, and splint insertion.

References

1 Levy JH, Goodnough LT. How I use fibrinogen replacement therapy in acquired bleeding. Blood. 2015;125(9):1387-93.

2 Peyvandi F. Epidemiology and treatment of congenital fibrinogen deficiency. Thromb Res. 2012;130 Suppl 2:S7-11.

3 Casini A, de Moerloose P, Group CFD. Management of congenital quantitative fibrinogen disorders: a Delphi consensus. Haemophilia. 2016;22(6):898-905.

4 Casini A, Undas A, Palla R, Thachil J, de Moerloose P, Fibrinogen SoFXa. Diagnosis and classification of congenital fibrinogen disorders: communication from the SSC of the ISTH. J Thromb Haemost. 2018;16(9):1887-90.

5 Nagler M, Kremer Hovinga JA, Alberio L, Peter-Salonen K, von Tengg-Kobligk H, Lottaz D, et al. Thromboembolism in patients with congenital afibrinogenaemia. Long-term observational data and systematic review. Thromb Haemost. 2016;116(4):722-32.

6 Casini A, Blondon M, Lebreton A, Koegel J, Tintillier V, de Maistre E, et al. Natural history of patients with congenital dysfibrinogenemia. Blood. 2015;125(3):553-61.

7 Castaman G, Lunardi M, Rigo L, Mastroeni V, Bonoldi E, Rodeghiero F. Severe spontaneous arterial thrombotic manifestations in patients with inherited hypo- and afibrinogenemia. Haemophilia. 2009;15(2):533-7.

8 Korte W, Poon MC, Iorio A, Makris M. Thrombosis in Inherited Fibrinogen Disorders. Transfus Med Hemother. 2017;44(2):70-76.

9 Spahn DR, Bouillon B, Cerny V, Duranteau J, Filipescu D, Hunt BJ, et al. The European guideline on management of major bleeding and coagulopathy following trauma: fifth edition. Crit Care. 2019;23(1):98.

10 Peyvandi F, Haertel S, Knaub S, Mannucci PM. Incidence of bleeding symptoms in 100 patients with inherited afibrinogenemia or hypofibrinogenemia. J Thromb Haemost. 2006;4(7):1634-7.

11 Cillo J, Pulsipher A, Rutherford CJ, Ellis E. Third molar extractions in a patient with congenital afibrinogenemia: a case report. J Oral Maxillofac Surg. 2001;59(8): 935-6.

12 Woods A, Brull DJ, Humphries SE, Montgomery HE. Genetics of inflammation and risk of coronary artery disease: the central role of interleukin-6. Eur Heart J. 2000;21(19):1574-83.

13 Green F, Humphries S. Control of plasma fibrinogen levels. Baillieres Clin Haematol. 1989;2(4):945-59.

14 D'Andrea A, Le Peillet D, Fassier T, Prendki V, Trombert V, Reny JL, et al. Functional Independence Measure score is associated with mortality in critically ill elderly patients admitted to an intermediate care unit. BMC Geriatr. 2020;20(1):334.

Table

Table 1: Results of hematological examinations conducted from the first visit to the date of hospital discharge.

Figure legend

Figure 1: Panoramic radiograph obtained at the patient's first visit. Arrow heads indicate the teeth planned for extraction.

Figure 2: Oral photograph 1 week following the first visit. Gingival hemorrhage had stopped.

Figure 3: Line graph of hematological examinations conducted from the first visit to the date of hospital discharge.

Figure 4: Oral photograph after removal of sutures at 1 week following the extraction. Arrowheads indicate the extraction sockets. The clot area of the maxillary right second molar socket was wide. However, all sockets showed healing tendency.

Figure 5: Oral photograph 19 months following the extraction; the remaining teeth were functional.

Table1. Results of hematological examinations conducted from the first visit to the date of hospital discharge

	First visit	Pre-operative Exam.	Adm	Post-supplementation of Fbg	POD.1	POD.3	POD.6	POD.10	POD.17
WBC (10^3/μL)	5.94	5.48	4.99		8.64	4.93	3.98	6.18	3.91
Hb (g/dL)	8.5	11.8	12.1		11.1	8.5	7.3	7.9	9.1
Plt (10^3/μL)	171	186	202		193	161	186	273	375
CRP (mg/dL)					3.34	8.64	2.5	0.44	0.08
Fbg (mg/dL)	71.9	53.9	53.7	92.8	92	80.7	72.5	58.3	63.6
PT-INR	2.63	2.35	2.13	1.69	1.52	1.42	1.52	1.62	1.7
APTT (sec)	47.4	51.6	49.6	50.1	43	36	39.4	38.8	37.8

Adm, admission; Fbg, fibrinogen; POD, Post-operative day; Exam., examination.

Fig.1

Fig.2

Fig.3

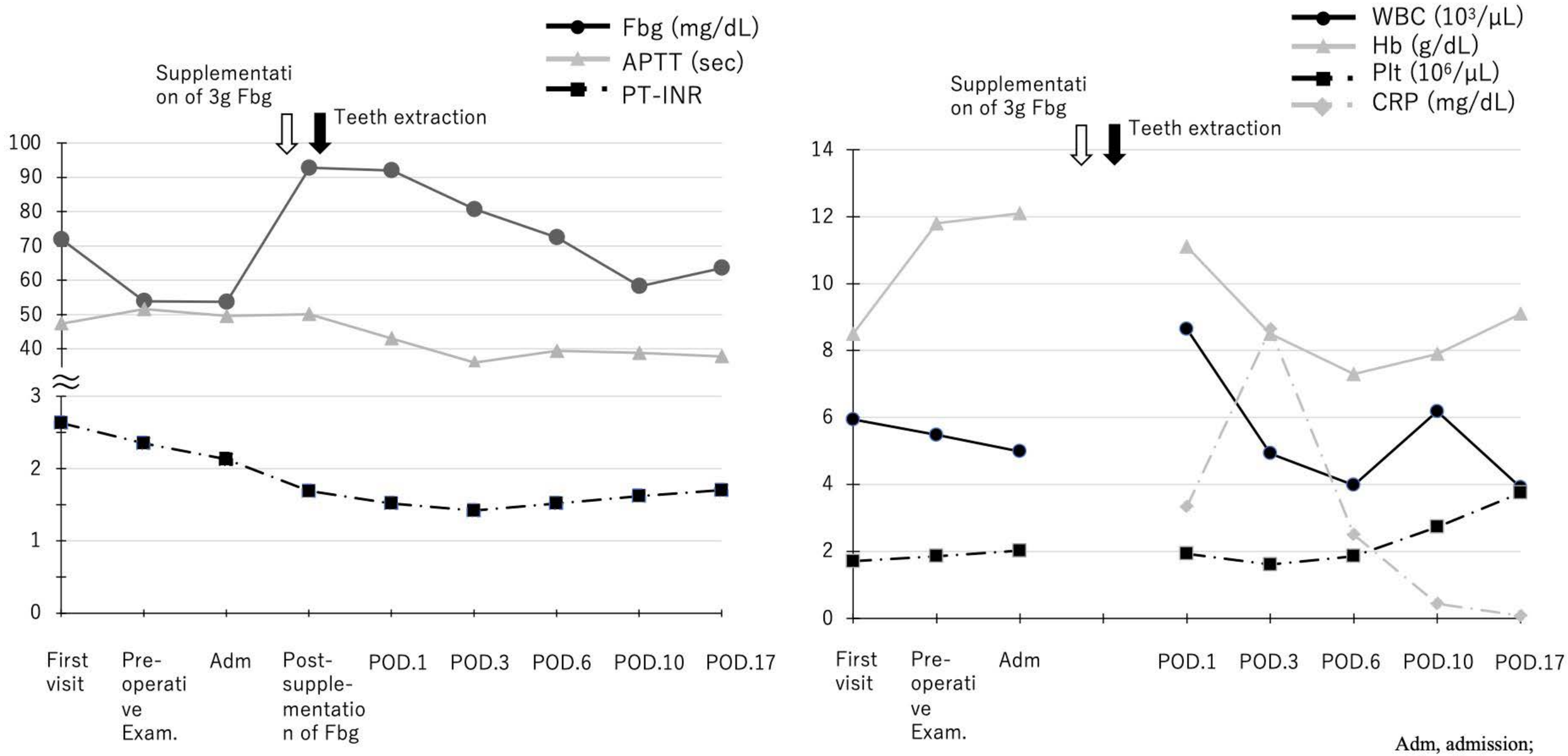

Adm, admission;
Fbg, fibrinogen
POD, Post-operative day
Exam., examination.

Fig.4

Fig.5