



Title	Objective evaluation of caudal deviation of the nasal septum and selection of the appropriate septoplasty technique
Author(s)	Kimura, Shogo; Suzuki, Masanobu; Honma, Aya; Nakazono, Akira; Osawa, Masayuki; Nakamaru, Yuji; Homma, Akihiro
Citation	Auris nasus larynx, 49(1), 67-76 <a href="https://doi.org/10.1016/j.anl.2021.04.012">https://doi.org/10.1016/j.anl.2021.04.012</a>
Issue Date	2022-02
Doc URL	<a href="http://hdl.handle.net/2115/88154">http://hdl.handle.net/2115/88154</a>
Rights	© 2021. This manuscript version is made available under the CC-BY-NC-ND 4.0 license <a href="http://creativecommons.org/licenses/by-nc-nd/4.0/">http://creativecommons.org/licenses/by-nc-nd/4.0/</a>
Rights(URL)	<a href="http://creativecommons.org/licenses/by-nc-nd/4.0/">http://creativecommons.org/licenses/by-nc-nd/4.0/</a>
Type	article (author version)
File Information	ANL 49(1) 67-76.pdf



[Instructions for use](#)

#### TITLE

Objective evaluation of caudal deviation of the nasal septum and selection of the appropriate septoplasty technique

#### AUTHORS

Shogo Kimura<sup>1</sup>, Masanobu Suzuki<sup>1</sup>, Aya Honma<sup>1</sup>, Akira Nakazono<sup>1</sup>, Masayuki Osawa<sup>2</sup>, Yuji Nakamaru<sup>1</sup>, and Akihiro Homma<sup>1</sup>

#### AFFILIATION

1. Department of Otolaryngology-Head & Neck Surgery, Faculty of Medicine and Graduate School of Medicine, Hokkaido University, Hokkaido, Japan.
2. Department of Plastic and Reconstructive Surgery, Faculty of Medicine and Graduate School of Medicine, Hokkaido University, Sapporo, Japan.

#### RUNNING TITLE

Objective evaluation of nasal septum deviation

#### CORRESPONDING AUTHOR

Yuji Nakamaru, Department Otolaryngology-Head and Neck Surgery, Hokkaido University Graduate School of Medicine, Kita 15, Nishi 7, Kita-ku, Sapporo, Hokkaido 060-8638, Japan. Tel: +81-11-706-5958, Fax: +81-11-717-7566 Email: nmaru@med.hokudai.ac.jp

## ABSTRACT

### ***Objective:***

Several methods have been reported to correct caudal deviation of the nasal septum, including open septorhinoplasty (OSR) and septoplasty with Killian incision (KI). In general, OSR is applied instead of KI for caudal deviation. However, there is little objective evidence own on the effects of OSR and KI for caudal deviation. In this study, we compared surgical outcomes between OSR and KI by quantifying nasal septum deviation using two simple and objective parameters on routine paranasal sinus CT scans.

### ***Methods:***

We retrospectively analyzed 18 patients who underwent OSR and 11 patients who underwent septoplasty with KI between April 2006 and October 2019. Caudal deviation was defined on the basis of the “Anterior-posterior Position of the most deviated point of the nasal septum (AP),” which was measured on computerized tomography. The deformation rate (DR) of the nasal septum was also calculated. Nasal airway resistance and visual analogue scale (VAS) score for nasal obstruction were examined.

### ***Results:***

The AP was significantly correlated with the VAS score ( $r=-0.58$ ,  $p=0.017$ ). The DR in patients with caudal septal deviation was significantly decreased by OSR ( $0.14\pm 0.06$  to  $0.03\pm 0.03$ ,  $p=0.004$ ), but not by KI ( $0.09\pm 0.08$  to  $0.04\pm 0.03$ ,  $p=0.25$ ). OSR also improved nasal airway resistance ( $1.10\pm 0.44$  to  $0.42\pm 0.15$ ,  $p=0.02$ ), and the VAS score ( $79.11\pm 14.74$  to  $5.78\pm 7.89$ ,  $p=0.004$ ).

### ***Conclusion:***

Nasal obstruction is more severe in patients with the caudal deviation. OSR corrects caudal deviation of the nasal septum more effectively than does KI. The AP could be useful for the evaluation of the deviation of the nasal septum and help in selecting the appropriate septoplastic technique.

***Key words:*** Open septorhinoplasty, caudal deviation of the nasal septum, deformation rate, Killian incision, nasal obstruction

## INTRODUCTION

Septoplasty is a surgical procedure for the correction of a deviated nasal septum, which is one of the major etiologies of nasal obstruction.[1] Several surgical techniques have been proposed to correct the various degrees of nasal septum deviation, including open septorhinoplasty (OSR) and endoscopic septoplasty with Killian incision (KI).[2] OSR addresses the deviated nasal septum from the anterior edge of the nasal septum cartilage via a small skin incision on the columella nasi.[3, 4] This surgical technique enables correction of deformation of the anterior part of the nasal septum, referred to as caudal deviation.[5-7] In contrast, KI cannot address the anterior part of the nasal septum as the incision is usually made in the mucosa posterior to or just on the anterior part of the nasal septum, not on the external skin of the nose (Figure 1a). In general, KI is preferred for cases without caudal deviation as the technique doesn't require an external skin incision, and OSR is often applied for cases with caudal deviation.[8, 9] However, no objective data have been provided on whether OSR does correct deviation of anterior part of the nasal septum, and there is no evidence that KI cannot correct caudal deviation. Further, no selection criteria for these different techniques of septoplasty have been established.

So far, little evidence has been presented regarding septoplasty, although the surgical procedure is one of the most frequently performed ENT operations. Recently, for the first time ever, a randomized controlled trial on septoplasty was reported and showed that septoplasty significantly improved nasal obstruction in comparison with non-surgical management.[10] However, neither the indication criteria for septoplasty nor the selection of different surgical techniques has been documented. Although caudal deviation is an important factor in terms of choosing between the different techniques, no definition of caudal deviation has been clearly established to date. At present, these clinically important judgements often depend on the surgeon's subjective preference based on their clinical experiences, not on robust objective data.[11]

The lack of high quality evidence regarding septoplasty is partly because there has been no standard method for evaluating nasal septum deviation.[12-14] It is true that numerous methods have been designed for the evaluation nasal septum deviation and internal nasal valve areas using acoustic rhinomanometry, optical coherence tomography and paranasal sinus computerized tomography(CT);[15-17] however, these are difficult to apply in daily practice as they require special devices or complicated morphological analysis. As mentioned above, there is no established method for evaluating the nasal septum, and a new evaluation method that can contribute to the selection of the

appropriate surgical technique is required.

In this study, we compared surgical outcomes between OSR and KI by quantifying nasal septum deviation using two simple and objective parameters on routine paranasal sinus CT scans. Based on these new simple parameters, we also set criteria for judging caudal deviation in an objective way and evaluated surgical outcomes of septoplasties in cases with or without caudal deviation.

## MATERIALS AND METHODS

### *Patients*

We retrospectively examined 18 patients with deviated nasal septum who underwent OSR and 11 patients who underwent septoplasty with KI between April 2006 and October 2019 at the Department of Otolaryngology, Hokkaido University Hospital. Before 2012, septoplasty with KI was performed for all patients with septal deviation. Since 2012, we have performed OSR for patients whom the surgeon subjectively considered to have caudal deviation and/or nose deformity. For all other patients, septoplasty with KI was performed. The paranasal sinus CT scans of the patients were reviewed, and nasal airway resistance and VAS score for nasal obstruction were retrospectively examined based on their medical records. This study was approved by the Institutional Review Board for Clinical Research of Hokkaido University Hospital, Sapporo, Japan (020-0141), and was conducted in accordance with the Declaration of Helsinki.

### *Computerized tomography (CT) imaging*

CT examinations of the maxillofacial and paranasal sinus were performed by using 320-slice area detector CT scanners (Aquilion ONE/Vision Edition) in the standard axial plane with a collimation of 0.5 mm, at 120 kV and 80 mA or less and a rotation time of 1.0 s. The subject's head was placed in a neutral position, without chin tilt, to match the infraorbital-meatal line (IOM line), which was drawn between the infraorbital margin and the external acoustic meatus. Coronal and sagittal multiplanar reconstruction (MPR) images were obtained from the axial images. Here, the coronal and sagittal images were adjusted so that these planes were perpendicular to the IOM plane.

### *Evaluation of nasal septum deviation*

In order to evaluate deviation of the nasal septum, we adopted two objective parameters of the most deviated point of the nasal septum (MDP); the Anterior-posterior Position of the MDP (AP) and the deformation rate (DR) [18] (Figure 1b).

The AP was measured by the following protocol,

- 1) First, the MDP was identified using coronal and horizontal CT scans.
- 2) Then, the distance between “the coronal CT scan including the tip of [the anterior nasal spine \(ANS\)](#)” and “the coronal CT scan including the MDP” was measured using sagittal CT scans.

The DR value was calculated by the following numerical formula,

$$DR = (a-b)/b = \{(a1+a2)-b\} /b.$$

Here, (a) is the maximal flexural deformed length at the MDP. (a1) is the upper side of the deformed septum cartilage; i.e., the distance from the top of the nasal septum cartilage to the nasal crest. (a2) is the lower side of the deformed septum cartilage; i.e., the distance from bottom of the nasal septum to the nasal crest. (a) is (a1) + (a2), and (b) is the original vertical length; i.e., the distance from the top of the nasal septum cartilage to the bottom of the nasal septum (Figure 2).

#### *Criteria for caudal deviation of the nasal septum*

The caudal area of the nasal septum within 10-15 mm from the caudal end is an important structure to maintenance of the shape of the nose and is referred to as the L-strut.[19] Caudal deviation of the nasal septum was defined AP < 15 mm.

#### *Surgery techniques*

For OSR: a V-shaped skin incision was made in the columella nasi, followed by elevation of the skin. The lower lateral cartilages were spread and the caudal edge of nasal septal cartilage was exposed at the midpoint of the lower lateral cartilages. A No. 15 scalpel was used to cut the mucosa at the edge of nasal septal cartilage and the mucoperichondrium on both sides of the nasal septum was elevated. Endoscopically, a portion of the nasal septal cartilage was resected with the L-strut left intact. In cases in which the L-strut was too long for the height of the nasal cavity, the inferior edge of the L-strut was appropriately shortened and the remaining sections of the L-strut were sutured to the nasal floor. The perpendicular plate and vomer also were resected. The harvested nasal septal cartilage was used as a batten graft or a spreader graft to correct external and/or internal nasal deformation, where necessary. Quilting sutures were placed through the septum to hold the flaps together. The skin of the ala nasi was also closed. As the final step in the procedure, silicon plates were placed on both sides of the nasal septum and the nasal cavities were packed with gauze for 4 days.

For KI: a mucosal incision was made in the junction between nasal vestibule skin and nasal mucosa on the left nasal septum. The mucoperichondrium on the left side of the nasal septum was elevated, leaving the right side intact. The perpendicular plate and

vomer were resected, while the majority of the nasal septum including the L-strut was left untouched. The following steps were same as for OSR, except that the closure of the skin of the ala nasi was unnecessary.[20]

#### *Rhinomanometry*

Nasal flow (ml/s) and pressure (Pa) at the narrow side of the nasal cavities were measured by rhinomanometry. Nasal airflow resistance (Pa/ml/s) was calculated at 100 Pa.

#### Visual analogue scale for nasal obstruction

Preoperative and postoperative symptoms of nasal obstruction were expressed using a visual analogue scale, where 0(mm) indicates an absence of nasal obstruction and 100(mm) indicates complete nasal obstruction.

#### *Statistical analysis*

All data are expressed as the mean  $\pm$  SD. Continuous variables such as AP, the DR value, nasal airway resistance, and VAS score for nasal obstruction were compared using the Wilcoxon signed-rank test. A P value  $<0.05$  was considered statistically significant. All statistical tests were performed using the JMP® pro version 14 software program (SAS Institute Inc., Cary, NC, USA).



## RESULTS

### *Clinical characteristics of patients with nasal septum deviation*

In order to evaluate nasal septum deviation and the surgical effectiveness of the two different techniques, we retrospectively reviewed 18 patients who underwent OSR for nasal septum deviation (OSR group) and 11 patients who received KI (KI group). In total, 9 (31%) of the patients were female and 20 (69%) were male. The median age was  $30\pm 3.4$  years (range, 16-77 years).

In the OSR group, 6 (33%) of the patients were female and 12 (67%) were male. The mean age was  $22.5\pm 4.0$  years (range, 16-77 years). Eleven patients had been diagnosed as congenital facial malformation, 6 patients had a history of facial trauma and one had previously undergone septoplasty.

In the KI group, 3 (27%) of the patients were female and 8 (73%) were male. The median age was  $52\pm 5.6$  years (range, 19-65 years). Eleven patients had idiopathic deviation of the nasal septum without congenital facial malformation, trauma, or previous septoplasty.

### *Morphological analysis of deviation of nasal septum*

The preoperative paranasal sinus CT scans were evaluated using the two simple parameters, the AP and DR value. The average AP was  $17.5\pm 11.0$  mm (Figure 3). Overall, the average preoperative DR value was  $0.15\pm 0.08$  and the average postoperative DR value was  $0.04\pm 0.03$ . In 13 of the 27 patients (48%), the AP was less than 15 mm, and these patients were judged to have caudal deviation of the nasal septum.

The height of the MDP from the floor of the nasal cavity was also measured. The average height of the MDP was  $13.3\pm 5.5$  mm. There were no cases in whom the MDP was located near the roof of the nasal cavity or the keystone area (Figure 3).

The AP was significantly correlated to the VAS score for nasal obstruction ( $p=0.017$ ,  $r=-0.58$ ) (Figure 4a). The VAS score in the patients with caudal deviation was significantly higher than that in the patients with non-caudal deviation (caudal deviation  $86.7\pm 10.3$  and non-caudal deviation  $63.3\pm 6.5$ ,  $p=0.02$ ) (Figure 4b). In contrast, the preoperative DR value was not significantly correlated to the preoperative VAS score ( $p=0.44$ ,  $r=-0.087$ ).

The AP was  $14.99\pm 10.18$  in the OSR group and  $21.72\pm 11.45$  in the KI ( $p=0.13$ ). Nine (33%) patients in the OSR group and 4 (15%) in the KI group were judged to have caudal deviation of the nasal septum. The preoperative DR value was  $0.17\pm 0.07$  in the OSR group and  $0.12\pm 0.08$  in the KI ( $p=0.21$ , Supplementary figure 1). The preoperative

DR value was  $0.12\pm 0.07$  in patients with caudal deviation and  $0.17\pm 0.08$  in patients without caudal deviation ( $p=0.08$ ).

*OSR significantly decreased the DR value, while KI did not in cases with caudal septal deviation.*

The preoperative and postoperative DR values were compared to evaluate the outcome of the septoplasty in morphological terms. The postoperative DR value were significantly decreased both in the OSR (preoperative  $0.17\pm 0.07$  to postoperative  $0.04\pm 0.03$ ,  $p<0.0001$ ) and KI groups (preoperative  $0.12\pm 0.08$  to postoperative  $0.04\pm 0.03$ ,  $p=0.01$ ) (Figure 5a).

In the patients with caudal deviation, the DR value were significantly decreased in the OSR group (preoperative  $0.14\pm 0.08$  to postoperative  $0.04\pm 0.03$ ,  $p=0.03$ ), but not significantly decreased in the KI group ( $0.08\pm 0.09$  to  $0.04\pm 0.03$ ,  $p=0.63$ ) (Figure 5b). In the patients without caudal deviation, the DR values were significantly decreased in both the OSR ( $0.20\pm 0.07$  to  $0.05\pm 0.03$ ,  $p=0.02$ ) and KI groups ( $0.14\pm 0.08$  to  $0.04\pm 0.03$ ,  $p=0.03$ ) (Figure 5c).

OSR also improved nasal airway resistance ( $1.10\pm 0.44$  to  $0.42\pm 0.15$ ,  $p=0.02$ ) (Figure 6a), and the VAS score ( $79.11\pm 14.74$  to  $5.78\pm 7.89$ ,  $p=0.004$ ) (Figure 6b).

## DISCUSSION

This study showed that the postoperative DR value in cases with caudal deviation were significantly improved by OSR, but not by KI, suggesting that the caudal deviation could be corrected with OSR, but not fully with KI. In addition, we presented objective data showing that patients with caudal deviation had more severe nasal obstruction than did those without it. We also found that the AP was significantly correlated with the VAS score. These results suggest that the symptoms of nasal obstruction largely depend on how close it is to the inner nasal valves and OSR should be applied for the cases with caudal deviation.

It is true that some of these findings, themselves, are not new and have been already widely assumed by ENT surgeons based on their clinical experience. In theory, the caudal deviation was assumed to worsen nasal obstruction as it narrows the inner nasal valves, the narrowest area in the airway in nasal cavities. OSR, rather than KI, is often selected for patients with caudal deviation as OSR enables an approach to the anterior part of nasal septum while KI cannot address the lesion as the technique is designed to keep this area intact (Figure 1a). However, there were no studies to provide objective data showing the significance of caudal deviation to nasal obstruction and the superiority of OSR to KI in case with caudal deviation. The discussion on these topics was not beyond the subjective rule of thumb due to the lack of standard objective methods to evaluate deviation of the nasal septum.

To date, numerous methods have been designed for the evaluation of deviation of the nasal septum and internal nasal valve areas using acoustic rhinomanometry, optical coherence tomography and paranasal sinus CT.[15-17] It is true that acoustic rhinomanometry and optical coherence tomography are useful for the objective evaluation of the form of the nasal septum, but special devices are required and it is still difficult to apply these methods in daily practice. As for paranasal sinus CT, several parameters have been proposed to evaluate deviation of the nasal septum. One of the proposed parameters is the internal nasal valve angle.[21] This angle is described by the upper lateral nasal cartilages and the nasal septum, which is displayed in the coronal images of the paranasal sinus CT. The angle was reported to be significantly decreased after septoplasty. This interesting study showed the usefulness of the angle for the evaluation surgical effectiveness, but their data did not directly contribute to the surgical criteria or help in the selection between different techniques. As another method, geometric morphometry was introduced with 30 landmarks on the nasal septum measured in each paranasal sinus CT.[22] However, as the number landmarks measured in the study

was as many as 30, it also makes this method difficult to apply in clinical use. In addition, these methods again did not provide surgical criteria or help in the selection between different septoplastic techniques.

Thus, there was no established method with which to evaluate the nasal septum based on paranasal sinus CT scans. A new evaluation method that can contribute to the selection of the appropriate surgical technique has been required.

In order to evaluate the degree of deviation of the nasal septum, we used two objective parameters: the DR value and AP. The DR value, originally proposed by Yang et al, reflects how laterally the nasal septum is deviated in the nasal cavity. However, it could not evaluate the front-to-back deviation of the nasal septum, which is also important, as shown in this study. Indeed, the correlation between the DR value and the VAS score for nasal obstruction was not significant.

As the surface of the nasal septum has multiple curves in three-dimensional space, another parameter on the orthogonal plane to the coronal plane where the DR value was measured was necessary. In this study, we adopt the AP for front-to-back evaluation. The combination of the AP and DR value can reflect where (the AP) and how much (the DR value) the nasal septum is deviated. With the two objective parameters, we could compare the pre- and post-operative form of the nasal septum in each individual to examine the outcome of the septoplasty. We also could assess the severity of the deviation, select the appropriate surgical technique, and compare outcomes between different techniques, in an objective manner.

To date, there have been no standard criteria for judging caudal deviation.[13-17];[21, 22, 25] The evaluation methods used in this study also allow us to set objective criteria for caudal deviation. In this study, we set a criterion for distinguishing caudal from non-caudal deviation based on AP of less than 15 mm. The caudal area of the nasal septum within 10-15 mm from the ANS (L-strut) is considered clinically important to maintaining the strength of the nasal septum (Figure 1b). As discussed above, the selection of surgical techniques is largely dependent on whether the MDP is located in the caudal area or not. Thus, we adopted 15 mm as the criterion for judging caudal deviation. This criterion is clinically valuable as it directly contributes to selection of the surgical technique.

As landmarks for the L-strut, previous studies reported imaginary lines defined on the anatomical landmarks in the endoscopic view. [23, 24] These imaginary lines are helpful during surgery. In contrast, our method using the AP and DR on CT views is useful for preoperative evaluation of deviation of the nasal septum. A combination of the

imaginary lines and our method would provide more effective surgical treatment for nasal septal deviation.

Our results showed that both KI and OSR corrected the deviation in cases where the MDP was located beyond 15mm posterior from the ANS (non-caudal deviation). In such cases, KI would be more suitable as the technique does not require an external skin incision on the columella nasi. On the other hand, OSR should be chosen for cases in which the MDP is located within 15 mm from the ANS as KI failed to significantly improve the DR value in such cases in this study.

The evaluation method used in this study is simple and clinical friendly as it uses only two parameters that are easily measured on paranasal sinus CT scans, which are routinely taken before surgery. In addition, our results showed that the AP also well reflect the VAS score. The combination of the evaluation methods, the VAS score and rhinomanometry would enable the evaluation of the deviation of the nasal septum[26-31] in terms of morphology, subjective severity and nasal airway function. Further studies with a larger patient population will shed light on the usefulness of the evaluation system in daily practice and could contribute to standardization of the diagnosis and treatment of the deviated nasal septum.

There are a few limitations to this study. First, the number of cases with caudal deviation treated by KI was small. Further study including a greater number of cases with caudal deviation is warranted. Second, as the coronal scans are not always parallel to the caudal edge of the nasal septum, there might be cases in whom the caudal deviation is “overjudged” although their MDP is located over 15 mm away from the caudal edge (See the green area in Supplementary figure 2a). Geometrically, the higher the MDP was located, the more likely the case would be “overjudged” as having caudal deviation, according to our criterion. However, the MDP in most cases was indeed located lower than the midpoint between the dorsum end of the nasal septum and the floor of the nasal cavity ( $31.7\pm 13.5\%$  in height from the bottom, Figure 3 and Supplementary figure 2b), suggesting the cases “overjudged” in terms of caudal deviation would be a few in a clinical situation. To the contrary, there is no possibility that cases with a MDP within 15 mm from the caudal edge could be “overlooked” as non-caudal deviation under this criterion. This priority to sensitivity rather than specificity for caudal deviation is preferable in a clinical situation as “overlooking”, rather than “overjudging”, directly affects the selection of different surgical techniques and, consequently, the surgical

outcome as shown in this study. Last, we could not present data on subjective or clinical comparisons of the surgical effect in this study. There are no articles on a comparison in the treatment effect between OSR and KI in terms of function and subjective symptoms. Further study will be necessary to allow the comparison of surgical outcomes between OSR and KI in terms of function and subjective symptoms.

## CONCLUSION

Nasal obstruction is more severe in patients with the caudal deviation. OSR corrects the caudal deviation of the nasal septum significantly better than KI. The AP could be useful for the evaluation of the deviation of the nasal septum and help in selecting the appropriate septoplastic technique, which will provide more effective surgical treatment for patients suffering from nasal obstruction due to nasal septal deviation.

## ACKNOWLEDGEMENTS

We are grateful to Yuka Masuda, Shizuka Sugawara, Yumiko Kimura, and Ayaka Kubota for help in preparing the manuscript.

## AUTHORSHIP CONTRIBUTION

SK, MS, and YN designed the study. MS, YN, and MO performed the surgeries. AkH supervised the project. AyH and N, SK and AN compiled the data. SK, MS, YN, and AkH wrote the manuscript. All authors provided feedback on the manuscript.

## Disclosure Statement

## CONFLICT OF INTEREST

None of the authors have any conflicts of interest or financial disclosures that are relevant to this study.

## FINANCIAL DISCLOSURE

This study was supported by JSPS KAKENHI Grant Number 17H06491, 18K16871, and 18KK0444 for MS, 19K18718 for AN, 20K18301 for AyH and 20K09703 for YN, and a GSK Japan Research Grant 2015, and the Akiyama Life Science Foundation to MS and AyH as well as a Sanofi Japan research grant to AkH.



## REFERENCES

1. Getz AE, Hwang PH. Endoscopic septoplasty. *Curr Opin Otolaryngol Head Neck Surg* 2008;16:26-31.
2. Chandra RK. Endoscopic septoplasty: "How I do it". *Am J Rhinol Allergy* 2017;31:276-7.
3. Hept W, Hildenbrand T. Septal surgery in septorhinoplasty. *Hno* 2011;59:831-43; quiz 44-5.
4. Vuyk HD, Olde Kalter P. Open septorhinoplasty. Experiences in 200 patients. *Rhinology* 1993;31:175-82.
5. Aksakal C. Surgical Outcomes of Bony Batten Grafting Through Endonasal Septoplasty in the Correction of Caudal Septum Deviation. *J Craniofac Surg* 2020;31:162-5.
6. Chung YS, Seol JH, Choi JM, Shin DH, Kim YW, Cho JH, et al. How to resolve the caudal septal deviation? Clinical outcomes after septoplasty with bony batten grafting. *Laryngoscope* 2014;124:1771-6.
7. Kim SA, Jang YJ. Caudal Septal Division and Interposition Batten Graft: A Novel Technique to Correct Caudal Septal Deviation in Septoplasty. *Ann Otol Rhinol Laryngol* 2019;128:1158-64.
8. Haack J, Papel ID. Caudal septal deviation. *Otolaryngol Clin North Am* 2009;42:427-36.
9. Most SP, Rudy SF. Septoplasty: Basic and Advanced Techniques. *Facial Plast Surg Clin North Am* 2017;25:161-9.
10. van Egmond M, Rovers MM, Hannink G, Hendriks CTM, van Heerbeek N. Septoplasty with or without concurrent turbinate surgery versus non-surgical management for nasal obstruction in adults with a deviated septum: a pragmatic, randomised controlled trial. *Lancet* 2019;394:314-21.
11. Dobratz EJ, Park SS. Septoplasty pearls. *Otolaryngol Clin North Am* 2009;42:527-37.
12. Rennie KJ, O'Hara J, Rousseau N, Stocken D, Howel D, Ternent L, et al. Nasal Airway Obstruction Study (NAIROS): a phase III, open-label, mixed-methods, multicentre randomised controlled trial of septoplasty versus medical management of a septal deviation with nasal obstruction. *Trials* 2020;21:179.
13. Vandenbroeck S, Jorissen M. Endoscopic septoplasty: literature review, surgical techniques and retrospective analysis at the University Hospitals Leuven. *J Laryngol Otol* 2019;133:262-8.
14. Wright L, Grunzweig KA, Totonchi A. Nasal Obstruction and Rhinoplasty: A Focused Literature Review. *Aesthetic Plast Surg* 2020.
15. Bloom JD, Sridharan S, Hagiwara M, Babb JS, White WM, Constantinides M. Reformatted computed tomography to assess the internal nasal valve and association with physical examination. *Arch Facial Plast Surg* 2012;14:331-5.
16. Cakmak O, Coşkun M, Celik H, Büyüklü F, Ozlüoğlu LN. Value of acoustic rhinometry for measuring nasal valve area. *Laryngoscope* 2003;113:295-302.
17. Enghard AS, Wiedmann M, Ledderose GJ, Lemieux B, Badran A, Jing JC, et al. In vivo imaging of the internal nasal valve during different conditions using optical coherence tomography.

- Laryngoscope 2018;128:E105-e10.
18. Yang G, Zhao H, Wang P, Han X, Zao X, Liu Z, et al. Measurement of deformation rate in nasal septum deviation by three-dimensional computer tomography reconstruction and its application in nasal septoplasty endoscopic surgery. *Exp Ther Med* 2017;14:1519-25.
  19. Spataro EA, Saltychev M, Kandathil CK, Most SP. Outcomes of Extracorporeal Septoplasty and Its Modifications in Treatment of Severe L-Strut Septal Deviation: A Systematic Review and Meta-analysis. *JAMA Facial Plast Surg* 2019;21:542-50.
  20. Wormald P-J. Endoscopic Sinus Surgery: Anatomy, Three-Dimensional Reconstruction, and Surgical Technique, 4th ed 2017:22-32.
  21. Yazici A, Er HC. The correlation of computed tomography in the evaluation of septoplasty patients. *Niger J Clin Pract* 2019;22:1196-200.
  22. Radulesco T, Hazbri D, Dessi P, Adalian P, Michel J. Geometric morphometric contribution to septal deviation analysis. *Surg Radiol Anat* 2019;41:823-31.
  23. Seth R, Haffey T, McBride JM, Sindwani R. Intranasal landmarks for adequate L-strut preservation during endoscopic septoplasty. *Am J Rhinol Allergy* 2014;28:265-8.
  24. Alhedaihy R, Alhussien A, Alroqi A, Alromaih S, Aloulah M, Alsaleh S. Intranasal endoscopic identification of the nasal septal L-strut: a cadaveric study. *Int Forum Allergy Rhinol* 2019;9:934-8.
  25. Saul B, Rettinger G, Scheithauer M, Veit J, Sommer F, Lindemann J. [Radiological findings of the nasal septum in CT scan in patients with deviated noses]. *Laryngorhinootologie* 2014;93:174-7.
  26. Balikci HH, Gurdal MM. Satisfaction outcomes in open functional septorhinoplasty: prospective analysis. *J Craniofac Surg* 2014;25:377-9.
  27. Başer E, Kocagöz GD, Çalim Ö F, Verim A, Yilmaz F, Özturan O. Assessment of Patient Satisfaction With Evaluation Methods in Open Technique Septorhinoplasty. *J Craniofac Surg* 2016;27:420-4.
  28. Erdivanli OC, Coskun ZO, Ozgur A, Ogurlu M, Demirci M, Dursun E. Comparison of Quality of Life Before and After Septoplasty With Short Form-36. *J Craniofac Surg* 2020.
  29. Rot P, Skrzypiec L, Jadcak M, Jurkiewicz D. Comparison of quality of life before and after open septorhinoplasty with the WHOQOL-BREF questionnaire. *Otolaryngol Pol* 2018;73:1-4.
  30. Sharma SD, Jacques T, Abed T, Gatland D. Outcomes in open structure septorhinoplasty. *B-ent* 2015;11:263-6.
  31. Shukla RH, Nemade SV, Shinde KJ. Comparison of visual analogue scale (VAS) and the Nasal Obstruction Symptom Evaluation (NOSE) score in evaluation of post septoplasty patients. *World J Otorhinolaryngol Head Neck Surg* 2020;6:53-8.

## FIGURES LEGENDS

### **Figure 1 Positional relationship to the caudal area of the nasal septum.**

(a) Incision line of septoplasty. KI (blue) is designed to leave the caudal area (yellow area) intact and could not address the caudal area, while OSR (red) enables an approach to and correction of the caudal area. Red arrow: Open septorhinoplasty (OSR), Blue arrow: Killian incision (KI).

(b) Definition of caudal deviation of the nasal septum. The L-strut is defined as the caudal and dorsal area (10-15mm) of the nasal septum cartilage (yellow area). The distance between “the coronal CT scan including the tip of the ANS” and “the coronal CT scan including the most deviated point (MDP)” was defined as the Anterior-posterior Position (MDP) of the nasal septum (AP). We defined cases with an AP of less than 15mm as having caudal septal deviation, because the MDP is located in the L-strut in such cases.

### **Figure 2 The Deformation Rate (DR).**

The DR value was used as an objective parameter of deviation of the nasal septum. The value was calculated by the following numerical formula:  $DR = (a-b)/b =$

$\{(a1+a2)-b\} /b$ . (a) is the maximal flexural deformed length, (a1) is the upper side of the deformed septum cartilage; i.e., the distance from the top of the nasal septum cartilage to the nasal crest, (a2) is the lower side of the deformed septum cartilage; i.e., the distance from the bottom of the nasal septum to the nasal crest, (a) is (a1) + (a2), and (b) is the original vertical length; i.e., the distance from the top of the nasal septum cartilage to the bottom of the nasal septum.

### **Figure 3 Comparison of the position of the MDP between the OSR and KI groups.**

The AP was  $14.99 \pm 10.18$  mm in the OSR group (red dots) and  $21.72 \pm 11.45$  mm in the KI group (blue dots), respectively ( $p=0.13$ ). The average height of the MDP from the floor of the nasal cavity was  $14.61 \pm 5.59$  mm in the OSR group and  $11.00 \pm 4.36$  mm in the KI group ( $p=0.14$ ). In 13 of the 27 patients (48%), the AP was less than 15 mm and these patients were judged to have caudal deviation of the nasal septum. Nine patients (33%) in the OSR group and 4 (15%) in the KI group were judged to have caudal deviation of the nasal septum, according to the criterion described above.

### **Figure 4 Comparison between paranasal sinus CT parameters and pre-operative. VAS score**

(a) The AP was significantly correlated with the VAS score ( $p = 0.017$ ,  $r=-0.58$ ).  
(b) The pre-operative VAS score for nasal obstruction in the caudal deviation group was significantly higher than that in the non-caudal deviation group (caudal  $86.7\pm 10.3$  and non-caudal  $63.3\pm 6.5$ ,  $p=0.02$ ).

### **Figure 5 Comparison of the DR values between the OSR and KI groups**

(a) The postoperative DR values were significantly decreased in the OSR and KI groups. (b) In the patients with caudal deviation, the postoperative DR value was significantly decreased in the OSR group, but not in the KI group. (c) In the patients without caudal deviation, the postoperative DR values were significantly decreased in both the OSR and KI groups.

### **Figure 6 Comparison between preoperative and postoperative nasal airway resistance and VAS score for nasal obstruction.**

(a) Postoperative nasal airway resistance was significantly improved in the OSR group. (b) The postoperative VAS score for nasal obstruction was also significantly decreased in the OSR group.

### **Supplementary figure 1 Comparison of the preoperative DR values between the OSR and KI groups.**

There was no significant difference in preoperative DR values between the KI group and the OSR group ( $p=0.24$ ).

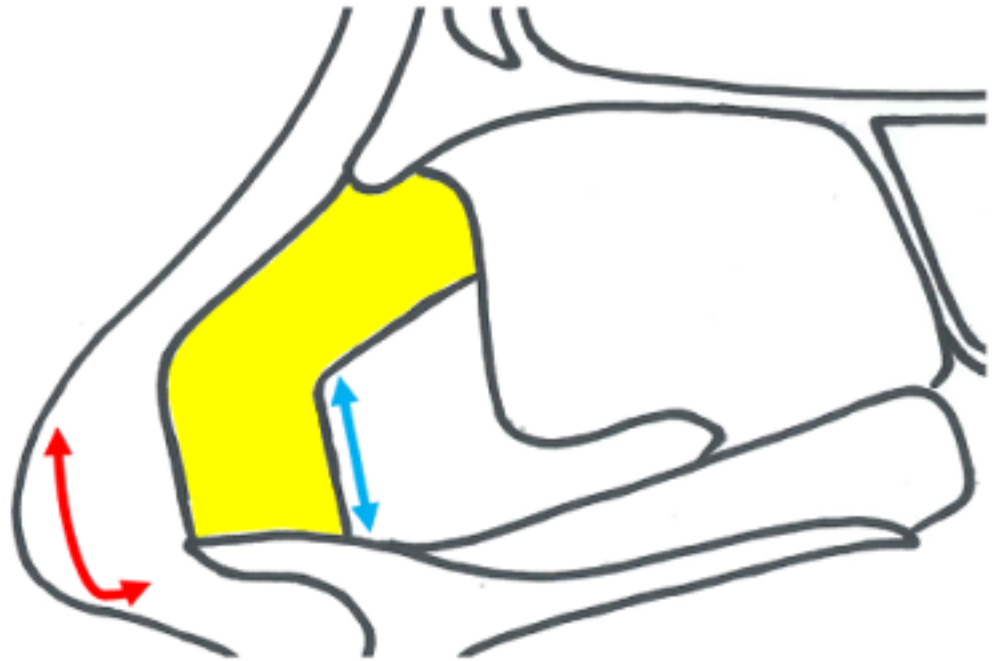### **Supplementary figure 2 Overjudging of caudal deviation is possible in theory, but occurs in a few cases in a clinical setting.**

(a) As the coronal scans are not always parallel to the caudal edge of the nasal septum, there might be cases in whom the “caudal deviation” is overjudged although the MDP is over 15 mm from the ANS. The blue is a line parallel to the caudal edge of the nasal septum 15 mm from the ANS. The area is that over 15 mm from the ANS although the AP is lower than 15 mm. In cases in which the MDP is in the green area, the case thought to be “overjudged” in terms of caudal deviation, according to the criterion in this study. Note the higher MDP was located, the more likely the case would be “overjudged”.

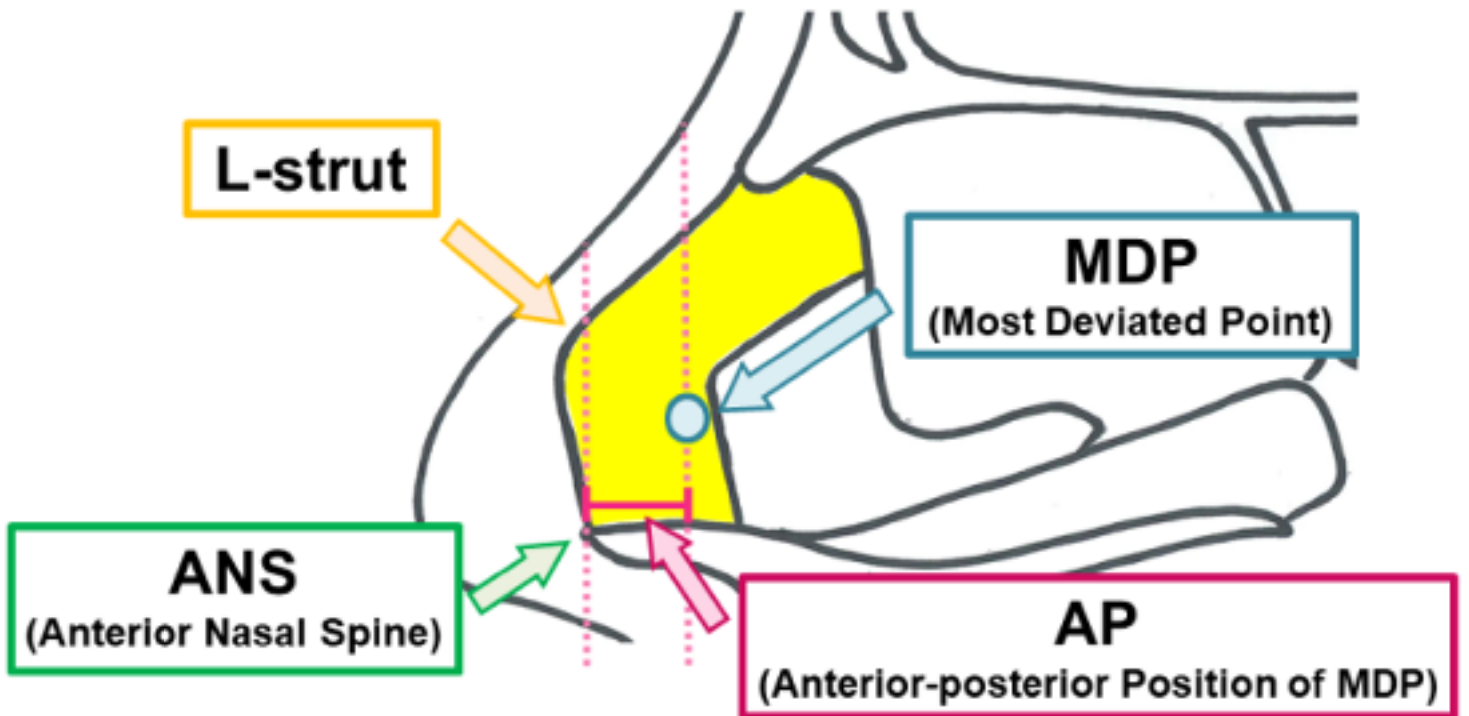
(b) However, the MDP in most cases was located lower than the midpoint between the dorsum end of the nasal septum and the floor of the nasal cavity ( $31.7 \pm 13.5\%$  mm in height from the floor of the nasal cavity), suggesting that the “overjudging” of cases occurs in a few cases in a clinical setting.

Kimura et al. Figure 1

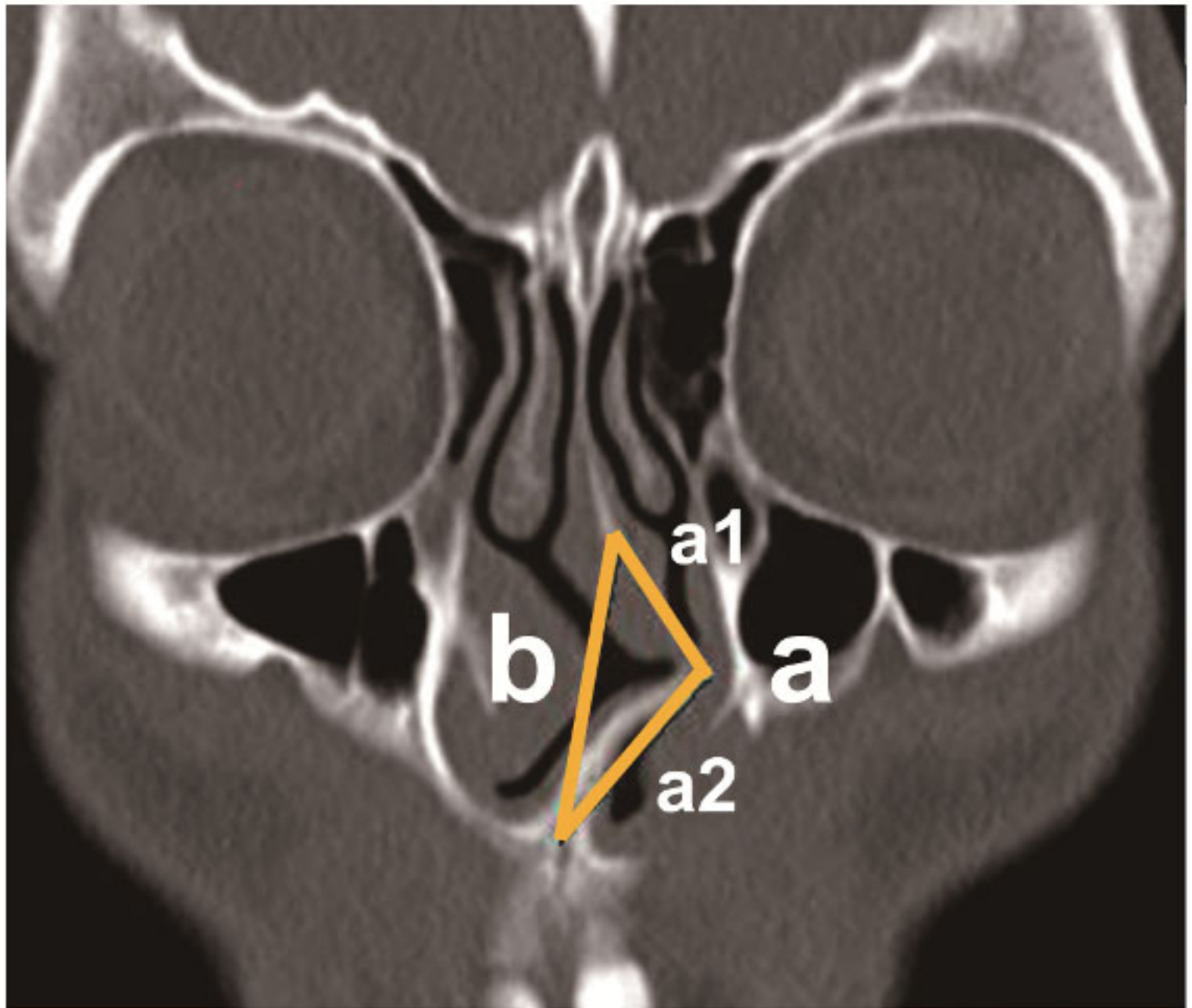
a



b

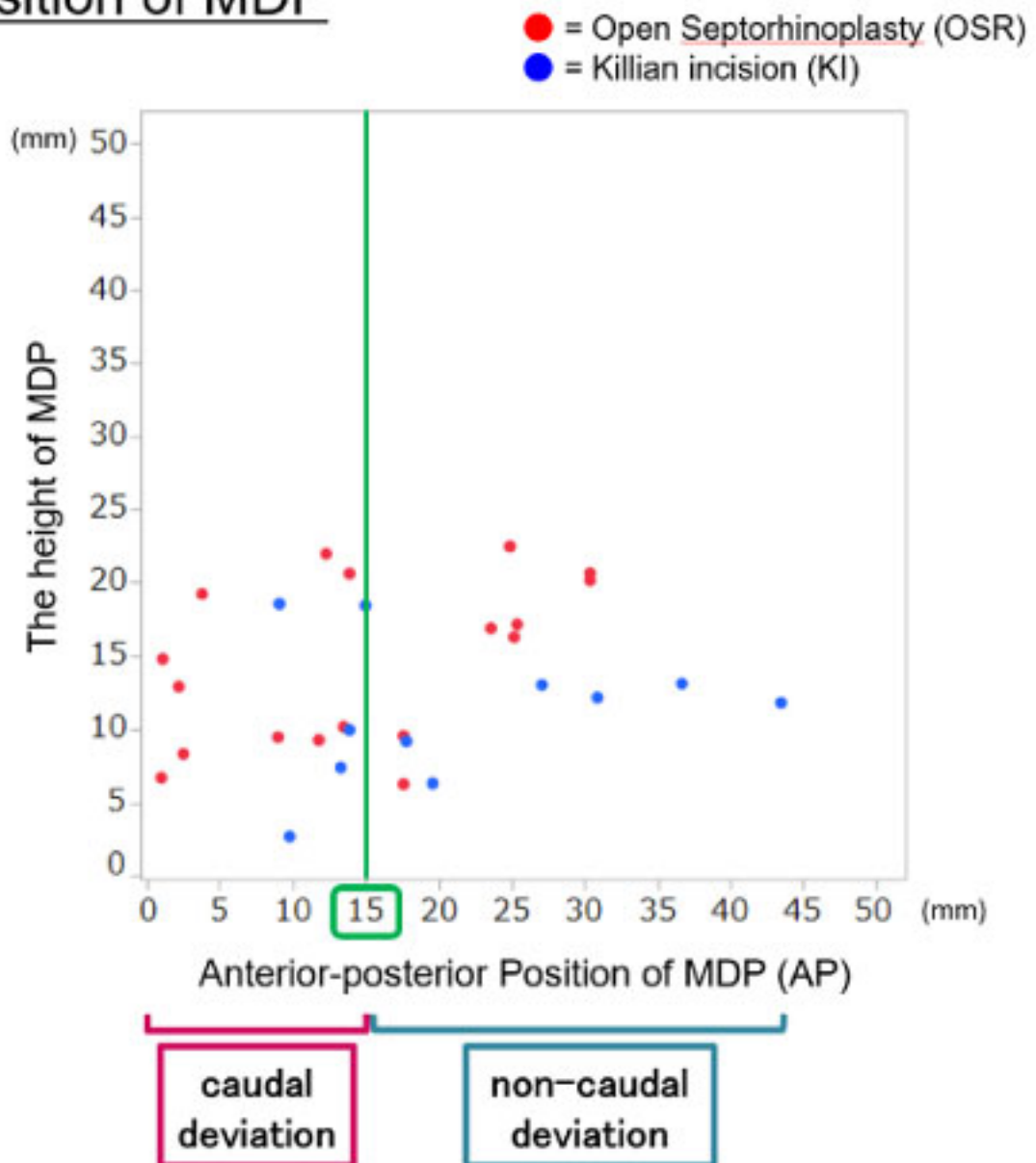


Kimura et al. Figure 2



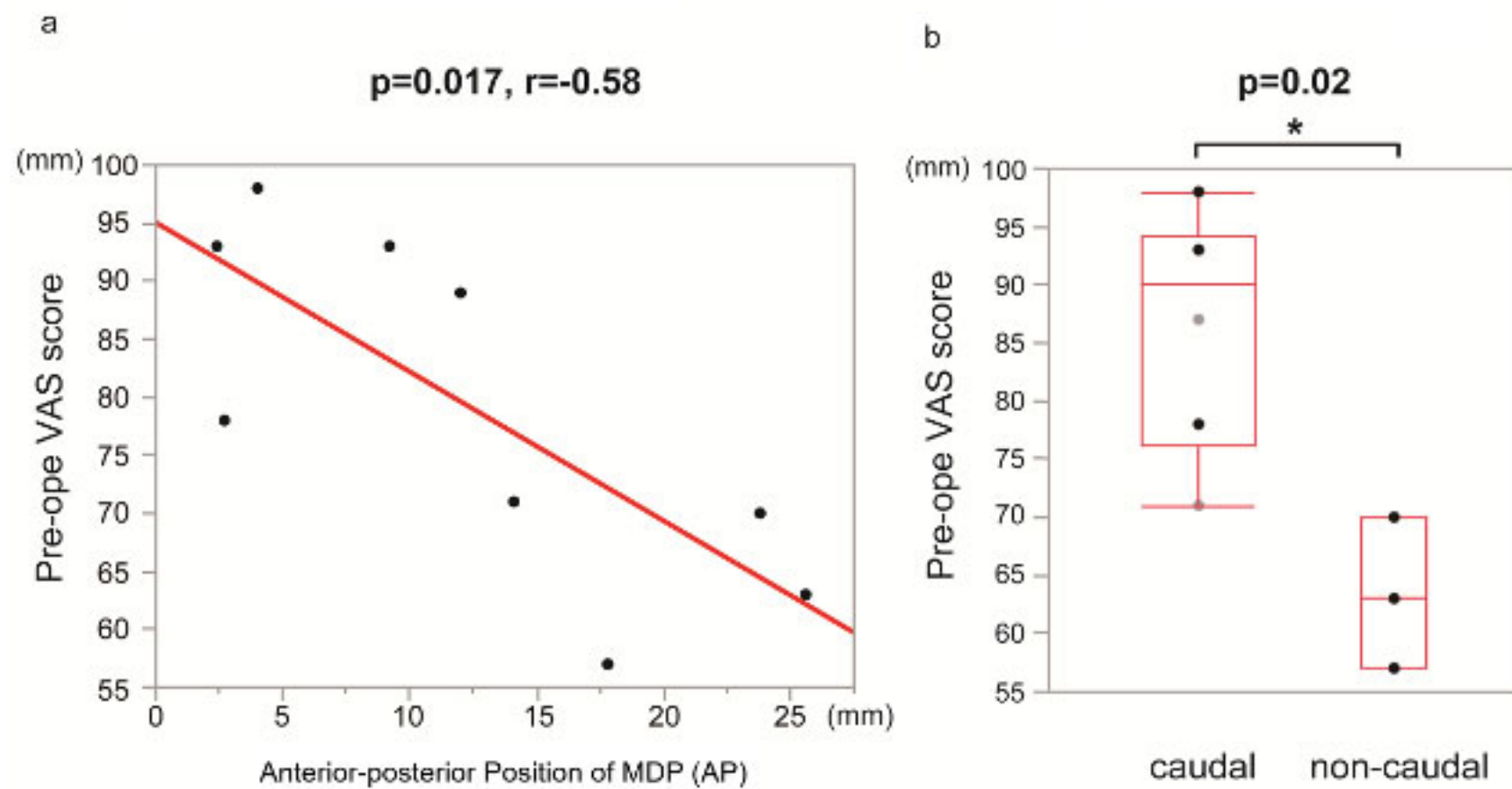
Kimura et al. Figure 3

## The position of MDP

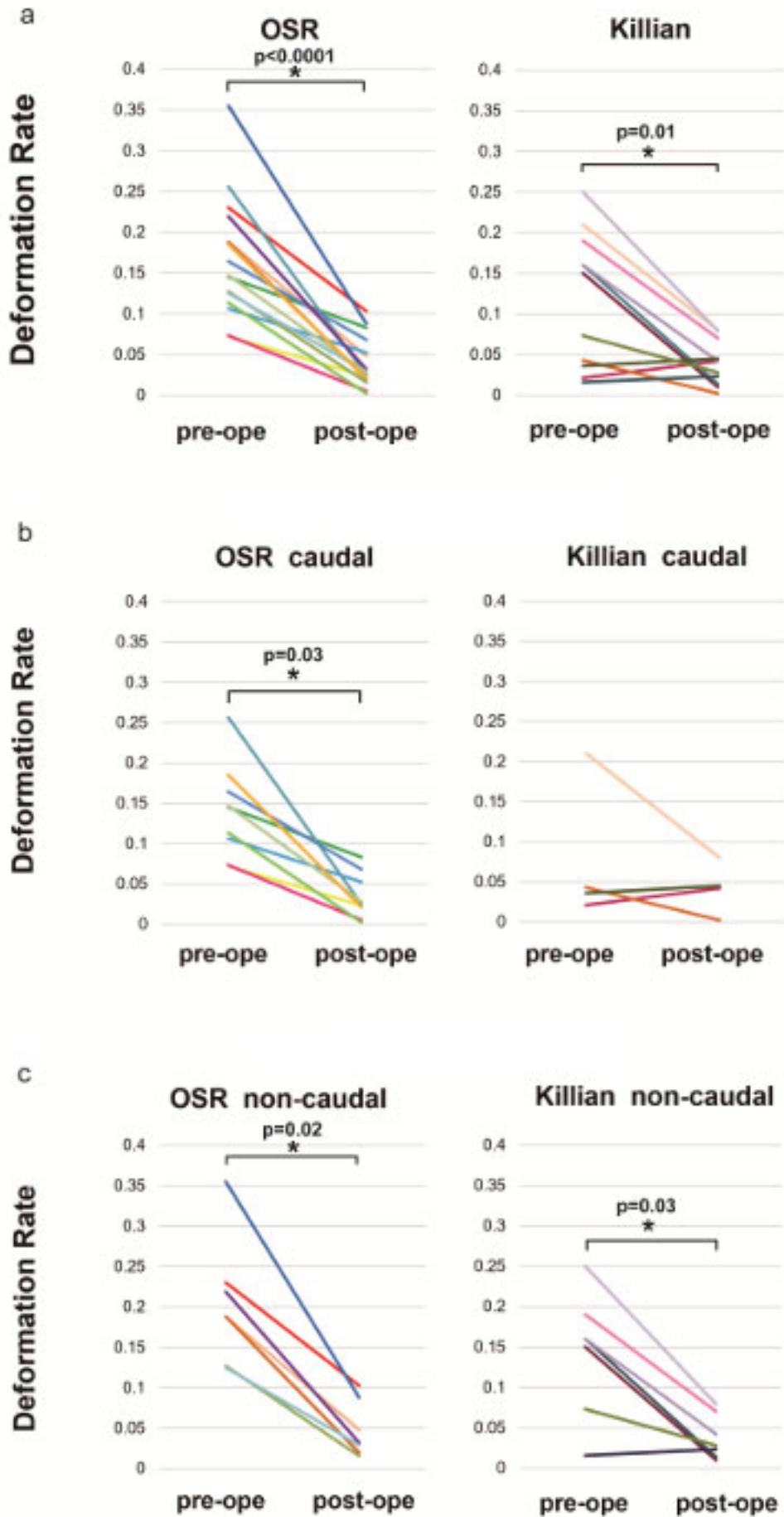




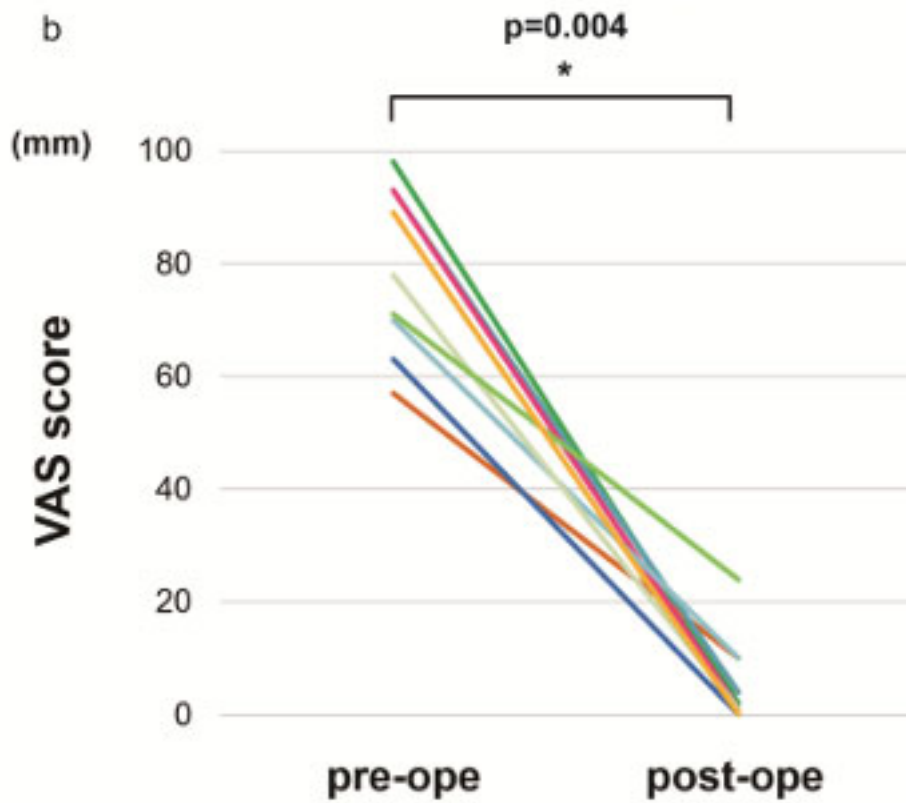
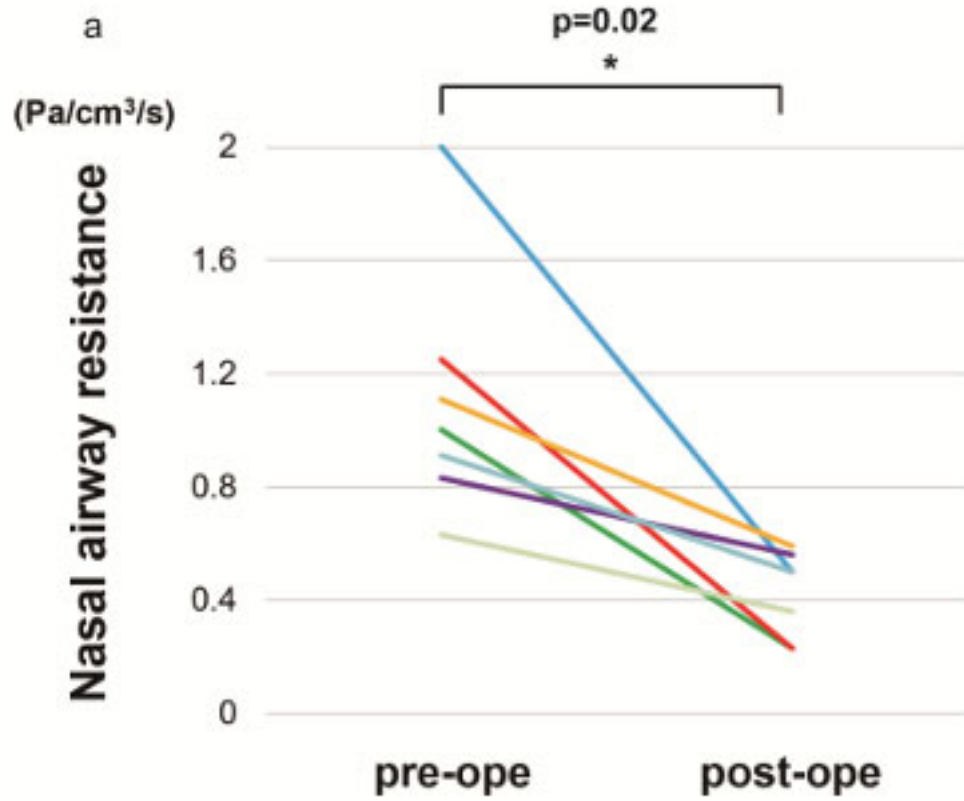
Kimura et al. Figure 4



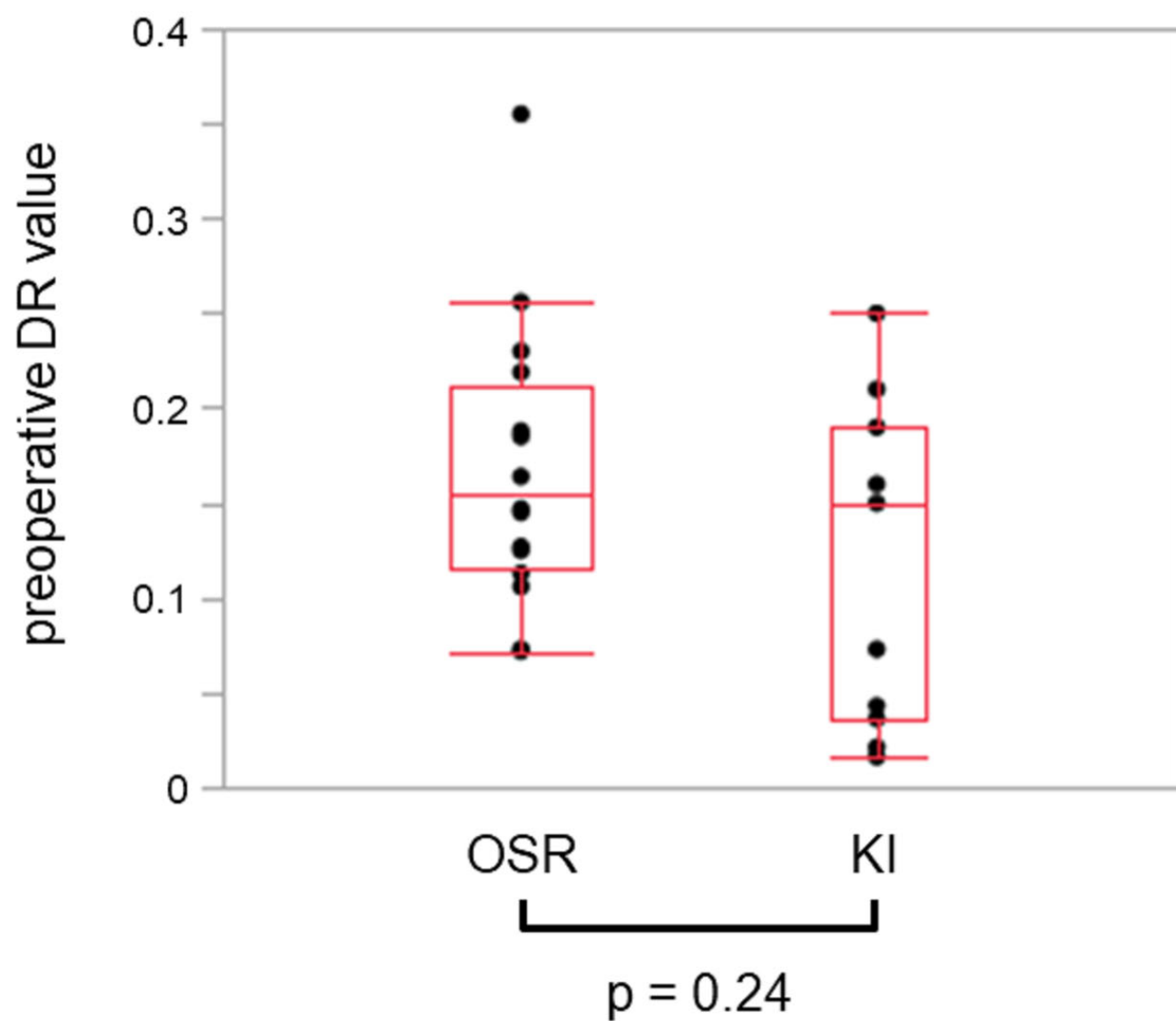
Kimura et al. Figure 5



Kimura et al. Figure 6



Kimura et al. Supplementary figure 1



Kimura et al. Supplementary figure 2

