1 **Clinical utility of superior vena cava flow velocity waveform measured from the subcostal window**

2 **for estimating right atrial pressure[1]**

3 Michito Murayama, MS[a,b], Sanae Kaga, PhD[c]*, Kazunori Okada, PhD[c], Hiroyuki Iwano, MD, PhD[d,e],

4 Masahiro Nakabachi, MS[a], Shinobu Yokoyama[a], Hisao Nishino[a], Shingo Tsujinaga, MD, PhD[d], Yasuyuki

5 Chiba, MD[d], Suguru Ishizaka, MD[d], Ko Motoi, MD[d], Kiwamu Kamiya, MD, PhD[d], Mutsumi Nishida,

6 PhD[a], Toshiyuki Nagai, MD, PhD[d], Toshihisa Anzai, MD, PhD[d]

7 [a] Diagnostic Center for Sonography, Hokkaido University Hospital, N14, W5, Kita-ku, Sapporo 060-8648,

8 Japan

9 [b] Graduate School of Health Sciences, Hokkaido University, N12, W5, Kita-ku, Sapporo 060-0812, Japan

10 [c] Faculty of Health Sciences, Hokkaido University, N12, W5, Kita-ku, Sapporo 060-0812, Japan

11 [d] Department of Cardiovascular Medicine, Faculty of Medicine and Graduate School of Medicine,

12 Hokkaido University, N15, W7, Kita-ku, Sapporo 060-8638, Japan

13 [e] Division of Cardiology, Hakodate Municipal Hospital, 1-10-1, Minatocho, Hakodate 041-8680, Japan

14 ***Corresponding author:**

---

[1] Abbreviations: RAP = Right atrial pressure; IVC = Inferior vena cava; SVC = Superior vena cava; ASE = American Society of Echocardiography; LV = Left ventricular; TR = Tricuspid regurgitation; RV = Right ventricular; Tricuspid E = Peak early-diastolic tricuspid inflow velocity; Tricuspid E/A = Ratio of tricuspid E to peak late-diastolic tricuspid inflow velocity; Tricuspid E/e′ = Ratio of tricuspid E to early-diastolic tricuspid annular velocity; RAP grading = Estimated RAP using IVC parameters according to the ASE guidelines; SVC-S = Peak systolic forward SVC flow; SVC-D = Peak diastolic forward SVC flow; SVC-S/D = Ratio of peak systolic to diastolic forward SVC flows

15 Sanae Kaga, PhD

16 Faculty of Health Sciences, Hokkaido University, N12, W5, Kita-ku, Sapporo 060-0812, Japan; Tel: +81-

17 11-706-3405; Fax: +81-11-706-3405; Email: sanae@med.hokudai.ac.jp

18 **Brief title**: SVC flow from subcostal window for RAP estimation

19

20 **ABSTRACT**

21 **Background**: Superior vena cava (SVC) flow velocity waveform from the supraclavicular window

22 reflects the right atrial pressure (RAP) status. Recent guidelines have stated that the subcostal window is

23 an alternative view for recording SVC flow, but the validity of this approach remains unclear. This study

24 aimed to determine the usefulness of SVC flow evaluation from the subcostal window for estimating RAP.

25 **Methods**: Differences in SVC flow characteristics between opposite approaches were examined in 38

26 healthy adults. In 115 patients with cardiovascular diseases who underwent cardiac catheterization and

27 echocardiography within 48 h, the ratio of peak systolic to diastolic forward SVC flows was measured

28 (SVC-S/D), and the diagnostic ability of SVC-S/D for elevated RAP was tested. A validation cohort was

29 conducted to confirm the diagnostic ability of SVC-S/D in 48 patients who underwent both cardiac

30 catheterization and echocardiography within 24 h. In 59 patients of derivation and validation cohorts, the

31 relationship between SVC flow and RAP was compared between the opposite windows.

32 **Results**: Both systolic and diastolic SVC flow velocities were higher in the subcostal than in the

supraclavicular approach, and effect of position change on the subcostal SVC-S/D was smaller than that on the supraclavicular SVC-S/D in healthy adults. Measurement of SVC-S/D from the subcostal window was feasible in 98 patients (85%). RAP was inversely correlated with SVC-S/D (r=-0.50, P<.001), and was an independent determinant of SVC-S/D after the adjustment for right ventricular systolic function (β=-0.48, P<.001). A cutoff value of 1.9 for SVC-S/D showed 85% sensitivity and 74% specificity in identifying elevated RAP. Additionally, SVC-S/D showed an incremental diagnostic value combined with inferior vena cava size and collapsibility (P=.006). When the cutoff value, SVC-S/D<1.9, was applied to the validation cohort, it showed an acceptable accuracy of 72%, and an incremental diagnostic value combined with inferior vena cava parameters (P=.033). SVC-S/D from the subcostal window correlated better with RAP than that from the supraclavicular window (P<.001, Meng's test).

Conclusions: Measurement of SVC flow velocity from the subcostal window was feasible, and SVC-S/D from the subcostal window could be an additive parameter for estimating RAP.

Key words: echocardiography, right atrial pressure, right atrial pressure estimation, superior vena cava, subcostal approach, supraclavicular approach

48 **INTRODUCTION**

49 Right atrial pressure (RAP) provides important information about right-sided cardiac pressure
50 loading, which is a critical component for optimal patient care.[1] In addition, RAP is the most important
51 hemodynamic factor for systemic congestion,[2-4] and its elevation is an important determinant of poor
52 clinical outcomes in patients with cardiovascular diseases.[2,3,5-9] Echocardiography of the inferior vena cava
53 (IVC) and its respiratory changes is used to non-invasively estimate the RAP .[10] However, previous studies
54 have shown limited accuracy of the IVC indices.[8,11]

55 Several studies have reported that the superior vena cava (SVC) flow velocity waveform
56 evaluated from the right supraclavicular or suprasternal windows reflects the RAP.[12-18] However, the
57 measurement of the SVC flow using this approach is not often used in daily practice, owing to its
58 cumbersome nature. Recently, the use of the subcostal window was recommended in the American
59 Society of Echocardiography (ASE) guidelines,[19] but the validity of the subcostal window approach for
60 recording the SVC flow remains untested. Thus, this study aimed to: (1) investigate the differences in
61 SVC flow characteristics between the subcostal and supraclavicular measurement approaches in healthy
62 volunteers, and (2) evaluate the clinical utility of SVC flow measurement using the subcostal window to
63 estimate RAP in patients with cardiovascular disease.

64 **METHODS**

65 ***Study protocols***

Protocol 1 (basic investigations in healthy volunteers)

We recruited 38 adult healthy volunteers (35±12 years old, men, n=26) who had no clinical and echocardiographic evidence of cardiovascular disease. In this cohort, we investigated the differences in SVC flow characteristics between the subcostal and the right supraclavicular measurement approaches and tested the reproducibility of SVC flow evaluation from both windows.

Protocol 2 (detection of elevated RAP)

Derivation cohort

First, we prospectively enrolled 140 consecutive hospitalized patients who were scheduled for right-heart catheterization and echocardiography within 48 h between February 2018 and October 2020 in Hokkaido University Hospital. All patients underwent a standard echocardiogram performed by a single sonographer (M.M.) at our echocardiography laboratory. There were no patients who needed assistance with ventilation, such as BiPAP, or were intubated and mechanically ventilated. We excluded patients with mechanical circulatory support devices (n=13), those who had undergone a heart transplant (n=10), and those with potential hemodynamic changes (diuretic or vasodilator dose change and dialysis or hemofiltration) between cardiac catheterization and echocardiography (n=2). Ultimately, 115 patients were eligible for SVC flow evaluation for RAP estimation (**Supplemental Figure 1**).

Validation cohort

Second, we prospectively enrolled 67 consecutive adult patients who were scheduled for right-

84 heart catheterization and echocardiography within 24 h between November 2020 and September 2021.
85 Patients were excluded if they met the exclusion criteria mentioned above (n=19). Ultimately, 48 patients
86 were included in the final analysis to validate the SVC flow evaluation for RAP estimation
87 (**Supplemental Figure 1**).

88 In 59 patients of Protocol 2 in whom the acquisition of SVC flow from both right supraclavicular
89 and subcostal windows was successful, the relationship between the SVC flow and invasive RAP was
90 compared from two opposite windows (supraclavicular vs subcostal) as a sub-analysis.

91 Protocol 1 was approved by the Ethics Committee of the Faculty of Health Sciences in Hokkaido
92 University, and all volunteers provided written informed consent. Protocol 2 was approved by the
93 Institutional Review Board of Hokkaido University Hospital (No. 019-0190). Since all examinations were
94 performed within the scope of medical care, an opportunity to opt-out was given to each participant
95 through a published disclosure document on the website of the institute and the requirement for informed
96 consent was waived.

97 ***Echocardiography***

98 Transthoracic echocardiography was performed using commercially available ultrasound
99 machines: an Artida system equipped with a 3.0 MHz probe (Canon Medical Systems, Otawara, Japan); a
100 Vivid E9 ultrasound system with an M5S probe (GE Healthcare, Chicago, Illinois, USA); an iE33
101 ultrasound system with an S5-1 probe (Philips Medical Systems, Andover, Massachusetts, USA); an

ACUSON SC2000 prime with a 4V1c probe (Siemens Healthineers, Erlangen, Germany); or a Prosound F-75 system with a 2.5 MHz probe (Hitachi Ltd., Tokyo, Japan). A comprehensive echocardiographic examination was performed in line with the ASE guidelines to evaluate the cardiac chamber morphology and left ventricular (LV) function.[20] The severity of valve regurgitation was determined according to the guidelines,[21] and significant tricuspid regurgitation (TR) was defined as more than moderate TR.[21] Right heart measurements were also performed according to the published ASE guidelines.[10] Basal right ventricular (RV) and mid-cavity diameter were measured at end diastole using RV-focused views, and RV systolic function was assessed based on tricuspid annular plane systolic excursion, systolic excursion velocity, and fractional area change. The ratio of peak early-diastolic tricuspid inflow velocity (tricuspid E) to peak late-diastolic tricuspid inflow velocity (tricuspid E/A) was measured using the RV modified apical four-chamber view, along with the early-diastolic peak of tricuspid annulus velocity; the ratio of tricuspid E to the tricuspid annulus velocity (tricuspid E/e′) was consequently calculated. The hepatic vein systolic filling fraction was calculated as the peak systolic wave velocity divided by the sum of peak systolic and diastolic velocities. Maximum right atrial area was measured at ventricular end systole in the apical four-chamber view. The IVC dimension and IVC respiratory changes were measured using the subcostal longitudinal image. We estimated the RAP as normal (3 mmHg) when the IVC diameter was ≤21 mm and collapsed >50%, and as high (15 mmHg) when the IVC diameter was >21 mm and collapsed <50% in line with the ASE guidelines (RAP grading).[10] In the cases where the IVC diameter and collapse

120 did not fit these criteria, RAP was classified as intermediate (8 mmHg).[10]

121 The SVC flow velocity waveform was recorded by pulsed-wave Doppler images from the
122 subcostal long-axis view (**Figure 1A**) or subcostal four-chamber view (**Figure 1B**) with the angle of the
123 transducer towards the head, and the patients in a supine position.[19] A 3- to 5-mm sample volume was
124 placed about 10 mm proximal to the junction of the right atrium and SVC. The peak systolic and diastolic
125 forward velocities of SVC flows (SVC-S and SVC-D, respectively) and the SVC-S/D ratio were measured
126 using the waveforms. For quantitative purposes, systolic flow reversal was assigned as SVC-S of 0 cm/s,
127 and SVC-S/D was calculated as 0 in line with the previous report.[22] In Protocol 1, the SVC flow was also
128 recorded from the right supraclavicular approach according to previous reports,[12,13,23] in the 45-degree
129 semi-sitting and supine positions. Echocardiographic data were acquired during a breath-hold at shallow
130 expiration or at the intermediate expiratory position under quiet respiration except for the IVC parameters.
131 In patients with atrial fibrillation, Doppler parameters were obtained from an index beat in which
132 preceding and pre-preceding RR intervals were similar.[24]

133 ***Cardiac catheterization***

134 Right-heart catheterization procedures were performed by trained physicians using 6F fluid-
135 filled balloon-tipped catheters. After calibration with the zero point at the mid-thoracic line, the catheters
136 were inserted through the internal jugular vein or the common femoral vein, and the waveforms for
137 pulmonary arterial wedge pressure, main pulmonary arterial pressure, and RAP were recorded at end

138 expiration. The cardiac output was measured using Fick's method in patients with severe TR or by the
139 thermodilution method in those without TR. Pulmonary vascular resistance was calculated as (mean
140 pulmonary arterial pressure − mean pulmonary arterial wedge pressure)/cardiac output. All measurements
141 were obtained from three consecutive beats and the averaged values were used for final analysis. An
142 elevated RAP was defined as a mean RAP of >8 mmHg.[2,13,22]

143 ***Statistical analysis***

144 Continuous data were expressed as mean ± standard deviation or median (interquartile range) as
145 appropriate. Student's t-test or Wilcoxon rank-sum test was used to compare continuous variables between
146 the two groups. Categorical variables were presented as numbers (%) and compared using the Chi-square
147 test or Fisher exact test, as appropriate. Parametric one-way analysis of variance with the Tukey-Kramer
148 post hoc test was used for comparisons of catheterization-derived RAP among the different RAP grading.
149 Relationships between two continuous variables were assessed by the linear correlation and regression
150 analysis. A receiver operating characteristic curve analysis was performed to evaluate the ability to predict
151 the elevation of the invasive RAP. Multiple linear regression analysis was used for assessing the
152 associations between the SVC-S/D and invasive RAP after adjustment for several confounders, which
153 were previously reported to influence the SVC and hepatic venous flow patterns.[14,27] Parameters with
154 P<.05 in the univariable analysis were incorporated into the multivariable model to detect independent
155 determinants of SVC-S/D. The performance of the RAP grading according to the ASE guidelines in

combination with the SVC flow in predicting elevated RAP was assessed using the c-index. Interobserver acquisition variability for SVC flow was assessed in the healthy volunteers in Protocol 1, and an intraclass correlation analysis was performed for interobserver comparison. All statistical analyses were conducted using JMP Pro 14.0.0 (SAS Institute Inc., Cary, NC, USA), and statistical significance was set at a P-value <.05.

RESULTS

Basic investigations in healthy volunteers

Difference between the subcostal and the right supraclavicular approaches

Of the 38 healthy volunteers, measurement of the SVC flow velocity was feasible in 32 subjects (84%) from the subcostal window and in all subjects (100%) from the right supraclavicular window. The supine SVC-S and D waves at expiration were significantly larger in the subcostal approach than in the supraclavicular approach (S: 57.8±14.2 vs. 41.5±9.8 cm/s, P<.001; D: 31.5±9.0 vs. 23.2±5.9 cm/s, P<.001, respectively), whereas S/D was similar in both approaches (1.9±0.7 vs. 1.9±0.7, P=.726). Although there was a significant increase in SVC-S and D in the semi-sitting position than in the supine position in the subcostal approach, S/D was not significantly affected by the position. Contrarily, in the supraclavicular approach, the semi-sitting position significantly increased the SVC-S and D, with a decreased S/D compared to that in the supine position (**Supplemental Table 1**). A representative case is shown in **Supplemental Figure 2**.

174 ***Reproducibility of SVC flow acquisition from subcostal and the right supraclavicular windows***

175 Re-acquisition variability was tested by two observers (M.M. [>5 years' experience] and S.M.
176 [beginner]) in the initial 18 participants of Protocol 1. In the subcostal approach, interobserver variability
177 for SVC-S, D, and S/D showed good intraclass correlation coefficients of 0.85, 0.91, and 0.84,
178 respectively, indicating satisfactory reproducibility of the measurement of SVC flow from the subcostal
179 window. The supraclavicular approach also showed adequate intraclass correlation coefficients of 0.78,
180 0.68, and 0.80 for SVC-S, D, and S/D, respectively, but the reproducibility of SVC flow measurement was
181 better in the subcostal approach.

182 **Detection of elevated RAP**

183 ***Derivation cohort***

184 ***Patient characteristics***

185 Of 115 patients who met the inclusion criteria, measurement of the SVC-S/D was feasible in 98
186 patients (85%). The characteristics of 17 patients in whom SVC flow could not be measured from the
187 subcostal approach are summarized in **Supplemental Table 2**. These 17 patients were characterized as
188 more frequently having the lowest quartile of body mass index (≤20 kg/m^2) and higher prevalence of atrial
189 fibrillation. The comparison between patients with normal and those with elevated RAP is presented in
190 **Table 1**. Among the 98 participants, the mean age was 64 years, and half of the patients were men.
191 Nonischemic dilated cardiomyopathy was the most frequently occurring cardiac disease, and one-third of

192 the patients presented with NYHA functional class III or IV. Pulmonary hypertension (mean pulmonary
193 arterial pressure >20 mmHg) was observed in 48 subjects (49%) and 35–38% of the cohort showed right
194 heart abnormalities detected based on a reduced fractional area change or enlarged RV. Significant TR was
195 observed in 17 patients (17%).

196 The mean RAP was 6.0±2.3 mmHg (range: 1–22 mmHg) and 20 patients (20%) showed elevated
197 RAP. More significant advanced remodeling of the right heart was observed in the elevated RAP group
198 than that in the normal RAP group (**Table 1**). While the RV systolic function was similar between the
199 groups, the elevated RAP group had a higher tricuspid E/A, larger IVC diameter, and a lower IVC
200 respiratory changes, resulting in the higher prevalence of high RAP estimated using the IVC findings.
201 According to the SVC flow parameters, the elevated RAP group had a significantly lower SVC-S, higher
202 SVC-D, and lower SVC-S/D than those in the normal RAP group.

203 ***Prediction of elevated RAP***

204 **Supplemental Figure 3** illustrates the comparison of invasive RAP among the patients classified
205 by the ASE guidelines.[10] Although the RAP was significantly higher in patients classified as elevated RAP
206 than those in other two grades; it was comparable in patients classified as normal or intermediate RAP.
207 Guideline-pre-specified elevated RAP findings predicted an invasive RAP of >8 mmHg with 40%
208 sensitivity, 97% specificity, 80% positive predictive value, 86% negative predictive value, and 86%
209 accuracy.

210 As shown in **Figure 2A**, the SVC-S/D was inversely correlated with invasive RAP (r=−0.50,
211 P<.001). Moreover, invasive RAP was an independent determinant of SVC-S/D even after adjustment for
212 potential confounders, including atrial fibrillation, RV systolic function, right atrial size, and significant
213 TR (β=−0.48, P<.001) (**Table 2**). An optimal cut-off value of 1.9 to identify the patients with an elevated
214 RAP was identified by receiver operating characteristic analysis. This cut off value yielded a c-index for
215 SVC-S/D of 0.84 (95% confidence interval [CI]: 0.76–0.93) and had 85% sensitivity, 74% specificity,
216 46% positive predictive value, 95% negative predictive value, and 77% accuracy (Figure 2B).

217 ***Incremental diagnostic value of SVC- S/D over the guideline-recommended RAP grading***

218 When an SVC-S/D of <1.9 was used in 49 patients whose RAP was graded as indeterminate by
219 the ASE guidelines, it could identify a subgroup of patients with elevated RAP with a sensitivity,
220 specificity, positive predictive value, negative predictive value, and accuracy of 63%, 78%, 36%, 91%,
221 and 76%, respectively. The SVC-S/D showed an incremental diagnostic value when combined with RAP
222 grading (c-index=0.72, 95% CI: 0.58–0.84 for RAP grading only, and c-index=0.86, 95% CI: 0.75–0.92
223 for RAP grading plus SVC-S/D, P=.006) (**Figure 3**).

224 ***Validation cohort***

225 Of 48 patients who met the inclusion criteria, measurement of the SVC-S/D was feasible in 43
226 patients (90%). Among the 43 patients, one-third of the patients presented with NYHA functional class III,
227 and no patients presented with NYHA functional class IV. The mean RAP was 5.7±3.3 mmHg (range 1–14

mmHg) and 8 patients (19%) showed elevated RAP. As shown in **Supplemental Figure 4**, the SVC-S/D ratio was inversely correlated with invasive RAP (r=−0.60, P<.001). When the SVC-S/D <1.9 performance for RAP elevation identification was tested in the validation cohort, it could identify a subgroup of patients with elevated RAP with a sensitivity, specificity, positive predictive value, negative predictive value, and accuracy of 100%, 66%, 40%, 100%, and 72%, respectively. Additionally, when the SVC-S/D was added to the RAP grading, the diagnostic value was significantly improved (**Supplemental Figure 5**).

Relationship between the SVC-S/D from the subcostal window and invasive RAP, in comparison with the right supraclavicular window

The association between SVC-S/D from both windows and invasive RAP was compared in 59 of Protocol 2 participants. Representative images of SVC flow and corresponding RAP waveforms are shown in **Figure 4.** As shown in **Figure 5**, the invasive RAP was more strongly correlated with SVC-S/D evaluated from the subcostal window than that evaluated from the supraclavicular window (r=−0.64, P<.001 vs. r=−0.28, P=.029; P<.001 by Meng's test).

DISCUSSION

Our findings can be summarized as follows: (i) the measurement of SVC flow velocities from the subcostal window was feasible, (ii) the effect of position change on the SVC-S/D ratio was less significant in the subcostal approach than in the supraclavicular approach, (iii) SVC-S/D ratio from the

246 subcostal window was inversely correlated with invasive RAP, (iv) evaluating the SVC-S/D ratio from the
247 subcostal window improved the diagnostic accuracy for RAP elevation when combined with guideline-
248 recommended RAP grading, and (v) the SVC-S/D ratio from the subcostal window correlated better with
249 RAP than that from the supraclavicular window, which is known as a conventional approach for
250 evaluating SVC flow. To the best of our knowledge, this is the first study to investigate the clinical utility
251 of SVC flow evaluated from the subcostal window. Our findings strengthen the clinical relevance of SVC
252 Doppler velocimetry in patients with cardiovascular diseases.

253 ***Echocardiographic estimation of elevated RAP***

254 Sonographic measurement of the diameter and respiratory changes in the IVC is a commonly
255 used noninvasive method for the estimation of RAP, and the current ASE guidelines recommend the
256 algorithm for categorizing RAP[10]; however, several studies reported that the RAP estimated using this
257 algorithm does not always match the invasive RAP.[8,11] Evaluation of the restrictive right-sided diastolic
258 filling pattern, tricuspid E/e′ >6, and diastolic flow predominance in the hepatic veins are recommended in
259 the cases where RAP remains indeterminate.[10] However, the diagnostic accuracy of the tricuspid E/A and
260 E/e′ for elevated RAP was limited,[25,26] possibly due to differences in the physiologic mechanism of e′ or E
261 between the left and right hearts, that is, absence of correlation between tricuspid e′ and RV relaxation and
262 the poor correlation between tricuspid E-wave velocity and RAP event after controlling for RV
263 relaxation.[25] The hepatic vein systolic filling fraction is considered to reflect the changes in RAP during a

264 cardiac cycle similar to that of SVC-S/D,[10,22] but previous studies failed to demonstrate its predictive value
265 for RAP.[25] This could be due to changes in hepatic vein flow associated with parenchymal fibrosis in
266 patients with organic hepatic disorders.[28] Incorporation of these secondary indices to refine RAP estimates
267 did not improve IVC measurement precision.[11,25] Therefore, further investigation is required for more
268 reliable and feasible RAP estimation methods.

269 ***SVC flow velocity waveform and RAP***

270 The SVC flow velocities reflect changes in RAP waveforms.[12-18] At low or normal RAP, the flow
271 profile in the SVC is biphasic with a systolic dominance.[12-15] In cases of elevated RAP, the observed SVC
272 flow profile is a diminished systolic flow velocity with a predominant diastolic forward flow.[13,15,18] The
273 flow velocity of SVC is usually recorded from the supraclavicular approach; however, the ASE recently
274 proposed using the subcostal window for SVC flow evaluation.[19] However, there is a paucity of data
275 regarding the clinical utility of SVC flow evaluation from a subcostal window; its association with
276 invasive RAP has not been validated. In the current study, we found that it was feasible to evaluate SVC
277 flow from the subcostal window, which was associated with the invasive RAP. Notably, patients with an
278 SVC-S/D <1.9 were observed to have an abnormally elevated RAP with acceptable accuracy. Based on its
279 ability to enhance the diagnostic accuracy of RAP grading (**Figure 3 and Supplemental Figure 5**),
280 subcostal SVC-S/D is a reliable marker for abnormal RAP, especially in patients with indeterminate RAP
281 based on IVC parameters.

282 ***Superiority of the subcostal approach over the supraclavicular approach***

283 We observed that the SVC flow velocities in healthy individuals were higher in the subcostal
284 approach than in the supraclavicular approach, which indicated a better Doppler incident angle in the
285 subcostal approach, because of the greater flexibility in probe position and scanning angles and evaluation
286 in two mutually orthogonal planes. Additionally, in the subcostal approach, the SVC flow may be recorded
287 after the confluence of the left innominate vein and the azygos vein, which is the only major tributary vein
288 that drains into the SVC,[17] resulting in a larger amount of blood for evaluation. Interestingly, our data
289 showed that SVC-S/D evaluation from the subcostal window correlated better with the invasive RAP than
290 that from the supraclavicular window (**Figure 5**). This may be because the sampling position was closer to
291 the right atrium in the subcostal approach than the supraclavicular approach. A previous study
292 demonstrated that central venous pressure measured within the femoral vein, which is farther away from
293 the right atrium, is less reliable.[29] Thus, we speculated that SVC flow recorded from the subcostal window,
294 which is closer to the right atrial, could more accurately reflect the RAP waveforms (**Supplemental**
295 **Figure 6**). Another explanation could be the better reproducibility of the SVC flow acquisition from the
296 subcostal window compared to the right supraclavicular window as shown in the result of Protocol 1,
297 probably because the sampling position is easily and adequately visualized in the subcostal view.
298 Moreover, the effect of position change on the SVC flow velocities was less significant in the subcostal
299 approach than in the supraclavicular approach (**Supplemental Table 1 and Supplemental Figure 2**).

300 Although we could not find any clear explanation, this might have a practical advantage of using subcostal
301 SVC-S/D for RAP estimation in every clinical setting, for example, in Fowler's position in cases of acute
302 decompensated heart failure showing orthopnea. Further studies are necessary to understand the
303 pathophysiological mechanisms of the SVC flow in postural changes.

304 ***Clinical applications***

305 Our findings showed that the use of SVC flow measurement from the subcostal window
306 improved the diagnostic accuracy of the RAP grading recommended by the ASE guidelines. Incorporating
307 these SVC flow measurements into routine echocardiographic evaluation requires minimal additional
308 effort and time; sonographers can measure the IVC indices from the subcostal window, and subsequently,
309 the SVC flow velocities can be measured by tilting the probe towards the head. Our data showed that the
310 SVC flow had an excellent negative predictive value; hence, the use of SVC flow may be an alternative to
311 IVC parameters for RAP estimation in individuals in whom the IVC appears enlarged despite low RAP.[1]
312 In practice, SVC flow evaluation from the subcostal window may have additional diagnostic implications
313 in patients with indeterminate RAP results based on IVC findings.

314 ***Study limitations***

315 There are several limitations in this study. First, the sample size was small, especially for
316 advanced heart failure patients showing high RAP (the number of patients with RAP greater than 10
317 mmHg was small: only 16 (16%) patients in the derivation cohort and 6 (14%) patients in the validation

318 cohort), thereby limiting the generalizability of the findings. Further study including a wider range of RAP
319 is needed. Second, cardiac catheterization and echocardiography were not performed simultaneously. In
320 the derivation cohort, no difference was found in the heart rate (69.2±11.1 vs. 68.3±10.7 beats/min,
321 p=0.261), systolic blood pressure (109.6±16.7 vs. 112.1±18.4 mmHg, p=0.176), diastolic blood pressure
322 (63.6±12.0 vs. 65.4±11.9 mmHg, p=0.144), and the body weight (57.4±11.1 vs. 57.3±11.0 kg, p=0.232)
323 between echocardiography and right-heart catheterization. Also, in the validation cohort, there were no
324 differences in the heart rate (67.7±9.3 vs. 67.5±10.3 beats/min, p=0.846), systolic blood pressure
325 (113.9±19.7 vs. 113.0±20.5 mmHg, p=0.744), diastolic blood pressure (64.9±13.5 vs. 64.1±13.4 mmHg,
326 p=0.728), and the body weight (58.5±15.5 vs. 58.4±15.4 kg, p=0.383) between echocardiography and
327 right-heart catheterization. However, the possibility of hemodynamic alteration might not be completely
328 excluded. Third, in patients with atrial fibrillation, the application of subcostal SVC flow for evaluating
329 RAP might be limited because feasibility was not high enough in such individuals (**Supplemental Table**
330 **2**). Moreover, atrial fibrillation was a strong independent determinant of the SVC-S/D ratio (**Table 2**). In
331 patients with atrial fibrillation, one needs to interpret our findings with caution, since it is based on a small
332 number of the patients. Fourth, because in the present study there were no patients who needed assistance
333 with ventilation such as BiPAP or mechanical ventilation via intubation, it remains unknown whether the
334 subcostal SVC flow could be applicable in such patients. Fifth, because the present study was conducted
335 in Asian subjects who had a relatively low body mass index (23 ± 3, 16 to 31 kg/m^2 in analyzed 98

336 patients from the derivation cohort; 23 ± 5, 14 to 34 kg/m^2 in analyzed 43 patients from the validation
337 cohort), it might affect generalizability when applied to patients with larger body size. Further
338 investigation involving a subset of patients with an elevated body mass index is necessary to validate the
339 clinical utility of SVC flow evaluation from the subcostal window and compare its diagnostic accuracy
340 with that from the supraclavicular window for RAP estimation.

341 **CONCLUSIONS**

342 Evaluation of SVC flow from the subcostal window could be useful to identify elevated RAP.
343 Importantly, a combined index using IVC parameter measurements and SVC flow evaluation from the
344 subcostal window may enable an accurate assessment of RAP. The SVC flow profile provides additional
345 diagnostic insights into the quantification of RAP.

346

347 **Acknowledgments:** We greatly appreciate Sana Maedomari, BS, for cooperation with Protocol 1. We also
348 acknowledge Ryosuke Fujisawa, MS, Miho Aiba, MS, Mio Shinkawa, BS, and Airi Onoda, BS, for their
349 contributions in data collection. We thank Asuka Tanemura, BS, Dr. Yoji Tamaki, Dr. Hiroyuki Aoyagi in
350 the echocardiography laboratory at Hokkaido University Hospital for supporting this project, and thank
351 Taisei Mikami, MD, Ph.D., for advice on the discussion section. We would also like to thank Editage
352 (www.editage.com) for English language editing.

353 **Funding**: This research did not receive any specific grant from funding agencies in the public,

354 commercial, or not-for-profit sectors.

355 **Declarations of Interest:** None

356 **Author Contributions:** MM, SK and KO designed the study. MM acquired the echocardiographic data.
357 MM and SK drafted the manuscript. MM, MN, SY, HN, ST, YC, SI, KO, and MN collected the
358 echocardiographic and demographic data. SK, KO, HI, MN, SY, HN, ST, YC, SI, KO, KK, MN, TN, and
359 TA supported the statistical analysis and counseled about the discussion section. MM, SK, KO, HI, MN,
360 SY, HN, and MN participated in the interpretation of the results regarding echocardiography. HI, ST, YC,
361 SI, KO, KK, TN, and TA collected the catheterization data and contributed to the interpretation of the
362 results. HI, KK, MN, TN, and TA advised on methodological consideration, provided guidance about main
363 thesis, revised the manuscript critically for important intellectual content and finally approved submission
364 of the manuscript. All authors have read and approved the final manuscript.

365

366 **REFERENCES**

367 1. Beigel R, Cercek B, Luo H, Siegel RJ. Noninvasive evaluation of right atrial pressure. J Am Soc
368 Echocardiogr 2013;26:1033-42.

369 2. Mullens W, Abrahams Z, Francis GS, Sokos G, Taylor DO, Starling RC, et al. Importance of venous
370 congestion for worsening of renal function in advanced decompensated heart failure. J Am Coll Cardiol
371 2009;53:589-96.

372 3. Damman K, van Deursen VM, Navis G, Voors AA, van Veldhuisen DJ, Hillege HL. Increased central
373 venous pressure is associated with impaired renal function and mortality in a broad spectrum of patients
374 with cardiovascular disease. J Am Coll Cardiol 2009;53:582-8.
375 4. Xanthopoulos A, Starling RC, Kitai T, Triposkiadis F. Heart failure and liver disease: cardiohepatic
376 interactions. JACC Heart Fail 2019;7:87-97.
377 5. Drazner MH, Rame JE, Stevenson LW, Dries DL. Prognostic importance of elevated jugular venous
378 pressure and a third heart sound in patients with heart failure. N Engl J Med 2001;345:574-81.
379 6. Uthoff H, Thalhammer C, Potocki M, Reichlin T, Noveanu M, Aschwanden M, et al. Central venous
380 pressure at emergency room presentation predicts cardiac rehospitalization in patients with decompensated
381 heart failure. Eur J Heart Fail 2010;12:469-76.
382 7. Benza RL, Miller DP, Gomberg-Maitland M, Frantz RP, Foreman AJ, Coffey CS, et al. Predicting
383 survival in pulmonary arterial hypertension: insights from the Registry to Evaluate Early and Long-Term
384 Pulmonary Arterial Hypertension Disease Management (REVEAL). Circulation 2010;122:164-72.
385 8. Austin C, Alassas K, Burger C, Safford R, Pagan R, Duello K, et al. Echocardiographic assessment of
386 estimated right atrial pressure and size predicts mortality in pulmonary arterial hypertension. Chest
387 2015;147:198-208.
388 9. Pellicori P, Shah P, Cuthbert J, Urbinati A, Zhang J, Kallvikbacka-Bennett A, et al. Prevalence, pattern
389 and clinical relevance of ultrasound indices of congestion in outpatients with heart failure. Eur J Heart Fail

390 2019;21:904-16.

391 10. Rudski LG, Lai WW, Afilalo J, Hua L, Handschumacher MD, Chandrasekaran K, et al. Guidelines for

392 the echocardiographic assessment of the right heart in adults: a report from the American Society of

393 Echocardiography endorsed by the European Association of Echocardiography, a registered branch of the

394 European Society of Cardiology, and the Canadian Society of Echocardiography. J Am Soc Echocardiogr

395 2010;23:685-713.

396 11. Magnino C, Omede P, Avenatti E, Presutti D, Iannaccone A, Chiarlo M, et al. Inaccuracy of right atrial

397 pressure estimates through inferior vena cava indices. Am J Cardiol 2017;120:1667-73.

398 12. Appleton CP, Hatle LK, Popp RL. Superior vena cava and hepatic vein Doppler echocardiography in

399 healthy adults. J Am Coll Cardiol 1987;10:1032-9.

400 13. Ghio S, Recusani F, Sebastiani R, Klersy C, Raineri C, Campana C, et al. Doppler velocimetry in

401 superior vena cava provides useful information on the right circulatory function in patients with

402 congestive heart failure. Echocardiography 2001;18:469-77.

403 14. Klein AL, Leung DY, Murray RD, Urban LH, Bailey KR, Tajik AJ. Effects of age and physiologic

404 variables on right ventricular filling dynamics in normal subjects. Am J Cardiol 1999;84:440-8.

405 15. Jia HP, Duan YY, Cao TS, Yuan LJ, Li J. The characteristics of the spectra of superior venae cavae in

406 patients with right heart failure. Cardiovasc Ultrasound 2006;4:21.

407 16. Wexler L, Bergel DH, Gabe IT, Makin GS, Mills CJ. Velocity of blood flow in normal human venae

408 cavae. Circ Res 1968;23:349-59.

409 17. Khouzam RN, Minderman D, D'Cruz IA. Echocardiography of the superior vena cava. Clin Cardiol

410 2005;28:362-6.

411 18. Klein AL, Hatle LK, Burstow DJ, Taliercio CP, Seward JB, Kyle RA, et al. Comprehensive Doppler

412 assessment of right ventricular diastolic function in cardiac amyloidosis. J Am Coll Cardiol 1990;15:99-

413 108.

414 19. Mitchell C, Rahko PS, Blauwet LA, Canaday B, Finstuen JA, Foster MC, et al. Guidelines for

415 performing a comprehensive transthoracic echocardiographic examination in adults: recommendations

416 from the American Society of Echocardiography. J Am Soc Echocardiogr 2019;32:1-64.

417 20. Lang RM, Badano LP, Mor-Avi V, Afilalo J, Armstrong A, Ernande L, et al. Recommendations for

418 cardiac chamber quantification by echocardiography in adults: an update from the American Society of

419 Echocardiography and the European Association of Cardiovascular Imaging. J Am Soc Echocardiogr

420 2015;28:1-39.

421 21. Zoghbi WA, Adams D, Bonow RO, Enriquez-Sarano M, Foster E, Grayburn PA, et al.

422 Recommendations for noninvasive evaluation of native valvular regurgitation: a report from the American

423 Society of Echocardiography developed in collaboration with the Society for Cardiovascular Magnetic

424 Resonance. J Am Soc Echocardiogr 2017;30:303-71.

425 22. Nagueh SF, Kopelen HA, Zoghbi WA. Relation of mean right atrial pressure to echocardiographic and

426 Doppler parameters of right atrial and right ventricular function. Circulation 1996;93:1160-9.

427 23. Reynolds T, Appleton CP. Doppler flow velocity patterns of the superior vena cava, inferior vena cava,

428 hepatic vein, coronary sinus, and atrial septal defect: a guide for the echocardiographer. J Am Soc

429 Echocardiogr 1991;4:503-12.

430 24. Torii Y, Kusunose K, Yamada H, Nishio S, Hirata Y, Amano R, et al. Updated left ventricular diastolic

431 function recommendations and cardiovascular events in patients with heart failure hospitalization. J Am

432 Soc Echocardiogr 2019;32:1286-97.

433 25. Tsutsui RS, Borowski A, Tang WH, Thomas JD, Popović ZB. Precision of echocardiographic

434 estimates of right atrial pressure in patients with acute decompensated heart failure. J Am Soc

435 Echocardiogr 2014;27:1072-8.

436 26. Patel AR, Alsheikh-Ali AA, Mukherjee J, Evangelista A, Quraini D, Ordway LJ, et al. 3D

437 echocardiography to evaluate right atrial pressure in acutely decompensated heart failure correlation with

438 invasive hemodynamics. JACC Cardiovasc Imaging 2011;4:938-45.

439 27. Fadel BM, Husain A, Alassoussi N, Dahdouh Z, Mohty D. Spectral Doppler of the hepatic veins in

440 pulmonary hypertension. Echocardiography 2015;32:170-3.

441 28. Soroida Y, Nakatsuka T, Sato M, Nakagawa H, Tanaka M, Yamauchi N, et al. A novel non-invasive

442 method for predicting liver fibrosis by quantifying the hepatic vein waveform. Ultrasound Med Biol

443 2019;45:2363-71.

29. Walsh JT, Hildick-Smith DJ, Newell SA, Lowe MD, Satchithananda DK, Shapiro LM. Comparison of central venous and inferior vena caval pressures. Am J Cardiol 2000;85:518-20.

FIGURE LEGENDS

Figure 1. Pulsed-wave Doppler measurements of SVC flow velocity waveform from the subcostal window

SVC flow velocity waveform was recorded from the subcostal long-axis view (A) or subcostal four-chamber view (B) with the angle of the transducer towards the head with the patients in a supine position. A 3- to 5-mm sample volume was placed approximately10 mm proximal to the junction of the RA and SVC. From the waveforms, the peak systolic and diastolic forward SVC flows (SVC-S and SVC-D, respectively) and SVC-S/D ratio were measured. IVC = inferior vena cava; SVC = superior vena cava; RA = right atrium; RV = right ventricle.

Figure 2. Correlation of SVC-S/D ratio with invasive RAP and receiver operating characteristic curve for the SVC-S/D ratio to detect RAP >8 mmHg in the derivation cohort

RAP = right atrial pressure; other abbreviations as in Figure 1.

Figure 3. Incremental diagnostic value of the SVC-S/D ratio to the RAP grading according to the guidelines for detecting elevated RAP in the derivation cohort

To test the incremental diagnostic ability of the SVC-S/D ratio to the established guidelines, two models

462 (model 1: RAP grading alone; model 2: model 1 plus SVC-S/D) were constructed and compared using
463 receiver operating curve analysis. CI = confidence interval; other abbreviations as in Figures 1 and 2.

464 **Figure 4. Examples of SVC flow from supraclavicular (*top*) and subcostal (*middle*) views, and**
465 **corresponding RAP (*bottom*).**

466 (A) A case of dilated cardiomyopathy showing normal RAP of 5 mmHg. The flow profile in the SVC is a
467 systolic dominance (supraclavicular SVC-S/D: 2.35; subcostal SVC-S/D: 2.30). (B) A case of left-sided
468 valvular heart disease showing elevated RAP of 11 mmHg. The flow profile in the SVC is a diastolic
469 dominance (supraclavicular SVC-S/D: 0.71; subcostal SVC-S/D: 0.45). Abbreviations as in Figures 1 and
470 2.

471 **Figure 5. Correlation of SVC-S/D ratio measured from the subcostal and right supraclavicular**
472 **windows with invasive RAP**

473 Abbreviations as in Figures 1 and 2.

474

475 **SUPPLEMENTARY MATERIAL**

476 **Supplemental Figure 1. Derivation and validation study population flowchart in Protocol 2**

477 Abbreviations as in Figures 1 and 2.

478 **Supplemental Figure 2. A representative case showing different impacts of postural changes on SVC**
479 **flow between the subcostal and supraclavicular windows**

480 The supine SVC flow from the subcostal window (**A**), and the sitting SVC flow from the subcostal
481 window (**B**). The supine SVC flow from the right supraclavicular window (**C**), and the sitting SVC flow
482 from the right supraclavicular window (**D**). In the subcostal approach, although a significant increase in
483 SVC-S and D in the sitting position was observed, S/D was not significantly affected by postural changes.
484 In contrast, in the supraclavicular approach, the sitting position significantly increased the SVC-S and D,
485 with a decreased S/D compared to that in the supine position. Abbreviations as in Figure 1.

486 **Supplemental Figure 3. Comparison of mean RAP among the three RAP grades from the guidelines**
487 **in the derivation cohort**

488 Error bars show average and range of standard deviation. Abbreviations as in Figure 2.

489 **Supplemental Figure 4. Correlation of SVC-S/D ratio with invasive RAP in the validation cohort**

490 Abbreviations as in Figures 1 and 2.

491 **Supplemental Figure 5. Incremental diagnostic value of the SVC-S/D ratio to the RAP grading**
492 **according to the guidelines for detecting elevated RAP in the validation cohort**

493 To confirm the incremental diagnostic ability of the SVC-S/D ratio to the established guidelines, two
494 models (model 1: RAP grading alone; model 2: model 1 plus SVC-S/D) were constructed and compared
495 using receiver operating curve analysis. Abbreviations as in Figures 1 to 3.

496 **Supplemental Figure 6. A representative case showing different SVC flow velocity waveforms in the**
497 **several sampling positions**

A case of chronic thromboembolic pulmonary hypertension showing normal RAP of 2 mmHg. In this case, note that the absolute SVC flow velocities differ depending on sample volume location and that the S/D ratio increases as the sample volume is moved to the right atrium. In this case, the SVC flow waveform recorded at the sampling location closest to the right atrial most accurately reflected the RAP waveforms. Abbreviations as in Figures 1 and 2.

Table 1. Comparison of clinical, echocardiographic, and invasive data stratified by RAP of the derivation cohort

Variable	Total	RAP ≤8 mmHg	RAP >8 mmHg	*P*
Demographics				
Number, n (%)	98	78 (80)	20 (20)	N/A
Age, years	64 ± 15	65 ± 15	63 ± 15	.694
Male, n (%)	45 (46)	35 (45)	10 (50)	.803
Body mass index, kg/m^2	23 ± 3	22 ± 3	24 ± 3	.100
NYHA functional class III or IV, n (%)	34 (35)	24 (31)	10 (50)	.121
Systolic blood pressure, mmHg	110 ± 17	110 ± 16	107 ± 18	.409
Heart rate, beats/min	69 ± 11	69 ± 11	70 ± 11	.804
Atrial fibrillation	11 (11)	8 (10)	3 (15)	.691
Cardiac disease, n (%)				
Nonischemic dilated cardiomyopathy	29 (30)	25 (32)	4 (20)	.412
Valvular heart disease	20 (20)	16 (21)	4 (20)	.999
Precapillary pulmonary hypertension	20 (20)	19 (24)	1 (5)	.066
Ischemic heart disease	9 (9)	6 (8)	3 (15)	.383
Hypertrophic cardiomyopathy	8 (8)	5 (6)	3 (15)	.354

Others	12 (12)	7 (9)	5 (25)	.065
Laboratory data				
Hemoglobin, g/dL	12.7 ± 1.8	12.9 ± 1.9	11.9 ± 1.6	.041
Platelets, 10^4/μL	21.0 ± 5.4	21.0 ± 5.2	20.9 ± 6.1	.912
eGFR, mL/min/1.73 m^2	58.5 ± 25.4	60.6 ± 25.5	50.2 ± 24.9	.105
Creatinine, mg/dL	0.9 (0.7–1.2)	0.9 (0.7–1.1)	0.9 (0.7–1.8)	.328
Total bilirubin, mg/dL	0.8 (0.6–1.1)	0.8 (0.6–1.1)	0.8 (0.7–1.2)	.986
AST, IU/L	21.0 (18.0–27.0)	21.0 (17.0–27.0)	20.5 (19.0–23.8)	.761
ALT, IU/L	15.5 (11.0–21.0)	15.5 (11.8–22.3)	15.5 (11.0–19.0)	.708
Albumin, g/dL	3.9 ± 0.5	3.9 ± 0.5	4.0 ± 0.4	.577
Cholinesterase, U/L	269 ± 74	280 ± 67	229 ± 96	.007
BNP, pg/mL	100 (33–338)	91 (29–223)	540 (81–1361)	.006
Echocardiography				
Left heart structure and function				
Left ventricular end-diastolic volume, mL	99 (70–145)	99 (75–144)	100 (62–165)	.734
Left ventricular mass index, g/m^2	104 (83–135)	105 (83–135)	101 (66–134)	.588
Left ventricular ejection fraction, %	58 (34–68)	58 (34–68)	59 (30–70)	.982

Right heart structure and function				
RV basal diameter, mm	39 ± 7	38 ± 7	43 ± 8	.008
RV mid diameter, mm	29 ± 6	28 ± 6	33 ± 7	.006
RV end-diastolic area, cm^2	19 ± 6	18 ± 6	22 ± 6	.005
RV fractional area change, %	37 ± 11	37 ± 11	36 ± 12	.525
Tricuspid annular plane systolic excursion, mm	18 ± 5	18 ± 5	18 ± 6	.712
RV S′, cm/s	10.9 ± 3.0	11.1 ± 3.1	9.8 ± 2.2	.090
Tricuspid E/A	1.1 (0.8–1.4)	1.0 (0.8–1.3)	1.3 (1.0–2.1)	.027
Tricuspid E/e′	4.8 (3.8–6.4)	4.5 (3.6–6.5)	5.5 (4.3–6.4)	.109
Hepatic vein systolic filling fraction, %	61 ± 9	62 ± 8	58 ± 10	.098
SVC-S, cm/s	47.7 ± 18.1	50.6 ± 16.6	36.6 ± 23.2	.018
SVC-D, cm/s	25.4 ± 10.3	23.7 ± 8.2	31.9 ± 16.1	.038
SVC-S/D	2.1 ± 0.9	2.3 ± 0.9	1.2 ± 0.7	<.001
Right atrial maximum area, cm^2	19 ± 6	18 ± 6	23 ± 8	.007
IVC dimension, mm	15 ± 5	13 ± 4	19 ± 7	.002
IVC respiratory change, %	44 ± 15	46 ± 14	35 ± 17	.002
Judgment by guidelines, n (%)				

Elevated RAP (15 mmHg)	10 (10)	2 (2)	8 (40)	<.001
Indeterminate RAP (8 mmHg)	49 (50)	41 (53)	8 (40)	.453
Normal RAP (3 mmHg)	39 (40)	35 (45)	4 (20)	.071
Significant tricuspid regurgitation, n (%)	17 (17)	11 (14)	6 (30)	.107
Cardiac Catheterization				
Mean RAP, mmHg	6.0 ± 2.3	4.5 ± 2.0	11.9 ± 3.4	<.001
Pulmonary arterial wedge pressure, mmHg	11.8 ± 5.0	10.1 ± 4.3	18.6 ± 7.1	<.001
Mean pulmonary arterial pressure, mmHg	22.9 ± 9.3	21.7 ± 9.5	27.6 ± 8.8	.013
Pulmonary vascular resistance, Wood units	2.8 ± 2.4	2.8 ± 2.4	2.6 ± 2.6	.787
Cardiac index, L/min/m^2	2.6 ± 0.6	2.6 ± 0.6	2.4 ± 0.6	.169

Data are expressed as mean ± standard deviation if normally distributed, median (interquartile range) if not normally distributed, or n (%). *P* values are from the Student's *t*-test, Wilcoxon rank-sum test, or chi-square test.

RAP = mean right atrial pressure; NYHA = New York Heart Association; eGFR = estimated glomerular filtration rate; AST = alanine aminotransferase; ALT = aspartate aminotransferase; BNP = plasma brain natriuretic peptide; RV = right ventricular; RV S′ = RV systolic excursion velocity derived from pulsed tissue Doppler echocardiography; Tricuspid E/A = the ratio of early-diastolic

transtricuspid flow velocity to late-diastolic tricuspid flow velocity; Tricuspid E/e′ = the ratio of early-diastolic transtricuspid flow velocity to early-diastolic tricuspid annular velocity; Hepatic vein systolic filling fraction = hepatic vein peak systolic velocity divided by the sum of peak systolic and diastolic velocity; SVC-S = the peak systolic velocity of superior vena cava derived from subcostal view; SVC-D = the peak diastolic velocity of superior vena cava derived from subcostal view; IVC = Inferior vena cava.

Table 2. Results of linear regression analysis to assess the associations between the SVC-S/D ratio and invasive RAP after adjustment for several confounders in the derivation cohort

Variable	Univariable		Multivariable	
	β	*P* value	β	*P* value
Age, years	−0.045	0.659		
Body mass index, kg/m^2	−0.059	0.562		
Heart rate, beats/min	−0.034	0.738		
Atrial fibrillation	−0.542	<0.001	−0.445	<0.001
Precapillary pulmonary hypertension	0.158	0.121		
Left ventricular ejection fraction, %	0.154	0.130		
RV basal diameter, mm	−0.116	0.256		
Tricuspid annular plane systolic excursion, mm	0.276	0.008	0.148	0.081
RV fractional area change, %	−0.015	0.885		
Right atrial maximum area, cm^2	−0.327	0.001	0.163	0.104
Significant tricuspid regurgitation	−0.382	<0.001	−0.117	0.248
Mean pulmonary arterial pressure, mmHg	−0.059	0.564		
Mean RAP, mmHg	−0.495	<0.001	−0.476	<0.001

Abbreviations are the same as in Table 1. We found no evidence for collinearity problems in our model (variance inflation factor values <2).

Table 3. Comparison of clinical, echocardiographic, and invasive data stratified by RAP of the validation cohort

Variable	Total	RAP ≤8 mmHg	RAP >8 mmHg	*P*
Demographics				
Number, n (%)	43	35 (81)	8 (19)	N/A
Age, years	69 ± 18	70 ± 18	68 ± 20	.803
Male, n (%)	20 (47)	15 (43)	5 (63)	.440
Body mass index, kg/m^2	23 ± 5	23 ± 5	24 ± 4	.643
NYHA functional class III, n (%)	11 (28)	7 (22)	4 (50)	.172
Systolic blood pressure, mmHg	114 ± 20	116 ± 19	106 ± 22	.212
Heart rate, beats/min	68 ± 9	68 ± 10	68 ± 8	.992
Atrial fibrillation	3 (7)	2 (6)	1 (13)	.470
BNP, pg/mL	166 (54–299)	123 (34–275)	294 (181–545)	.024
Cardiac disease, n (%)				
Valvular heart disease	15 (35)	12 (34)	3 (38)	.999
Nonischemic dilated cardiomyopathy	13 (30)	11 (31)	2 (25)	.999
Precapillary pulmonary hypertension	7 (16)	6 (17)	1 (13)	.999
Ischemic heart disease	5 (12)	4 (11)	1 (13)	.999

Others	3 (7)	2 (6)	1 (13)	.939
Right heart structure and function				
RV basal diameter, mm	41 ± 7	40 ± 6	43 ± 10	.328
RV fractional area change, %	39 ± 11	39 ± 11	35 ± 10	.299
SVC-S, cm/s	47.4 ± 21.0	52.5 ± 19.5	25.0 ± 9.9	<.001
SVC-D, cm/s	27.6 ± 12.4	26.3 ± 12.2	33.0 ± 12.4	.172
SVC-S/D	1.9 ± 0.9	2.2 ± 0.7	0.9 ± 0.5	<.001
IVC dimension, mm	15 ± 5	14 ± 4	20 ± 6	.048
IVC respiratory change, %	45 ± 16	48 ± 13	33 ± 20	.016
Judgment by guidelines, n (%)				
Elevated RAP (15 mmHg)	5 (12)	1 (3)	4 (50)	.003
Indeterminate RAP (8 mmHg)	20 (46)	18 (51)	2 (25)	.250
Normal RAP (3 mmHg)	18 (42)	16 (46)	2 (25)	.434
Significant tricuspid regurgitation, n (%)	16 (37)	10 (29)	6 (75)	.022
Cardiac Catheterization				
Mean RAP, mmHg	5.7 ± 3.3	4.5 ± 2.2	11.0 ± 2.0	<.001
Mean pulmonary arterial pressure, mmHg	21.4 ± 7.7	20.3 ± 7.1	26.6 ± 8.4	.034

Pulmonary vascular resistance, Wood units	2.5 ± 1.6	2.5 ± 1.6	2.7 ± 1.3	.762
Cardiac index, L/min/m^2	2.6 ± 0.6	2.7 ± 0.6	2.4 ± 0.7	.273

Data are expressed as mean ± standard deviation if normally distributed, median (interquartile range) if not normally distributed, or n (%). *P* values are from the Student's *t*-test, Wilcoxon rank-sum test, or chi-square test.

Abbreviations are the same as in Table 1.

Fig 1

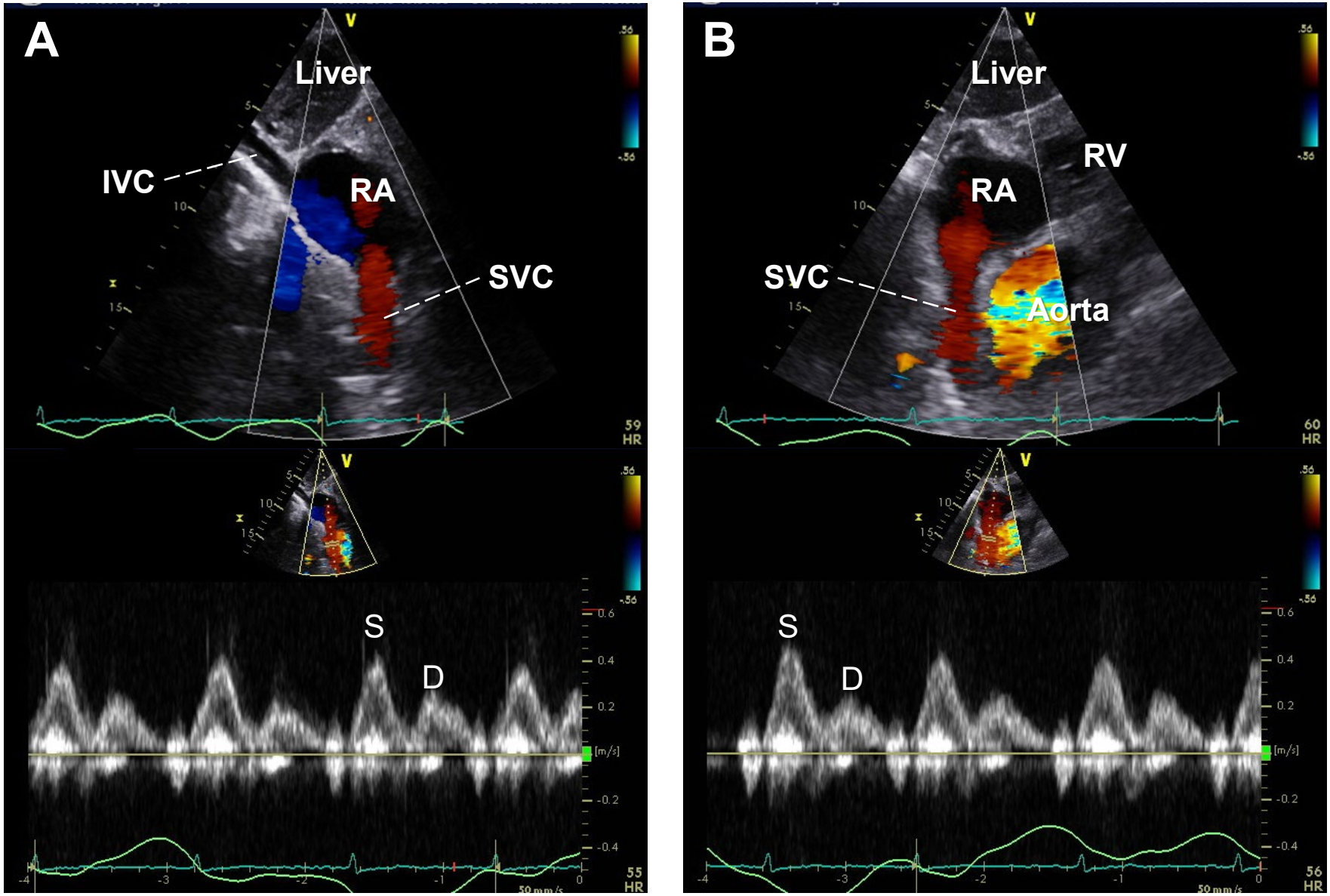

R1 Fig 2

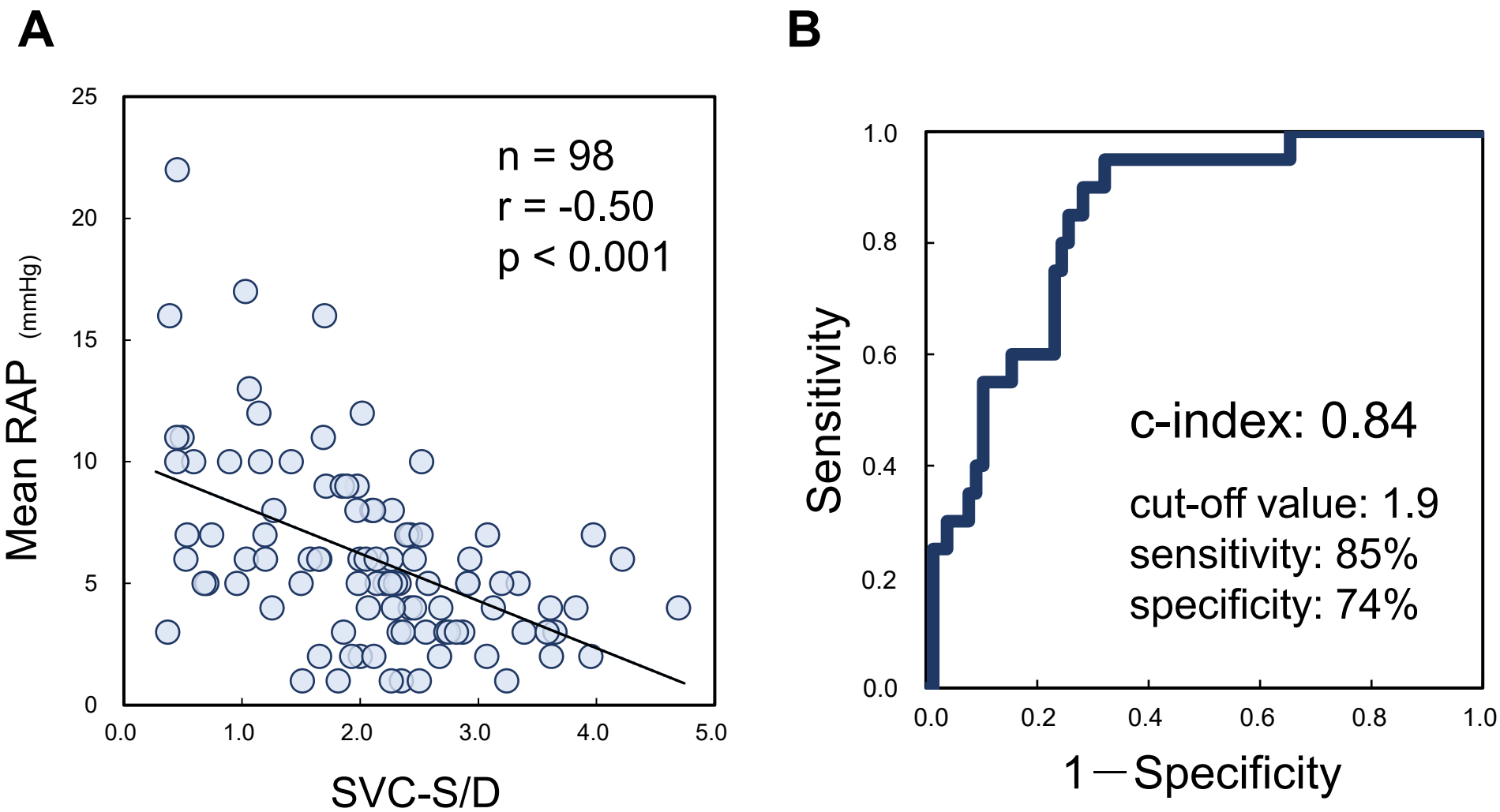
A
n = 98
r = -0.50
p < 0.001
Mean RAP (mmHg)
SVC-S/D
0
5
10
15
20
25
0.0
1.0
2.0
3.0
4.0
5.0
B
c-index: 0.84
cut-off value: 1.9
sensitivity: 85%
specificity: 74%
Sensitivity
1 − Specificity
0.0
0.2
0.4
0.6
0.8
1.0

R1 Fig 3

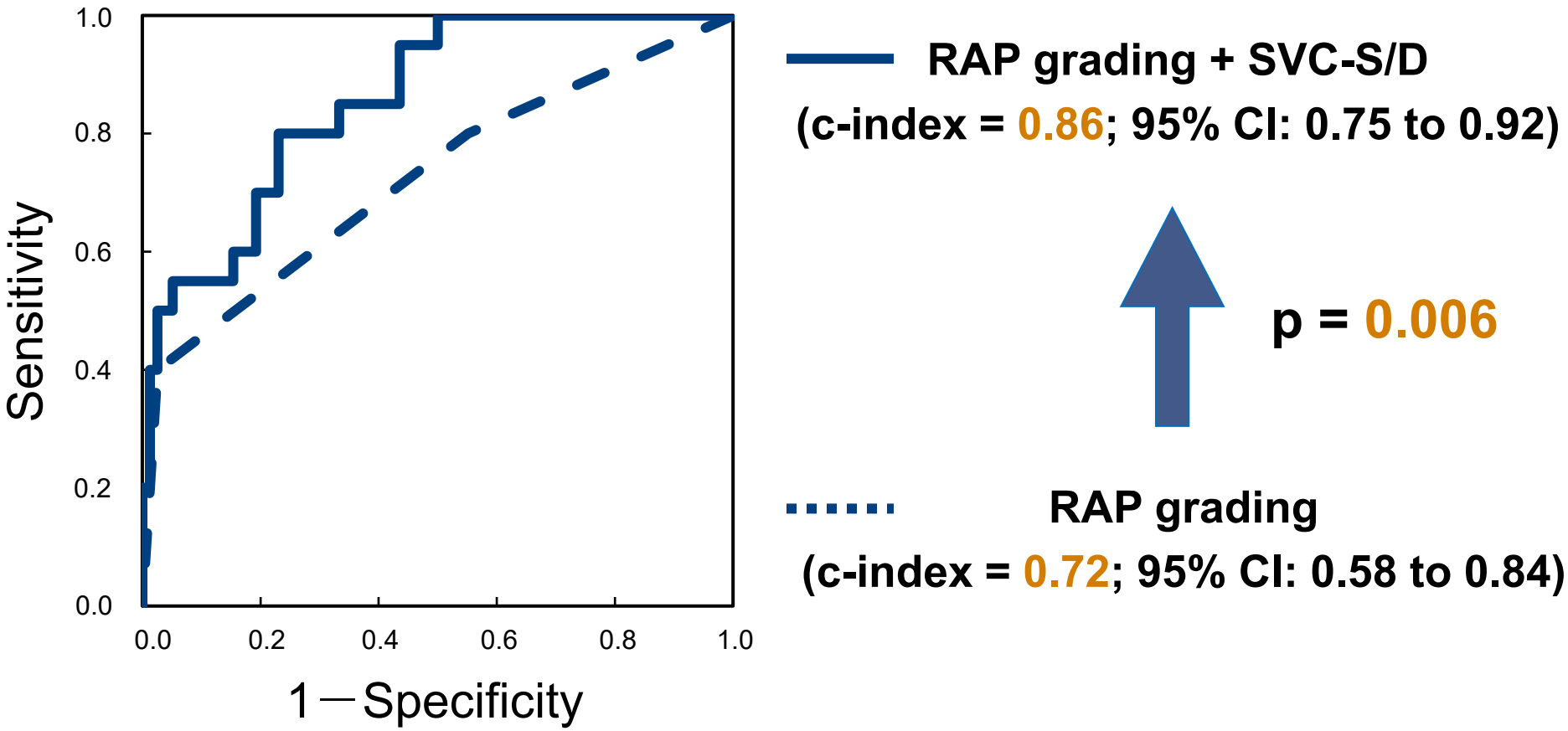
1.0
0.8
0.6
0.4
0.2
0.0
Sensitivity
0.0
0.2
0.4
0.6
0.8
1.0
1－Specificity
RAP grading + SVC-S/D
(c-index = 0.86; 95% CI: 0.75 to 0.92)
p = 0.006
RAP grading
(c-index = 0.72; 95% CI: 0.58 to 0.84)

R1 Fig 4

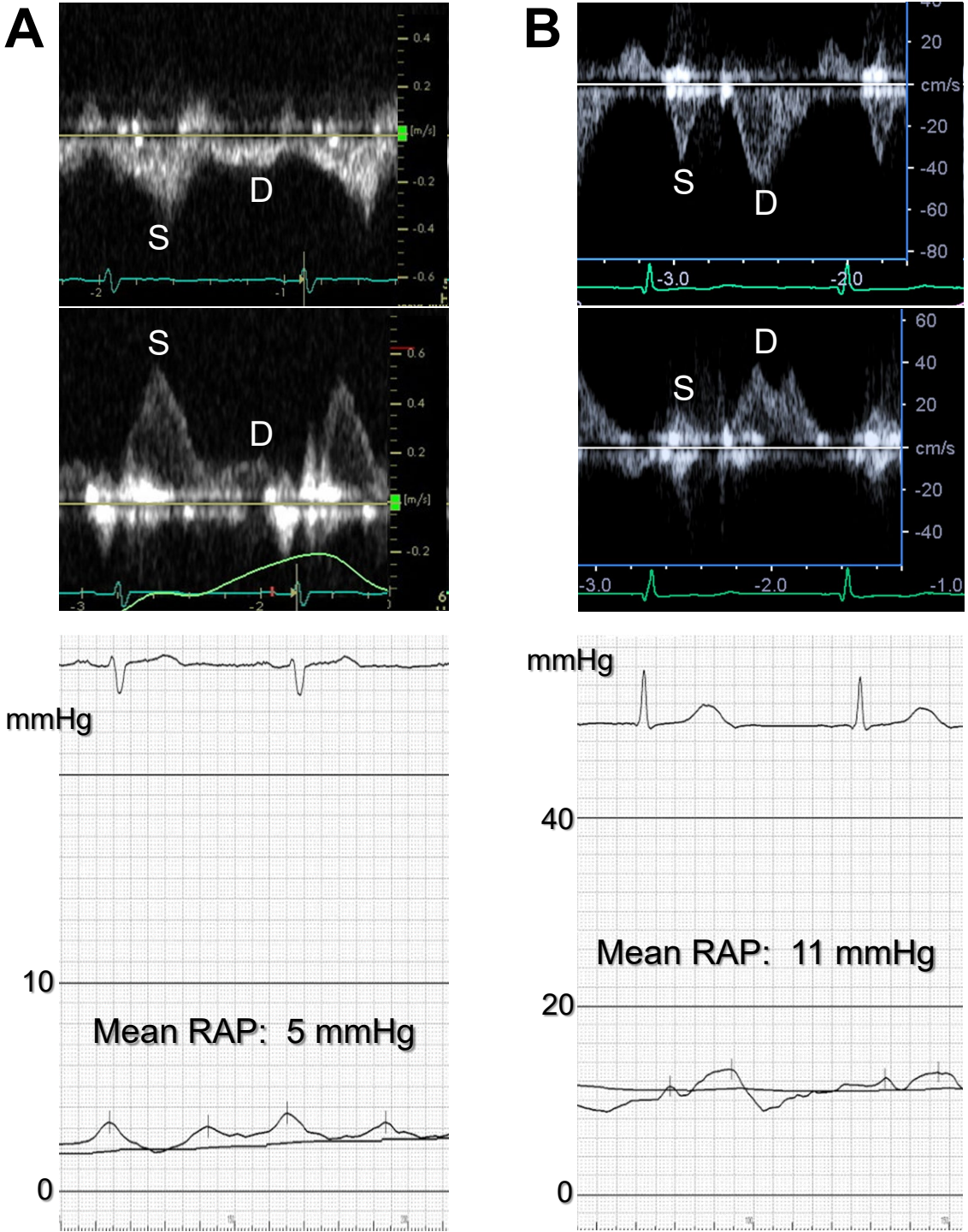
A
B
S
D
S
D
S
D
S
D
cm/s
[m/s]
mmHg
10
0
Mean RAP: 5 mmHg
mmHg
40
20
0
Mean RAP: 11 mmHg

R2 Fig 5

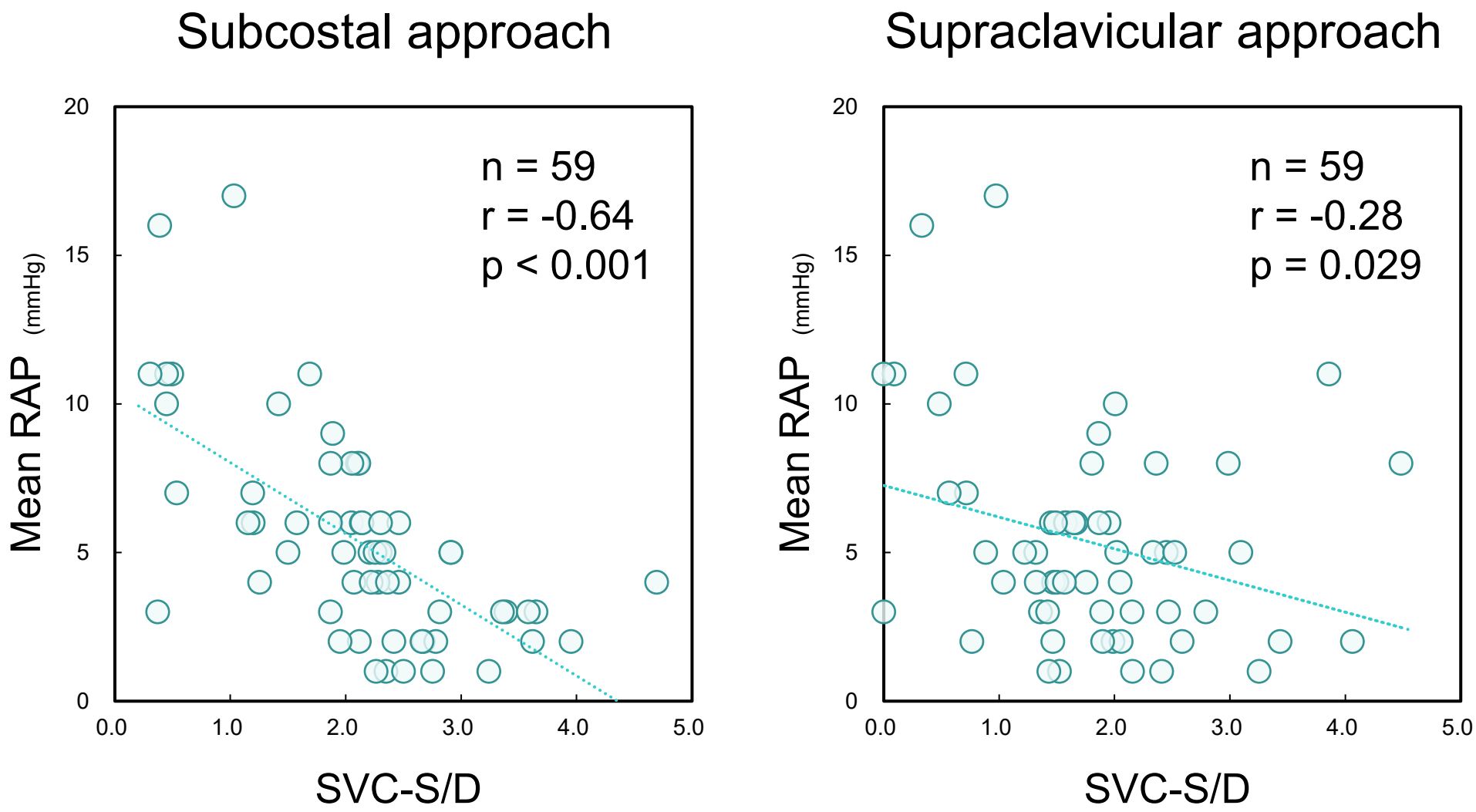
Subcostal approach
n = 59
r = -0.64
p < 0.001
Mean RAP (mmHg)
SVC-S/D
0
5
10
15
20
0.0
1.0
2.0
3.0
4.0
5.0
Supraclavicular approach
n = 59
r = -0.28
p = 0.029
Mean RAP (mmHg)
SVC-S/D

R1
Sup
Fig 1

Derivation cohort of Protocol 2

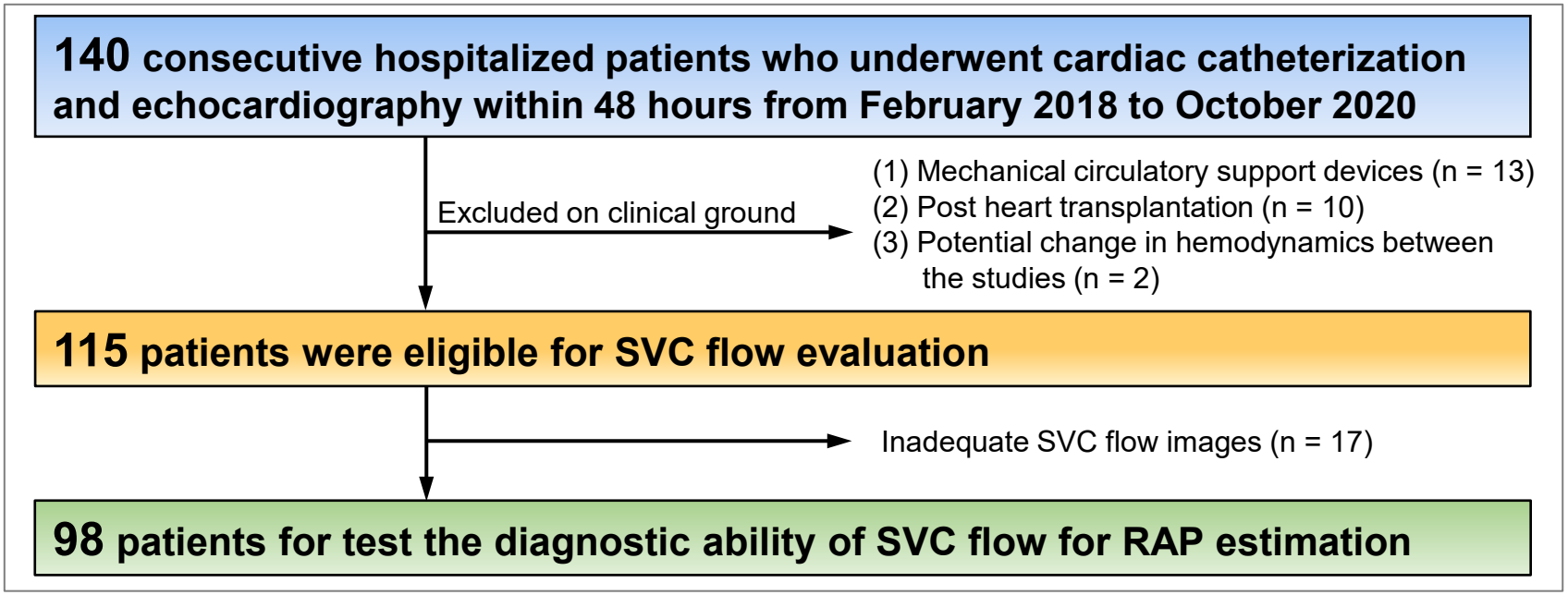

Validation cohort of Protocol 2

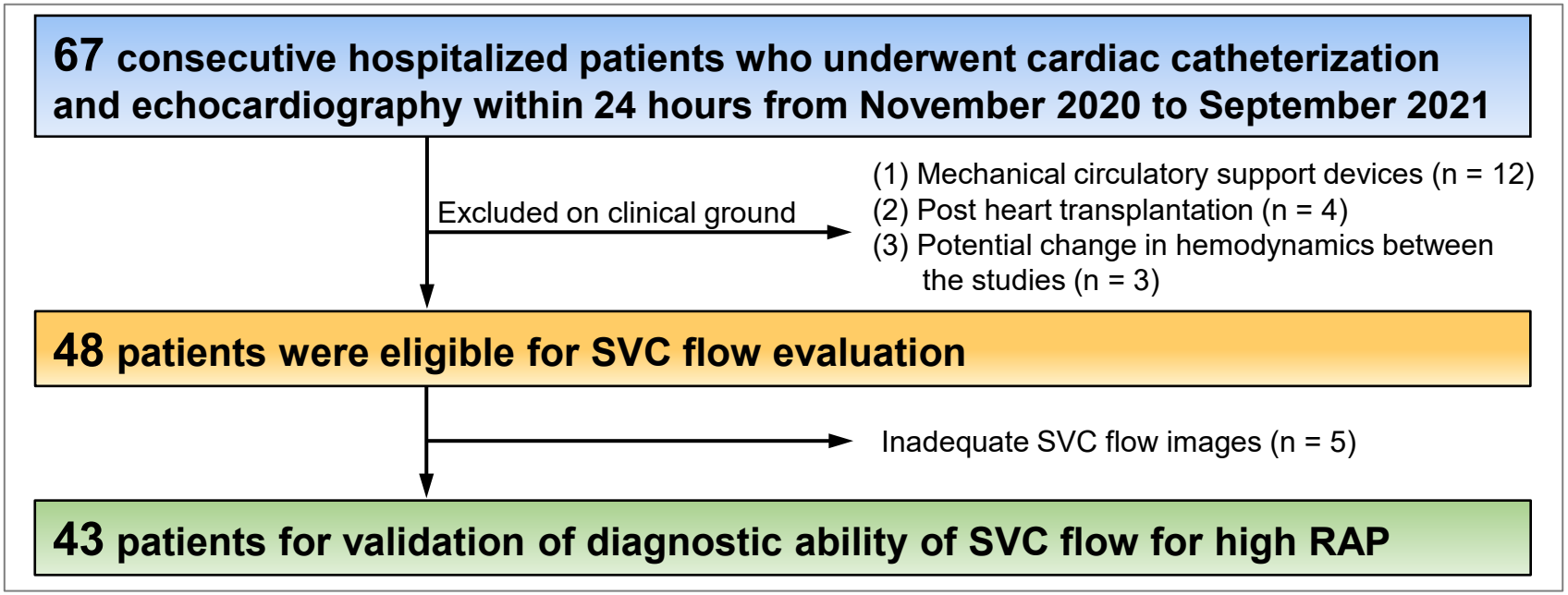

R2 Sup Fig 2

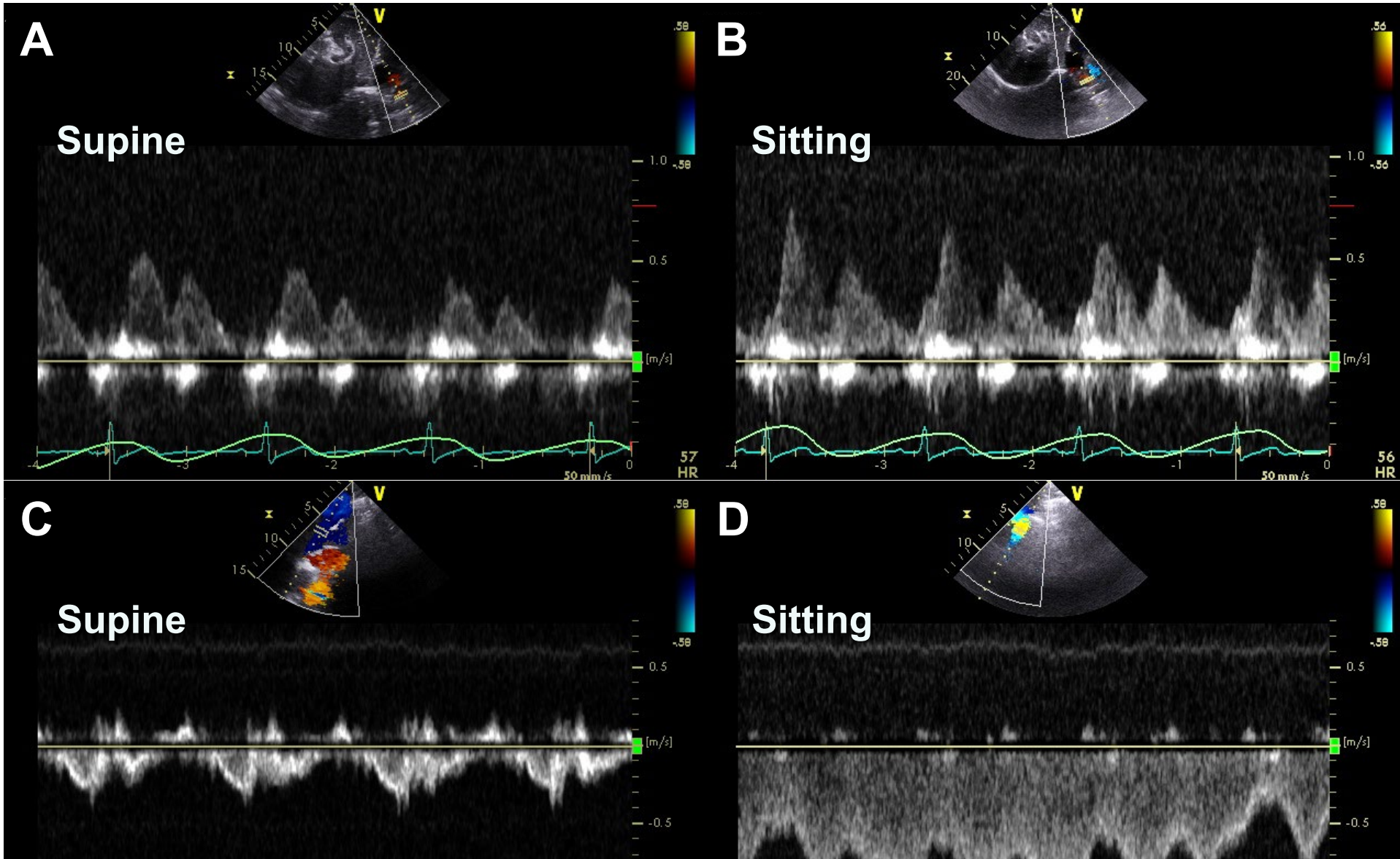

R1 Sup Fig 3

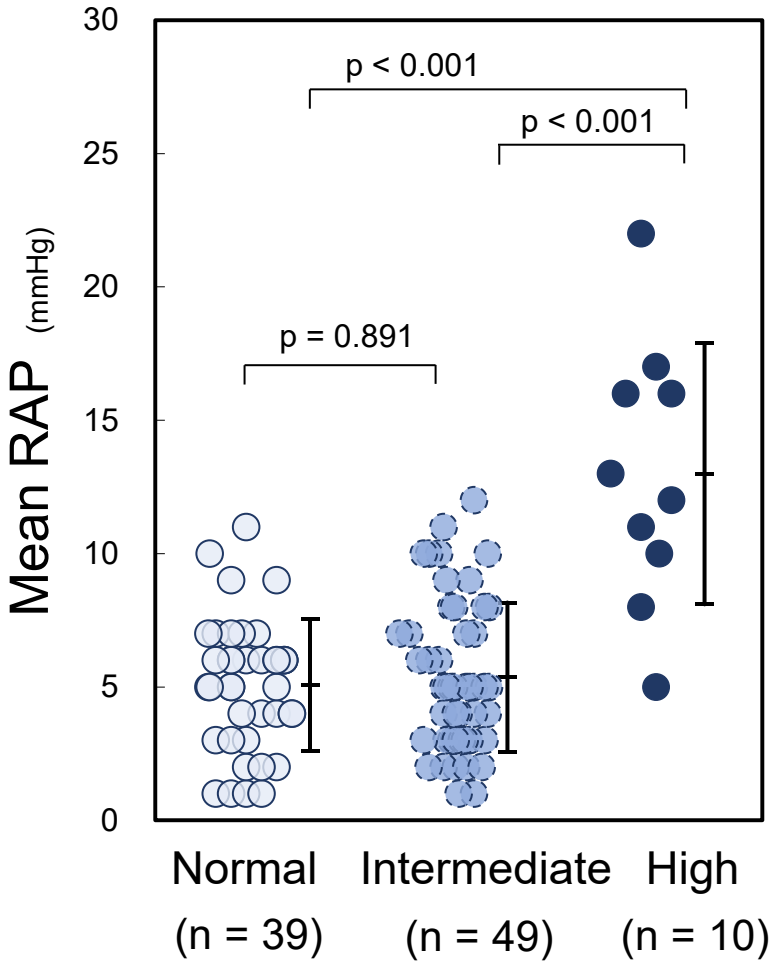
30
25
20
15
10
5
0
Mean RAP (mmHg)
p < 0.001
p < 0.001
p = 0.891
Normal
(n = 39)
Intermediate
(n = 49)
High
(n = 10)

R1 Sup Fig 4

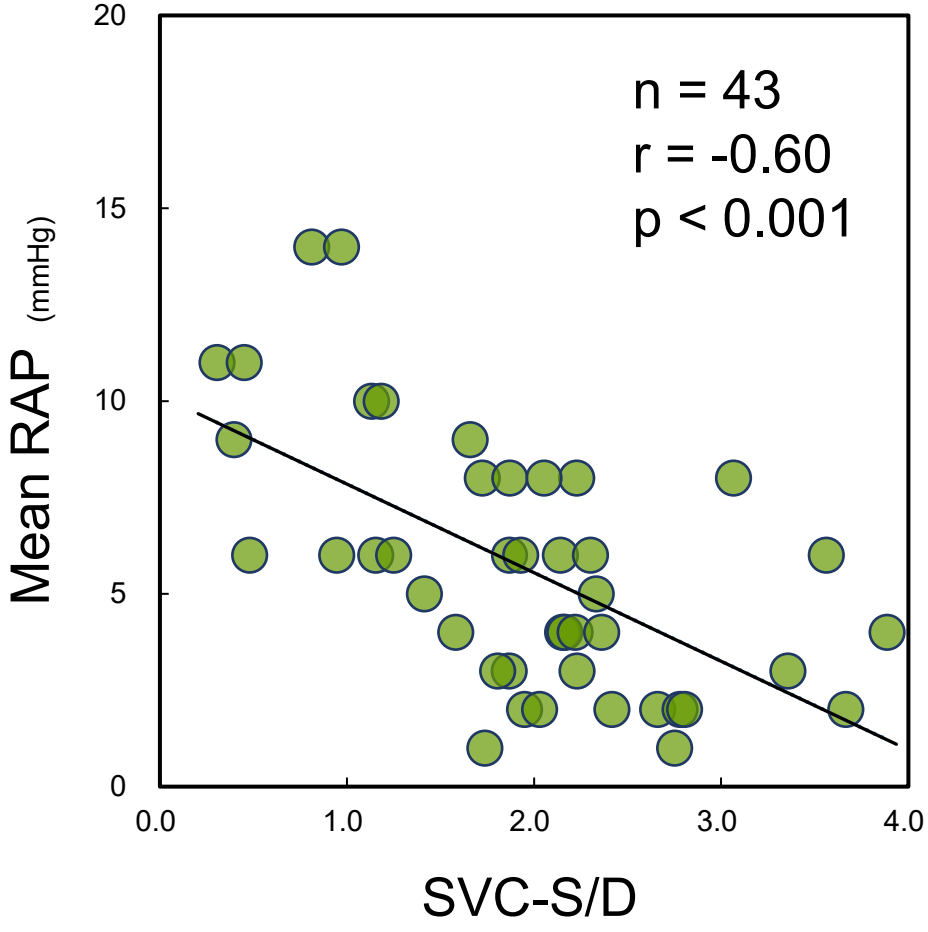

R1 Sup Fig 5

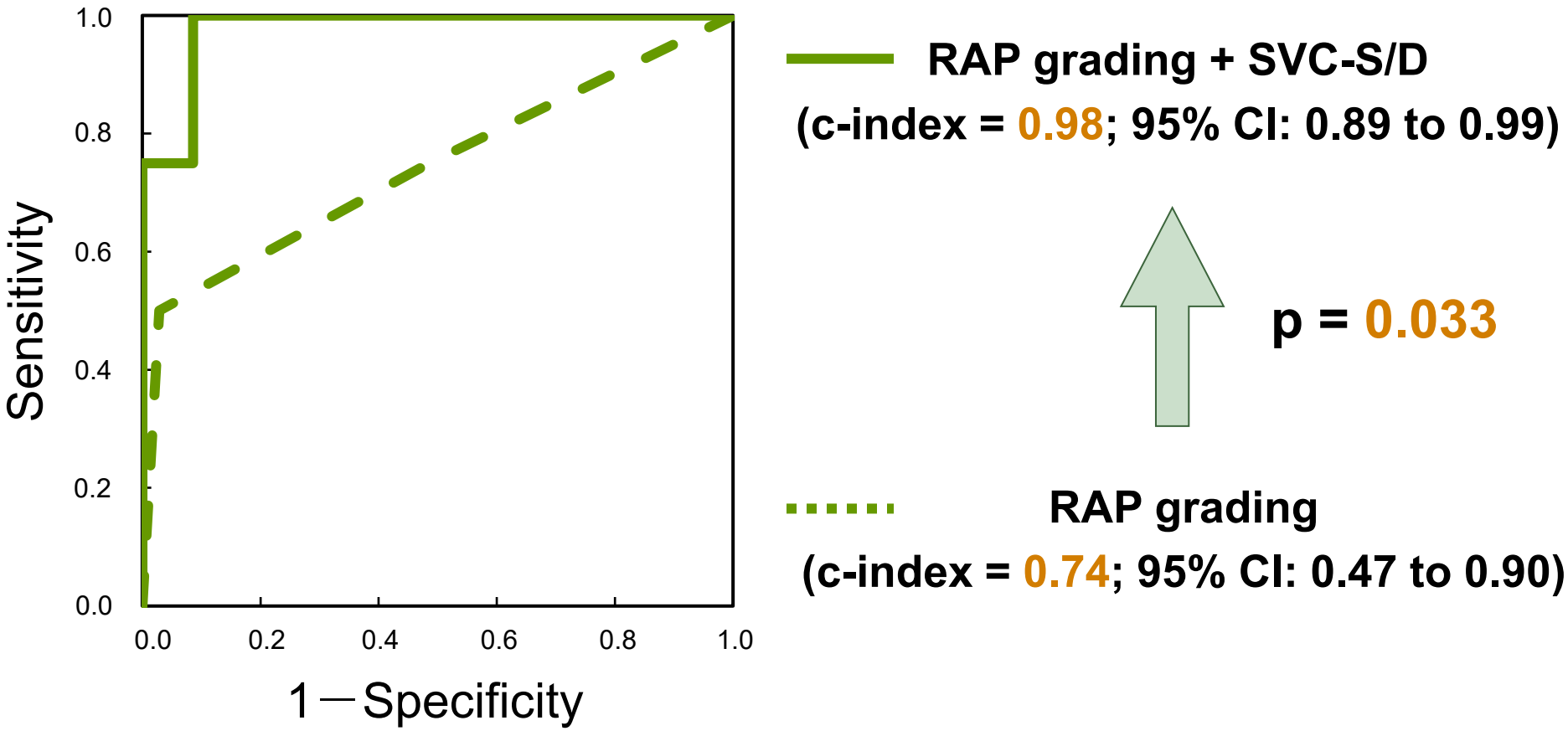
1.0
0.8
0.6
0.4
0.2
0.0
Sensitivity
0.0
0.2
0.4
0.6
0.8
1.0
1 − Specificity
RAP grading + SVC-S/D
(c-index = 0.98; 95% CI: 0.89 to 0.99)
p = 0.033
RAP grading
(c-index = 0.74; 95% CI: 0.47 to 0.90)

R2 Sup Fig 6