

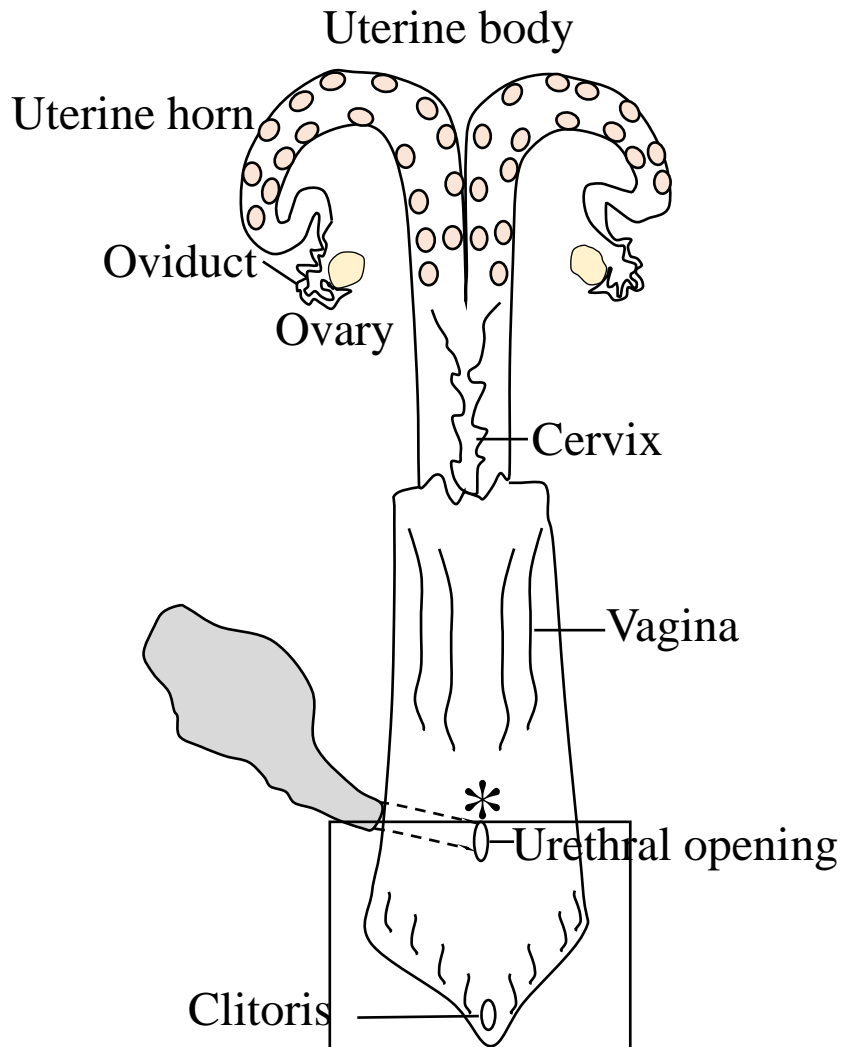


Title	Genital organ-associated lymphoid tissues arranged in a ring in the mucosa of cow vaginal vestibules
Author(s)	Chuluunbaatar, Tsolmon; Ichii, Osamu; Masum, Md Abdul; Namba, Takashi; Islam, Md Rashedul; Otani, Yuki; Elewa, Yaser Hosny Ali; Kon, Yasuhiro
Citation	Research in veterinary science, 145, 147-158 https://doi.org/10.1016/j.rvsc.2022.02.011
Issue Date	2022-07
Doc URL	http://hdl.handle.net/2115/90205
Rights	© 2022. This manuscript version is made available under the CC-BY-NC-ND 4.0 license https://creativecommons.org/licenses/by-nc-nd/4.0/
Rights(URL)	https://creativecommons.org/licenses/by-nc-nd/4.0/
Type	article (author version)
Additional Information	There are other files related to this item in HUSCAP. Check the above URL.
File Information	Supplementary file.pdf (Supplementary material)



[Instructions for use](#)

Cow reproductive organ



Additional file 1. Illustration of reproductive organs in a cow.

Vagina and vaginal vestibule (VV) are cut open. The square indicates VV, and external part of genital organ area, examined in this study.