



HOKKAIDO UNIVERSITY

Title	ON THE ERGOT OF EQUIDAE
Author(s)	YOSCHIDA, Schin
Citation	The journal of the College of Agriculture, Tohoku Imperial University, Sapporo, Japan, 6(8), 171-190
Issue Date	1915-06-25
Doc URL	https://hdl.handle.net/2115/12531
Type	departmental bulletin paper
File Information	6(8)_p171-190.pdf



ON THE ERGOT OF EQUIDAE.

By

Schin. Yoshida.

In 1913 I wrote the work entitled "Morphologische und Physiologische Bedeutung der Sogenannten Kastanie an den Gliedmassen der Equiden", for the Zoological Institute at Halle a. S. In this work, the outcome of a great deal of microscopic and macroscopic study, I believe I have given a definite answer to the question "What is a Callosity?" but I did not then give any results of histological research on the Ergot, a small hornified mass found in the tuft of hair at the back of the fetlock. Since that time I have made further histological observations, the results of which I give below.

In order to do this I wish first to refer to the results of former zoologists.

Flower, in "The Horse", says, "The Ergot in the horse corresponds to the Afterclaw in the tapir, which is of the greatest use to the animal".

In 1903, Lydekker, in "Proceedings of the General Meetings for Scientific Business of the Zoological Society of London", Vol. 1 wrote a great deal on the subject of Callosities without mentioning the Ergot. Against Ewart's theory, published in "The Royal Society of Edinburgh", that the Callosity is a rudimentary toe, he wrote as follows: "A more important objection to the foot-rest theory is to be drawn from the fact that the fore Callosities are above the Carpus and are, therefore, too high to serve as foot-rests to any plantigrades, and as it is impossible that any change of position should have taken place, they never could have served as foot-rests."

The hind Callosities lie, on the contrary, below the hock and are therefore on a part of the leg which, by plantigrades is considered the foot surface; but while the fore Callosities are altogether homologous with the hind, it is

clear that as the fore Callosities are not foot-rests neither can the hind ones be.

If the Callosities are toe-rests, the ancestors of these families must, at the time when they were still plantigrades, have possessed them, but, so far as I know, no Ungulata was ever a sole-walker with all its limbs.

Lydekker has studied the Tarsal glands of reindeer and said that these corresponded with the Callosities of the horse and that the Ergots are rudimentary toes.

Ludwig Frank, in "Handbuch der Anatomie der Haustiere", second edition, page 796, has written on the microscopic structure of the Ergot and Callosity, that these form rudimentary horntubes and laminae.

Ellenberger, Stoss, Bonnet and many histologists have stated in their handbooks that the Ergot is of the same histological structure as the Callosity, that it is possible that the Ergot may be a rudimentary digit but that this has not been proved.

In 1913, when I wrote "Morphologische und Physiologische Bedeutung der Sogenannten Kastanie an den Gliedmassen den Equiden", my research into the matter of the Callosity had been thorough but I had made little histological observation on the Ergot. I had only made a macroscopical observation of the position and said that it might be a rudimentary pad.

In 1914, Zietzmann wrote in "Morphologie, Genese und Bedeutung von Kastanie und Sporn der Equidae", that from many deep microscopic, macroscopic and embryological researches he had concluded that the Callosity and Ergot are rudimentary pads.

Since that time, to determine whether the Ergot, like the Callosity, is a rudimentary digit or, on the other hand, a rudimentary pad, I have made further investigation which I shall now describe in the following order :

- 1.) Microscopic and Macroscopic Observations of the Ergot.
- 2.) Histological comparison of the Ergot and Pad.
- 3.) My own opinions on the subject.

I obtained material for observation from the slaughterhouse of Halle a.S by the kind favour of Professor Haeckel ; first, fresh material preserved in

70% alcohol for three hours, after that in pure alcohol for twenty-six hours, in Xylol for twenty-four hours, and so on, then embedded in paraffin, stained with Vangieson's solution and Haematoxylin. The pad of the dog and cat I have preserved in the same manner.

I must express my gratitude to Professor Haeckel and his assistant Fraulein Dr. Kuttner for the kind encouragement and advice they have always given me and also to Professor Thomas in the British Museum for his kindness in allowing me to inspect so much material.

1. Microscopic and Macroscopic Observation of the Ergot

The Ergot is the name applied to the mass of wart-like horn situated in the tuft of hair on the inner side of the fetlock. Its size varies in the case of different horses and with different ages. Among the Equidae, when the Ergot appears on both fore and hind feet, according to my measurements, it is larger on the latter than on the former, but in many cases it is found on the hind feet only, with no trace of one on the fore feet.

Generally, the Ergot is larger among the heavier breeds of horses than in the smaller breeds, but there are exceptions. Very small horses, as for instance native breeds, sometimes have a large Ergot on the hind foot, and in the case of English thoroughbreds it is sometimes larger than among heavy horses. In conclusion I will repeat that:

- 1.) When the Ergot is found on fore and hind feet it is larger on the latter than on the former,
- 2.) Sometimes it is found on the hind feet alone.

Professor Zietzmann's measurements of the diameter of the Ergot on the donkey are, on the forefoot, 2.0 cm., on the hind foot 2.3 cm. Its thickness, however, though small in comparison with the Callosity yet measures some millimeters.

Among Zebras, the diameter of the Ergot on the hindfoot is 2.0 cm. larger than that on the fore foot.

In the British Museum I have observed the following different equine breeds :

Equus grevyi (?). Ergot on fore and hind feet, very large on hind feet.

Equus samalicus. Ergot on fore feet $1\frac{1}{2}$ mm. broad, $2\frac{1}{2}$ mm. long, on hind feet, $2\frac{1}{2}$ mm. broad, 3 mm. long.

Burchell's Zebra (*Eq. burchelli selousi*). Ergot on fore foot smaller than on hind foot.

Grey's Zebra (*Eq. grevyi*). Ergot on fore and hind foot, that on hind very large.

As these specimens are stuffed the skin has shrunk somewhat causing the Callosity and Ergot to become smaller, but as I only desire to compare the relative sizes of fore and hind Callosities and Ergots this shrinking is of no account. Professor Zietzmann's research in the case of the Ergot has been very thorough. He says that among hinnies the Ergot grows as with horses to a considerable thickness (over 2 cm.), that those on the hind feet have the larger surface, the greatest diameter of which sometimes exceeds 2 cm. In the case of mules he had made no observations.

As I have said above, from the microscopic studies, the Ergot, in contradistinction to the Callosity which is of the same size on fore and hind feet, is always larger on the hind feet.

In my conclusion I wish to give an explanation of this.

In the first place, to examine the theory of many histologists that the Ergot is a rudimentary pad, I have compared it with the toe pad and central pad of dogs and cats, and in particular with the carpal pad which, at the present time, is not used by its possessor.

If the Ergot is a rudimentary pad it was formerly used by its possessor as a pad, and in my opinion its histological structure should be similar to, or the same as, that of the pads of dogs and cats. I have, therefore, first made histological studies of the pads of domestic cats and dogs as follows :

A.) Histological structure of the pads of cat and dog,

a) Pad of domestic cat.

The Stratum Mortificatum is composed of quite dry, flat, scaly cells, from which hornified scales are thrown off from the superficial layer. In the pad of the cat this layer is more compact than in the Chestnut of the horse.

The Stratum Mortificatum gradually merges into the Stratum Corneum with no distinct connecting line. This latter Stratum consists of layers of cells with hornified membrane, and large and small scales which are continually forming the Stratum Mortificatum. These are the dead elements. In this layer, the Marklayer of the supra papillar epidermis, which is to be seen in the epidermis of the Ergot, cannot be found.

Stratum Corneum is connected with Stratum Granulosum by Stratum Lucidum. This latter consists of hornified cells without nucleus; the cell wall is hardly to be seen even in thin sections, and is generally quite indistinct.

Stratum Granulosum is a quite thin layer, and is only to be distinguished from its upper layer, Stratum Lucidum, by staining with Hematoxylin as the nucleus of the cell of Stratum Granulosum is easy to stain. The cells of Stratum Granulosum are quite flat in form and contain a small round nucleus.

Stratum Spinosum or Stratum Malpighii in the pad of the cat is very well developed, and contains the cone-shaped Papillae which do not penetrate this layer as in the case of the Ergot.

The Prickle Cell of Stratum Spinosum is larger than in the Callosity and Ergot, and more distinct. The cells are joined by means of fibrils which pass from one to the other as in the case of other hornified cells.

Stratum Germinativum consists of cylindrical cells, containing a nucleus, and arranged in rows in quite thin layers which gradually merge into Stratum Spinosum with no distinct dividing line. When the pad is black this Stratum Germinativum contains much pigment, and when it is stained with Hematoxin takes a strong colour which distinguishes it from the other layer.

From this layer (Stratum Germinativum) the cells are continually being divided and driven upwards with the groups of pigment bodies and gradually

changed to Prickle Cells.

The Papillae of the pad of the cat are comparatively less developed and are cone-shaped. These are filled with connective tissue, which is joined perpendicularly to the tissue in the Stratum Reticulare. This latter tissue is finer and contains many small blood vessels.

In the Cutis Vera of these balls, hair roots and sweat glands are not found, but on the border line between the common skin and the pad many hair roots and sweat glands are found.

My histological studies of the pad of the cat have enabled me to verify the following important facts :

The Papillae of the pad of the cat are cone-shaped with broad base and pointed top, and they are enveloped with a layer of Prickle Cells. They never penetrate the Stratum Spinosum and keep a simple form.

b) Pad of the dog.

The histological structure of the pad of the dog differs very slightly from that of the cat. I have, therefore, to avoid repeating myself, described only the differences, which are as follows :

Stratum Corneum is more developed than in the cat and I have obtained the following average measurement : 0.45 mm.

Stratum Lucidum, as in the cat, is a very thin layer, fine and clear and difficult to stain.

Stratum Spinosum is a very simple wave-like layer and thin as in the cat. The Prickle Cells are difficult to stain and contain a distinct round nucleus, which, as the cells gradually reach Stratum Germinativum, becomes easier to color, and the cells themselves become flatter and flatter.

Stratum Germinativum, in the case of a colored pad, contains very many pigment cells in its lower part. This pigment is found in the bottom layer of cells which make a mitotic division, and it passes upwards with the divided cell.

The Papillae in this pad are larger than in the cat and are of an elongated cone form. They are enveloped by Stratum Malpighii, but their tops do not

penetrate Stratum Malpighii as they do in the Callosity and Ergot.

The histological structure of the pad of the dog is in general similar to that of the cat.

B. Histological Structure of the Ergot

As I have related above, the Ergot, like the Callosity and the Pad, was originally a variety of the common skin, and its histological structure, therefore, should resemble that of the other two; when, however, it is studied in very minute detail some differences in the degree of divergence from the original are discerned.

The result of my histological study is as follows, starting from the surface layer downwards:

Stratum Mortificatum, in the Ergot, is very well developed and is very long. It consists of large and small scales, which, being delicate and flat, adhere closely together and are not easily rubbed off as in the pad of the dog and cat, and therefore grow long like a nail. As the surface of an undeveloped Ergot is comparatively flat, the thickness of Stratum Mortificatum varies with the degree of development, but the other layers remain unchanged.

Stratum Corneum, as in the Callosity and Pad consists of a layer of cells with hornified membrane, connected with a layer of Prickle Cells by Stratum Lucidum. In this layer Horntubes are to be found which are not seen in the Callosity and the Pad. These are formed by the tops of the elongated Papillae which penetrate Stratum Lucidum and the Prickle Cell layer. In a horizontal section Rohrwand cells and Horntube mark cells may distinctly be seen in these Horn tubes.

Stratum Lucidum, in the case of the Ergot, shows no distinct connecting line with Stratum Granulosum, and the former is to be distinguished from the latter only because it is more difficult to stain.

The Prickle Cell layer is very thick, with an average thickness of 1-3 mm. It is penetrated by elongated and well developed Papillae and divided by them into interpapillary and superpapillary epidermis. On the base of

the superpapillary epidermis many pigment groups are to be found.

Stratum Reticulare, which forms the Corium, contains fine fibres which always run parallel with the layer and perpendicularly to the papillary body. In these fibres blood and lymph vessels are embedded. In the case of the pad many fat cells are found in this tissue, but in the Ergot they are found, not in these fibres but in the Subcutis.

The fine elastic fibres in Stratum Reticulare, running into the Papillae with blood and lymph vessels, compose the so-called Stratum Corpus Papillary. When this is stained with Vangieson's solution these fibres can easily be distinguished from the Rinden surface of Stratum Germinativum.

The Rinden surface consists of one-layered cells, of somewhat cylindrical shape, containing a large nucleus which can be easily stained with Kaematoxil. The histological form of these cells is similar to those in the base of the Epithel of the Oesophagus, but the contents of the former cells are clearer than of the latter.

The Papillae of the Ergot, according to my measurements, are 1–2.9 mm. long; their number is greater than in the Chestnut and Pad and they are better developed. Their histological form is similar to that of the Papillae and Horn-tubes which are found in the claw wall of cattle.

In particular the Horntube Mark and Horntube Wall cells and the easily stained granulated cells, which are found in the hoof of the young horse, are also seen in the Ergot. I cannot find such well developed Horntube Mark and Horntube Wall cells in the Callosity and the Pad.

In my histological study of the Ergot I have remarked the following important points:

- 1) A well developed Papillae which penetrates the Prickle Cell layer, made up of the Horntube Mark in Stratum Cornium,
- 2) The number of Papillae is greater than in the Callosity and the Pad,
- 3) In all other respects it is similar to the Callosity.

As I have written above, from my microscopic studies, the histological structure of the Ergot is the same as that of the Callosity, especially in the

full development of the Papillae. Such well-developed Papillae are not found in the Pad and other common skins. That the histological structure of the Ergot resembles that of the Callosity has already been declared by Professor Ellenberger and other zoologists. Professor Zietzschmann and others have said that the Ergot and the Callosity are rudimentary pads. If this were the case, their histological structure should be the same as, or at least be similar to, that of the Pad. This resemblance I have not been able to find in my studies, and therefore believe that the Ergot and the Callosity are rudimentary digits.

That, by means of histological and embryological studies, I find the Callosity to be a rudimentary digit, I have already explained in "Archiv fuer wissenschaftliche und praktische Tierheilkunde", Band 39, Heft 6, 1903; from which I will only repeat the most important points for the sake of clearness. At that time I proved my opinion from Papillae in all grades of development. These I have divided into four periods:

- 1) In this stage the Papillae have a flat outline, very little waved, and are found in less developed skin as the hornified tissues in a very early stage.
- 2) In this stage the Papillae are cone-shaped. These are found in the sole pad of the cat and dog.
- 3) In this stage the Papillae penetrate other layers and reach the hornified surface. These are found in the Horn of a three month's calf and in the Callosity of a full grown horse.
- 4) In this stage, fully developed and secondary Papillae are found, of very complicated form, as can be seen in the Hoof and Claw.

Thus the hornified tissue can be distinguished according to the grade of development of the Papillae. Now let us see to which grades the Papillae of the Callosity, Ergot and Pad belong.

As I have written in 1913, the Papillae of the Callosity belong to the third grade of development. After still further research I am in a position to declare that the Papillae of the Ergot belong to the third grade and those of the Pad to the second grade of development.

And now I should like to ask the theorists who affirm that the Callosity and Ergot are rudimentary Pads the following question. "Why are the Papillae and hornified conditions of the hornified organs, the Callosity and Ergot of the horse, which to-day are useless to their possessors, more developed than that of the pad of the cat and dog which is still a useful organ to its possessor.?"

If the Callosity and Ergot are rudimentary pads, the histological structure of the Papillae should be the same as, or similar to, that of the pad.

The rudimentary pad theorist might perhaps say that the pad of the horse had been in a more developed state than that of the dog and cat, but when the histological structure of the Frog is observed the Papillae are found to be less developed than in the Callosity and Ergot and the tops do not penetrate the Prickle Cell layer but are merely enveloped by it, precisely similar to that of the pad of the dog and cat.

From this I infer that the Ergot and Callosity were formerly digits and that the Frog of the hoof is a rudimentary ball.

Professor Zietzmann in the "Morphologie, Genese und Bedeutung von Kastanie und Sporn der Equiden", published his opinion that the Callosities and Ergots of Equidae are rudimentary pads, thus supporting Ewart's and Hinntze's theory. His histological and embryological investigations were very extensive and in opposition to the rudimentary toe theorists he wrote (page 12):

"The histological structure of hoof, claw and nail have quite another characteristic, and even the peculiarity that a prominent mass (hoof, claw, nail) composed of horn cells and closely bound to the underlayer is thrown off from the place of its origin over a wide surface of the cutis vera before it appears with its distal edge. This characteristic procedure affects such organs in the same manner as a stamp, heavily pressed would, so that it appears quite distinctly in the most rudimentary stages. I am thinking especially of the hind claws of ruminants and particularly of some kinds of deer, which are very little developed but which clearly show the aforesaid growth ten-

dency. Nothing of this, however, is to be seen on either the Ergot or the Callosity."

The question may be put by other theorists: "Why, if the Callosity and Ergot are rudimentary digits, are they found in such impossible positions?"

Before answering this question, I should like to give the results of my observations of the Callosity and the Ergot. I have already published the greater number of these observations of the Callosity in 1913. Since that time, however, I have made further studies of the Callosities of several other species of Equidae and of the Ergots of all Equidae.

Race name		Fore Callosity			Hind Callosity		
		Length	Breadth	Height	Length	Breadth	Height
Belgian	left	3,6	5,6	6,23	2,16	3,7	4,66
	right	3,4	5,46	6,00	2,33	3,65	4,51
Persian	left	3,82	4,7	6,4	2,1	4,2	4,1
	right	3,62	4,6	6,4	2,1	4,1	4,5
Clydesdale	left	3,1	4,0	4,05	2,4	3,6	2,6
	right	3,1	3,7	3,8	2,4	1,65	3,05
English Thoroughbred	left	1,4	2,9	0,7	0,87	1,5	0,55
	right	1,45	2,98	0,75	0,75	1,55	0,55
American Trotter	left	2,0	3,9	0,76	1,5	2,4	0,66
	right	2,0	3,8	0,8	1,4	2,2	0,6
English Thoroughbred, reared in Australia.	left	2,0	4,0	0,8	1,7	2,3	0,5
	right	2,0	3,8	0,6	1,7	2,3	0,4
Japanese horse × English Thoroughbred (½ English Thoroughbred.)	left	2,3	4,1	0,7	1,5	2,0	0,46
	right	2,5	4,2	0,6	1,5	2,0	0,43

As the above table shows, the Callosities of the heavy horses are larger and more fully developed than those of the lighter breeds, but in both cases they are larger on the fore than on the hind feet.

With donkeys and zebras it is only to be found on the fore feet. By examination of the stuffed specimens of different breeds in the British Museum, I have obtained the following results:

Race Name		Fore Callosity			Hind Callosity			
		Length	Breadth	Height	Length	Breadth	Height	
Equus Grevyi	(a) left	cm. ,6	cm. 1,0	cm. —	cm. —	cm. —	cm. —	
	right	,8	1,7	—	—	—	—	
	" (b)	left	,9	2,1	—	—	—	—
		right	1,1	2,0	—	—	—	—
Equus Samalicus	left	2,0	4,0	—	—	—	—	
	right	2,1	4,3	—	—	—	—	
Equus Burchelli (Burchelli Zebra)	left	2,0	3,2	—	—	—	—	
	right	2,1	3,4	—	—	—	—	
Equus Asinus Africanus (Nubian Wild Ass)	left	2,3	2,4	—	—	—	—	
	right	2,2	2,5	—	—	—	—	
Equus Caballus Prezwalskii (Mongolian Wild Ass)	left	1,5	3,0	—	0,3	2,2	—	
	right	1,6	2,9	—	0,4	2,1	—	
Equus Heminous Kiang	left	4,1	7,4	—	—	—	—	
	right	4,0	7,0	—	—	—	—	
Equus Quagga	left	2,9	5,0	—	—	—	—	
	right	2,8	5,3	—	—	—	—	

In the case of the Callosities of the bastards, Professor Ewart has published his observations in the "Proceedings of the Royal Society of Edinburgh", p. 467. He writes, "Among the Esquimaux hybrids the Callosity is absent; among Mongolian hybrids it is absent on the right fore foot and quite small on the left; while on the zebra hybrids it is very large on the hind feet." Many other zoologists have also recorded the results of their studies of the Callosities of the mule, eselzebroid and hinny. All these observations point to the same conclusion that when Callosities are found on both fore and hind feet, they are larger on the former than on the latter; and that when only one pair is found, this is always on the fore feet. On the contrary, when Ergots are found on all four feet, they are larger on the hind feet than on the fore; and when only one pair is found, this is always situated on the hind feet.

Thus we see that while the histological structure of the Callosity and Ergot is similar, the position of the larger pair is in the one case on the fore feet and in the other case on the hind feet.

How is it that such a peculiarity should have arisen among Equidae?

To account for it I will first write of the Callosity. That the Callosity is a rudimentary nail from its histological structures, and the reason of its being found either on the fore feet only or when on both fore and hind feet larger on the former than on the latter, I have already explained, but will now briefly repeat.

When the digits of different Mammalia are observed, it is found with a few exceptions that when the number on the fore and hind limbs is different, this is always greater on the fore than on the hind limbs, and that when fore and hind limbs have the same number, those on the fore limbs are always more developed than those on the hind.

Man and the man-like apes have five perfect digits on all four extremities, but those on the hind limbs are smaller than those on the fore.

Among dogs, five toes are found on the fore legs and four only on the hind legs, sometimes with a fully developed fifth.

Cattle have four toes on the fore and hind feet, with two degenerated so-called after-claws.

Tapirs have four toes on the fore feet and three on the hind feet.

Parameles have three toes on the fore feet with rudimentary first and fifth, on the hind feet two toes with rudimentary first, second and third.

The Equidae have one toe on both fore and hind legs.

Why is there this difference between the digits of the fore and hind limbs?

The fingers of the fore extremities serve to take up nourishment and for purposes of suckling, while those of the hind extremities are only used to support the body or for movement, and therefore they need to be more developed on the fore than on the hind limbs.

When we observe the many specimens in the Natural History Department of the British Museum, and if we believe the theory of English naturalists of the development of the Equidae, we can understand that the Callosity, which from its histological structure is a rudimentary digit, is always more

fully developed on the fore limbs. For example, *Hyracotherium*, found in the lower Eocene, had four fully developed toes on the fore feet and two functional lateral toes on the hind feet; other *Paraeotherinae* in the Eocene and *Oligocaen* had somewhat rudimented lateral toes further from the ground, so that the function was lost, and the present horse uses only one toe to walk with.

This theory has been proved by many naturalists, so that, from the development of the horse, we see that the fore foot has always borne a larger number of fully developed digits than the hind foot.

If we observe this development of the digits of the horse, and the condition of the digits of all present mammals, that the greater development is always found on the fore feet, also that the callosity is either found on the fore feet alone, or is larger on the fore than on the hind feet, we must conclude that these facts are connected.

From my own histological observations and from these three facts, I infer that the Callosity must be a rudimentary digit.

For the theorists who affirm that the Callosity is a rudimentary pad, I must write that with the ox and deer which are now true digitigrades, the organ that corresponds to the pad is greatly rudimented and is sometimes scarcely to be seen, especially the pad which should belong to the after-claws. Only at the junction of the claw wall and the common skin can a slight trace be discerned, but sometimes not even that.

That, among the present Equidae, whose remote ancestors—those at least earlier than the *Hipparion*, as fossils indubitably show—had already developed from plantigrades to digitigrades—a large rudimentary pad should still be seen, is quite impossible!

In order to compare the after claw with the ergot I should like first to write something of the after claw.

The after claw of Ungulata, which is found on the fetlock,—of what use is this to its possessor? It is clear that this organ, which is not so rudimented, that is, not so far from the ground, as in the ox and deer, is found

among animals so that when they walk on soft or marshy ground they may not sink too deeply into the yielding earth, and when the animal is accustomed to walk on steep hilly ground the after claw is needed as a support. These less rudimented after claws of the ox and deer are of similar development on fore and hind feet, but among the Ungulata, which have a quite rudimented after claw, we find a difference in the size on the fore and hind limbs. In particular, the after claw on the forefoot of the Madoquo Phillipsi is very small and that on the hind foot very large.

I have obtained the following result, that the more rudimented and useless the after claws the nearer they are together. For example, the fully rudimented after claws of the *Dorcotragus Megarotis* (Pl. VIII. Fig. 2), especially on the forefoot are quite close together and appear as one; the claw wall of its after claw has been thrown off and it has the appearance of a pad.

In particular, when the histological structure of such a fully rudimented after claw is seen, the Papillae are simpler than in the Ergot and Callosity of Equidae, and the hornified cell layer is thicker, that is the Stratum Corneum is not degenerated, than in the Ergot and Callosity.

That the Callosity and Ergot which have a more developed histological structure than the after claw of the *Dorcotragus*, should be rudimentary pads is not to be considered, because, as I have written above, the pad which is still functional is less developed than the Callosity and Ergot. I must here describe what I mean by the development of a hornified mass, which I have sometimes mentioned. This is the degree of development of the Papillae in the hornified tissue and of the horny layer. Because the Papillae always contain fine blood vessels which carry nourishment to the layers above, when the Papillae are developed the layers above will be equally so; such a fact may be seen in every hornified mass found on mammals, for example, in the fully developed hoof of the horse quite complicated Papillae may be seen with secondary Papillae. From such complicated Papillae to those of simple, nearly flat form which are found in the tissue of the very little developed hornified skin, the degree of development of the hornified mass is divided

into four classes as I have already described.

In the hoof, however, at the early embryological stage, the Papillae are quite simple.

The above results of my own observations show that the Callosity and Ergot which the present Equidae carry must be rudimentary toes.

I now wish to write of the frog, which, found in the hind part of the hoof, of Equidae, is a rudimentary pad which belongs to the toe, in order to ascertain its morphological connection with the Callosity and Ergot.

I have measured the frogs of various kinds of Equidae with the following results :

Race Name	Fore Hoof				Hind Hoof			
	a. b.	c. d.	e. f.	g. h.	a. b.	c. d.	e. f.	g. h.
Equus Burchelli	5½ cm	11 cm	6,2cm	1½ cm	7½ cm	10 cm	6½ cm	2 cm
Equus Grevyi	3,2cm	8,2cm	6,2cm	1,5cm	4 cm	8 cm	7 cm	2 cm
Equus Chapnani (a) left side	6½ cm	11½cm	6 cm	2½ cm	7 cm	10 cm	6 cm	3 cm
Equus Chapnani (b) right side	6 cm	10,2cm	6,4cm	1,4cm	5,8cm	10 cm	7 cm	2 cm

a. b.....distance of two bases of bulbar expansion of periopilic ring, which is seen to be continuous with the sensitive frog

c. d.....distance between middle point of frog base and point of hoof

e. f.....length of frog

g. h.....breadth of frog

As these show, with most Equidae, the frog of the hind foot is always larger than that of the fore foot, especially in the Kiang and Grevy's zebra, where the frog of the hind foot touches the ground. It is clear that this has come from the fact that the angle which the hind foot makes with the ground is always smaller than that of the fore foot. We can tell that the present frog is still useful as a pad to the hoof. For the same reason we may infer that the Ergot formerly served as a support to the foot and was used at a later period by the hind foot than by the fore, and is therefore more rudimented on

the former than on the latter, also that the fore foot is a truer toe-walker with one hoof than the hind foot.

Finally, I have classified the Equidae according to the number and position of the Ergots and Callosities, which are rudimentary toes, in order to find out what condition the rudimented toe has on different kinds of Equidae and how the finger and toe have developed, as follows :

1. With Callosity and Ergot on both fore and hind feet.
2. With Callosity on fore foot but not on hind foot, and Ergot on hind and fore foot.
3. With Callosity on fore foot but not on hind foot, and Ergot on hind but not on fore foot.
4. No Callosities or Ergots on either fore or hind feet.

To compare with the Ungulata I have given the following table :


1. With two after claws on both fore and hind feet, all of the same size.
2. With two after claws on both fore and hind feet, but larger on the hind than on the fore feet.
3. With no after claws.

From the above table I can draw the following inference : from the fact that the fore extremities are always used for picking up food or for means of attack, their digits are more developed than those of the hind which are only used for support or to assist movement. The Callosity, which, as written above, is always more developed, must be the rudimented organ which was formerly used by Equidae for picking up food or as a weapon of attack. There must also be some connection between the facts that the Ergot is always larger on the hind foot among Equidae, and the after claw among cattle.

In order to make this clear, if the foot bones of those animals which now possess five fingers are compared with those of the Equidae, the following conclusion may be drawn : the first finger of Equidae was the earliest rudimented, as the hind foot finger of the present dog, then the second and fifth fingers were rudimented, which condition may be seen in the foot of the present pig. Still more rudimented second and fifth fingers are to be seen in

the after claws of cattle. This was the development in the case of the Ungulata, but with the Perisodactira the first finger was rudimented, then the fifth, fourth and second in order. That the fourth finger was rudimented earlier than the second may be seen from the splint bones of the present Equidae, because the inner splint bone is always larger and longer than the outer. From this fact I infer that the Callosity is the nail of the second toe and the Ergot of the fourth toe. But when the present position of the Callosity and Ergot is observed it appears to be a curious place for a nail to grow. To that I will answer that in a perfect finger the nail should be at the tip, but in the case of a rudimented finger there is no connection between the finger bone and the nail. A good example of this may be seen in the nail of the first finger of the hind foot of a dog, the position of which has so greatly altered. In particular, when the finger bone has no function as finger and the nail is still of use to its possessor, the latter always remains in a useful position, and the bone only is rudimented. From this fact, with the Equidae, as the second and fourth fingers only were rudimented, the nail of the fourth finger, the Ergot, was of use, like the after claw of cattle; the nail of the second finger of the foot remained as a means of attack, and it can be seen that when a horse fought with its enemy, hugging him with the fore feet, the Callosity might have been a useful weapon.

From the above morphological and histological results it is not to be believed that the Callosity and Ergot which present Equidae bear are, as Zietzmann and other zoologists state, rudimentary pads, and I must affirm that they are rudimentary digits.



Literature

- 1.) Yoschida Morphologische und physiologische Bedeutung der sogenannten Kastanie an den Gliedmassen der Equiden. aus dem Archiv f. wissensch. u. prakt. Tierheilkunde. Bd. 39. Heft. 6. 1913.
- 2.) Professor Dr. Otto Zietzschmann. Morphologie, Genese und Bedeutung von Kastanie und Sporn der Equiden. Aus der Festschrift der Dozenten der Universitaet Zürich. 1914.



Explanation of Plates**Plate VII.**

- Fig. 1. Cross section through Ergot
 Fig. 2. Cross section through Pad of Dog
 Fig. 3. Cross section through Pad of Cat

Plate VIII.

- Fig. 1. Cross section through Ergot. (original size)
 Fig. 2. Fore and hind Foot of *Dorcotragus Megarotis*. (p—pad)
 (1/3 size)
 Fig. 3. Diagramatic view of fore and hind Hoof of Horse. (a—fore
 foot, b—hind foot)

b.....blood vessels
 c.....corium
 e.....epidermis
 p.....stratum papillae
 pig.....pigment
 s. t.....prickle cell layer
 str. c.....stratum corneum
 str. g.....stratum granulosum
 str. germi. stratum germinativum
 str. l.....stratum lucidum
 str. m.....stratum mortificatum
 str. reticustratum reticulare
 str. subcu. stratum subcutaneum

Fig. I.

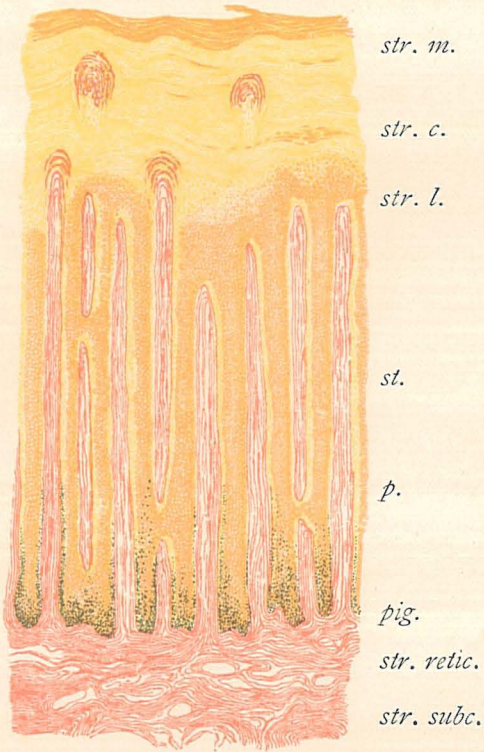


Fig. II.

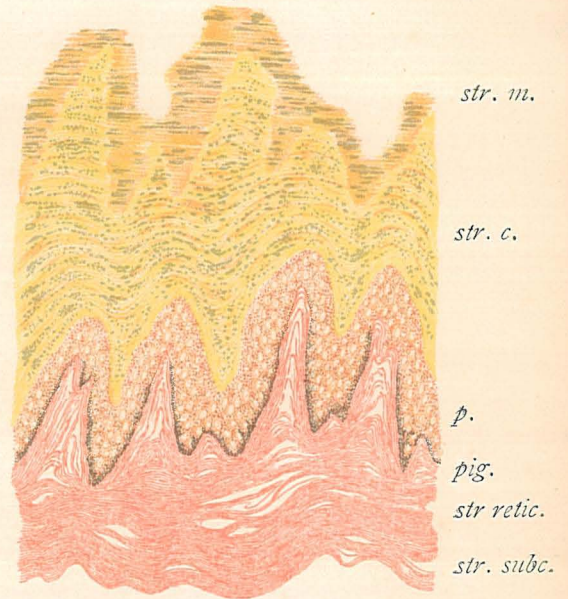


Fig. III.

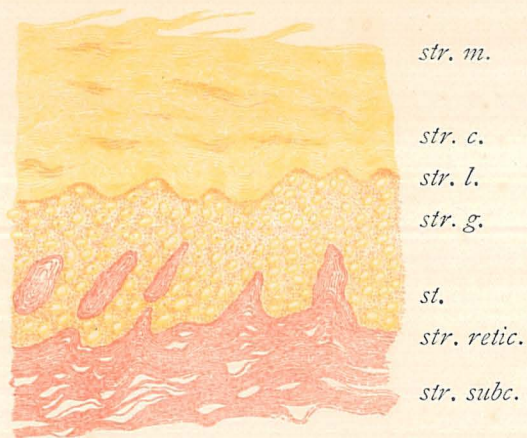

Fig. I.

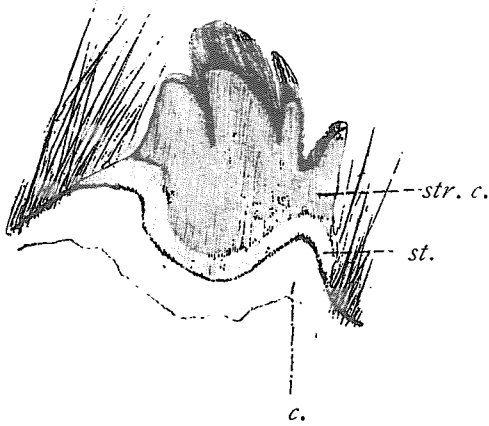


Fig. II.

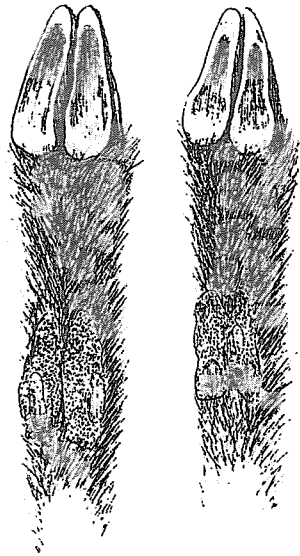


Fig. III.

