



HOKKAIDO UNIVERSITY

Title	Cyclic Changes in the Female Genital Mucosa of the Normal Estrous Rabbit
Author(s)	TSUTSUMI, Yoshio
Citation	Journal of the Faculty of Agriculture, Hokkaido University, 54(2), 151-170
Issue Date	1965-12
Doc URL	https://hdl.handle.net/2115/12815
Type	departmental bulletin paper
File Information	54(2)_p151-170.pdf



CYCLIC CHANGES IN THE FEMALE GENITAL MUCOSA OF THE NORMAL ESTROUS RABBIT

By

Yoshio TSUTSUMI

Department of Animal Science,
Faculty of Agriculture,
Hokkaido University,
Sapporo, Japan

Cyclical changes in the vaginal smear of the rabbit have been reported by several investigators. Nucleated epithelial cells appeared regularly and abundantly during estrus, but cornified epithelial cells and leucocytes appeared irregularly during the sexual cycle (9, 20, 33, 40, 41, 45, 46, 47, 55, 56, 57, 61). The ovary in the rabbit may bear two phases, the mature follicle phase and the immature follicle phase (21, 23, 50, 62). The mucus of the reproductive tract shows variations in pH value attributable to the stage of the sexual cycle. The cyclical variations in the pH of the vaginal mucus in the rabbit were reported by ABE (1) and TSUTSUMI and MATSUMOTO (56, 57). During the sexual cycle, the vaginal mucus varied in composition; an alkaline group occurred alternately with a neutral one every 5.6 ± 2.5 days (TSUTSUMI and MATSUMOTO, 57). HAMILTON (20) observed cyclic variations in the vaginal smear, blood estrogen level and histology of the reproductive tract in the rabbit. MYERS and POOLE (40) observed behavior of female rabbits running with vasectomized males. The animals periodically became sexually attractive to these at short intervals of 4-6 days, or multiples thereof. The crystal morphology and epithelial cell numbers from the vaginal flushing and the pH fluctuation in the vagina are closely correlated to the number of follicles on the surface of the rabbit ovary (TSUTSUMI and MATSUMOTO, 59).

The present study deals with histological observations on the genital mucosa in relation to the sexual cycle.

MATERIALS AND METHODS

Eleven normal 18-month old 3 kg. female rabbits were used. The does were slaughtered at various stages of the vaginal cycle. The vaginal cycle was

determined by the following methods. The vestibule was flushed with physiological saline and the flushing placed on two slides. One of the slides was left untreated while the fluid was removed from the other with a pipette in order to make a thin film of solution on the slide. Both slides were dried, fixed with methanol and 10% silver nitrate solution and stained with GIEMSA's solution. The former was used for observation of the epithelial cells and the latter for the shape of dried smear. The pH value of vaginal fluid was checked using pH test paper. A narrow glass tube was inserted into the vaginal orifice through the vestibule a distance of 7 cm. A spatula with a piece of the test paper at its tip was inserted into the tube and then removed and read.

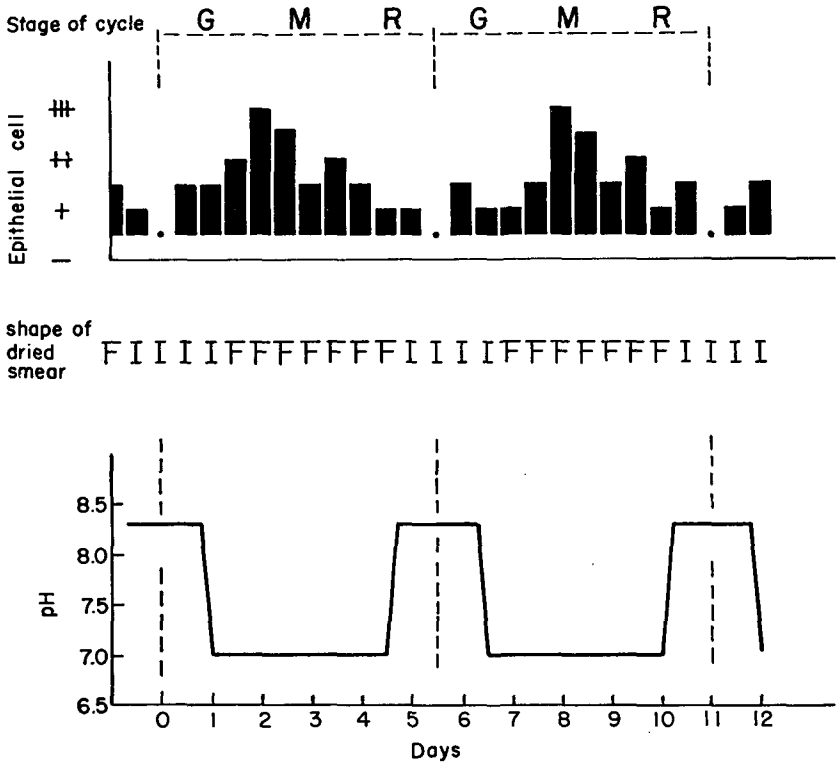


Figure 1. Diagram of cycle in the vaginal mucus. Nucleated epithelial cells appear abundantly during the mature follicle stage. In the dried smear, the F-type shape predominates during the mature follicle stage. Cyclical variations occur in the pH of the vaginal mucus.

G-Growing follicle stage; M-Mature follicle stage;
 R-Regressing follicle stage; F-Fern- and Chrysanthemum-like figures; I-Polygonal Figures.

Fluctuations in these three tests were rated as follows :

- 1) Appearance of the epithelial cells in the vaginal flushing.
 - (##)—Large number of cells forming a mass on the slide.
 - (++)—Small masses of cells sporadically scattered among densely scattered cells.
 - (+)—Cells scattered sparsely.
 - (—)—Few recognizable cells.
- 2) Differentiation of the shape of dried smear.
 - (F-type)—Fern- and Chrysanthemum-like figures.
 - (I-type)—Polygonal figures.
- 3) The pH value was traced continuously.

The cycle in the vaginal mucus are shown diagrammatically in Figure 1.

The ovarian follicles in each slaughtered rabbit were observed macroscopically. The ovarian cycle was classified by the life span of the largest follicles in the ovaries into three stages, *i. e.*, (1) *the growing follicle stage* (the follicles are growing); (2) *the mature follicle stage* (the follicles reach their maximum diameter); (3) *the regressing follicle stage* (the follicles are regressing). In the present study, four animals (No. 1, 2, 3, and 4) were grouped in the growing follicle stage; five (No. 5, 6, 7, 8, and 9) were grouped in the mature follicle stage; and two (No. 10 and 11), in the regressing follicle stage, one of which had blood follicles and therefore was placed in the third group (Table 1).

TABLE 1. Number of follicles in each rabbit

Groups	Animal Number*	Number of Follicles		
		Small Follicle (1-1.5 mm in diameter)	Medium Follicle (about 2 mm in diameter)	Large Follicle (2.5-3 mm in diameter)
I	1, 2, 3, 4	6, 31, 24, 15	2, 9, 3, 11	0, 0, 0, 0
II	5, 6, 7, 8, 9	15, 6, 22, 4, 22	3, 5, 5, 5, 6	4, 8, 6, 3, 3,
III	10, 11	8, 8	8, 8	3, 0

- I. Growing follicle stage.
- II. Mature follicle stage.
- III. Regressing follicle stage.

* Numbers arranged chronologically according to the stage of the vaginal cycle as judged by the vaginal mucus.

Three fixatives, Ciaccio, Helly and Carnoy, were used for the genital organs. Paraffin sections 5μ or 10μ thick were made and stained with hematoxylin-eosin, mucicarmine or azan stain. In addition, tissues from the uteri were stained with iron hematoxylin.

RESULTS

1. Oviduct

In the fimbriae region, long, finger-like folds of mucosa were accompanied by more abundant connective tissue than were in the ampulla (Fig. 2). In the region of transition from the fimbriae to the ampulla, the ostium abdominale tubae, the muscular layer was more highly developed than that in the ampulla. Large blood vessels were also present. The muscular layer sent muscle fibers or bundles into the lamina propria mucosa of the folds of the fimbria. Blood vessels were distributed more abundantly in the folds of the fimbriae than in any other portion of the oviduct. Simple epithelium was present with the ciliated columnar cells and mucus-secreting cells. However, the mucus-secreting cells were very scant in number and weak in mucification. The epithelial cells of the fimbriae were lower in height and rougher in arrangement than those of the ampulla.

The lumen of the ampulla was broader than that in the isthmus but it was filled with many slender, delicate, long folds of mucosa. The folds were winding and had few branches. Epithelial cells were taller than those in the isthmus and were pseudostratified. The number of ciliated columnar cells exceeded that of mucus-secreting cells. The cells at the tops and projections of the folds were more intimate than in other parts of the epithelium as in the isthmus. Connective tissue was sparse in the folds of the ampulla (Figs. 3, 4).

In the isthmus, the lumen was somewhat narrower than was the ampulla (Figs. 5-7). Several large folds of mucosa, papilla like in shape, were arranged radially in the lumen. However, the height of folds was relatively short compared to that of the ampulla. The mucosa was lined by a simple columnar epithelium, which was formed by ciliated and mucus-secreting cells. The number of mucus-secreting cells predominated over that of the ciliated cells in this region. Epithelial cells were tall and in close proximity to one another. However, the epithelial cells in the fossae and basal regions of the folds were somewhat unevenly arranged and tended to be shorter than those in the ampulla. The nuclei of the ciliated cells were located in the central portion of each cell, whereas the nuclei of the mucus-secreting cells were located at the base of the cell. Mucus secretion in the isthmus was active in all animals, and there were no marked differences.

Very few mitoses were observed in the epithelium of the oviduct (Fig. 3). There were many small vacuoles filled with mucus located near the base of

the epithelial cells in all animals. In No. 3, somewhat larger vacuoles were seen in the epithelium, and two mitoses facing two vacuoles were shown (Fig. 3). The epithelial cells surrounding the large vacuoles had very little cytoplasm and were cuboidal or squamous in shape. Cytoplasmic projections of epithelial cells into the lumen of large vacuoles were observed. Desquamated cells were enclosed in some large vacuoles.

Generally, the histological feature of the oviduct in each animal, was not so variable. However, in the mature follicle stage, the folds of mucosa were more branching and angular and the mucus secretion was more active than in the other two stages.

2. Uterus

Both uterine horns were divided into five segments. Cross sections were taken from three segments and longitudinal sections were taken from two segments.

Generally, the uterine mucosa was simple epithelium that was composed of three kinds of cells, ciliated, mucus-secreting, and non-ciliated non-mucus-secreting. The appearance of these three types varied greatly, not only from one portion of the uterine horn to another but also from one area in a section to another. The epithelial cells were cuboidal or cylindrical. It seemed that the non-ciliated non-mucus-secreting cells were either degenerating forms or precursors of the other two kinds of cells (Figs. 12, 26). The three types of cells were arranged individually or in groups. There was a tendency for the non-ciliated non-mucus-secreting cells to predominate at the base of the endometrial folds. The ciliated cells had highly stained cytoplasm and were larger in size than the mucus-secreting cells. The nuclei of these cells were round or oval in shape and located centrally or near the free surface of cells. The mucus-secreting cells were narrow and tall compared to the ciliated cells. Their cytoplasm and nuclei both stained intensely. In many cases the free surfaces of these cells swelled and projected independently into the uterine lumen (Figs. 11, 14, 19, 20). Both the nucleus and cytoplasm in the cells of uterine glands stained weak. The cells showed cylindrical or cuboidal shapes and were arranged radially to the glandular lumen.

1) The growing follicle stage

Within the No. I Group, the 4 rabbits were identified as No. 1, 2, 3, 4. The numbers arranged chronologically according to the stage of the vaginal cycle as judged by the vaginal mucus.

In No. 1, the surface of the endometrial folds was smooth. The uterine glands were short and located mainly near the surface of the folds (Fig. 9). In longitudinal sections, the folds showed simple papillae-like shapes and were parallel, like the teeth of a comb (Fig. 8). Slight mucus secretion was evident in the uterine epithelium. The average number of mitoses in the endometrial cross sections was 2.8.

In No. 2, the folds were contracted. The uterine glands were located near the surface of the folds. The epithelial cells were cuboidal or flat. Non-ciliated non-mucus-secreting cells were predominant and the ciliated and mucus-secreting cells were obscure (Figs. 11, 12). Large vacuoles occurred in some folds and seemed to originate from the lumen of uterine glands (Figs. 31, 33, 34). Their sizes and shapes were various, and the features of cells surrounding these vacuoles were various. In some vacuoles, the epithelial cells were lost, desquamated into the lumen, and the connective tissue was facing the lumen directly. In some specimens, cells of the connective tissue surrounding the vacuoles were swelling to fill the lumen. The average number of mitoses in the endometrium was 16.6 per 5μ cross section.

In No. 3, the folds became more angular than those in No. 2, but still retaining the papillae-like shape in longitudinal section (Fig. 10). The uterine glands were elongated, reaching the central portion of the fold, and some glands showed branching. The endometrial epithelium showed weak mucus secretory activity. The epithelial cells were taller than those in No. 1 and 2. The non-ciliated non-mucus secreting cells predominated. The average number of mitoses per cross section in the endometrium was 11.5.

In No. 4, slight expansion of the glandular lumen occurred. The surface of the folds was broken by many glandular openings. Therefore, some ob-mesometrial folds had remarkable branching (Fig. 13). These breaks were located near the surface of the fold. The height of the epithelial cells became greater. Only a few non-ciliated non-mucus-secreting cells were located at the bases of the folds. The ciliated cells and the mucus-secreting cells were mixed equally (Fig. 14). The average number of mitoses per cross section in the endometrium was 30.0.

2) The mature follicle stage

In this stage, the five animals were identified as No. 5, 6, 7, 8, and 9.

In No. 5, the folds were sharply broken by expanded glandular openings, resulting in an irregular surface. Some of the folds had mushroom-like structures in the longitudinal sections (Fig. 15). The glands elongated to reach the deep portion of the folds near the mesometrium and most lumina were enlarged

(Fig. 16). Some folds had a network construction of large glandular lumina; however, some lumina were cystic as described in No. 2 (Fig. 32). There were very few non-ciliated non-mucus-secreting cells. The mucus production of the epithelium seemed to be high. In this animal, crystal-like substances were present in the uterine lumen, glandular lumen and endometrium (Fig. 16). The average number of mitoses per cross section in the endometrium was 18.8.

In No. 6, the folds were markedly branched, more irregular in shape than those in No. 5, and spongy in structure with expanded glandular lumina (Figs. 17, 18). The epithelium was composed chiefly of ciliated and mucus-secreting cells (Figs. 19, 20). The glandular cells facing the expanded glandular lumina changed to ciliated or mucus-secreting cells, similar to those in the uterine epithelium, though the glandular cells located near the myometrium still retained their proper character. The mucus secretory activity of the uterus was very high. The average number of mitoses per cross section in the endometrium was 12.9.

In No. 7, the folds which were irregular in shape branched markedly in some portions. However, the textural irregularities on the surface of the folds were not so sharp as those in No. 6 (Fig. 21). The height of the epithelial cells decreased. Degeneration of the cells at the tops of folds was evident. The mucus-secretory activity in the uterus seemed to be weak. In some specimens, the crystal-like substances were evident in the endometrium. The average number of mitoses per cross section in the endometrium was 1.7.

In No. 8, the uterine glands were distributed abundantly in the mucosa. The folds became irregular in shape due to expansion of the glandular lumina. Some of them had a mushroom-like shape in longitudinal section (Fig. 22). The epithelial cells were tall. Non-ciliated non-mucus-secreting cells were sparse. The cells in the glandular lumen appeared to be the same as those in the uterine epithelium. In other words, there was no differentiation between the epithelial cells of the uterine lumen and the glandular lumen. The mucus-secretion of the uterus was high. The average number of mitoses per cross section in the endometrium was 7.2.

In No. 9, the folds showed a hilly appearance in cross section and a papillae-like shape in longitudinal section (Figs. 23, 24). The texture of the surface was not markedly rough. The epithelial cells were low, cilia were irregular, and the mucification was very weak (Figs. 25, 26). These phenomena probably indicate a decrease in the mucus secretory activity of the uterine mucosa. Crystal-like substances were seen in the uterine lumen and the endometrium. Sometimes, small cystic lumina also existed in the endometrium. The average number of mitoses per cross section in the endometrium was 49.0.

3) The regressing follicle stage

In the 3rd Group, the two animals were identified as No. 10 and No. 11.

In No. 10, the folds had a somewhat irregular surface, though the breaks of the surface were not so marked as in other specimens (Fig. 27). The uterine glands were located near the surface of the folds, and their lumina were expanded to some degree. However, most of the orifices of the glands were closed (Fig. 28). The glandular lumina were united in some areas, and disquamated epithelial cells were observed in many of these lumina. These features gave the impression that the expanded glandular lumen became a cystic lumen by constriction of the orifice of the gland during development of the mucosa. The thickness of epithelial cells narrowed and the cells were arranged irregularly. The cilia of the ciliated cells were degenerated. The non-ciliated non-mucus-secreting cells were predominant. The mucus secretory activity was weak although mucus remained in the uterine lumen. Many crystal-like substances were evident. The average number of mitoses per cross section in the endometrium was 11.7.

In No. 11, papillae-like folds in longitudinal section were shallow and broken by uterine glands (Fig. 29). The epithelial cells were cylindrical, and differentiation to ciliated and mucus-secreting cells was clear. However, the mucus secretory activity seemed to be low. The average number of mitoses per cross section in the endometrium was very large, 183.2.

3. Cervix

The cervical mucosa had large longitudinal folds similar to those of the uterine mucosa. The folds which were always slenderly and delicately branched had triangular shapes and were arranged radially to the lumen in cross section. The epithelium was simply composed of cylindrical cells which were mixed with ciliated and mucus-secreting cells similar to those in the oviduct (Figs. 38-40). However, the cells were not so tall as the epithelial cells in the oviduct. It seems that ciliated cells outnumbered the mucus-secreting cells. Ordinarily, the round or oval nuclei of the ciliated cells were located at the central portion or near the free surface of the cell. The mucus-secreting cells were narrow compared to the ciliated cells, and they had densely stained slender nuclei located near the base of cells. A large number of round or oval bodies in epithelial cells as reported by LOEB and SMITH (36), were recognizable (Fig. 38). These bodies and mucus stained similarly which suggests that these bodies might be precursors of cell vacuoles as is the case in the epithelium of the oviduct. The vacuoles were located mainly near the base of the cells.

Generally speaking, histological features in the cervical mucosa in each animal were quite similar, although a few variations were seen in the height and vacuolation of cells, branching of folds, and mucus secretion. There were only a few mitotic figures in the cervical epithelium. Only one mitosis was recognized in a section from No. 3 (Fig. 39).

4. Vagina

The vagina had the broadest lumen of the genital tract and the vaginal mucosa formed many folds which were arranged longitudinally in parallel. The folds were delicately branched. The mucosa was covered with simple columnar epithelium composed almost entirely of mucus-secreting cells (Fig. 42). A few ciliated cells were scattered in the epithelium of some animals. Epithelial cells were arranged densely at the projection of folds. Round or oval nuclei were located at the base of these epithelial cells. The cells at the fossa or base of the fold were arranged irregularly, were broad in size, stained lightly, and tended to have pyknotic nuclei located at the base of the cell. A few mitotic figures were seen. Vacuolation of the epithelial cells occurred in some specimens. The transition from cervical to vaginal epithelium was not clearly marked. A clear-cut transition was evident where the vaginal epithelium joined the epithelium of the vestibule. In some specimens, the wandering cells of the mucosa, chiefly lymphocyte-like cells, polynuclear leucocytes and plasma like cells, gathered at the tops of the projections of the folds.

1) The growing follicle stage

In No. 1, branching of the folds was not so delicate as that of later stages and the surface of the folds was smooth (Fig. 41). The nuclei of the epithelial cells were round or oval. Several mitoses are evident in the epithelium. The location of mitoses was not constant, but for most part, they were at the base of the fold (Fig. 43).

In No. 2, branching of the folds was sharp (Fig. 44). The mucification of the epithelial cells was not constant. In most parts, it was strong; in other parts, quite weak. A few mitoses were recognized. In some specimens crystal-like substances existed in the vaginal lumen.

In No. 3, the surface of the folds was smooth (Fig. 45). The epithelial cells irregularly arranged, from the middle of the vagina to the vaginal fornix were degenerated, and showed considerable vacuolation (Fig. 46). The cell vacuoles varied in size and were randomly located in the cytoplasm. Many wandering cells had infiltrated into the epithelium. The mucification in this

portion was weak. However, at the lower portion of the vagina, the epithelium remained normal. Only one mitosis was observed and this was in the lower part of the vagina.

In No. 4, branches of the folds reached into the lumen, although the breaks of the folds were not deep (Fig. 47). The mucus secretory activity in the epithelium seemed to be high. Ciliated cells were scattered in the epithelium in small numbers. One mitosis was recognized in a section of the upper portion of the vagina.

2) The mature follicle stage

In No. 5, folds, generally, did not branch although a few folds did have strong branching (Fig. 48). The epithelial cells were various in shape from the middle of the vagina to the vaginal fornix. In this portion, the epithelium was formed from three kinds of cells; normal mucus-secreting cells, vacuolated cells and weakly mucified cells, having darkly stained cytoplasm. The latter seemed to be in the process of cell mucification. Vacuolation in the cells was strongest in the vaginal fornix and became weaker near the middle of the vagina. In the lower part of the vagina, the folds were weakly branched and lined with normal mucus-secreting cells. No mitosis was seen. In general, there was active mucus secretion throughout the vagina. A few crystal-like substances existed in the vaginal lumen.

In No. 6, the folds were smaller than those in the other specimens. They branched and stretched into the vaginal lumen. The mucification and swelling of the epithelial cells were marked. Their nuclei were pyknotic and located at the base of the cells arranged in a row. Only a few ciliated cells appear. The mucus-secretory activity was very high. Mitotic figures were not observed in this animal.

In No. 7, the folds were large and branched. The appearance of the folds and the epithelium were the same as those in No. 6. The mucus-secretion was very strong. No mitosis was evident.

In No. 8, the epithelial cells at the vaginal fornix were reduced in height and irregularly arranged. Branching of folds was not marked, and the surface of the folds was smooth (Fig. 49). One mitosis was seen in a cross section in the middle of the vagina. Wandering cells in this animal gathered at the tops of fold projections, and some parts of the epithelium showed degeneration, irregular arrangement, and desquamation due to infiltration of the wandering cells. The mucus secretory activity still remained high.

In No. 9, the folds were large and markedly branched (Fig. 50). Mucus secretory activity seemed high due to strong mucification of cells. Clear desqua-

mation of the epithelial cell-masses at the projections of folds was observed. Some parts of the epithelium had been infiltrated by wandering cells and had degenerated similarly to parts in No. 8. In most cases these cell-masses seemed to be accompanied by some connective tissue. The cell-masses seemed to be pushed out from the epithelium into the vaginal lumen by contraction of the mucosa itself. These cell-masses were sloughed from the epithelium into the lumen (Figs. 52-55). These free cell masses appeared in large number at the middle and upper portion of the vagina. No mitosis was observed.

3) The regressing follicle stage

In No. 10, the mucosa formed large folds which were sharply branched (Fig. 51). The mucus secretory activity of the epithelium was very high. In some parts of the epithelium infiltration by wandering cells was observed. There were a few scattered ciliated cells. No mitotic figures were recognized.

In No. 11, the epithelium was very similar to that of No. 3 in the ripening stage. The folds in general were low, blunt and smooth surfaced. The epithelial cells which were markedly vacuolated were arranged irregularly. The wandering cells infiltrated into the epithelium. This indicated a degenerative process in the epithelium which became more marked toward the vaginal fornix. One mitosis was seen in the connective tissue under the epithelium in a section from the lower part of the vagina. The mucus secretory activity seemed to be very weak or inactive.

5. Vestibule

Desquamation of the surface cells was seen in each animal. There was no marked variation in the epithelium (Fig. 56).

DISCUSSION

The number of mucus-secreting cells predominated in the isthmus of the oviduct, and decrease toward the ampulla. Ciliated cells predominated in the fimbriae. The mucosa of the fimbriae exhibited some secretory activity. Many round or oval bodies were seen in the cytoplasm. These bodies showed mucus-like staining characteristics. It is assumed that some of these bodies drain their contents into the lumen of the oviduct and then become the vacuoles located in the epithelium. In some portions of the epithelium of the oviduct, mitotic figures were observed in the cells surrounding these vacuoles. The formation of the vacuoles should be related to some epithelial function, possibly regeneration. These vacuoles and mitoses were both located at the bases or

fossae of the folds in most cases. The epithelial cells were arranged compactly at the projections of the folds, while the cells at the bases or fossae of folds were arranged irregularly.

The epithelium of the oviduct was easily distinguished from that of the uterus by the tall columnar and ciliated cells. The results of other investigations concerning the uterine epithelium have not been too consistent (12, 17, 27, 28, 29, 32, 49, 63). The histological picture was quite variable throughout the uterus. There were areas with tall columnar, cuboidal or squamous cells. Moreover, ciliated and non-ciliated cells were present. It is well known that the immature female has no ciliated epithelial cells in its uterus, but ciliated cells appear in the epithelium of the mature rabbit.

Concerning degeneration and regeneration in the uterine epithelium, SAEKI (45) stated he observed expansion of the uterine glandular lumen, branching of the folds of the mucosa, and desquamation of the epithelial cells during estrum. In the present study, no marked desquamation of the epithelium was recognized. But cells sloughing into the lumen and cells degenerating by vacuolation or developing pyknotic nuclei were observed on the surface of the uterine mucosa. Free epithelial cells were also seen in the uterine and glandular lumina.

Counts of mitotic figures in the endometrial mucosa showed highest mitotic activity in the glandular epithelium, less in the uterine epithelium, and least in the lamina propria. It appears then that the glandular epithelium plays an important role in supplying new uterine epithelial cells. Although cells in the base of the gland remain unchanged throughout the cycle, during extremely high mucus secretion cells in the neck of the gland become ciliated and mucus-secreting as they move out of the orifice to become part of the uterine epithelium.

Ciliated cells in the cervix were more numerous than the mucus-secreting cells. The round and oval bodies which occurred in the epithelial cells as described by LOEB and SMITH (36) and HAMILTON (20) were observed. HAMILTON (20) claimed that at one phase the cervical projections and the vaginal recesses were covered by a simple epithelium made of broad, non-ciliated, columnar cells, while during another phase they were covered with a shallow, stratified, squamous epithelium. According to MATSUMOTO and TSUTSUMI (37), at the vaginal fornix, the columnar ciliated cells are mingled with the columnar mucus-secreting cells from the vaginal side and the number of these ciliated cells increases toward the *orificium externum uteri*. In the present study, marked changes were observed in the epithelium at the vaginal fornix. The arrangement of the cells became irregular through vacuolation of the cytoplasm to the point of degeneration. However, squamous cells were never

seen in this area.

The cytoplasm of the epithelial cells was highly mucified throughout most of the vagina. The epithelial cells were arranged compactly at the projections and irregularly at the fossae or bases of the folds. A few mitoses were seen, and they were located chiefly at the fossae or bases of the folds. Therefore, it appears that the vaginal epithelial cells move, gradually sliding on the lamina propria to the tops of the projections of the folds, similar to those in the intestinal epithelium. This was supported by the fact that masses of vaginal epithelium at the projections of folds were being sloughed off into the vaginal lumen together with wandering cells as seen in No. 52.

The vestibule was lined with a stratified epithelium which was composed of cuboidal or columnar cells of 3 to 6 layers. The lumen of the vestibule was narrow and the mucosa formed many longitudinal papillar folds. These observations agree with many other investigators (12, 20, 26, 45). Desquamation of the epithelium was observed in all animals.

The cyclic changes of the genital mucosa in the normal female rabbit has been described by IWATA (28, 29) and HAMILTON (20).

The mucus secretion of the oviduct was always high, especially in the isthmus. Although HAMILTON (20) claimed that the results of histological observation of the oviduct were uniform, regardless of the vaginal smear picture, observations in the present experiment showed little variation in secretory activity in the ampulla and fimbriae. The mucus secretory activity was strongest and branching of the folds was more delicate in the mature follicle stage than in the other two stages. There were only a very few mitotic figures in the mature follicle stage. Cell vacuolation was observed in all animals but its cyclic behavior was obscure.

In the growing follicle stage, the uterine mucosa was contracted, the folds of the mucosa were hilly in shape and smooth surfaced. The uterine glands were short and located near the surface of the mucosa. The epithelium was thin. Many non-ciliated non-mucus-secreting epithelial cells appeared. The arrangement of cilia of the ciliated cells was irregular and the mucification in the mucus-secreting cells was scant. In a longitudinal section, the folds were papillar in shape and arranged like the teeth of a comb. A few mitotic figures were observed.

In the stage preceding this, uterine glands elongated and began to branch to some degree. The epithelial cells became taller and non-ciliated non-mucus-secreting cells decreased in number. The ciliated cells and mucus-secreting cells appeared to be in a healthy condition. In the epithelium of the uterine mucosa and uterine glands, many mitotic figures were seen. Lumina of the

uterine glands became broader near the surface of the mucosa and the surface of the folds became irregular.

In the mature follicle stage, the lumina of the uterine glands were markedly expanded, except in deeper parts located near the myometrium. There, the folds were strongly branched. In shape, some folds showed a weak progesterational condition. As in the case of uterine epithelial cells, the glandular epithelial cells facing these expanded lumina changed to the ciliated or mucus-secreting cells. Mucus secretory activity seemed to be highest in this stage. The sloughing off of some parts of the branching folds from the endometrium may occur at this time. There were very few mitotic figures.

In the regressing follicle stage, the mucus secretory activity became weak. The lumina of the uterine glands were closed and shortened. The surface of the folds became smooth. The epithelial cells were short in height and the cilia were irregular in arrangement. Many non-ciliated non-mucus-secreting cells appeared. A number of mitoses were observed.

According to HAMILTON (20), the cervical and vaginal regions undergo cyclic alterations in their staining response corresponding with the vaginal smear cycle. However, the author did not find such a cyclical variation.

In the vaginal region, the degree of branching of the folds was noted by HONDA (26), and TAKASHIMA and HONDA (51). The results presented here agree with their observations. The change in the vaginal mucosa was not as obvious as that in the uterine mucosa. There was a tendency for the folds of the vaginal mucosa to be branched reaching into the vaginal lumen. The mucification and swelling of the epithelial cells were more pronounced in the mature follicle stage than in the other stages. Vacuolation in the epithelial cells was observed in some animals, especially, No. 3 and 11 who were in the growing and regressing follicle stages, respectively. Cell vacuolation in the epithelium was more pronounced in the middle and upper vagina including the vaginal fornix in these two animals. In the lower vagina the arrangement of epithelial cells became irregular and desquamation of epithelial cells occurred.

It was noted that masses of epithelial cells were desquamated from the epithelium at the projections of the vaginal folds along with wandering cells in No. 9, who was considered to be in a later period of the mature follicle stage. It was also worthy of note that several mitotic figures were seen in the vaginal epithelium both in the growing and regressing follicle stages, although they were, with one exception, not seen in the mature follicle stage. Therefore, it is postulated that the vaginal activity in mucus secretion and branching of the folds is high in the mature follicle stage compared to that in other stages which are in a degenerating or regenerating state. The desqua-

mation of cell masses was the result of a normal contracting phenomena occurring in the vaginal mucosa.

The phenomena of progestational proliferation of the rabbit's uterus had been confirmed by many investigators. Their results point strongly to the existence of a special action of the corpus luteum upon the endometrium, bringing about progestational proliferation (7, 8, 10, 18, 30, 31, 34, 35, 42, 49, 52, 53, 54, 60, 63, 64). Furthermore, it became clear that progestational proliferation originated by the effect of progesterone (4, 22, 38). These investigations have established methods of bioassay for progesterone in the rabbit's uterus. During the proliferation period of the uterine mucosa, uterine glands penetrate nearly to the myometrium. This final stage is especially characterized by distention of the glands, giving a broken-up appearance to the endometrium (39). In the present study one animal showed such endometrial features throughout the uterine horns. In some animals such features were recognized only in locally limited areas. These animals were all in the mature follicle stage. This means that the uterine mucosa in the normal adult female shows a weak progestational response during the mature follicle stage and is evidence that progesterone and related substances act cyclically on the endometrium.

Recently, it was established that the ovary which contains mature follicles before ovulation also secretes progesterone (5, 13, 14, 65). FORBES (15) stated that rabbits which are mated or injected with gonadotrophin secrete progesterone prior to ovulation. However, it is important to notice that he discarded an additional rabbit when the control specimen showed a positive response. No description was made for it. Furthermore, progesterone and its metabolite were present in the ovarian vein blood of estrous rabbits without functional corpora lutea (24). HILLIARD et al. (25) believed that the interstitial tissue may be the principal site of progestin synthesis.

From the literature above and the results of this study, it appears that progesterone or a related substance is secreted in normal non-pregnant rabbits and it causes a weak progestational response in the normal uterine mucosa.

Concerning the effect of estrogen on the endometrium, many authors point out the induction of uterine hyperemia and glandular cystic hyperplasia in various species (2, 3, 6, 11, 16, 19, 43, 52, 53, 66). According to ZONDEK (66), glandular-cystic hyperplasia of the endometrium of rabbits is brought about by prolonged application of large doses of follicular hormone. He stated that there is an increased number of glands, the dilatation of their lumina amounts to several times their usual size, the epithelial lining shows marked flattening, the larger glands rupture, and the leucocytes which are found in their lumina, extravasate into the tissues. In castrated rabbits estrogen combined with

progesterone causes a progestational reaction or inhibits the progestational effect of progesterone or again it leads to profound vascular changes in the uterus (19). As the estradiol is increased less progesterone is necessary to cause the hyperemia. The glands in some areas were widely dilated and looked cystic; the size of the cysts was accentuated by the low columnar or even cuboidal epithelium which lined the glands, unlike those normally found in a progestational endometrium. PARKES (44) demonstrated the "Swiss cheese" hyperplasia of the endometrium in the uterus of the ovariectomised mouse after prolonged injection of estrin. In the present study glandular cysts of various sizes appeared in normal rabbits. They seemed to be formed by union of expanded glandular lumina in which desquamated cells were enclosed in some cases. Some of the glands lost their epithelium and the lumina closed. The author considered that the formation of cystic glandular lumina and their closing are part of the normal uterine function. In the present study, glandular cysts were marked in one animal in the middle stage and in two animals in the regressing stage.

The degeneration and regeneration of the uterine mucosa in woman and monkey in normal cyclic conditions is well known. However, in many other animals, there is no marked degeneration of the endometrium as in woman. The present study showed that there is two kinds of mechanisms acting on the endometrium of the rabbit for regression of branched folds of the endometrium. One mechanism is the formation of glandular cysts, and the other is the sloughing off of some parts of the branched folds from the endometrium.

In the former, many elongated and branched glandular lumina are absorbed by the cystic glandular lumina, and the glands are simplified and reduced in number. The cystic lumina close by desquamation (Figs. 30-37).

The latter case was postulated after the following considerations. TSUTSUMI and MATSUMOTO (58) reported that large ciliata-like substances which were multicellular and able to be moved by cilia were observed in the vaginal mucus of the pregnant rabbit. They considered that these originated from the uterine mucosa by flow of the uterine milk into the vaginal lumen. According to DEANESLY and PARKES (10), the sterile horn of the rabbit undergoes characteristic progestational changes lasting 12 to 14 days and regresses afterwards. The glands and epithelium disintegrate and blocks of debris are found in the uterine lumen. It was noted here that the uterine epithelium is composed of ciliated cells as well as other kinds of cells. It seems clear that ciliata-like substances are produced by the endometrium in the pregnant rabbit. Furthermore, the large ciliata-like substances were evident in the vaginal mucus of normal non-pregnant rabbits in a few cases (TSUTSUMI, unpublished). The present study confirms that weak progestational changes occur in the endo-

metrium in normal rabbits at some stage of the cycle. Therefore it seems reasonable that the sloughing off of some parts of the endometrium should occur.

SUMMARY

Eleven adult non-pregnant female rabbits were classified into three sexual phases according to the appearance of the vaginal mucus and maturity and regression of the ovarian follicles. The mucosa of the genital tracts was examined histologically. The mucosa showed cyclical changes corresponding to changes in the ovary and vaginal mucus. The endometrium showed greater variation than did the vaginal mucosa, whereas little cyclical variation was observed in the oviduct, cervix and vestibule. Some histological characteristics of the uterine mucosa are discussed in relation to the endocrine milieu. Two kinds of mechanisms appear to be acting on the endometrium for regression of the branched folds, namely, the formation of glandular cysts and sloughing off of the branched folds.

ACKNOWLEDGMENT

Thanks are due to Prof. E. S. E. HAFEZ and Dr. R. E. MAUER, Washington State University, and Prof. Y. HACHINOHE, Hokkaido University, for reading the manuscript and making helpful suggestions.

References

- 1) ABE, S. 1927: *Hokkaido-Igaku-Zasshi* 5: 278.
- 2) ALLEN, E., and E. A. DOISY 1923: *J. A. M. A.* 81: 819-821.
- 3) ALLEN, E., B. F. FRANCIS, L. L. ROBERTSON, C. E. COLGATE, C. G. JOHNSTON, E. A. DOISY, W. B. KOUNTZ and H. V. GIBSON 1925: *Amer. J. Anat.* 34: 133-181.
- 4) ALLEN, W. M., and G. P. HECKEL 1936: *Anat. Rec.* 64: Abst. P. 2.
- 5) ASTWOOD, E. B. 1939: *Amer. J. Physiol.* 126: 162-170.
- 6) CLEVELAND, R., D. PHELPS and J. C. BURCH 1941: *Endocrinol.* 28: 659-663.
- 7) CORNER, G. W. 1928: *Amer. J. Physiol.* 86: 74-81.
- 8) CORNER, G. W., and W. M. ALLEN 1929: *Amer. J. Physiol.* 88: 326-339.
- 9) ČUDNOVSKII, L. A. 1957: *Karakulevodstvo i Zverovodstvo* 10: 37-38. (A. B. A. 25: 299, 1957).
- 10) DEANESLY, R., and A. S. PARKES 1931: *Proc. Roy. Soc. London S. B.* 109: 196-213.
- 11) DE LANGE, M. 1950: *Onderstepoort Jour. Veterinary Sci. and Animal Industry* 24: 125-354.
- 12) DRAHN, F. 1924: *Halban-Zeits. Biologie und Pathologie des Weibes* 1: 457.

- 13) EDGAR, D. G. 1952: *Nature* 170: 543-544.
- 14) FORBES, T. R. 1950: *Amer. J. Obst. & Gynec.* 60: 180-186.
- 15) ————— 1953: *Endocrinol.* 53: 79-87.
- 16) FRANK, R. T. 1922: *J. A. M. A.* 78: 181-185.
- 17) FROBÖSE, H. 1932: *Zeitschrift f. mikroskopische-anatomische Forschung* 30: 295-406.
- 18) FUJIWARA, T. 1935: *Ōsaka-Igakkai-Zasshi* 34: 127-141.
- 19) GILLMAN, J. 1941: *Endocrinol.* 29: 336-342.
- 20) HAMILTON, C. E. 1951: *Anat. Rec.* 110: 557-571.
- 21) HARA, H. 1941: *Nihon-Seirigaku-Zasshi* 6: 599-620.
- 22) HASKINS, A. L. 1939: *Proc. Soc. Exp. Biol. & Med.* 42: 624-628.
- 23) HILL, M., and W. E. WHITE 1934: *J. Physiol.* 80: 174-178.
- 24) HILLIARD, J., E. ENDRÖCZI, and C. H. SAWYER 1961: *Proc. Soc. Exp. Biol. & Med.* 108: 154-156.
- 25) HILLIARD, J., D. ARCHIBALD, and C. H. SAWYER 1963: *Endocrinol.* 72: 59-66.
- 26) HONDA, K. 1938: *Sanka-Fujinka-Kiyō* 21: 793.
- 27) INOUE, S. 1935: *Chōsen-Igakkai-Zasshi* 25: 886-964.
- 28) IWATA, M. 1924: *Hokkaido-Igaku-Zasshi* 2: 648-670.
- 29) ————— 1925: *Hokkaido-Igaku-Zasshi* 3: 29-48.
- 30) ————— 1926: *Nippon-Fujinka-Gakkai-Zasshi* 21: 1291.
- 31) KATAHIRA, T. 1935: *Nihon-Tetsudōi-Kyōkai-Zasshi* 21: 271-298.
- 32) KATO, K. 1927: *Ōsaka-Igakkai-Zasshi* 21: 2531-2550.
- 33) KATO, K., and T. HORIKAWA 1952: *Bulletin Nippon Veterinary and Zootechnical College* 1: 10-20.
- 34) KNAUS, H. 1930: *Klinische Wochenschrift* 9: 961-964.
- 35) KUBO, F. 1928: *Ōsaka-Igakkai-Zasshi* 27: 1261-1294.
- 36) LOEB, L., and M. G. SMITH 1935: *Anat. Rec.* 63: 91-92.
- 37) MATSUMOTO, K., and Y. TSUTSUMI 1955: *Research Bulletins of the Experimental Farm, Hokkaido University* 11: 97-107.
- 38) MCGINTY, D. A., L. P. ANDERSON and N. B. MCCULLOUGH 1939: *Endocrinol.* 24: 829-832.
- 39) MCPHAIL, M. K. 1935: *J. Physiol.* 83: 145-156.
- 40) MYERS, K., and W. E. POOLE 1962: *Nature* 195: 358-359.
- 41) NAITO, M. 1946: *Japanese Jour. Zootechnical Sci.* 17: 14-40.
- 42) NAKAMURA, N. 1935: *Ōsaka-Igakkai-Zasshi* 34: 715-722.
- 43) NELSON, W. O. 1937: *Anat. Rec.* 68: 99-102.
- 44) PARKES, A. S. 1935: *Lancet* 228: 485-486.
- 45) SAEKI, Y. 1951: *National Institute of Agricultural Sci. (Japan), S. G.* 1: 113-120.
- 46) SHIBATA, S. 1931: *Journal of the College of Agriculture, Imperial University of Tokyo* 11: 309-340.
- 47) ————— 1932: *Japanese Jour. Zootechnical Sci.* 5: 69-98.
- 48) SHIRAI, S. 1929: *Ōsaka-Igakkai-Zasshi* 28: 849-874.
- 49) SHIRAI, S., and M. TAWARA 1929: *Ōsaka-Igakkai-Zasshi* 28: 523-536.
- 50) SMELSER, G. K., A. WALTON, and E. O. WHETHAM 1934: *J. Exp. Biology* 11: 354-363.

- 51) TAKASHIMA, R., and K. HONDA 1940: *Acta anatomica Nipponica* 16: 16.
- 52) TANI, S. 1932a *Nippon-Fujinkagakkai-Zasshi* 28: 2005-2040.
- 53) ——— 1932b *Nippon-Fujinkagakkai-Zasshi* 28: 1737-1770.
- 54) TSUNEOKA, S. 1936: *Ōsaka-Iji-Shinshi* 7: 348-352.
- 55) TSUTSUMI, Y., and K. MATSUMOTO 1955: *Memoirs of Faculty of Agriculture, Hokkaido University* 2: 128-136.
- 56) ——— and ——— 1956a: *Memoirs of Faculty of Agriculture, Hokkaido University* 2: 181-194.
- 57) ——— and ——— 1956b: *Memoirs of Faculty of Agriculture, Hokkaido University* 2: 178-180.
- 58) ——— and ——— 1958: *Memoirs of Faculty of Agriculture, Hokkaido University* 3: 104-121.
- 59) ——— and ——— 1959: *Memoirs of Faculty of Agriculture, Hokkaido University* 3: 185-199.
- 60) UYAMA, F. 1929: *Ōsaka-Igakkai-Zasshi* 28: 72-144.
- 61) WATANABE, H. 1954: *Jour. Japanese Obstetrical and Gynecological Society* 6: 236.
- 62) YAJIMA, T. 1939: *Jour. Chōsen Medical Association* 29: 1709-1755.
- 63) YŌDA, T. 1930: *Nippon-Fujinka-Gakkai-Zasshi* 25: 1063-1099, 1139-1164, 26: 1-34.
- 64) YOKOYAMA, S. 1925: *Chōsen-Igakkai-Zasshi* 56: 1-19.
- 65) ZANDER, J. 1954: *Nature* 174: 406-407.
- 66) ZONDEK, B. 1936 *J. Exp. Med.* 63: 789-794.

EXPLANATION OF FIGURES**PLATE 1**

Figures 2-7 are cross sections of the oviduct.

- 2 Epithelium of fimbriae. (Ciaccio fixative, Azan stain, $\times 280$)
- 3 Mitosis on the epithelium of ampulla. (Ciaccio fixative, Hematoxylin-eosin stain, $\times 280$)
- 4 Epithelial cells of the ampulla. (Helly fixative, Mucicarmine stain, $\times 280$)
- 5 Cross section of isthmus in the growing follicle stage. (Ciaccio fixative, Mucicarmine stain, $\times 70$)
- 6 Cross section of isthmus in the maturing follicle stage. (Helly fixative, Mucicarmine stain, $\times 70$)
- 7 Cross section of isthmus in the regressing follicle stage. (Carnoy fixative, Mucicarmine stain, $\times 70$)

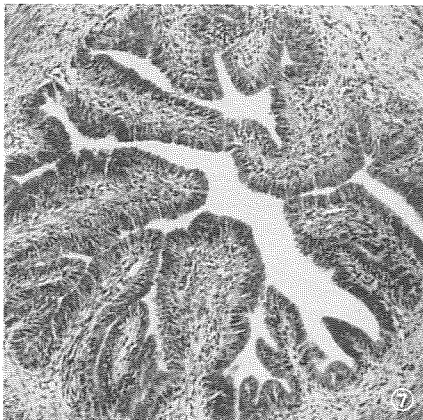
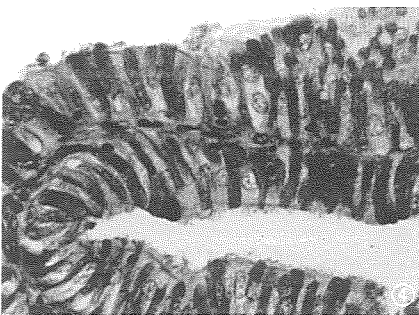
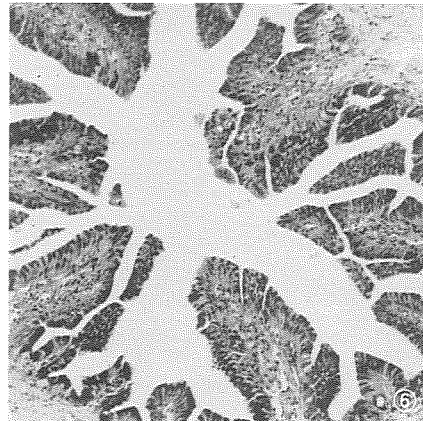
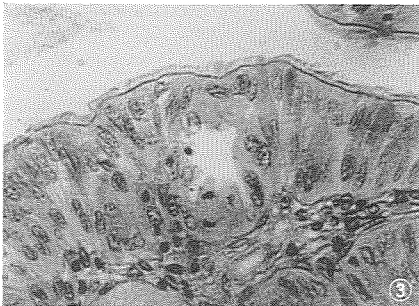
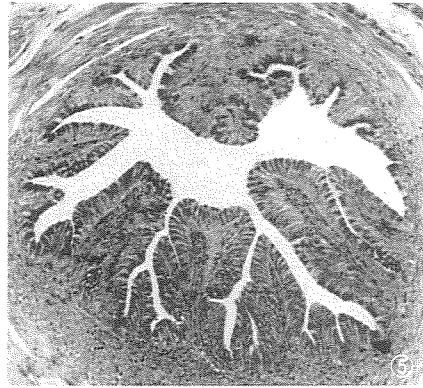
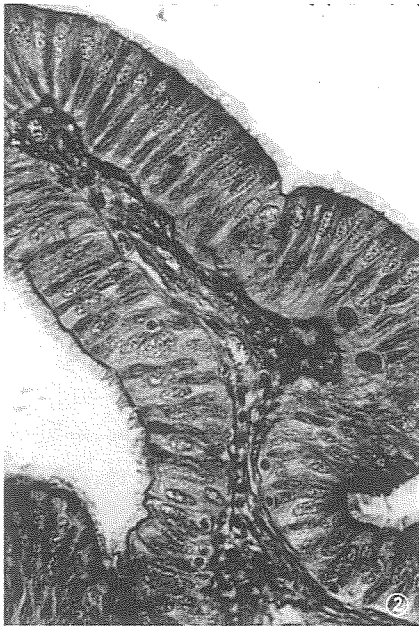


PLATE 2

Figures 8-14 are sections of the uterus.

- 8 Longitudinal section of ob-mesometrial uterine folds in the growing follicle stage. (No. 1, Ciaccio fixative, Iron-hematoxylin stain, $\times 60$)
- 9 Cross section of mesometrial fold of uterine mucosa in the growing follicle stage. (No. 1, Carnoy fixative, Azan stain, $\times 60$)
- 10 Longitudinal section of ob-mesometrial uterine folds in the growing follicle stage. (No. 3, Ciaccio fixative, Iron-hematoxylin stain, $\times 60$)
- 11 and 12 Uterine epithelial cells in the growing follicle stage. (No. 2, Helly fixative, Hematoxylin-eosin stain, $\times 800$)
- 13 Longitudinal section of ob-mesometrial uterine folds in the growing follicle stage. (No. 4, Helly fixative, Hematoxylin-eosin stain, $\times 60$)
- 14 Cross section of uterine mucosa in the growing follicle stage. (No. 4, Helly fixative, Mucicarmine stain, $\times 200$)

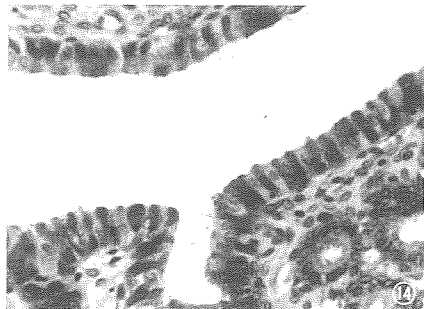
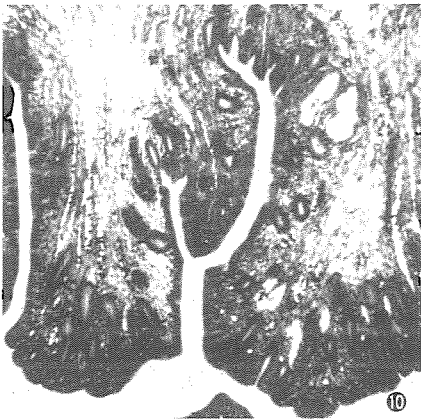
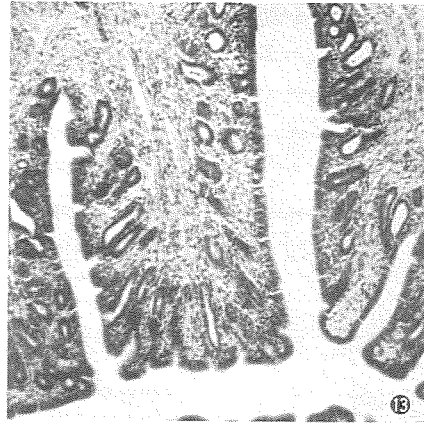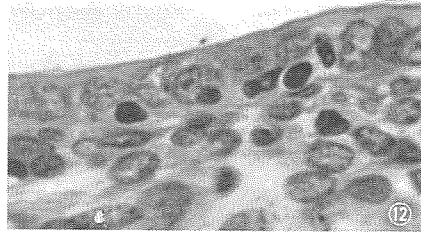
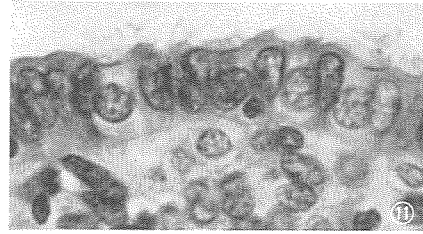
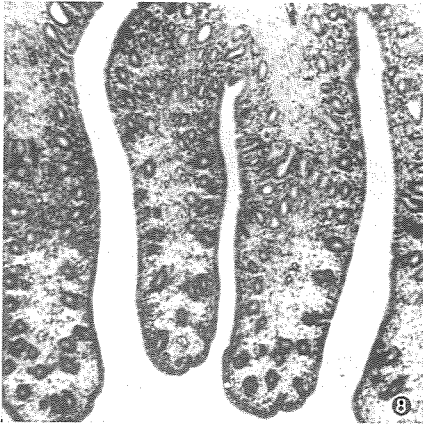


PLATE 3

Figures 15-20 are sections of the uterus.

- 15 Longitudinal section of ob-mesometrial uterine fold in the mature follicle stage. (No. 5, Helly fixative, Azan stain, $\times 60$)
- 16 Cross section of mesometrial fold in the mature follicle stage. Crystal situated in uterine glandular cavity. (No. 5, Helly fixative, Hematoxylin-eosin stain, $\times 60$)
- 17 Cross section of the uterine folds showing complex branching in the mature follicle stage. (No. 6, Helly fixative, Iron-hematoxylin stain, $\times 60$)
- 18 Longitudinal section of the mesometrial uterine folds in the mature follicle stage. (No. 6, Helly fixative, Azan stain, $\times 60$)
- 19 Epithelial cells of the uterine mucosa in the mature follicle stage. (No. 6, Helly fixative, Azan stain, $\times 800$)
- 20 Epithelial cells of the uterine mucosa in the mature follicle stage. (No. 6, Helly fixative, Mucicarmine stain, $\times 800$)


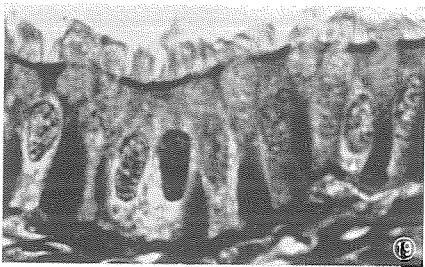
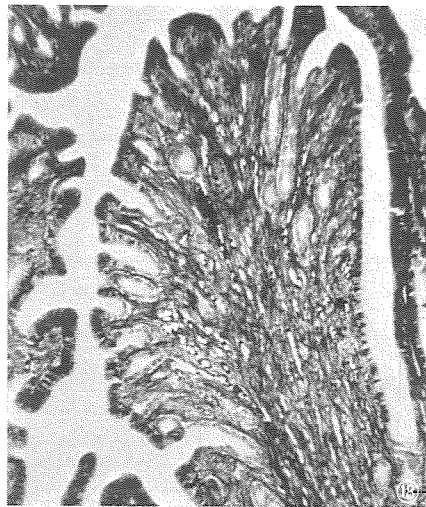
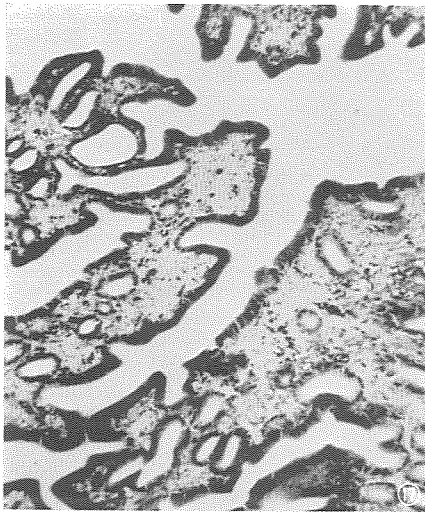
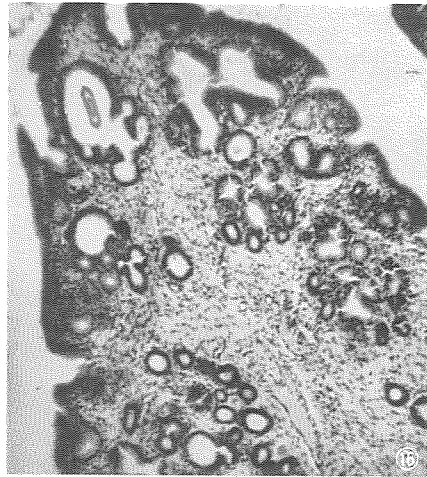
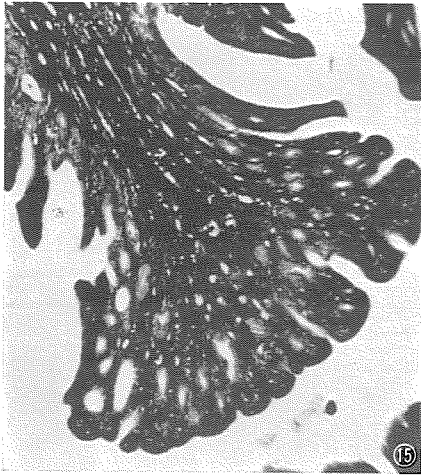


PLATE 4

Figures 21-27 are sections of the uterus.

- 21 Longitudinal section of ob-mesometrial uterine fold in the mature follicle stage. (No. 7, Ciaccio fixative, Iron-hematoxylin stain, $\times 60$)
- 22 Longitudinal section of ob-mesometrial uterine fold in the mature follicle stage. (No. 8, Carnoy fixative, Azan stain, $\times 60$)
- 23 Longitudinal section of ob-mesometrial uterine folds near end of the mature follicle stage. (No. 9, Ciaccio fixative, Iron-hematoxylin stain, $\times 60$)
- 24 Cross section of uterine folds near end of the mature follicle stage. (No. 9, Carnoy fixative, Iron-hematoxylin stain, $\times 60$)
- 25 Uterine epithelial cells near end of the mature follicle stage. (No. 9, Carnoy fixative, Azan stain, $\times 800$)
- 26 Uterine epithelial cells near end of the mature follicle stage. (No. 9, Ciaccio fixative, Iron-hematoxylin stain, $\times 800$)
- 27 Longitudinal section of ob-mesometrial uterine folds in the regressing follicle stage. (No. 10, Helly fixative, Azan stain, $\times 60$)

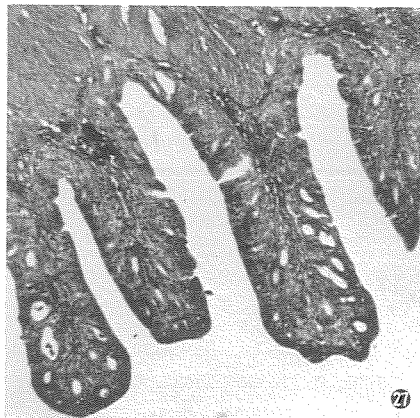
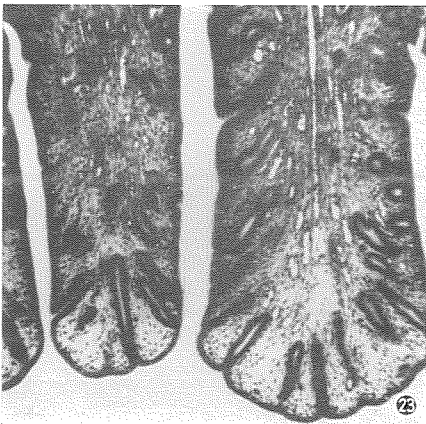
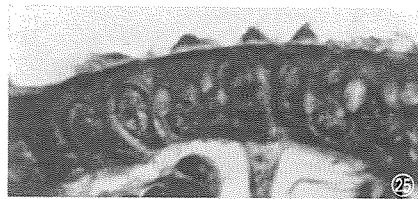
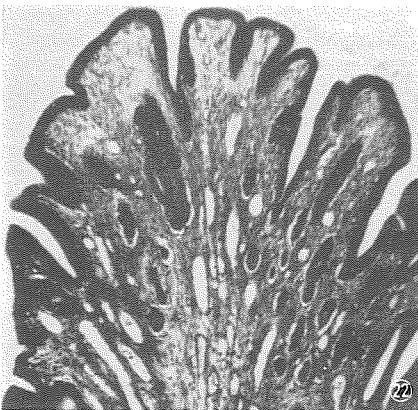
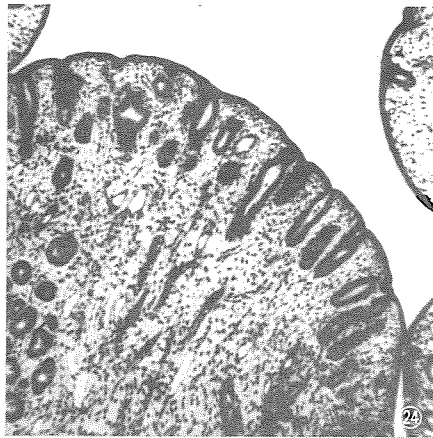
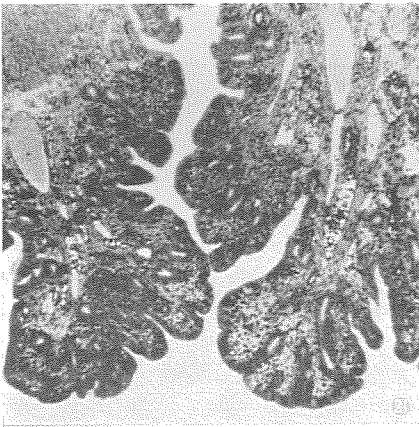


PLATE 5

Figures 28-34 are sections of the uterus.

- 28 Cross section of uterine mucosa in the regressing stage. (No. 10, Helly fixative, Iron-hematoxylin stain, $\times 60$)
- 29 Longitudinal section of ob-mesometrial uterine folds in the regressing follicle stage. (No. 11, Ciaccio fixative, Iron-hematoxylin stain, $\times 60$)
- 30 Formation of cystic glandular lumina. Mesometrial fold. (No. 3, Carnoy fixative, Azan stain, $\times 150$)
- 31 Formation of cystic glandular lumina. Mesometrial fold. (No. 2, Helly fixative, Hematoxylin-eosin stain, $\times 200$)
- 32 Formation of cystic glandular lumina. (No. 5, Helly fixative, Hematoxylin-eosin stain, $\times 200$)
- 33 Longitudinal section of mesometrial fold. A large cystic cavity is seen in the fold. (No. 2, Helly fixative, Mucicarmine stain, $\times 60$)
- 34 Cystic glandular lumen, having no epithelial cell. (No. 2, Helly fixative, Mucicarmine stain, $\times 200$)

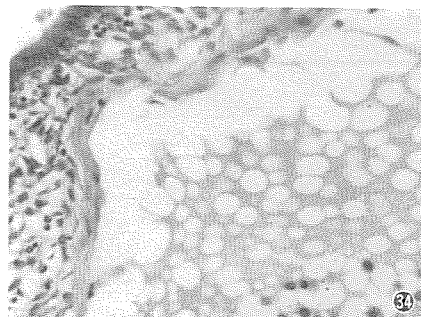
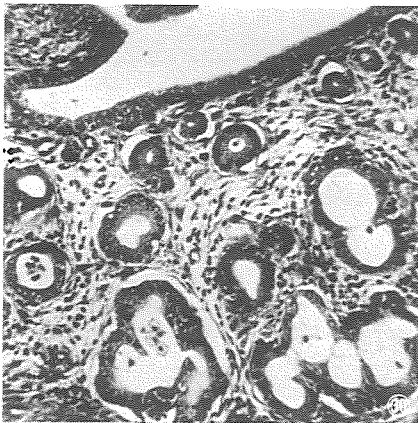
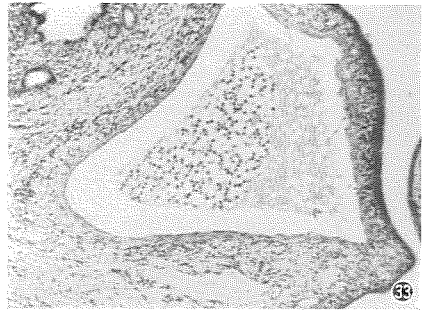
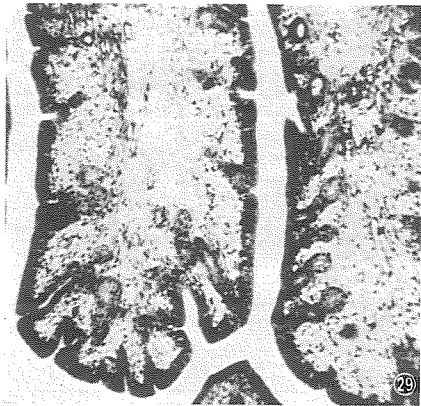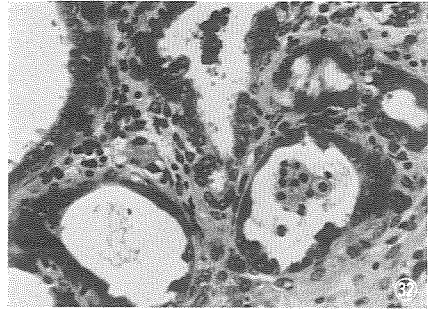
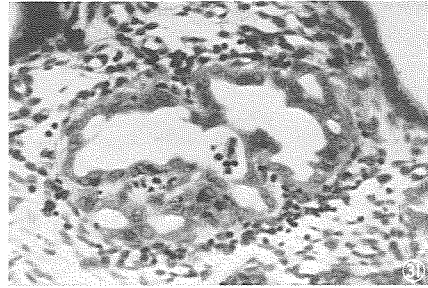
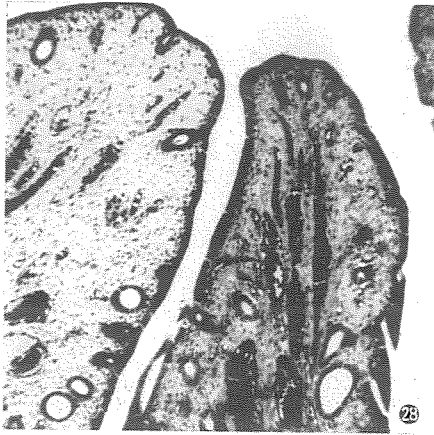


PLATE 6

Figures 35-37 are sections of the uterus.

Figures 38-40 are sections of the cervix.

Figures 41-42 are sections of the vagina.

- 35 Cystic cavity in uterine mucosa, having no epithelial cell. (No. 5, Helly fixative, Hematoxylin-eosin stain, $\times 150$)
- 36 Closing of the cystic cavity in the uterine mucosa. (No. 5, Helly fixative, Hematoxylin-eosin stain, $\times 200$)
- 37 Closing of the cystic cavity in the uterine mucosa. (No. 2, Helly fixative, Mucicarmine stain, $\times 200$)
- 38 Cervical epithelial cells in the growing follicle stage. (No. 3, Ciaccio fixative, Hematoxylin-eosin stain, $\times 280$)
- 39 Mitotic figure is recognized in the epithelium of cervix in the growing follicle stage. (No. 3, Ciaccio fixative, Mucicarmine stain, $\times 280$)
- 40 Cervical epithelial cells in the mature follicle stage. (No. 6, Helly fixative, Mucicarmine stain, $\times 280$)
- 41 Cross section of vaginal folds in the growing follicle stage. (No. 1, Ciaccio fixative, Azan stain, $\times 70$)
- 42 Vaginal epithelial cells in the growing follicle stage. (No. 1, Ciaccio fixative, Hematoxylin-eosin stain, $\times 280$)

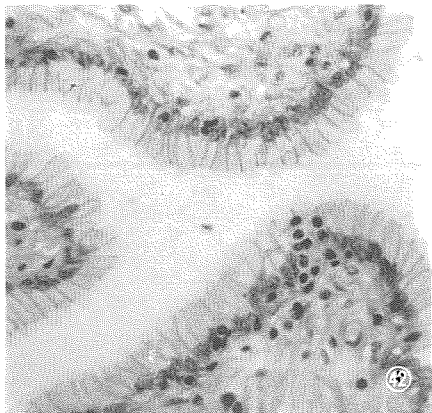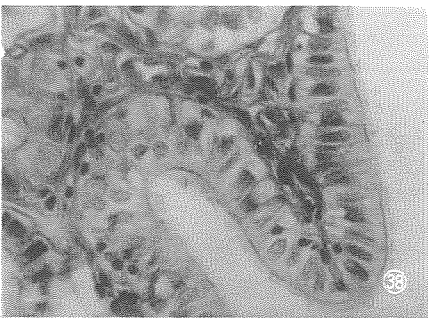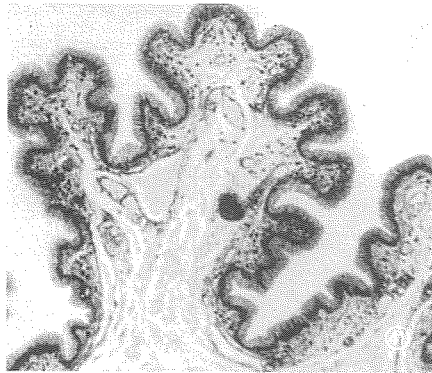
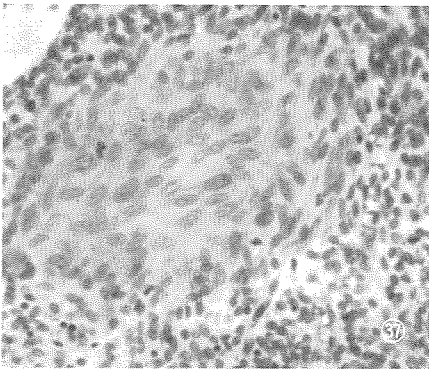
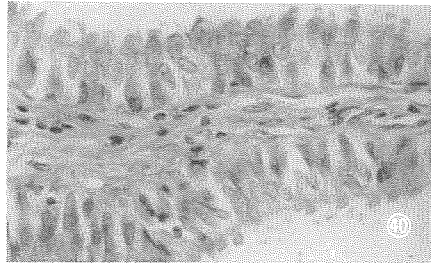
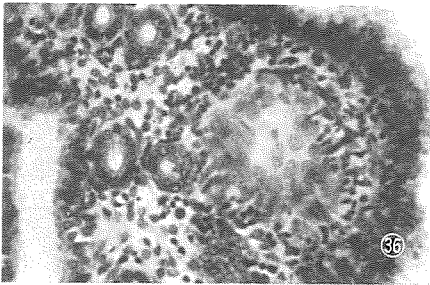
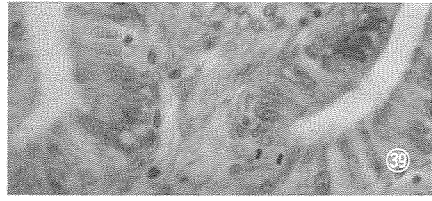
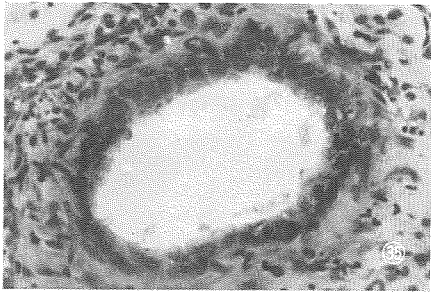


PLATE 7

Figures 43-49 are sections of the vagina.

- 43 Mitosis exists in the vaginal epithelium. (No. 1, Ciaccio fixative, Hematoxylin-eosin stain, $\times 280$)
- 44 Cross section of vaginal folds in the growing follicle stage. (No. 2, Ciaccio fixative, Hematoxylin-eosin stain, $\times 70$)
- 45 Cross section of vaginal folds in the growing follicle stage. (No. 3, Ciaccio fixative, Azan stain, $\times 280$)
- 46 Vaginal epithelial cells showing vacuolation and irregular arrangement in the growing follicle stage. (No. 3, Ciaccio fixative, Azan stain, $\times 280$)
- 47 Cross section of vaginal folds in the growing follicle stage. (No. 4, Helly fixative, Hematoxylin-eosin stain, $\times 70$)
- 48 Cross section of vaginal folds in the mature follicle stage. (No. 5, Helly fixative, Mucicarmine stain, $\times 70$)
- 49 Cross section of vaginal folds in the mature follicle stage. (No. 8, Ciaccio fixative, Hematoxylin-eosin stain, $\times 70$)

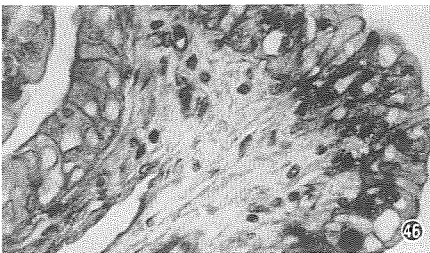
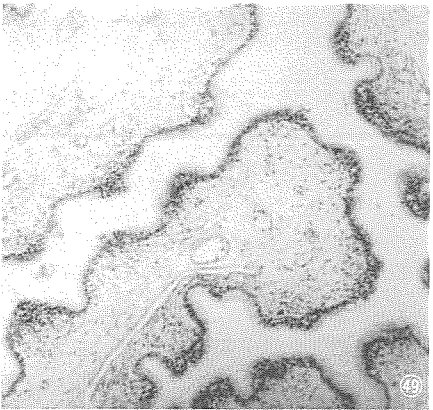
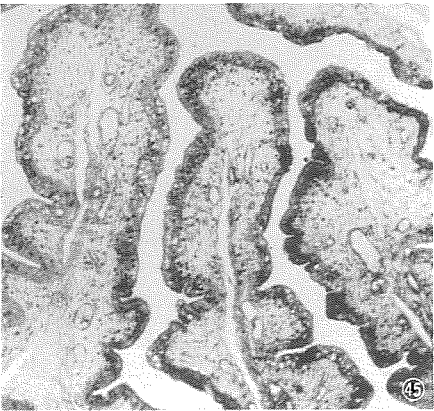
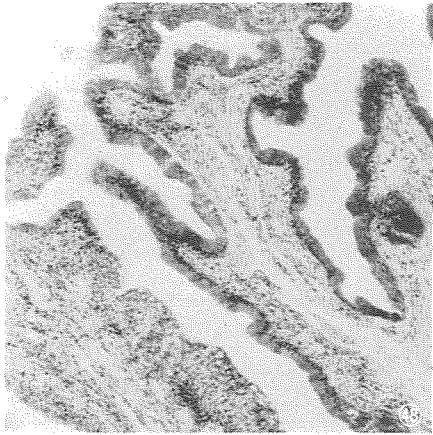
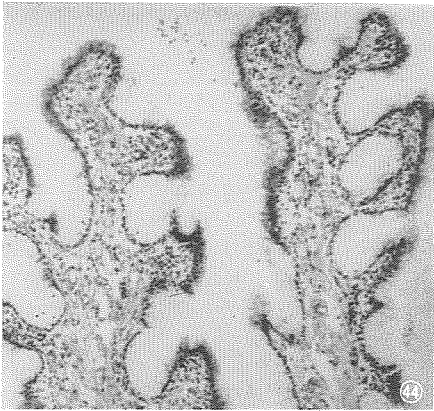
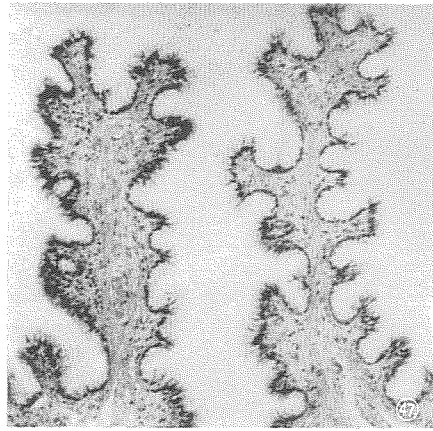
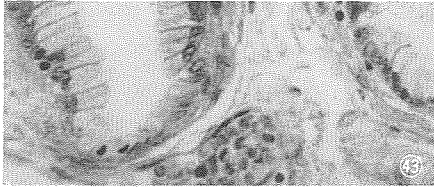


PLATE 8

Figures 50-55 are sections of the vagina.

Figure 56 is section of the vestibule.

- 50 Cross section of vaginal folds in the mature follicle stage. (No. 9, Ciaccio fixative, Azan stain, $\times 70$)
- 51 Cross section of vaginal folds in the regressing follicle stage. (No. 10, Helly fixative, Mucicarmine stain, $\times 70$)
- 52-55 Cell-masses of vaginal epithelial cells are being sloughed off into the vaginal lumen. (No. 9, Ciaccio fixative, Azan stain, $\times 280$)
- 56 Vestibular epithelial cells. (No. 3, Ciaccio fixative, Azan stain, $\times 280$)

