



# HOKKAIDO UNIVERSITY

Title	Microscopic Observations on the Zona Pellucida of Unfertilized Eggs Recovered from the Oviduct and Uterus in the Rabbit
Author(s)	TSUTSUMI, Yoshio; TAKEDA, Tetsuo
Citation	Journal of the Faculty of Agriculture, Hokkaido University, 60(2), 101-106
Issue Date	1981-03
Doc URL	<a href="https://hdl.handle.net/2115/12947">https://hdl.handle.net/2115/12947</a>
Type	departmental bulletin paper
File Information	60(2)_p101-106.pdf



# MICROSCOPIC OBSERVATIONS ON THE ZONA PELLUCIDA OF UNFERTILIZED EGGS RECOVERED FROM THE OVIDUCT AND UTERUS IN THE RABBIT

Yoshio TSUTSUMI and Tetsuo TAKEDA

(Department of Animal Science, Faculty of Agriculture,  
Hokkaido University, Sapporo 060, Japan)

Received August 19, 1980

## Introduction

It has been reported that unfertilized rabbit eggs are sporadically expelled into the vaginal lumen during pseudopregnancy. The unfertilized eggs, recovered vaginally, showed severe degeneration in both the vitellus and the zona pellucida. Although the existence of a zona pellucida was clear in half the number of eggs recovered vaginally 4 days *post coitum* (*p.c.*), the inner part of the zona pellucida became unclear in most of the eggs after 5 days *p.c.*; and eventually the zona pellucida seemed to disappear in such eggs.<sup>10</sup> This previous study from our laboratory tends to support ADAMS' observations,<sup>1</sup> in which he described a diffusion of the inner aspect of the zona pellucida of uterine eggs by 7 days *p.c.* and a disappearance of the zona pellucida after 8 days *p.c.* HASHIMOTO<sup>5</sup> mentioned that the zona pellucida showed a slight swelling 90 to 150 hours *p.c.* However, no changes in the zona pellucida were noted 12 to 105 hours *p.c.* by TAKEISHI *et al.*<sup>9</sup> In all of the experiments cited above, the eggs were examined in the untreated and raw state under the microscope. Therefore, our aim in the present study was to make histological observations on the zona pellucida in rabbits during pseudopregnancy.

## Materials and Methods

Eighteen female adult rabbits were mated with vasectomized bucks and simultaneously received intravenous injections of 50 I. U. of human chorionic gonadotropin (hCG) to insure ovulation. To confirm the results of previous reports,<sup>1,10</sup> 7 does were killed so that unfertilized eggs could be obtained from the oviduct and uterus at 7, 9, 11, 13, 15, 16 and 17 days *p.c.*, re-

spectively. Their oviducts and uteri were flushed with physiological saline solution to recover the eggs to be examined microscopically in the raw state.

For histological study, 9 does were killed 1 to 9 days *p. c.*, respectively. Eggs recovered from the oviduct and uterus were fixed with 3% glutaraldehyde in 0.1 M phosphate buffer at 4°C, then embedded in an agar gel.<sup>9</sup> After dehydration of small pieces of agar gel, containing eggs, in a graded series of ethanol, the pieces were embedded in Epon 812. Semi-thin sections of 0.8 to 1.2  $\mu\text{m}$  were made using an ultramicrotome (Porter-Blum MT-2 B, Sorvall), and were stained with alcian blue and/or by periodic acid-Schiff (PAS) after removal of epon according to the method of IMAI *et al.*<sup>9</sup>

The oviducts of the other 2 does were ligated at the utero-tubal junction 1 day after hCG administration, and the does were killed at 5 and 9 days after hCG dosage, respectively, to permit recovery of the oviductal eggs. All eggs recovered from these 2 does were examined histologically.

### Results

For microscopic observations on the raw eggs, 33 unfertilized eggs were recovered from the uteri of 6 does 7 to 16 days *p. c.*, and 5 eggs from oviducts of 2 does 13 and 15 days *p. c.*, respectively (Table 1). Vaginal flushings in each doe before killing yielded no eggs from the vagina. In a general view of these degenerated eggs, a thick mucin coat, having a fine, concentric-circular structure, was seen to cover them (Figs. 1-8). The somewhat smooth inner aspect of the mucin coat was clearly identified under low magnification in most of the uterine eggs up to 9 days *p. c.* (Figs. 3, 5); but in some eggs at 9 days *p. c.*, and in all eggs recovered thereafter, the boundary aspect between the mucin coat and the egg became irregular and angular in shape (Figs. 4-8). The zona pellucida was not clearly iden-

TABLE 1. Numbers of unfertilized and degenerated eggs recovered from the oviduct and uterus of pseudopregnant rabbits

	Days <i>post coitum</i>						
	7	9	11	13	15	16	17
No. of corpora lutea	13	14	12	10	11	9	13
No. of eggs recovered from oviduct	0	0	0	3	2	0	0
No. of eggs recovered from uterus	6	6	9	8	2*	2	0
Recovery rates (%)	46	43	75	110	36	22	0

\* One uterine horn was not examined because of pyometra.

tified as a zone in the uterine eggs at 7 days *p. c.* and thereafter (Figs. 4-8). The degenerated vitellus appeared to be floating within a large perivitelline and intra-zonal space covered directly by the mucin layer (Figs. 3, 5). In these eggs, the inner aspect of the mucin coat was noted to be a rough surface (Fig. 5). In most uterine eggs after 13 days *p. c.*, granulation, perhaps of the zona pellucida, had occurred in the perivitelline space; and the boundary area between the mucin coat and the perivitelline space was unclear (Fig. 8). In 2 cases, at 13 and 15 days *p. c.*, eggs were still located in the oviduct, and the oviductal eggs had well preserved zonae pellucidae, differing in this respect from the uterine eggs (Figs. 1, 2). The vitellus presented a shrunken appearance or was fragmented in various sizes *en bloc* in the intra-zonal space. Shrinkage of the vitellus was severe in uterine eggs after 11 days *p. c.*

Fourteen eggs recovered from the oviduct at 1 and 2 days *p. c.*, and 47 eggs recovered from the uterus at 3 to 9 days *p. c.*, were examined histologically. All oviductal eggs had clear and compact zonae pellucidae in stained semi-thin sections (Fig. 9). Some oviductal eggs showed darkly stained stripes running radially across the zona pellucida. The inside aspect of the zona pellucida was smooth, but the outside aspect was roughly connected with the thin mucin coat by a spongy zone which had formed intermediate to the zona pellucida and mucin coat (Fig. 9).

In some uterine eggs at 3 to 5 days *p. c.*, the inner aspect of the zona pellucida had become unclear due to diffusion or swelling of the inner part of the zona pellucida. The perivitelline space of such eggs was filled with a substance which stained weakly with alcian blue and PAS (Figs. 10, 11). The fine concentric-circular structure of the mucin coat became clear after 3 days *p. c.* (Figs. 11-14).

In most eggs at 5 days *p. c.*, the vitellus had become fragmented and the deutoplasm was diffuse (Figs. 10-12). Although the zona pellucida could hardly be observed in the raw egg at 6 days *p. c.* and thereafter, stained sections showed the persistence of the zona pellucida. In general, the boundary area between the perivitelline space and the zona pellucida was unclear, and the zona pellucida consisted of a few narrow layers which differed in density of staining (Figs. 13, 14). The spongy zone between the zona pellucida and the mucin coat had become thin. In eggs recovered from ligated oviducts of does at 5 and 9 days *p. c.*, the zonae pellucidae appeared intact in both the raw state and stained sections (Figs. 15, 16).

### Discussion

In our previous study,<sup>10</sup> eggs recovered from vaginae of pseudopregnant rabbits and observed directly under a microscope seemed to have lost the zona pellucida after 5 days *p. c.* Therefore, observations of uterine eggs in pseudopregnant rabbits were made in the first experiment of the present study to see if such a phenomenon could be observed in uterine eggs during pseudopregnancy, as reported by ADAMS<sup>9</sup>. However, histological observations on both oviductal and uterine eggs, 1 to 9 days *p. c.*, showed no actual disappearance of the zona pellucida during pseudopregnancy. Although the zona pellucida in oviductal eggs appeared to be compact and unchanged (Figs. 1, 2, 15, 16), that of the uterine eggs became unclear in the inner aspect and seemed to consist of concentric layers after 7 days *p. c.* (Figs. 13, 14). The perivitelline space of such eggs was stained by alcian blue and PAS (Figs. 11-14). This means that there had occurred diffusion or swelling of the zona pellucida into the perivitelline space, resulting in difficult identification of the zona pellucida in raw eggs. This situation could lead one to conclude erroneously that the zona pellucida had disappeared. It is considered that the rough aspect of the inner part of the mucin coat (Fig. 5), which was clear in the raw state, may represent the spongy zone (Fig. 9) which was seen as an intervening zone between the zona pellucida and the mucin coat in histology. Because this spongy zone was clear in oviductal eggs, but became thin or disappeared in uterine eggs (Figs. 11-14), it may be related to the degenerative process in unfertilized eggs.

Surprisingly, a total of 5 unfertilized eggs was recovered from the oviducts of 2 does out of 7 at 13 and 15 days of pseudopregnancy. This indicates that some unfertilized eggs are able to lodge for a long time after ovulation in the oviduct, as reported in horses.<sup>2-4,7</sup> In an attempt at *in vivo* recovery of eggs from vaginae of superovulated does, TSUTSUMI *et al.*<sup>11</sup> obtained 3 unfertilized and degenerated eggs, coated with an extraordinarily thick mucin coat; and they speculated that the eggs had been retained in the oviduct for a long period prior to the recent ovulation. It seems that retention of unfertilized eggs may occur in rare cases in the rabbit.

Unfertilized eggs recovered from the oviduct at 13 and 15 days of pseudopregnancy, and those recovered from the oviduct at 5 and 9 days *p. c.*, have always shown a clear zona pellucida (Figs. 1, 2, 15, 16), in spite of diffusion or swelling of the zona pellucida in uterine eggs recovered at the same time. Although the reasons for this difference are not yet known, some environmental difference between the oviduct and the uterus must be

involved. As the phenomenon has never been found in fertilized eggs, it is possible that such eggs produce some factor(s) to resist the uterine-induced diffusion or swelling of the zona pellucida which occurs in unfertilized eggs. Anyway, it is certain that some uterine environmental factor(s) act on the zona pellucida of unfertilized eggs in such a way as to change the zonal character, and that fertilized eggs have the ability to resist such uterine action.

### Summary

The zona pellucida of unfertilized rabbit eggs, which were recovered from the oviduct and uterus of pseudoprenant rabbits, has been observed both directly in raw eggs and in stained histological sections. Although raw uterine eggs seemed to have lost their zonae pellucidae during pseudopregnancy, histological observations showed intact zonae pellucidae of uterine eggs which had diffused or swelled into the perivitelline space. The zonae pellucidae of eggs which were lodged in the oviduct, through either natural or artificial conditions, clearly retained their zonal appearance. It was speculated from the above results that some uterine factor(s) may cause diffusion or swelling of the inner part of the zona pellucida of unfertilized eggs, and that fertilized egg have an ability to resist such uterine environmental action.

### Acknowledgments

The authors are grateful to Prof. W. J. MELLENS, Department of Veterinary and Animal Sciences, University of Massachusetts, Amherst, U. S. A., for reading the manuscript and offering his valuable suggestions. The work was supported in part by a Grant-in-Aid for Co-operative Research (Project No. 536021) from the Ministry of Education, Science and Culture, Japan.

### Literature Cited

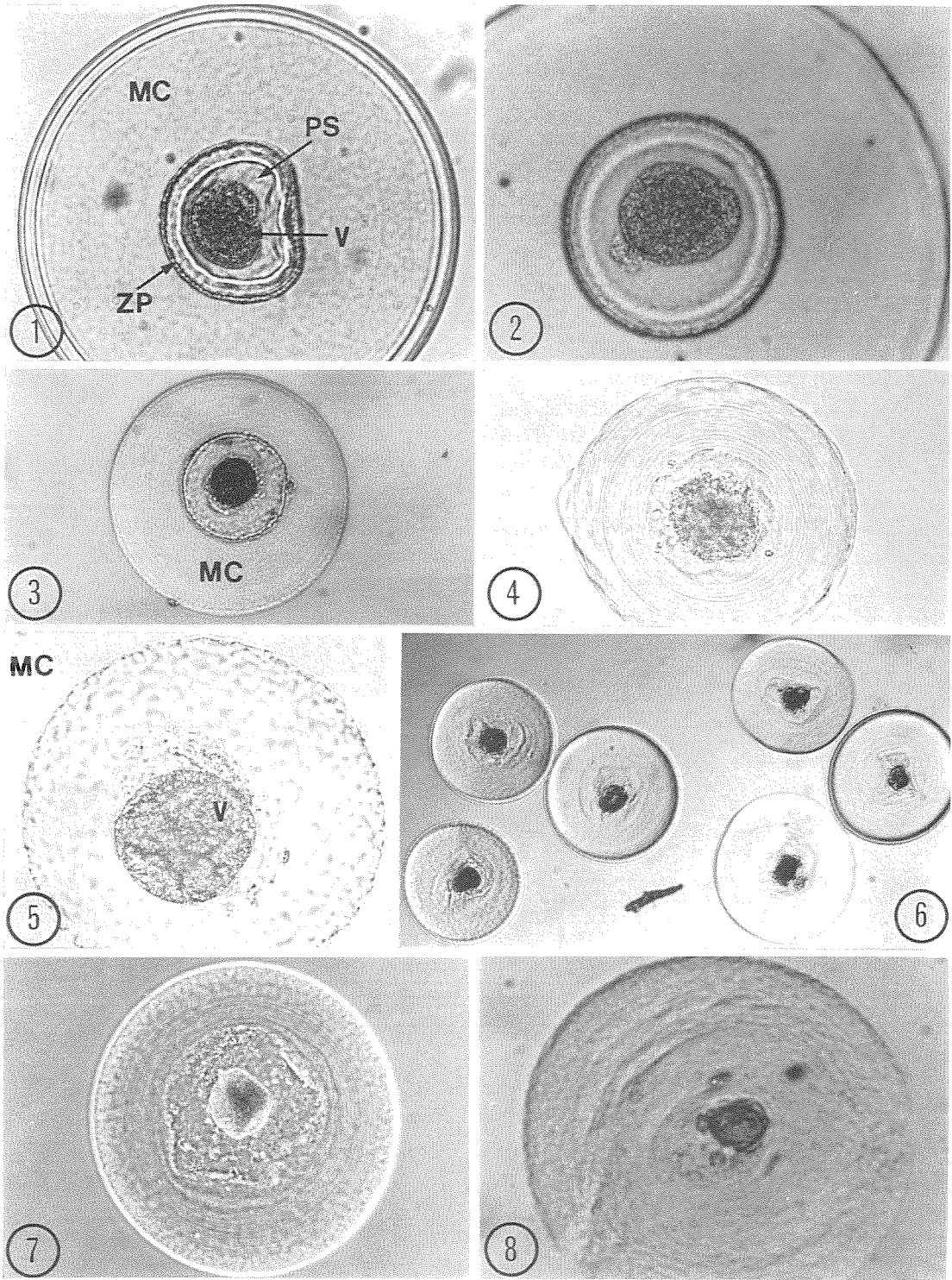
1. ADAMS, C. E.: The fate of unfertilized eggs in the rabbit, *J. Reprod. Fert.*, **23**: 319-324. 1970
2. BETTERIDGE, K. J. and MITCHELL, D.: A surgical technique applied to the study of tubal eggs in the mare, *J. Reprod. Fert., Suppl.* **23**: 519-524. 1975
3. DAVID, J. S. E.: A survey of eggs in the oviducts of mares, *J. Reprod. Fert., Suppl.* **23**: 513-517. 1975
4. FLOOD, P. E., JONG, A. and BETTERIDGE, K. J.: The location of eggs retained in the oviducts of mares, *J. Reprod. Fert.*, **59**: 291-294. 1979
5. HASHIMOTO, K.: Experimental studies on the fate of rabbit ova in the Fallopian tubes and uterine cavity. Report I. On the albumen layer of unfertilized rabbit ova, *Bull. Exp. Biol.*, **8**: 124-132. 1958

6. IMAI, Y., SUE, A. and YAMAGUCHI, A.: A removing method of the resin from epoxy-embedded sections for light microscopy, *J. Electron Microscopy*, **17**: 84-85. 1968
7. OGURI, N. and TSUTSUMI, Y.: Studies on lodging of the equine unfertilized ova in Fallopian tubes, *Res. Bull. Livestock Farm, Hokkaido Univ.*, **6**: 32-43. 1972
8. SAMUEL, D. M.: The use of an agar gel in the sectioning of mammalian eggs, *J. Anat.*, **78**: 173-175. 1944
9. TAKEISHI, M., ŌUCHI, T., ICHIHARA, K., TSUNEKANE, T. and SUGAWA, A.: Morphological observations on the unfertilized ovum of the rabbit at varying time after an intravenous application of H. C. G., *Bull. Coll. Agr. & Vet. Med., Nihon Univ.*, **16**: 28-35. 1963
10. TSUTSUMI, Y. and TAKEDA, T.: Evidence of expulsion of unfertilized ova into the vagina in pseudopregnant rabbits, *Japan. J. Zootech. Sci.*, **47**: 509-517. 1976
11. TSUTSUMI, Y., TERAMI, Y., TAKEDA, T., SUZUKI, H. and MATSUI, S.: *In vivo* egg recovery from the vaginae and the pattern of egg distribution in superovulated rabbit, *Japan. J. Anim. Reprod.*, **26**: 6-14. 1980

### Plate 1

#### Explanation of Figures

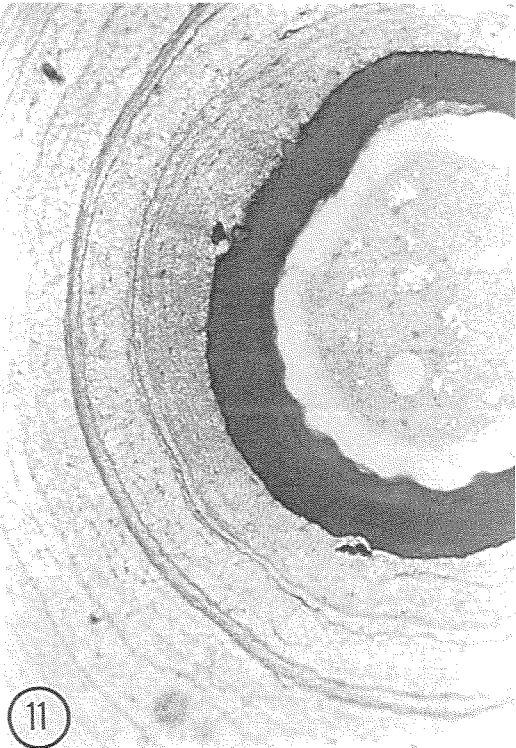
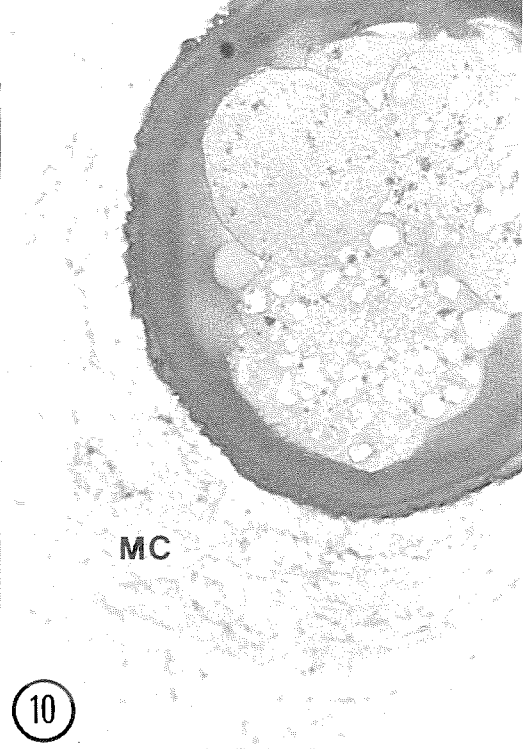
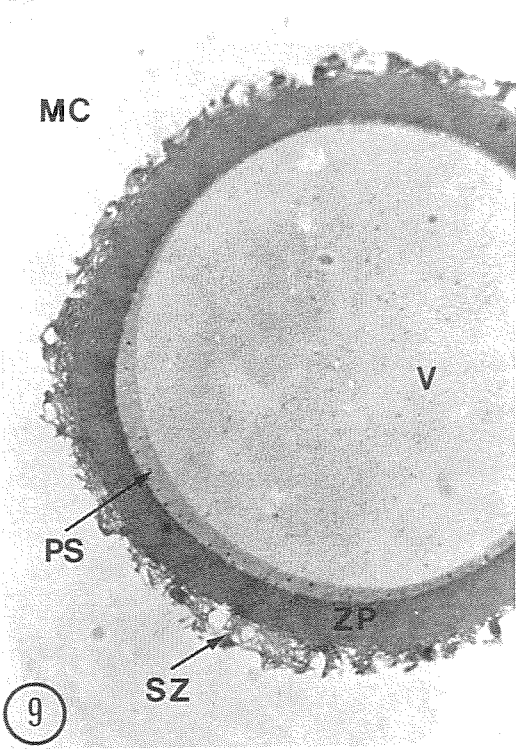
- Fig. 1. A raw egg recovered from an oviduct at 13 days of pseudopregnancy. Note the well preserved zona pellucida. ( $\times 147$ )  
MC, mucin coat; ZP, zona pellucida; PS, perivitelline space; V, vitellus.
- Fig. 2. A raw egg recovered from an oviduct at 15 days of pseudopregnancy. Note the well preserved zona pellucida. ( $\times 189$ )
- Fig. 3. A raw egg recovered from a uterus at 7 days of pseudopregnancy. There is no distinct zona pellucida. ( $\times 147$ )
- Fig. 4. A raw egg recovered from a uterus at 9 days of pseudopregnancy. A fine concentric-circular structure of the mucin coat is clear. ( $\times 147$ )
- Fig. 5. Rough surface of the inner part of the mucin coat in a uterine egg, observed in the raw state at 9 days of pseudopregnancy. ( $\times 244$ )
- Fig. 6. Raw eggs recovered from one uterine horn at 11 days of pseudopregnancy. ( $\times 44$ )
- Fig. 7. A raw egg recovered from a uterus at 13 days of pseudopregnancy. The doe in this case had 3 eggs in her oviducts simultaneously. One of the oviductal eggs is shown in Fig. 1. Note the granulation in the intra-zonal space. ( $\times 147$ )
- Fig. 8. A raw egg recovered from a uterus at 15 days of pseudopregnancy. Note the unclear intra-zonal space. ( $\times 151$ )



## Plate 2

### Explanation of Figures

- Fig. 9. A semi-thin section of an egg which was recovered from an oviduct at 2 days of pseudopregnancy. Note the spongy zone intermediate between the zona pellucida and the mucin coat. ( $\times 1230$ )  
MC, mucin coat; SZ, spongy zone; ZP, zona pellucida; PS, perivitelline space; V, vitellus.
- Fig. 10. A semi-thin section of an egg, recovered from a uterus at 4 days of pseudopregnancy. Note the diffusion or swelling of the inner part of the zona pellucida into the perivitelline space, the fragmentation of the vitellus, and the reduced spongy zone. ( $\times 1230$ )
- Fig. 11. A semi-thin section of an egg, recovered from a uterus at 6 days of pseudopregnancy. Note the fine concentric-circular structure of the mucin coat. ( $\times 1230$ )
- Fig. 12. A semi-thin section of an egg, recovered from a uterus at 7 days of pseudopregnancy. ( $\times 1230$ )



**Plate 3**  
Explanation of Figures

- Fig. 13. A semi-thin section of an egg, recovered from a uterus at 8 days of pseudopregnancy. Note the stratification of the zona pellucida. ( $\times 1230$ )  
MC, mucin coat; DZP, diffused zona pellucida; V, vitellus.
- Fig. 14. A semi-thin section of an egg, recovered from uterus at 9 days of pseudopregnancy. ( $\times 1230$ )
- Fig. 15. A semi-thin section of an egg, recovered from a ligated oviduct at 5 days of pseudopregnancy. Note the well preserved zona pellucida. ( $\times 1230$ )  
PS, perivitelline space.
- Fig. 16. A semi-thin section of an egg, recovered from a ligated oviduct at 9 days of pseudopregnancy. No diffusion or swelling of the zona pellucida occurs in oviductal eggs. ( $\times 510$ )

