



# HOKKAIDO UNIVERSITY

|                  |  |
|------------------|--|
| Title            | MSA-C is the predominant clinical phenotype of MSA in Japan : Analysis of 142 patients with probable MSA   |
| Author(s)        | Yabe, Ichiro; Soma, Hiroyuki; Takei, Asako et al.  |
| Citation         | Journal of the Neurological Sciences, 249(2), 115-121<br><a href="https://doi.org/10.1016/j.jns.2006.05.064">https://doi.org/10.1016/j.jns.2006.05.064</a> |
| Issue Date       | 2006-11-15   |
| Doc URL          | <a href="https://hdl.handle.net/2115/14449">https://hdl.handle.net/2115/14449</a>  |
| Type             | journal article  |
| File Information | yabe_jns.pdf   |



**Original Article**

**MSA-C is the predominant clinical phenotype of MSA in Japan: Analysis of 142 patients with probable MSA**

Ichiro Yabe<sup>1\*</sup>, Hiroyuki Soma<sup>1\*</sup>, Asako Takei<sup>2</sup>, Naoto Fujiki<sup>3</sup>, Tetsuro Yanagihara<sup>4</sup>, and Hidenao Sasaki<sup>1</sup>

1) Department of Neurology, Hokkaido University, Graduate School of Medicine, Sapporo, Hokkaido, Japan

2) Hokuyukai Neurology Hospital, Sapporo, Hokkaido, Japan

3) Department of Neurology, Sapporo Minami National Hospital, Sapporo, Hokkaido, Japan

4) Department of Neurology, Ebetsu City Hospital, Ebetsu, Hokkaido, Japan

\*: These authors contributed equally to this work.

Corresponding Author:

Ichiro Yabe,

Department of Neurology,

Hokkaido University, Graduate School of Medicine,

N15W7, Kita-Ku, Sapporo, Hokkaido, 060-8368, Japan

Phone: +81-11-706-6028

Fax: +81-11-700-5356

E-mail address: [yabe@med.hokudai.ac.jp](mailto:yabe@med.hokudai.ac.jp)

Number of words in the abstract: 221

Number of words in the manuscript: 2,986

Number of Tables: 5

Number of Figures: 1

Number of references: 40

Running title: MSA-C predominates in Japanese MSA

*Key Words:* multiple system atrophy; cerebellar ataxia; parkinsonism; autonomic failure;

MR imaging; diagnostic criteria

## **Abstract**

We investigated the clinical features and mode of disease progression in 142 patients with probable multiple system atrophy (MSA) according to the Consensus Criteria. The subjects included 84 men and 58 women with a mean age at onset of 58.2  $\pm$  7.1 years (range: 38-79 years). Cerebellar signs were detected in 87.3% of these patients at the time of initial examination, and were found in 95.1% of them at latest follow-up. MSA-C was diagnosed in 83.8% of the patients at their first examination. Parkinsonism was initially detected in 28.9% of the patients, increasing to 51.4% at the latest follow-up. Among all of the subjects, only 16.2% were classified as having MSA-P on initial examination. At the latest follow-up, parkinsonian features had become predominant over cerebellar features in 24.6% of the 65 patients with MSA-C who were followed for more than 3 years. Although parkinsonism usually masked the signs of cerebellar involvement in MSA-C patients, none of the patients with MSA-P at an early stage showed predominance of cerebellar features at the latest follow-up. Parkinsonism is the predominant feature of MSA among Western patients, even at an early stage, but this study showed that cerebellar deficits are the main feature in

Japanese patients. This difference of disease manifestations between ethnic groups suggests that genetic factors may influence the clinical phenotype of MSA.

## **1. Introduction**

Multiple system atrophy (MSA) is an adult-onset sporadic neurodegenerative disease that is clinically characterized by various combinations of poorly levodopa-responsive parkinsonism, cerebellar dysfunction, autonomic failure, and pyramidal tract involvement [1]. Neuropathologically, MSA is characterized by variable neuronal loss and gliosis in the putamen, substantia nigra, pontine nuclei, cerebellar cortex, inferior olive, and intermediolateral column of the spinal cord. The characteristic neuropathologic feature of MSA is the presence of glial cytoplasmic inclusions (GCIs) containing  $\alpha$ -synuclein in the oligodendrocytes [2, 3]. Therefore, MSA is classified as an “ $\alpha$ -synucleinopathy” together with Lewy body disease and Parkinson’s disease [4]. Recently, neural cytoplasmic inclusions (NCIs) were also reported to be a neuropathological feature of MSA. Sporadic olivopontocerebellar atrophy (OPCA), striatonigral degeneration (SND), and Shy-Drager syndrome were once classified as

different conditions on the basis of their predominant clinicopathological features, but Graham and Oppenheimer demonstrated that the main features of these three disorders are similar and first proposed the concept of “MSA” as a new disease entity in 1969 [5]. Quinn stated that autonomic dysfunction was the most important diagnostic feature of MSA, which was classified as the OPCA type when cerebellar deficits were predominant along with autonomic dysfunction, or as the SND type when parkinsonism was predominant together with autonomic dysfunction [6]. These diagnostic criteria later developed into the Consensus Criteria [1], which presently act as the basis for the clinical diagnosis of MSA. Patients with predominantly parkinsonian features are referred to as “MSA-P”, while those with predominantly cerebellar features are designated as “MSA-C”. However, the clinical features of MSA are variable and heterogenous. In addition, MSA patients often show only one of the defining features mentioned above at an early stage. Therefore, MSA is often misdiagnosed as one of the other disorders that present with parkinsonism or cerebellar ataxia [7, 8, 9, 10, 11, 12]. However, the prognosis of MSA is much worse than that of either idiopathic Parkinson’s disease or hereditary ataxia and the median survival time of MSA patients is

less than 10 years [13,14]. Accordingly, to make an accurate clinical diagnosis and provide appropriate advice and management, it is important to analyze the clinical features, course, and prognosis of this disorder. There is also a reported difference in the clinical manifestations of MSA between Japanese and Caucasian patients. MSA-P is generally the predominant type in Caucasians, while MSA-C is the more common type in Japanese patients [3,7, 15, 16, 17], but the basis of this ethnic difference is not well understood. In order to confirm the existence of this ethnic difference and clarify the clinical features of MSA, we investigated the initial symptoms, phenotype, MRI findings, and disease progression in Japanese patients with probable MSA.

## **2. Methods**

### *2.1. Patient selection and evaluation*

We retrospectively examined the medical records of 414 Japanese patients who were clinically suspected to have MSA and were referred to the Neurology Clinics of Hokkaido University Hospital, Hokuyukai Neurology Hospital, Sapporo Minami National Hospital, or Ebetsu City Hospital between 1982 and 2004. We evaluated these

patients according to the Consensus Criteria [1], and found that 142 patients fulfilled the criteria for probable MSA, while the other patients fitted the category of possible MSA. Unfortunately, a final diagnosis could not be made in the patients with possible MSA because we were not able to perform follow-up. The 142 patients with probable MSA underwent periodical review at our neurology outpatient clinics. We analyzed the clinical features, clinical phenotype, brain magnetic resonance imaging (MRI) findings, and natural history of these 142 probable cases. The Hokkaido University Ethics Committee approved this study. The clinical phenotype was decided according to the classification assigned at the first visit or at an early stage of the illness. Initial symptoms were defined as the first awareness of autonomic, motor, or respiratory symptoms by each patient. Respiratory symptoms included stridor, snoring, and dyspnea. While respiratory symptoms are actually included among motor symptoms, we assessed these symptoms independently because of the possibility of such symptoms causing sudden death. Autonomic symptoms consisted of urinary frequency, incontinence, and retention, postural light-headedness, syncope associated with orthostatic hypotension, and impotence. A symptom was defined as being present when the chief physician

mentioned it in a patient's medical record or when the physician detected it by asking the patient, spouse, or children questions about the presence of certain symptoms ( neurogenic bladder, snoring, stridor, dyspnea and impotence ). Motor symptoms included either parkinsonism or cerebellar ataxia, and consisted of gait disturbance, clumsiness of the upper extremities, dysarthria, and tremor. In patients who reached the advanced stage, we classified the clinical phenotype by considering whether parkinsonism or cerebellar ataxia provided a greater obstacle to daily activities. We examined each patient at least every six months and we evaluated the parameters mentioned above, including the activities of daily life (ADL), from information in each patient's medical record. In 109 patients (76.8%), brain MRI was performed to acquire T<sub>1</sub>- and T<sub>2</sub>-weighted axial images [2,300-4,000 ms repetition time ( TR), 80-120 ms echo time (TE), 5-8 mm slice thickness and 1-2.5 mm interslice gap].

## *2.2. Statistical analysis*

The Mann-Whitney U test was used to compare continuous variables between two subgroups. Contingency tables were analyzed by Fisher's exact test when the smallest expected value was < 5 or the chi-square test when the smallest expected value was > 5.

All tests were two-sided, and significance was set at  $p < 0.05$ . We used the StatView version 4.5 statistical software package for these calculations.

### **3. Results**

#### *3.1. Profile of the MSA Patients*

There were 84 men and 58 women. The mean age at onset of the first reported symptom was  $58.2 \pm 7.1$  years (range; 38-79 years) and the mean follow-up period was  $2.5 \pm 1.7$  years (range; 1-13 years). A total of 119 patients (83.8%) were initially classified as having MSA-C and 23 patients (16.2%) were classified as having MSA-P. The overall gender distribution (male : female) was 1.4 : 1, while it was 1.5 : 1 in MSA-C and 1.1 : 1 in MSA-P. There were no significant differences between the two types of MSA with regard to the age at onset and the follow-up period.

#### *3.2. Clinical features*

##### *3.2.1. Initial symptoms*

One hundred and seven patients (75.4%) complained of motor dysfunction as the

initial symptom (Table 1), while only 22.5% of the patients had autonomic problems. Gait disturbance was the most common symptom (62.2%), while 12.0% of the patients complained of neurogenic bladder and 9.9% had orthostatic hypotension. Interestingly, three patients (2.1%) initially presented with respiratory impairment and tracheotomy was performed.

### *3.2.2. Autonomic failure*

Symptoms of autonomic failure were present in 85.2% of the patients at initial examination (Table 2), and were detected in all of the patients at the time of latest follow-up (Table 3). Among these symptoms, urinary dysfunction was the most common (90.1%). Orthostatic hypotension was found in 88.0% of the MSA patients, while dyshidrosis was present in 22.5% and constipation was found in 16.2%.

### *3.2.3. Cerebellar dysfunction*

Cerebellar signs were detected in 87.3% of the patients at the time of initial examination (Table 2), and this increased to 95.1% at the latest follow-up (Table 3).

Cerebellar signs were present in 16 (69.6%) of the 23 MSA-P patients at latest follow-up. One of these patients only had ataxic dysarthria, while the other 15 had various forms of cerebellar ataxia. Among the latter 15 patients, gait ataxia combined with limb ataxia was present in 12 and the other 3 only demonstrated limb ataxia. In contrast, both gait ataxia and limb ataxia were present at latest follow-up in all of the MSA-C patients. Ataxic dysarthria was found in 96.6% of the MSA-C patients versus 47.8% of the MSA-P patients. Gaze nystagmus was detected in 35.2% of the patients overall, including 38.7% of MSA-C patients and 17.4% of MSA-P patients.

#### *3.2.4. Parkinsonism*

Parkinsonism was detected in 28.9% of the patients at initial examination (Table 2), but was present in 51.4% at the latest follow-up (Table 3). Although parkinsonism was detected in 50 MSA-C patients (42.0%) at the latest follow-up, bradykinesia with rigidity was seen in only 27 of them (22.7%). Tremor was documented in 19.0% of all patients and 43.5% of MSA-P patients, but resting tremor was only observed in 6 out of 142 MSA patients (4.2%) and 3 out of 23 MSA-P (13.0%).

In most of the patients, levodopa therapy did not alleviate these symptoms. Among the 37 patients who were prescribed levodopa, only 8 (21.6%) responded well during the early phase of therapy, but three of them subsequently became poor responders. One of these 3 patients had MSA-C and the other two had MSA-P.

#### *3.2.5. Respiratory dysfunction*

Respiratory dysfunction was evident in 33.8% of the MSA patients. Laryngoscopy revealed vocal cord paralysis in most of them and tracheotomy had to be performed in 7.0% (Table 3).

#### *3.2.6. Other clinical features*

Pyramidal tract signs, such as an extensor planter response and hyperreflexia, were detected in 67.6% and 33.1% of the MSA patients, respectively (Table 3). Abnormal ocular movements ( in addition to nystagmus ) were seen in response to saccadic pursuits in 19.7% of the patients. Vibration sensation was decreased in the lower extremities of 21.8% of the patients.

### 3.3. MRI evaluation

Fifty-three patients were evaluated with a 1.5 T MRI scanner, while 63 patients were assessed with a 0.5 T scanner. Atrophy of the cerebellum and brainstem were observed in most of the patients. Abnormal putaminal signals, including a hyperintense ( T2WI ) rim at the outer margin of the putamen, were evident in 16.7% of MSA-C patients and 68.4% of MSA-P patients ( $p < 0.001$ ). Abnormal pontine signals, including a 'hot cross bun' sign, were found in 54.4% of MSA-C patients and 31.6% of MSA-P patients ( $p = 0.067$ ) (Table 4). There were no significant differences in the frequency of signal abnormalities between the images obtained with the 1.5 T and 0.5 T MRI scanners ( data not shown ). Signal abnormalities became more frequent as the duration of disease increased (Table 5).

### 3.4. Changes of clinical features

We followed 65 patients with MSA-C for at least 3 years. At the initial examination, parkinsonism was only detected in 15.4% of these patients, but it was

found in 53.8% of them at the latest follow-up. In 24.6% of these patients, parkinsonian features became dominant over cerebellar features during follow-up (Figure 1). Some of the patients who were initially classified as “MSA-C” were reclassified as “MSA-P” by the time of the latest follow-up. In contrast, no patient initially classified as MSA-P showed dominance of cerebellar features at the latest follow-up.

### 3.5. Survival

Nineteen patients ( 14 men and 5 women ) died during the data collection period, but autopsies was not performed on any of them. Their mean age at onset was  $58.2 \pm 6.5$  years (range; 45-74 years) and their mean duration of disease was  $7.2 \pm 3.9$  years (range; 1-27 years). Sudden death occurred in 4 of these patients, and the mean time from onset to death was  $4.5 \pm 2.0$  years (range; 2-7 years). All patients were initially classified as having MSA-C, with initial parkinsonism being detected in only 5 of them (26.3%). At the latest follow-up, however, parkinsonism was present in 12 of these patients (63.2%) and parkinsonian features had become dominant in 5 of them (26.3%). On the other hand, parkinsonism was never detected in the other 7 patients (36.8%).

#### **4. Discussion**

One hundred and nineteen (83.8%) of our 142 patients with probable MSA were initially classified as having MSA-C, which was a much more frequent manifestation of MSA than MSA-P (16.2%). In another series, 155 (67%) out of 230 Japanese MSA patients were classified as having MSA-C [17]. Therefore, MSA-C is considered to be the most common initial manifestation of MSA in the Japanese population. In contrast, parkinsonism is predominant from the onset among Caucasian MSA patients [3, 7, 13, 15]. One study performed in Germany showed that the frequency of MSA-C was higher than that of MSA-P [16], but there may have been some bias in this epidemiological study because it was mainly based on neuroimaging data.

In addition to the differences in the initial presentation of MSA patients, further differences emerged as the disease progressed. By the time of latest follow-up, parkinsonian features had become dominant over the cerebellar features in 24.6% of 65 patients with MSA-C who were followed for more than 3 years. Only a few authors have previously described this clinical transition of MSA [18,19]. A change of clinical

manifestations was observed in some of our MSA-C patients, but none of the patients with MSA-P at an early stage showed dominance of cerebellar features by the time of latest follow-up, although this might have been due to the small number of MSA-P cases and the short follow-up period of our study. It might also be an indication that progression of parkinsonism is much faster than that of cerebellar ataxia in some MSA patients. Ozawa et al. performed a semi-quantitative analysis of pathological changes in the striatonigral and olivopontocerebellar regions of 100 MSA patients with well-characterized clinical phenotypes, and reported that MSA-P was predominantly associated with striatonigral changes, while olivopontocerebellar pathology was prominent in MSA-C [4]. They also suggested that the pathological threshold for the clinical onset of parkinsonism was lower than that for ataxia [4]. This may explain why parkinsonian features become dominant over cerebellar features in some MSA-C patients. However, parkinsonism was not detected in 7 of our 19 patients with MSA-C who died during the data collection period. Progression of parkinsonism and/or cerebellar ataxia varies considerably between individual MSA patients, and it is difficult to predict the course of either symptom complex. The predominant manifestation of

MSA also varies among different ethnic populations [3, 7, 15, 17], suggesting that differences of the genetic background or environmental factors can influence the phenotype, clinical features, and progression of MSA. Although no association has been found between MSA and polymorphism of the  $\alpha$ -synuclein, synphilin, tau, APOE, Fragile X, and brain-derived neurotrophic factor genes [20, 21, 22, 23], polymorphism of the interleukin-1A, interleukin-1B, interleukin-8, intercellular adhesion molecule-1, tumor necrosis factor, and alpha-1-antichymotrypsin genes has been reported to increase the risk of MSA [24, 25, 26, 27, 28]. In addition, a few familial cases of MSA have recently been reported [29, 30]. Although further genetic studies are needed, it seems possible that genetic factors may influence the clinical manifestations and course of MSA. Therefore, the clinical features revealed by our data may be useful in molecular genetic studies such as association studies. On the other hand, Vanacore et al. recently reported that smoking and farming might independently influence the risk of MSA [31]. Moreover, some authors have reported that patients with MSA have significantly more potential exposure to environmental toxins than a control population [32, 33]. Although we could not investigate the lifestyle and occupations of the MSA patients in our series,

it is possible that environmental factors also influenced their clinical features.

In this series, the frequency of neurogenic bladder at an early stage and impotence was relatively low compared with several previous reports [12, 14]. However, this result may have been biased because it was determined by asking questions and by retrospective review of each patient's medical record.

According to the current criteria [1], probable MSA is diagnosed clinically in patients who have parkinsonism with a poor response to levodopa plus autonomic dysfunction or cerebellar ataxia plus autonomic dysfunction. Physicians who specialize in ataxia tend to diagnose patients with sporadic cerebellar ataxia as having MSA-C because some patients with sporadic olivopontocerebellar atrophy eventually develop MSA [34]. However, our data were not skewed by a special interest in cerebellar disorders, because none of our patients were seen at cerebellar units, and instead were assessed at the general neurology ward or outpatient clinic. Other disorders associated with parkinsonism, such as Parkinson's disease with autonomic failure, progressive supranuclear palsy (PSP), and diffuse Lewy body disease (DLBD), may often be misdiagnosed as MSA-P [7, 8, 9, 10, 11, 12]. A neuropathological study showed that

the false-positive diagnoses of MSA included Parkinson's disease, PSP, and cerebrovascular disease [10]. Since MSA patients usually show little cognitive impairment, PSP and DLBD can be distinguished from MSA on this basis [35]. In addition, when cerebellar ataxia exists throughout the clinical course, MSA can be accurately distinguished from other forms of parkinsonism, but discrimination is often difficult at an early stage. Accordingly, some patients with MSA-P may be misdiagnosed as having Parkinson's disease in Japan. For more accurate diagnosis, it is important to carefully observe the clinical course.

Although the diagnostic criteria for MSA do not include specific imaging findings, our data suggest that brain MRI may be useful for making a correct diagnosis. Most MSA patients have some abnormalities on brain MRI, and follow-up MRI showed that signal abnormalities in the pons and putamen became more frequent with a longer duration of disease. In addition, Oba et al. have reported that measurement of the area of the midbrain on mid-sagittal MRI can be used to differentiate PSP from MSA [36]. Besides MRI, myocardial iodine-123 meta-iodobenzylguanidine (MIBG) scintigraphy is also useful for distinguishing between Parkinson's disease, DLBD, and MSA, since

myocardial MIBG uptake is significantly lower in Parkinson's disease and DLBD than in MSA [37, 38]. Moreover, single photon emission computed tomography (SPECT) and positron emission tomography (PET) have also been reported to be helpful for differentiating between MSA and other forms of parkinsonism. SPECT imaging of patients with DLBD and Parkinson's disease shows that cerebral blood flow is reduced in the occipital lobe [39], while a [<sup>18</sup>F]fluorodeoxyglucose (FDG)-PET study showed that glucose hypometabolism was most prominent in the cerebellum, the brain stem, the striatum, and the frontal and motor regions of the cerebral cortex in MSA [40].

In summary, our findings suggest that co-existence of both poorly levodopa-responsive parkinsonism and cerebellar ataxia at some point in the clinical course is necessary for an accurate clinical diagnosis of probable MSA, and that the results of imaging studies like brain MRI, myocardial MIBG scintigraphy, and SPECT/PET should also be added to the diagnostic criteria.

### **Acknowledgements**

This work was partly supported by a Grant-in-Aid for "the Research

Committee for Ataxic Diseases" of the Research on Measures for Intractable Diseases from the Ministry of Health, Welfare and Labour, Japan, by a Grant-in-Aid for Scientific Research from the Ministry of Education, Science, Sports, and Culture, Japan, by a Grant from the Akiyama Foundation, and by a Grant from the Noastic Foundation.

## References

1. Gilman S, Low PA, Quinn N, Albanese A, Ben-Shlomo Y, Fowler CJ, Kaufmann H, Klockgether T, Lang AE, Lantos PL, Litvan I, Mathias CJ, Oliver E, Robertson D, Schatz I, Wenning GK. Consensus statement on the diagnosis of multiple system atrophy. *J Neurol Sci* 1999; 163: 94–8.
2. Wakabayashi K, Yoshimoto M, Tsuji S, Takahashi H.  $\alpha$ -Synuclein immunoreactivity in glial cytoplasmic inclusions in multiple system atrophy. *Neurosci Lett* 1998; 249: 180–2.
3. Wenning GK, Ben-Shlomo Y, Hughes A, Daniel SE, Lees A, Quinn NP. What clinical features are most useful to distinguish definite multiple system atrophy from

- Parkinson's disease? *J Neurol Neurosurg Psychiatry* 2000; 68:434-40.
4. Ozawa T, Paviour D, Quinn NP, Josephs KA, Sangha H, Kilford L, Healy DG, Wood NW, Lees AJ, Holton JL, Revesz T. The spectrum of pathological and olivopontocerebellar systems in multiple system atrophy: clinicopathological correlations. *Brain* 2004; 127: 2657-71.
  5. Graham J, Oppenheimer DR. Orthostatic hypotension and nicotine sensitivity in a case of multiple system atrophy. *J Neurol Neurosurg Psychiatry* 1969; 32: 28-34.
  6. Quinn N. Multiple system atrophy. In: Marsden CD, Fahn S (eds) *Movement disorders 3*. London: Butterworths, 1994: 262-81.
  7. Chrysostome V, Tison F, Yekhlef F, Sourgen C, Baldi I, Dartigues JF. Epidemiology of multiple system atrophy: a prevalence and pilot risk factor study in Aquitaine, France. *Neuroepidemiology*. 2004; 23: 201-8.
  8. Lee EA, Cho HI, Kim SS, Lee WY. Comparison of magnetic resonance imaging in subtypes of multiple system atrophy. *Parkinsonism Relat Disord* 2004; 10: 363-8.
  9. Litvan I, Goetz CG, Jankovic J, Wenning GK, Booth V, Bartko JJ, McKee A, Jellinger K, Lai EC, Brandel JP, Verny M, Chaudhuri KR, Pearce RK, Agid Y. What is the

- accuracy of the clinical diagnosis of multiple system atrophy? A clinicopathologic study. *Arch Neurol* 1997; 54: 937-44.
10. Osaki Y, Wenning GK, Daniel SE, Hughes A, Lees AJ, Mathias CJ, Quinn N. Do published criteria improve clinical diagnostic accuracy in multiple system atrophy? *Neurology* 2002; 59:1486-91.
11. Wenning GK, Ben-Shlomo Y, Magalhaes M, Daniel SE, Quinn NP. Clinicopathological study of 35 cases of multiple system atrophy. *J Neurol Neurosurg Psychiatry* 1995; 58 : 160–166.
12. Wenning GK, Tison F, Ben Shlomo Y, Daniel SE, Quinn NP. Multiple system atrophy: a review of 203 pathologically proven cases. *Mov Disord* 1997; 12:133-47.
13. Ben-Shlomo Y, Wenning GK, Tison F, Quinn NP. Survival of patients with pathologically proven multiple system atrophy: a meta-analysis. *Neurology* 1997; 48: 384-93.
14. Wenning GK, Ben-Shlomo Y, Magalhes M, Daniel SE, Quinn NP. Clinical features and natural history of multiple system atrophy: an analysis of 100 cases. *Brain* 1994; 117: 835-45.

15. Bower JH, Maraganore DM, McDonnell SK, Rocca WA. Incidence of progressive supranuclear palsy and multiple system atrophy in Olmsted County, Minnesota, 1976 to 1990. *Neurology* 1997; 49:1284-8.
16. Schulz JB, Klockgether T, Petersen D, Jauch M, Muller-Schauenburg W, Spieker S, Voigt K, Dichgans J. Multiple system atrophy: natural history, MRI morphology, and dopamine receptor imaging with 123IBZM-SPECT. *J Neurol Neurosurg Psychiatry* 1994; 57:1047-56.
17. Watanabe H, Saito Y, Terao S, Ando T, Kachi T, Mukai E, Aiba I, Abe Y, Tamakoshi A, Doyu M, Hirayama M, Sobue G. Progression and prognosis in multiple system atrophy: an analysis of 230 Japanese patients. *Brain* 2002; 125: 1070–83.
18. Dejerine J, Thomas A. L'atrophie olivo-ponto-cerebelleuse. *Nouv Iconogr Salpetriere* 1900; 13: 330-70.
19. Hirayama K, Saito M, Chida T, Iizuka R, Murobushi K. A clinicopathological study on extrapyramidal components in cerebellar degeneration with special reference to olivo-ponto-cerebellar atrophy. *Shinkei Kenkyu no Shinpo* 1997; 21: 37-54. (in Japanese)

20. Garland EM, Vnencak-Jones CL, Biaggioni I, Davis TL, Montine TJ, Robertson D. Fragile X gene premutation in multiple system atrophy. *J Neurol Sci* 2004; 227: 115-8.
21. Morris HR, Vaughan JR, Datta SR, Bandopadhyay R, Rohan De Silva HA, Schrag A, Cairns NJ, Burn D, Nath U, Lantos PL, Daniel S, Lees AJ, Quinn NP, Wood NW. Multiple system atrophy / progressive supranuclear palsy: alpha-synuclein, synphilin, tau, and APOE. *Neurology* 2000; 55: 1918-20.
22. Nishimura M, Kuno S, Kaji R, Kawakami H. Brain-derived neurotrophic factor gene polymorphism in Japanese patients with sporadic Alzheimer's disease, Parkinson's disease, and multiple system atrophy. *Mov Disord* 2005; 20: 1031-59.
23. Yabe I, Soma H, Takei A, Fujiki N, Sasaki H. No association between FMR1 premutations and multiple system atrophy. *J Neurol* 2004; 251: 1411-2.
24. Combarros O, Infante J, Llorca J, Berciano J. Interleukin-1A (-889) genetic polymorphism increases the risk of multiple system atrophy. *Mov Disord* 2003; 18 :1385-6.
25. Furiya Y, Hirano M, Kurumatani N, Nakamuro T, Matsumura R, Futamura N, Ueno

- S. Alpha-1-antichymotrypsin gene polymorphism and susceptibility to multiple system atrophy (MSA). *Mol Brain Res* 2005; 138: 178-81.
26. Infante J, Llorca J, Berciano J, Combarros O. Interleukin-8, intercellular adhesion molecule-1 and tumour necrosis factor-alpha gene polymorphisms and the risk for multiple system atrophy. *J Neurol Sci* 2005; 228:11-3.
27. Nishimura M, Kawakami H, Komure O, Maruyama H, Morino H, Izumi Y, Nakamura S, Kaji R, Kuno S. Contribution of the interleukin-1 beta gene polymorphism in multiple system atrophy. *Mov Disord* 2002; 17: 808-11.
28. Nishimura M, Kuno S, Kaji R, Kawakami H. Influence of a tumor necrosis factor gene polymorphism in Japanese patients with multiple system atrophy. *Neurosci Lett* 2005; 374:218-21.
29. Soma H, Yabe I, Takei A, Fujiki N, Yanagihara T, Sasaki H. Hereditary in multiple system atrophy. *J Neurol Sci* 2006; 240: 107-10.
30. Wullner U, Abele M, Schmitz-Huebsch T, Wilhelm K, Benecke R, Deuschl G, Klockgether T. Probable multiple system atrophy in a German family. *J Neurol Neurosurg Psychiatry* 2004; 75:924-5.

31. Vanacore N, Bonifati V, Fabbrini G, Colosimo C, De Michele G, Marconi R, Stocchi F, Nicholl D, Bonuccelli U, De Mari M, Vieregge P, Meco G; ESGAP Consortium. Case-control study of multiple system atrophy. *Mov Disord* 2005; 20:158-63.
32. Hanna PA, Jankovic J, Kirkpatrick JB. Multiple system atrophy: the putative causative role of environmental toxins. *Arch Neurol* 1999; 56: 90-4.
33. Nee LE, Gomez MR, Dambrosia J, Bale S, Eldridge R, Polinsky RJ. Environmental-occupational risk factors and familial associations in multiple system atrophy: a preliminary investigation. *Clin Auton Res* 1991; 1: 9-13.
34. Gilman S, Little R, Johanns J, Heumann M, Kluin KJ, Junck L, Koeppe RA, An H. Evolution of sporadic olivopontocerebellar atrophy into multiple system atrophy. *Neurology* 2000; 55:527-32.
35. Bak TH, Rogers TT, Crawford LM, Hearn VC, Mathuranath PS, Hodges JR. Cognitive bedside assessment in atypical parkinsonian syndromes. *J Neurol Neurosurg Psychiatry* 2005; 76:420-2.
36. Oba H, Yagishita A, Terada H, Barkovich AJ, Kutomi K, Yamauchi T, Furui S, Shimizu T, Uchigata M, Matsumura K, Sonoo M, Sakai M, Takada K, Harasawa A,

- Takeshita K, Kohtake H, Tanaka H, Suzuki S. New and reliable MRI diagnosis for progressive supranuclear palsy. *Neurology* 2005; 64: 2050-5.
37. McKeith IG, Dickson DW, Lowe J, Emre M, O'Brien JT, Feldman H, Cummings J, Duda JE, Lippa C, Perry EK, Aarsland D, Arai H, Ballard CG, Boeve B, Burn DJ, Costa D, Del Ser T, Dubois B, Galasko D, Gauthier S, Goetz CG, Gomez-Tortosa E, Halliday G, Hansen LA, Hardy J, Iwatsubo T, Kalaria RN, Kaufer D, Kenny RA, Korczyn A, Kosaka K, Lee V.M-Y, Lees A, Litvan I, Londos E, Lopez OL, Minoshima S, Mizuno Y, Molina JA, Mukaetove-Ladinska EB, Pasquier F, Perry RH, Schulz JB, Trojanowski JQ, Yamada M, and for the Consortium on DLB. Diagnosis and management of dementia with Lewy bodies. Third report of the DLB consortium. *Neurology* 2005; 65: 1863-72.
38. Orimo S, Ozawa E, Oka T, Nakade S, Tsuchiya K, Yoshimoto M, Wakabayashi K, Takahashi H. Different histopathology accounting for a decrease in myocardial MIBG uptake in PD and MSA. *Neurology* 2001; 57:1140-1.
39. Mito Y, Yoshida K, Yabe I, Makino K, Hirotsu M, Tashiro K, Kikuchi S, Sasaki H. Brain 3D-SSP SPECT analysis in dementia with Lewy bodies, Parkinson's disease

with and without dementia, and Alzheimer's disease. *Clin Neurol Neurosurg* 2005; 107: 396-403.

40. Gilman S. Functional imaging with positron emission tomography in multiple system atrophy. *J Neural Transm* 2005; 112: 1647-55.

## **Legends**

Table 1. Initial symptoms

Table 2. Neurological findings at the first examination

Table 3. Clinical features at the latest follow-up

Table 4. Characteristic MRI findings

Table 5. Disease duration and frequency of MRI signal abnormalities

Figure 1. Sixty-five MSA-C patients followed for more than 3 years. At the initial examination, parkinsonism was only detected in 10 patients, but it was found in 35 patients at the latest follow-up. Furthermore, parkinsonian features were dominant over cerebellar features in 16 of the patients.

P (-); MSA-C patients without parkinsonian features,

P (+); MSA-C patients with parkinsonian features,

P predominance; patients in whom parkinsonian features became predominant over cerebellar features.

Table 1. Initial symptoms

|  | <b>MSA</b> | <b>MSA-C</b> | <b>MSA-P</b> |
|--|------------|--------------|--------------|
| <b>Number of patients</b>              | 142        | 119          | 23           |
| <b>Autonomic symptoms;</b>             | 32(22.5)*  | 28 (23.5)    | 4 (17.4)     |
| <b>Neurogenic bladder</b>              | 17 (12.0)  | 14 (11.8)    | 3 (13.0)     |
| <b>Impotence</b>                       | 1 (0.7)    | 1 (0.8)      | 0            |
| <b>Orthostatic hypotension</b>         | 14 (9.9)   | 13 (10.9)    | 1 (4.4)      |
| <b>Motor symptoms;</b>                 | 107 (75.4) | 88 (74.0)    | 19 (82.6)    |
| <b>Dysarthria</b>                      | 10 (7.0)   | 10 (8.4)     | 0            |
| <b>Clumsiness of upper extremities</b> | 8 (5.6)    | 4 (3.4)      | 4 (17.4)     |
| <b>Gait disturbance</b>                | 88 (62.0)  | 74 (62.2)    | 14 (60.7)    |
| <b>Respiratory symptoms</b>            | 3 (2.1)    | 3 (2.5)      | 0            |

\* number of patients ( % of all subjects)

Table 2. Neurological findings at the first examination

|                                | <b>MSA-C</b> | <b>MSA-P</b> | <b>MSA</b> |
|--------------------------------|--------------|--------------|------------|
| <b>Number of patients</b>      | 119          | 23           | 142        |
| <b>Autonomic failure</b>       | 102 (85.7)*  | 19 (82.6)    | 121 (85.2) |
| <b>Neurogenic bladder</b>      | 83 (69.7)    | 19 (82.6)    | 102 (71.8) |
| <b>Orthostatic hypotension</b> | 85 (71.4)    | 12 (52.2)    | 97 (68.3)  |
| <b>Cerebellar ataxia</b>       | 112 (94.1)   | 12 (52.2)    | 124 (87.3) |
| <b>Parkinsonism</b>            | 18 (15.1)    | 23 (100)     | 41 (28.9)  |
| <b>Pyramidal signs</b>         | 22 (18.5)    | 2 (8.7)      | 24 (16.9)  |
| <b>Respiratory failure</b>     | 13 (10.9)    | 7 (30.4)     | 20 (14.1)  |

\* number of patients ( % of all subjects)

Table 3. Clinical features at the latest follow-up

|                                  | <b>MSA</b>  | <b>MSA-C</b> | <b>MSA-P</b> |
|----------------------------------|-------------|--------------|--------------|
| <b>Number of patients</b>        | 142         | 119          | 23           |
| <b>Autonomic failure</b>         |             |              |              |
| <b>Neurogenic bladder</b>        | 128 (90.1)* | 108 (90.8)   | 20 (87.0)    |
| <b>&lt; Therapy &gt;</b>         |             |              |              |
| <b>Catheter</b>                  | 31 (21.8)   | 26 (24.1)    | 5 (25.0)     |
| <b>Self-catheter</b>             | 27 (21.1)   | 23 (21.3)    | 4 (20.0)     |
| <b>Medication</b>                | 11 (8.6)    | 6 (5.6)      | 5 (25.0)     |
| <b>None</b>                      | 59 (46.1)   | 53 (49.1)    | 6 (30.0)     |
| <b>Impotence (male)</b>          | 54 (64.3)   | 46 (63.9)    | 8 (66.7)     |
| <b>Orthostatic hypotension</b>   | 125 (88.0)  | 108 (90.8)   | 17 (73.9)    |
| <b>≥ sys. 20 or dia. 10 mmHg</b> | 16 (11.3)   | 13 (10.9)    | 3 (13.0)     |
| <b>≥ sys. 30 or dia. 15 mmHg</b> | 109 (76.8)  | 95 (79.8)    | 14 (60.1)    |
| <b>Dyshidrosis</b>               | 32 (22.5)   | 30 (25.2)    | 2 (8.7)      |
| <b>Constipation</b>              | 23 (16.2)   | 20 (16.8)    | 3 (13.0)     |
| <b>Motor impairment</b>          |             |              |              |
| <b>Cerebellar dysfunction</b>    | 135 (95.1)  | 119 (100)    | 16 (69.6)    |

|                                |                                      |            |            |           |
|--------------------------------|--------------------------------------|------------|------------|-----------|
|                                | <b>gait ataxia</b>                   | 131 (92.3) | 119 (100)  | 12 (52.2) |
|                                | <b>limb ataxia</b>                   | 134 (94.4) | 119 (100)  | 15 (65.2) |
|                                | <b>ataxic dysarthria</b>             | 126 (88.7) | 115 (96.6) | 11 (47.8) |
|                                | <b>nystagmus</b>                     | 50 (35.2)  | 46 (38.7)  | 4 (17.4)  |
| <b>Parkinsonism</b>            |                                      | 73 (51.4)  | 50 (42.0)  | 23 (100)  |
|                                | <b>bradykinesia</b>                  | 61 (43.0)  | 38 (31.9)  | 23 (100)  |
|                                | <b>rigidity</b>                      | 62 (43.7)  | 39 (32.8)  | 23 (100)  |
|                                | <b>postural instability</b>          | 45 (31.7)  | 22 (18.5)  | 23 (100)  |
| <b>Tremor (total)</b>          |                                      | 27 (19.0)  | 17 (14.3)  | 10 (43.5) |
|                                | <b>Resting tremor</b>                | 2 (1.4)    | 1 (0.8)    | 1 (4.3)   |
|                                | <b>Resting &amp; postural tremor</b> | 4 (2.8)    | 2 (1.7)    | 2 (8.7)   |
|                                | <b>Postural &amp; action tremor</b>  | 14 (9.9)   | 12 (10.1)  | 2 (8.7)   |
|                                | <b>Unspecified tremor</b>            | 7 (4.9)    | 2 (1.7)    | 5 (21.7)  |
| <b>Pyramidal signs</b>         |                                      |            |            |           |
|                                | <b>Hyperreflexia</b>                 | 47 (33.1)  | 42 (35.3)  | 5 (21.7)  |
|                                | <b>Extensor plantar reflex</b>       | 96 (67.6)  | 85 (71.4)  | 11 (47.8) |
| <b>Respiratory dysfunction</b> |                                      | 48 (33.8)  | 41 (34.5)  | 7 (30.4)  |
|                                | <b>Tracheotomy</b>                   | 10 (7.0)   | 10 (8.4)   | 0         |

---

\* number of patients ( % of all subjects)

Table 4. Characteristic MRI findings

|   | <b>MSA (total)</b>  | <b>MSA-C</b>        | <b>MSA-P</b>        | <b>p value (MSA-C vs MSA-P)</b> |
|---|---------------------|---------------------|---------------------|---------------------------------|
| <b>Number of patients (men : women)</b> | 109 (63 : 46)       | 90 (54 : 36)        | 19 (9 : 10)         |                                 |
| <b>Time from onset (range)</b>          | 4.0 ± 3.2 (1-24) yr | 3.9 ± 2.0 (1-12) yr | 4.6 ± 5.2 (1-24) yr | 0.849                           |
| <b>Atrophy ;</b>                        |                     |                     |                     |                                 |
| <b>cerebellum</b>                       | 103 (94.5%)*        | 87 (96.7%)          | 16 (84.2%)          | 0.064                           |
| <b>brain stem</b>                       | 93 (85.3%)          | 80 (88.9%)          | 13 (68.4%)          | 0.033                           |
| <b>Abnormal intensity ;</b>             |                     |                     |                     |                                 |
| <b>Pons</b>                             | 55 (50.5%)          | 49 (54.4%)          | 6 (31.6%)           | 0.067                           |
| <b>hot cross bun sign</b>               | 31 (28.4%)          | 29 (32.2%)          | 2 (10.5%)           | 0.056                           |
| <b>Putamen</b>                          | 28 (25.7%)          | 15 (16.7%)          | 13 (68.4%)          | < 0.001                         |
| <b>hypointensity</b>                    | 17 (15.6%)          | 7 (7.8%)            | 10 (52.6%)          | < 0.001                         |
| <b>hyperintense rim</b>                 | 15 (13.8%)          | 10 (11.1%)          | 5 (26.3%)           | 0.1265                          |
| <b>Cerebellar white matter</b>          | 2 (1.8%)            | 2 (2.2%)            | 0                   |                                 |

\* number of patients ( % of all subjects)


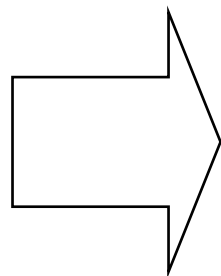
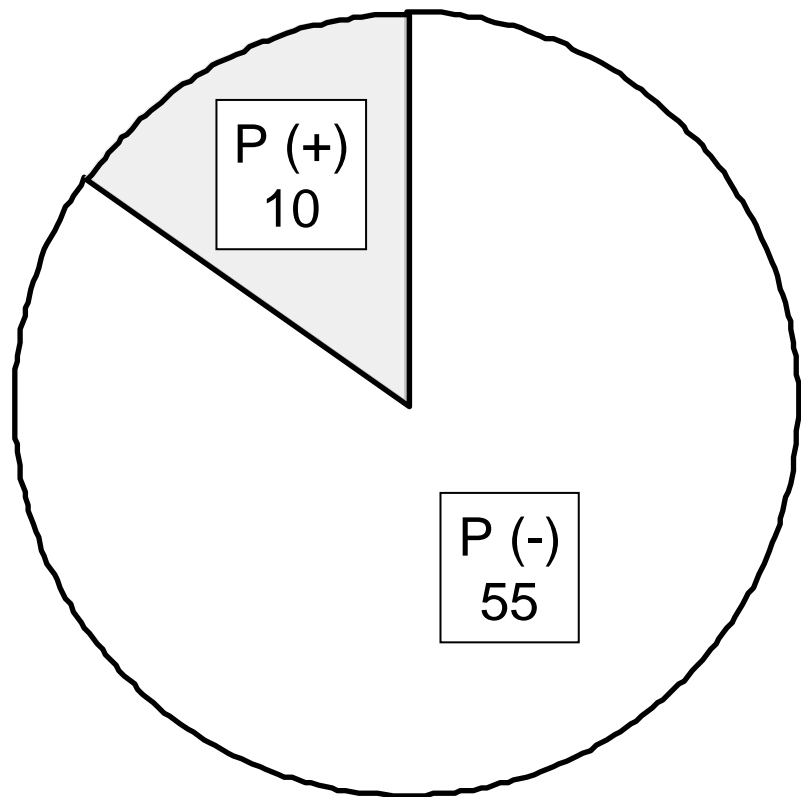
Table 5 Disease duration and frequency of MRI signal abnormalities

| Disease duration | MSA-C |                            |          | MSA-P |                            |           |
|------------------|-------|----------------------------|----------|-------|----------------------------|-----------|
|                  | n     | Signal abnormalities n (%) |          | n     | Signal abnormalities n (%) |           |
|                  |       | pons                       | putamen  |       | pons                       | putamen   |
| ≤ 2 years        | 74    | 18 (24.3)                  | 5 (6.8)  | 9     | 1 (11.1)                   | 3 (33.3)  |
| ≤ 4 years        | 46    | 22 (47.8)                  | 7 (15.2) | 9     | 5 (55.6)                   | 5 (55.6)  |
| > 4 years        | 32    | 21 (65.6)                  | 7 (21.9) | 6     | 3 (50.0)                   | 6 (100.0) |

Figure 1

First examination

Latest follow-up



n = 65