HOKKAIDO UNIVERSITY

Title	Establishment and characterization of amylase-producing lung adenocarcinoma cell line, IMEC-2.
Author(s)	Yokouchi, Hiroshi; Yamazaki, Koichi; Asahina, Hajime et al.
Issue Date	2006-07
Doc URL	https://hdl.handle.net/2115/15843
Type	journal article
File Information	AR26-4B.pdf

Hokkaido University Collection of Scholarly and Academic Papers : HUSCAP

Establishment and Characterization of Amylase-producing Lung Adenocarcinoma Cell Line, IMEC-2

HIROSHI YOKOUCHI,[1] KOICHI YAMAZAKI,[1] HAJIME ASAHINA, [1] MASAHIKO SHIGEMURA,[2] TAKANORI MORIYAMA,[3] KAZUO TAKAOKA,[4] JUN MORIYA,[5] TOMOO ITOH,[5] ICHIRO KINOSHITA,[6] HIROTOSHI DOSAKA-AKITA,[6] YUTAKA TSUTSUMI,[7] and MASAHARU NISHIMURA [1,2]

[1]First Department of Medicine, Hokkaido University School of Medicine, North 15, West 7, Kita-ku, Sapporo 060-8638; [2] Department of Clinical Laboratory, Hokkaido University Hospital, North 14 West 5, Sapporo 060-8648; [3]Division of Laboratory Technology, Department of Healthy Sciences, School of Medicine, Hokkaido University, North 12 West 5, Sapporo 060-0812; [4]Department of Respiratory Medicine, Sapporo Hospital of Social Health Insurance, 2-6-2-1, Atsubetsuchuo, Atsubetsu-ku, Sapporo 004-8618; [5]Department of Surgical Pathology, Hokkaido University Hospital, North 14 West 5, Kita-ku, Sapporo 060-8648; [6]Department of Medical Oncology, Hokkaido University Graduate School of Medicine, North 15, West 7, Kita-ku, Sapporo 060-8638; [7]First Department of Pathology, Fujita Health University School of Medicine, 1-98, Dengakugakubo, Kutsukake-cho, Toyoake, 470-1192, Japan

Correspondence to: Hiroshi Yokouchi, First Department of Medicine, Hokkaido University School of Medicine, North 15, West 7, Kita-ku, Sapporo 060-8638,

Japan. Tel.: +81-11-706-5911, Fax: +81-11-706-7899, e-mail: yokouchi@med.hokudai.ac.jp

Key words: amylase, lung cancer, cell line, sialylation, IMEC-2.

Running title: Amylase-producing lung cancer cell line

This work is a full paper of ***Experimental study.7***

Date of revise submission: March 26th., 2006

Abstract.

Background: Few studies have successfully established an amylase-producing lung cancer cell line or have examined its cytological, biochemical and biological features. Materials and Methods: Cancer cells isolated from pleural effusion using a gradient method were cultivated. Results: Amylase production from the newly established cell line was confirmed by positive staining for α-amylase and increased amylase levels in culture supernatant. Electron microscopy revealed zymogen granule-like structures. Sialylation of salivary-type amylase was confirmed directly from the cell line by examining neuraminidase sensitivity and amylase elution profile under high-performance liquid chromatography. *EGFR* or *KRAS* mutation was not found. Conclusions: This cell line offers a useful tool for analyzing the pathogenesis and pathophysiology of amylase-producing lung cancers. Moreover, it might be useful for probing metastasis and invasiveness of lung cancer cells and for developing an early diagnostic method based on sialylated salivary-amylase

production.

Introduction

Since Weiss *et al*. (1) presented the first case of bronchogenic carcinoma associated with elevated serum amylase levels in 1951, several similar reports have been published (2-12). Analysis of primary tumor tissues has strongly supported the theory that amylase is produced by lung carcinoma cells. Isoenzyme determination on tumor tissues has revealed salivary-type amylase. However, few studies have managed to successfully establish a cell line or have examined the cytological, biochemical and biological features of the cell line.

Herein, we present an amylase-producing lung adenocarcinoma cell line carrying sialyl salivary-type amylase productivity and describe the ultrastructural, immunohistochemical and biochemical features. This cell line offers a useful tool for analyzing the pathogenesis and pathophysiology of amylase-producing lung cancers.

Patient and methods

Clinical course.

In August 2003, a 71-year-old man was admitted to our hospital suffering from exertional dyspnea. Physical examination revealed reduced respiratory sounds over the left lung field. Chest radiography and computed tomography (CT) indicated massive pleural effusion. Abdominal and neck CT, brain

magnetic resonance imaging (MRI), gastroscopy, colonoscopy, bone scintigraphy and otolaryngological examination revealed no evidence of abnormalities. Laboratory findings on admission were within normal limits, except for elevated amylase levels in serum (306 U/l) and urine (1065 U/l). Isotyping revealed that 90% of this amylase was salivary-type. Puncture of pleural effusion was performed on day 2 after admission. Cytological examination revealed adenocarcinoma cells. Primary lung adenocarcinoma was diagnosed based on subsequent immunohistochemical analysis, with positive results for thyroid transcription factor-1 (TTF-1), partial positive results for surfactant protein-A (SP-A) and carcinoembryonic antigen (CEA), and negative results for calretinin. Clinical stage was T4N0M0, stage IIIB. Chemotherapy was initiated, comprising 1 course of cisplatin (70 mg/m^2) and docetaxel (50 mg/m^2) on day 1, and 2 courses of gemcitabine (800 mg/m^2) and vinorelbine (20 mg/m^2) on days 1, 8 and 15. According to RECIST guidelines, clinical evaluation of response indicated stable disease of a non-measurable lesion. A decrease in serum and urinary amylase level correlated with disease stability, although serum CEA levels continuously increased (Figure 1). The patient suffered back pain due to bone metastasis as a result of being refractory to a third course of the second chemotherapy regimen, and received local irradiation for pain control. The patient selected palliative care and finally died in July 2004.

Cell culture.

Before chemotherapy, pleural effusion was obtained after informed consent

from the patient and following approval by the review board of our institute. Papanicolaou staining showed that the cells formed papillary clusters with high nucleus/cytoplasm (N/C) ratio, eccentrically placed nuclei, and prominent nucleoli (Figure 2). These features were compatible to adenocarcinoma. The cancer cells were isolated from the pleural effusion using a Ficoll-Hypaque gradient method (Pharmacia Biotech, Wikstroms, Sweden) and washed twice using AIM-V medium (13,14) (Invitrogen, Carlsbad, CA). Collected cells were suspended in AIM-V medium supplemented with 20% heat inactivated fetal bovine serum (Invitrogen) and cultured in a 25 cm^2 tissue culture flask (Becton Dickinson, Franklin Lakes, NJ) at 37 °C in a humidified atmosphere of air – 5% CO_2. Volume of the medium per flask was 10 ml. When the cultured cells became confluent, the cells were dispersed with 0.25 % trypsin solution (Invitrogen) and seeded in new flasks for passage. These procedures were serially performed until establishment of a cell line.

Immunohistochemistry.

Formaldehyde-fixed, paraffin-embedded cell blocks of primary cancer cells in pleural effusion and established cell line were prepared. Sections (4 μm thick) were stained using hematoxylin and eosin (HE). Immunohistochemical reactions were performed using streptavidin-biotin-peroxidase methods. Each slide was deparaffinized using xylene, rehydrated through a graded series of ethanol/water and treated in a pressure cooker for 2.5 min. Slides were immunostained using the Ventana NX automated immunohistochemistry system

(Ventana Japan, Yokohama, Japan). The automated protocol is based on an indirect biotinavidin system and uses a universal biotinylated immunoglobulin secondary antibody, diaminobenzidine substrate and hematoxylin counterstain. Primary antibodies used comprised mouse antibodies against TTF-1 (15,16) (clone; 8G7G3/1, DakoCytomation, Glostrup, Denmark), α-amylase (polyclone, Sigma-Aldrich, St. Louis, MO), surfactant protein A (SP-A) (17) (clone; PE10, DakoCytomation), CEA (clone: ZC23, Nichirei, Tokyo), and calretinin (18) (polyclone, Zymed Laboratories, San Francisco, CA).

Electron microscopy.

Cells were fixed overnight in 2% glutaraldehyde, postfixed in 2% osmium tetroxide and embedded in Epok 812 (Okenshoji, Tokyo, Japan). Sections were electron-stained using uranyl acetate and lead citrate. Grids were examined under a JEM-1011 transmission electron microscope (JEOL, Tokyo, Japan) and photographed at ×1500-15,000 magnification.

Determination of amylase levels in culture supernatant.

The cells cultured in a 25 cm^2 flask were dispersed with 0.25 % trypsin solution, suspended in AIM-V medium supplemented with 20% heat inactivated fetal bovine serum, and then seeded into each well of a 6-well tissue culture plate (Becton Dickinson) with titration of cell number and incubated for 60 hours. Volume of the medium per well was 3 ml. Culture supernatants were then harvested, filtrated through a 20-μm filter (ADVANTEC, Tokyo, Japan), and

subjected to blocked 6-N_3G_5CNP assay (19) using an chemistry analyzer (AU5421, Olympus, Tokyo, Japan) and electrophoresis using a cellulose acetate membrane as described before (20).

Neuraminidase treatment.

Neuraminidase (E.C. 3.2.1.18) from *Arthrobactor urefaciens* (Specificity: $\alpha 2 \rightarrow 3$, $\alpha 2 \rightarrow 6$, $\alpha 2 \rightarrow 8$) was purchased from Nakarai Chemicals (Kyoto, Japan). Culture supernatant was incubated with neuraminidase at 37 °C for 1 h, in accordance with the methods described by Sudo and Kanno (21).

High-performance liquid chromatography.

High-performance liquid chromatography (HPLC) was performed using an automated fast-protein liquid chromatography (FPLC) system (Pharmacia Biotech) with a Superose 12 column (30 cm × 1.0 cm internal diameter). Sample (200 μL) was injected and eluted with 150 mmol/L NaCl and 50 mmol/L phosphate buffer (pH 7.2). The volume of each fraction was 0.8 mL/tube. Protein was monitored at 280 nm, and amylase activity was determined using an amylase test kit (Toyobo, Osaka, Japan).

Results

Establishment of cell line.

Cancer cells started to grow steadily within 2 weeks and proliferated

consistently thereafter with an adherent style on a culture flask (Figure 3A). The cell line was designated as IMEC-2. This cell line has been stably maintained for more than 50 passages (more than 12 months) *in vitro*.

Cytological features of IMEC-2.

Cytological features of the cell line were then examined. HE staining of the cell line shown in Figure 3B demonstrated that basophilic cells with a high nucleus/cytoplasm (N/C) ratio forming an organoid structure resembling tubules or acini. Immunohistochemical analysis revealed that the cell line was positive for α-amylase in cytoplasm (Figure 3C) and TTF-1 in nuclei (Figure 3D). We could also detect a few cells which were SP-A-positive in cytoplasm (Figure 3E), but not the cells positive for CEA (Figure 3F).

Ultrastructural findings in IMEC-2.

Electron microscopy revealed that tumor cells possessed round vesicular nuclei with prominent nucleoli, while the apical surfaces of cells were lined with short microvilli (Figure 4A). Tight junctions were formed beneath the surfaces and desmosomal junctions were easily noted. In the cytoplasm, zymogen granule-like structures were observed, with a mean diameter of 280 nm (range, 200-400 nm; Figure 4B).

Sialyl salivary-type amylase production from IMEC-2.

Whether these cells secrete α-amylase was verified. Amylase levels in culture

supernatants were found to increase dependent on the number of cultivated cells in a well, as confirmed by blocked 6-N_3G_5CNP assay (Figure 5).

Isoamylase characterization of culture supernatant was performed using electrophoresis on cellulose acetate membrane. Abnormal bands were detected migrating toward the anode faster than the salivary isoamylase sub-band (S_2) (Figure 6A). This abnormal band was diminished on treatment with neuraminidase (Figure 6B), demonstrating that the amylase contains sialyl salivary-type amylase.

The elution profile was then examined to thoroughly confirm the amylase phenotype under HPLC analysis. An elution peak corresponding to normal amylase from a healthy subject was noted, with a corresponding fraction number of 29. In the sample obtained from culture supernatant of IMEC-2, amylase activity was eluted in a broad peak (Figure 7). This result verified that the amylase was sialylated, as suggested previously (22-24).

Discussion

We report herein the successful establishment of the IMEC-2, an amylase-producing lung adenocarcinoma cell line. So far, few reports have studied the mechanisms of production of amylase from lung adenocarcinoma cells. The reason for this is presumed that amylase-producing lung cancer is relatively rare [approximately 3 % in all types of lung cancer (25)], and the difficulty in establishing lung cancer cell lines (26) that allow repeated experiments. To date, only 1 cell line producing sufficient amounts of amylase

has been established (27). In addition, the present study offers the first demonstration of the sialylation of salivary-type amylase occurring independently in lung cancer cells, using an established cell line.

We have previously demonstrated that myeloma cells produce sialylated salivary-type amylase and this type of amylase activity may have important clinical implications (22-24). Conversely, Sudo *et al*. (21) showed that amylase in the sera of patients with amylase-producing lung cancers was also sialylated. Amylase secreted from amylase-producing lung cancers was also found to be sialylated through examination of the elution profile of amylase from tumor extracts using gel filtration methods (5). In addition to these studies, the present study provided the first direct evidence in an established cell line that sialylation of salivary-type amylase occurs in lung cancer cells. This was confirmed by neuraminidase sensitivity and protein elution profiles on HPLC analysis.

Various investigators have shown that increased sialylation in cell surface proteins represents a characteristic feature of cancer cells, particularly related to metastatic potential and invasiveness (28-30). Definition of the relationship between sialylation of amylase and clinical outcomes is anticipated. Moreover, our findings indicate that examining sialylation of amylase in sera of lung cancer patients with augmented amylase levels might be useful for early diagnosis of amylase-producing lung cancer.

The molecular biological mechanisms of ectopic amylase production from lung cancer cells have yet to be clearly elucidated. Using the cell line first generated by Izumi *et al.* (27) several authors have attempted to examine the

underlying molecular biological mechanisms of this phenomena. S1 mapping of amylase mRNAs using a probe that covered the 5' region of the first exon in the normal salivary amylase gene revealed the absence of tumor-specific amylase-activation mechanisms, including promoter insertion or fusion of 1 gene into another actively transcribed gene (31). They suggested that amylase-producing neoplastic tissues are formed from a founder cell that was itself an amylase producer, such as bronchial gland or ciliated epithelial cells (32). Conversely, Tomita *et al*. (33) discovered 2 novel transcripts of human endogenous retroviral long terminal repeat (LTR) sequences from mRNA in the same cancer cell line. However, precise location of the LTR sequences could not be identified, nor were the LTR sequences found to be associated with a promoter or enhancer of the amylase gene in the cell line. Under these circumstances, this newly established amylase-producing lung adenocarcinoma cell line, IMEC-2, might provide a useful tool not only for verifying studies, but also for clarifying novel genes and molecules responsible for amylase-production in lung cancer.

In the present case, chemotherapy resulted in reduced amylase levels in sera, whereas serum CEA levels continuously increased. The patient eventually became refractory to chemotherapy, although amylase levels were kept low. This clinical course indicates that chemotherapy was only effective against the CEA-negative amylase-positive cell phenotype, as was the established cell line. Given the clinical response of the patient against chemotherapy, whether amylase productivity of cells correlates with chemosensitivity is of interest.

Moreover, SP-A positive cells were seen among IMEC-2 cells, implying that alveolar type-II cells might represent a candidate for the founder cells forming the amylase-producing lung cancer.

In rat experimental models, amylase secretion from pancreatic acinar cells was regulated through EGFR down signaling which involves inositol triphosphate (IP_3) pathway when high concentration of EGF was added (34). In contrast, mutated *EGFR* gene mediates oncogenic effects by altering downstream signaling through differential phosphorylation of EGFR (35-38). However, mutations of *EGFR* gene responsive to gefitinib (35-37) or resistant T790M (39, 40) were not detected in IMEC-2. Also *KRAS* gene mutations, which are exclusively found in lung cancers with wild-type *EGFR* (41), were not identified (data not shown).

Though further work will be required to increase our understanding of the mechanisms of ectopic amylase production in the lung, this cell line will provide potential insight into the pathogenesis of amylase-producing lung cancer.

Acknowledgements

This study was supported by a Grant-in-Aid for Encouragement of Scientists, Japan Society for the Promotion of Science. We would like to thank Dr. Akio Hiraki (University of Texas Health Science Center) for technical advice on establishment of the cell line. We also appreciate the assistance of Takahito Hirota (SRL Hokkaido Corp.) in coordinating several assays.

References

1 Weiss MJ, Edmondson HA and Wertman M: Elevated serum amylase associated with bronchogenic carcinoma. Am J Clin Pathol *21*: 1057-1061, 1951.

2 Gomi K, Kameya T, Tsumuraya M Shimosato Y, Zeze F, Abe K *et al*: Ultrastructural, histochemical, and biochemical studies of two cases with amylase, ACTH, and β-MSH producing tumor. Cancer *38*: 1645-1654, 1976.

3 Yokohama M, Natsuizaka T, Ishii Y, Ohshima S, Kasagi A and Tateno S: Amylase-producing lung cancer: Ultrastructural and biochemical studies. Cancer *40*: 766-772, 1977.

4 Morohoshi T, Nakamura N, Hayashi K and Kanda M: Amylase producing lung cancer: Electronmicroscopical and biochemical studies. Virchows Arch A Path Anat and Histol *387*: 125-132, 1980.

5 Katayama S, Ikeuchi M, Kanazawa Y, Akanuma Y, Kosaka K, Takeuchi T *et al*: Amylase-producing lung cancer: Case report and review of the literature. Cancer *48*: 2499-2502, 1981.

6 Maeda M, Otsuki M, Hosai Y, Saeki S, Yamahashi T and Baba S: Salivary-type hyperamylasemia in primary lung cancer: Observation of a possible precursor of the salivary-type isoamylase. Eur J Cancer Clin Oncol *18*: 123-128, 1982.

7 Yoshida Y, Mori M, Sonoda T, Sakauchi F, Sugawara H and Suzuki A: Ultrastructural immunohistochemical and biochemical studies on

amylase and ACTH producing lung cancer. Virchows Arch Pathol Anat *408*: 163-172, 1985.

8 Tomita M, Matsuura N, Horii A, Emi M, Nishide T, Ogawa M *et al*: Expression of α-amylase in human lung cancers. Cancer Res *48*: 3292-3296, 1988.

9 Tsukawaki M, Izawa M, Yoshida M, Araki N, Hashiba Y, Nakagawa H *et al*: A case of amylase-producing lung cancer. Internal Med *31*: 60-63, 1992.

10 Yamamoto H, Ohta T, Kojima J, Abe T, Suzuki A and Fujioka Y: An amylase producing lung cancer with thrombocytosis: A case report. Gan no Rinshou (Jpn J Cancer Clin) *38*: 1487-1491, 1992 (in Japanese, Abstract in English).

11 Grove A: Amylase in lung carcinomas: An ultrastructural and immunohistochemical study of two adenocarcinomas, and a review of the literature. APMIS *102*: 135-144, 1994.

12 Lenler-Petersen P, Grove A, Brock A and Jelnes R: Alpha-amylase in resectable lung cancer. Eur Respir J *7*: 941-945, 1994.

13 Muul LM, Nason-Burchenal K, Hyatt C, Schwarz S, Slavin D, Director EP, *et al*: Studies of serum-free culture medium in the generation of lymphokine activated killer cells. J Immunol Methods *105*: 183-192, 1987.

14 Sadava D, and Castillo T: Growth of human small-cell lung cancer cells in AIM-V®, a serum-free medium. Focus 18: 59-60, 1996.

15 Ng WK, Chow JCY and Ng, PKH: Thyroid transcription factor-1 is highly sensitive and specific in differentiating metastatic pulmonary from extrapulmonary adenocarcinoma in effusion fluid cytology specimens. Cancer Cytopathol *96*: 43-48, 2002.

16 Stenhouse G, Fyfe N, King G and Kerr KM: Thyroid transcription factor 1 in pulmonary adenocarcinoma. J Clin Pathol *57*: 383-387, 2004.

17 Kuroki Y, Fukada Y, Takahashi H and Akino T: Monoclonal antibodies against human pulmonary surfactant apoproteins: specificity and application in immunoassay. Biochim Biophys Acta *836*: 201-209, 1985.

18 Ordonez NG: The immunohistochemical diagnosis of mesothelioma: a comparative study of epithelioid mesothelioma and lung adenocarcinoma. Am J Surg Pathol *27*: 1031-1051, 2003.

19 Henkel E, Morich S and Henkel R: 2-chloro-4-nitrophenyl-β-D-maltoheptaoside: A new substrate for the determination of α-amylase in serum and urine. J Clin Chem Clin Biochem *22*: 489-495, 1984.

20 Takeuchi T, Matsushima T, Sugimura T, Kozu T, Takeuchi T and Takemoto T: A rapid, new method for quantitative analysis of human amylase isozymes. Clin Chim Acta *54*: 137-144, 1974.

21 Sudo K and Kanno T: Properties of the amylase produced in carcinoma of the lung. Clin Chim Acta *73*: 1-12, 1976.

22 Moriyama T, Tozawa T, Yamashita H, Onodera S, Nobuoka M and Makino M: Separation and characterization of sialic acid-containing

salivary-type amylase from patient's sera with immunoglobulin A-type myeloma. J Chromatogr *571*: 61-72, 1991.

23 Moriyama T, Tozawa T, Nobuoka M and Ikeda H: Sialyl salivary-type amylasemia associated with immunoglobulin D-type multiple myeloma. Clin Chim Acta *233*: 127-134, 1995.

24 Shigemura M, Moriyama T, Endo T, Shibuya H, Suzuki H, Nishimura M *et al*: Myeloma cells produce sialyl salivary-type amylase. Clin Chem Lab Med *42*: 677-680, 2004.

25 Nakayama T. Amylase isoenzyme found in lung and ovarian cancers. In: Onco-developmental gene expression (Fishman WH and Sell S, eds). New York, Academic Press 1976, pp 455-462.

26 Sugaya M, Takenoyama M, Osaki T, Yasuda M, Nagashima A, Sugio K, *et al:* Establishment of 15 cancer cell lines from patients with lung cancer and the potential tools for immunotherapy. Chest *122*: 282-288, 2002.

27 Izumi T, Nagata Y, Okabe T, Sasaki K, Kitamura S, Kosaka K *et al*: A case report of amylase-producing lung cancer. Nippon Kyobu Rinsyo *40*: 210-214, 1981 (in Japanese).

28 Yogeeswaran G and Salk PL: Metastatic potential is positively correlated with cell surface sialylation of cultured murine tumor cell lines. Science *212*: 1514-1516, 1981.

29 Bolscher JG, Schallier DC, Smets LA, van Rooy H, collard JG, Bruyneel EA *et al*: Effect of cancer-related and drug-induced alterations in surface

carbohydrates on the invasive capacity of mouse and rat cells. Cancer Res *46*: 4080-4086, 1986.

30 Bresalier RS, Ho SB, Schoeppner HL, Kim YS, Sleisenger MH, Brodt P *et al*: Enhanced sialylation of mucin-associated carbohydrate structures in human colon cancer metastases. Gastroenterology *110*: 1354-1367, 1996.

31 Nakamura Y, Tomita N, Nishide T, Emi M, Horii A, Ogawa M *et al*: Production of salivary type α-amylase in human lung cancer. Gene *77*: 107-112, 1989.

32 Hayashi Y, Fukayama M, Koike M and Nakayama T: Amylase in human lungs and the female genital tract: histochemical and immunohistochemical localization. Histochemistry *85*: 491-496, 1986.

33 Tomita N, Horii A, Doi S, Yokouchi H, Ogawa M, Mori T *et al*: Transcription of human endogenous long terminal repeat (LTR) sequence in a lung cancer cell line. Biochem Biophys Res Comm *166*: 1-10, 1990.

34 Stryjek-Kaminska D, Piiper A, Stein J, Caspary WF and Zeuzem S: Epidermal growth factor receptor signaling in rat pancreatic acinar cells. Pancreas *10*: 274-280, 1995.

35 Paez JG, Janne PA, Lee JC, Tracy S, Greulich H, Gabriel S *et al*: EGFR mutations in lung cancer: correlation with clinical response to gefitinib therapy. Science (Wash DC) *304*: 1497-1500, 2004.

36 Lynch TJ, Bell DW, Sordella R, Gurubhagavatula S, Okimoto RA,

Brannigan BW *et al*: Activating mutations in the epidermal growth factor receptor underlying responsiveness of non-small-cell lung cancer to gefitinib. N Engl J Med *350*: 2129-2139, 2004.

37 Pao W, Miller V, Zakowski M, Doherty J, Politi K, Sarkaria I *et al*: EGF receptor gene mutations are common in lung cancers from “never smokers” and are associated with sensitivity of tumors to gefitinib and erlotinib. Proc Natl Acad Sci USA *101*: 13306-13311, 2004 .

38 Sordella R, Bell DW, Haber DA and Settleman J: Gefitinib-sensitizing *EGFR* mutations in lung cancer activate anti-apoptotic pathways. Science *305*: 1163-1167, 2004.

39 Kobayashi S, Boggon TJ, Dayaram T, Janne PA, Kocher O, Meyerson M *et al*: EGFR mutation and resistance of non-small-cell lung cancer to gefitinib. N Engl J Med *352*: 786-792, 2005.

40 Pao W, Miller VA, Politi KA, Riely GJ, Somwar R, Zakowski MF *et al*: Acquired resistance of lung adenocarcinoma to gefitinib or erlotinib is associated with a second mutation in the EGFR kinase domain. PLos Med *2*: 1-11, 2005.

41 Kosaka T, Yatabe Y, Endoh H, Kuwano H, Takahashi T and Mitsudomi T: Mutations of the epidermal growth factor receptor gene in lung cancer: biological and clinical implications. Cancer Res *64*: 8919-8923, 2004.

Figure legends

Figure 1. Clinical course of the patient. A decrease in serum and urinary

amylase level correlated with initiation of chemotherapies, although serum CEA levels continuously increased. s-Amy, serum amylase; u-Amy, urinary amylase; CDDP, cisplatin; TXT, docetaxel; GEM, gemcitabine; VNR, vinorelbine.

Figure 2. Cytology of the primary cells in pleural effusion (Papanicolaou stain, A: ×100, B: ×400)

Figure 3. Cytological features of the established IMEC-2 cell line. A) Microscopic findings in culture flask; B-F), cell block stained using HE (B), α-amylase (C), TTF-1 (D), SP-A (E) and CEA (F) (×200).

Figure 4. Electron microscopic findings in IMEC-2. A) Nucleus (N), and microvilli (arrow) (×1500). B) Nucleus (N), tight junctions (arrow), desmosomal junctions (arrowhead), and zymogen-like granules (G) (×15,000).

Figure 5. Amylase production from culture supernatant of IMEC-2 dependent on the number of cultivated cells by blocked 6-N_3G_5CNP assay. Each point and bar represents the mean ±SD from triplicates.

Figure 6. Isoamylase electrophoretic characterization of culture supernatant from IMEC-2 on cellulose acetate membrane. Amylase activity was detected using the blue starch staining technique. A) 1, control serum amylase from healthy subject; 2, denatured control serum amylase from healthy subject; 3,

culture medium from IMEC-2. Fast-migrating isoamylase (arrows) was observed in lane 3. B) Electrophoresis on cellulose acetate membrane of isoamylase from culture supernatant of IMEC-2 after neuraminidase treatment. 1, control serum from healthy subject; 2, culture supernatant of IMEC-2; 3, culture supernatant of IMEC-2 treated with neuraminidase; 4, sialyl salivary-type amylase from amylase-producing myeloma (22); 5, sialyl salivary-type amylase from amylase-producing myeloma treated using neuraminidase (22). Fast-migrating isoamylase (arrows) was observed in lanes 2 and 4. Abnormal isoamylases showed electrophoretically reduced mobility to the cathodic side on the treatment with neuraminidase.

Figure 7. Elution profile of amylase in culture medium from IMEC-2 by HPLC using a Superose 12 column. Protein was monitored at 280 nm, and amylase activity was determined using an amylase test kit. (solid line) Normal human serum protein; (closed circle) elution profile of amylase in culture medium from IMEC-2; (open circle) elution profile of amylase in control serum from healthy subject. A small notch (arrow) was observed in the elution peak of culture medium from IMEC-2, which demonstrates sialyl salivary-type amylase.

Figure 1 Yokouchi et al.

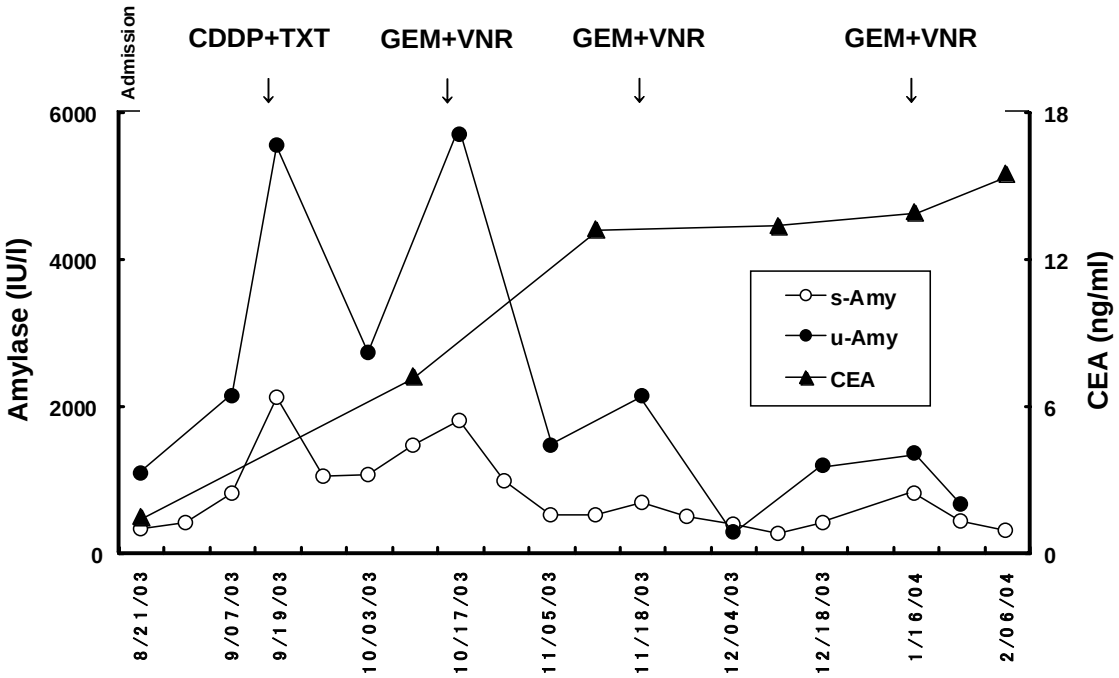

Figure 2

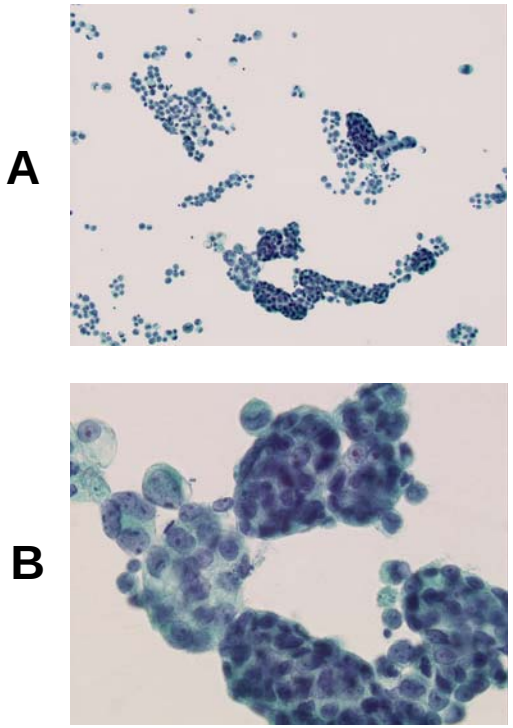

Figure 3

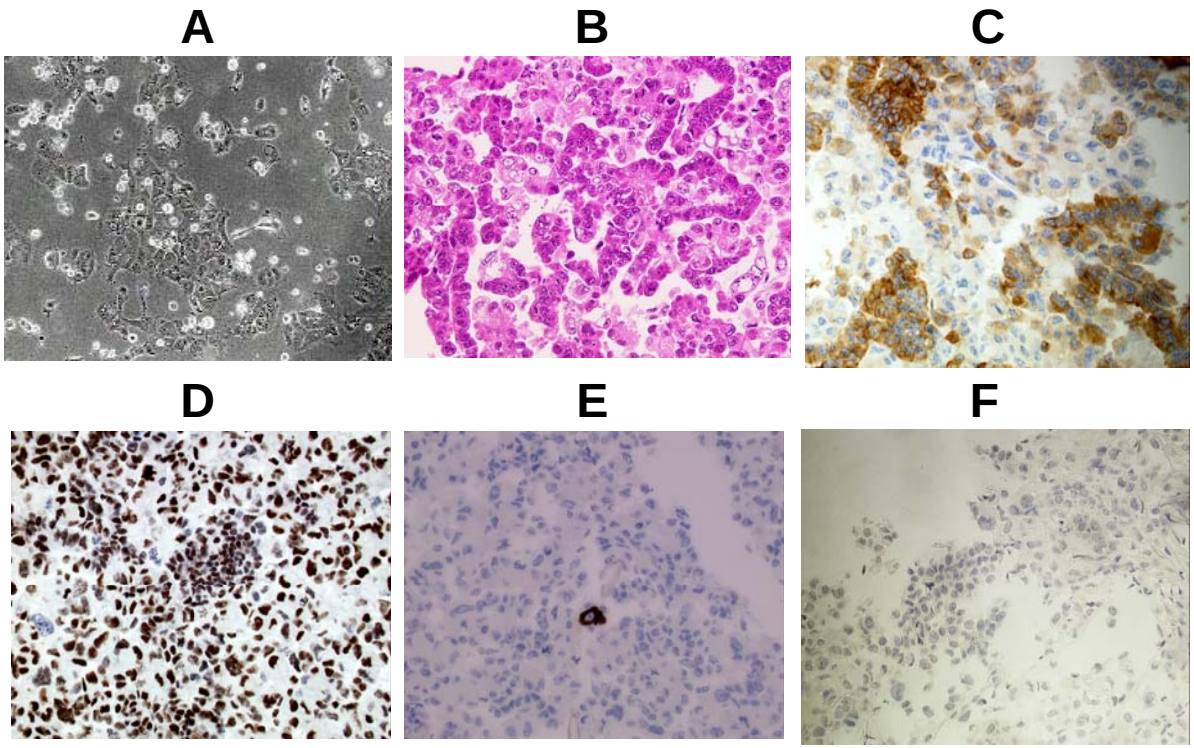

Figure 4

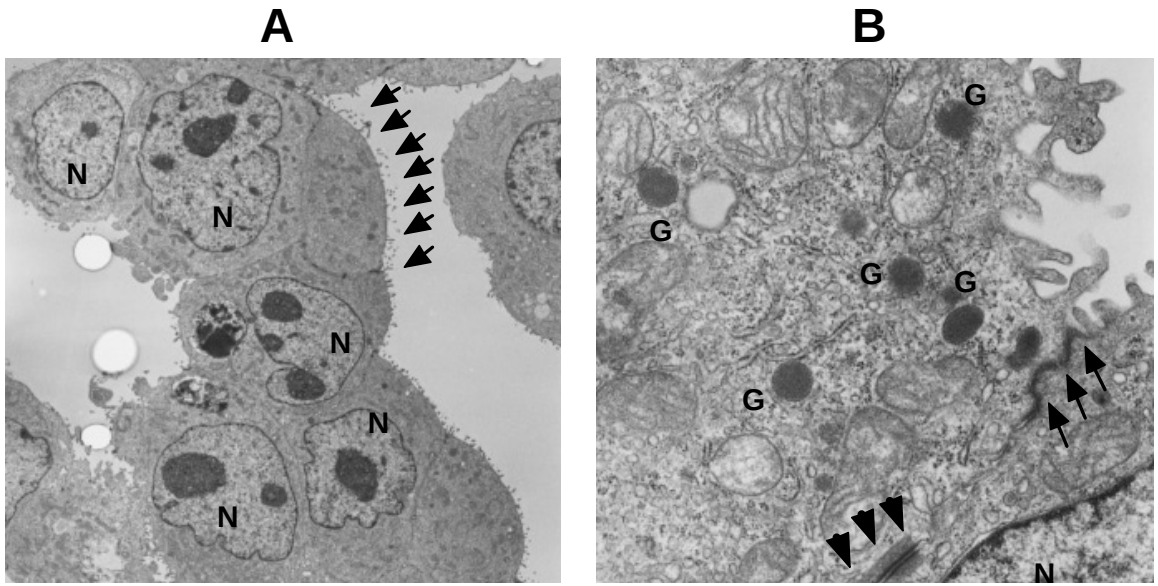

Figure 5

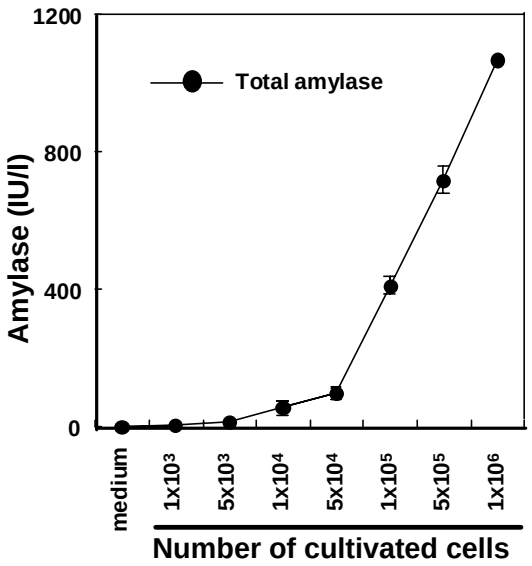
1200
800
400
0
Amylase (IU/l)
Total amylase
medium
1x10³
5x10³
1x10⁴
5x10⁴
1x10⁵
5x10⁵
1x10⁶
Number of cultivated cells



Figure 6

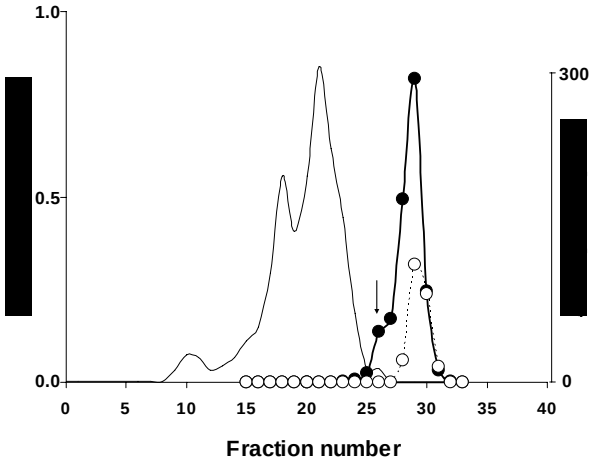

Figure 7