



HOKKAIDO UNIVERSITY

Title	ON A CASE OF EPILEPSY IN A LION
Author(s)	OHBAYASHI, Masashi; FUJIMOTO, Yutaka
Citation	Japanese Journal of Veterinary Research, 2(1), 11-20
Issue Date	1954-03-30
DOI	https://doi.org/10.14943/jjvr.2.1.11
Doc URL	https://hdl.handle.net/2115/1651
Type	departmental bulletin paper
File Information	KJ00002372864.pdf



ON A CASE OF EPILEPSY IN A LION

Masashi OHBAYASHI and Yutaka FUJIMOTO

*Laboratory of Veterinary Pathology, Faculty of
Veterinary Medicine, Hokkaido University,
Sapporo, Japan*

(Received for Publication, March 12, 1954)

I. PREFACE

The authors investigated pathologically a case of male lion with anamnesis of epileptic fits. Multiple focal lesions distributed mainly in subcortical cerebral white matter and in inner layer of cerebral cortex were even macroscopically visible; through neurohistological studies the lesions were identified as sclerotic foci made up of fibrous astrocytes remarkably proliferated successively in the loci of cerebral focal hemorrhages.

It is needless to call attention to the fact that the repairing process of ecto- and mesodermal origin occurs in the hemorrhagic focus of nervous tissue and finally the sclerotic focus of the hemorrhages occurs.

Any case like the present one cannot be found in veterinary literature and it is true that chances of sufficient pathological investigation upon the nervous disease of domestic animals are scarce in spite of the unexpectedly frequent occurrence of such diseases. The authors, therefore, describe the case in this report with much interest for the purpose of the accumulation of precious data.

II. METHODS

The case was autopsied 24 hours after the death. The materials of viscera for histological examination were fixed in 10% formalin, embedded in paraffin and the sections were stained with hematoxylin-eosin.

Macroscopical lesions of the brain, after formalin fixation, were carefully examined on frontal cut surfaces at about 5 mm intervals. Histological investigation of the brain was carried out on many sections including such as frontal, parietal, temporal and occipital lobe, *corpus striatum*, interbrain, midbrain, *pons*, *medulla oblongata* and *cerebellum*. Various staining methods indispensable for neuropathological investigations were applied on the sections; hematoxylin-eosin stain, v. GIESON stain for collagen fiber, WEIGERT stain for elastic fiber, WEIGERT'S fibrin stain, MALLORY'S fuchsin stain, PERLS'S Berlin blue reaction, OKA'S modification of

BIELSCHOWSKY'S silver impregnation for argyrophile fiber, Sudan III stain, SPIELMEYER stain for myelin sheath, HOLZER'S glia stain, CAJAL'S silver impregnation method for glial fiber and BIELSCHOWSKY'S silver impregnation method for neurofibrile.

III. DESCRIPTIONS

1. Clinical Symptoms

A male lion, estimated to be 10 years old, was transferred to Sapporo Zoo in October 1952 and was kept there until June 28th, 1953, when the animal died at 10 a. m. During the time kept in the zoo, the animal manifested four fits of epileptic type such as convulsion, inversion, unconsciousness etc., and the symptoms always recovered in a short time. The animal died in the last fit.

2. Macroscopical Changes

Autopsy number P. 3409, post mortem about 24 hours. A carcass of lion, male, not emaciated, weighed approximately 170 kg. *Rigor mortis* was observable on all extremities, smooth and wet conjunctivae, relaxed and slightly clouded cornea. Buccal mucous membrane in normal, reddish fluid leaked through nostrils, subcutaneous tissues slightly exsiccated, no lesions on fat and muscles.

Peritoneal fluid was slightly increased and reddish, peritoneum had no sign of abnormality. Blood vessels of large omentum dilated and congested. Spleen weighed 750 g, margin dull, cut surfaces convexed and glazed, blood content of parenchyma increased and with distinctive trabeculae and follicles. Liver, 3600 g, was subcapsularly congested, fibrinous membranes on the diaphragmatic surface, blood content increased on cut surfaces, and congested parenchyma. Mucous membrane of cholecyst was congested. Pancreas weighed 120 g. Mesenterium was congested and some of mesenteric lymph nodes showed cyst-formation. Congested medulla of suprarenal glands and thin cortex. Kidneys weighed 450 g respectively, thick and fibrous capsules, subcapsular blood vessels ramiformly congested, elastic consistency, and glomerular hyperemia on cut surfaces. Renal pelvis in normal. Pigeon-egg size testicles and slightly increased interstitial connective tissue. Poor content in stomach, serosa congested and mucosa was anemic with sporadic grayish white miliary nodules. As to the changes of small intestine; poor content, brownish feces in ileum, in serous and mucous membranes no pathological changes. Large intestine in normal. Thoracic fluid was slightly increased and reddish. Pleura was normal. Oesophagus showed ramiform hyperemia of mucosa. Content of pericardium was reddish, watery and slight. Heart showed subepicardiac congestion, large amount of tar-like blood clots in the right ventricle and auricle, discovered about 10 *Dirofilaria*-worms from the right ventricle to pulmonary artery, no sign of pathological symptoms in endocardium and valves, myocardium congested and its elasticity decreased. Lungs were rich in air content, pleura in normal, slight anthracosis of parenchyma, small amount of reddish viscid mucus in bronchial

lumina, and pulmonary arteries contained liquid blood. Pulmonary hilus lymph nodes were thumbhead-size and slightly anthracotic.

Tongue showed hyperemia on the mucosa of its root. Tonsils in normal. Laryngo-pharyngeal mucous membranes congested.

The brain, weighed 300 g, had marked macroscopical changes. The lateral ventricles dilated with increased transparent cerebrospinal fluid. Multiple small focal lesions could be observed by making many frontal cut surfaces at about 5 mm intervals after formalin fixation. The foci were yellowish-brown or reddish-brown in colour, more indurative than the peripheral normal tissue and their size ranged from that of poppy seed to rice grain, and sometimes showed the appearance of ring hemorrhage. The foci were almost always clearly demarcated, mainly distributed in subcortical white matter or inner layer of cortex of cerebral hemispheres, and were found diffusely in the area from frontal to occipital lobe and also in *hypothalamus*, but no lesions confirmed in midbrain, *pons*, *medulla oblongata* and *cerebellum*. Total number of the foci was more than twenty. The foci were more densely found in the dorsal part than the ventral.

3. Histological Changes of Viscera

Liver congested, slight fatty infiltration of hepatic cells was observed, lymphocytic cell accumulation was sometimes notable and the arteriole in the GLISSON'S sheath manifested hyaline change of its wall. Spleen remarkably congested and edematous and follicles persisted sporadically. Kidney showed obvious glomerular congestion, detected small lymphocytic accumulations in interstitium, renal tubules showed fatty infiltration and walls of the BOWMAN'S capsule were generally thick. Myocardium remarkably congested and interstitial small cell accumulation scarcely observed. Lung slightly anthracotic. Suprarenal gland showed marked congestion, especially in medullar tissue. Pancreas and tonsil congested. In mandibular lymph node, slight anthracosis, follicular lymphocytic hyperplasia, increase of plasma cells in medullary cords and cortex were found and lymphatic stasis also noteworthy. Changes of gastric lymph node were in general similar to mandibular, although accumulations of plasma cells and eosinophile leucocytes were discovered in capsule and trabeculae; that were parasitic foci. Mesenteric lymph node was congested with partial hemorrhage and high grade of lymphatic stasis. Pulmonary hilus lymph node showed slight anthracosis and focal cortical hyaline changes. Remarkable lymphatic stasis in lienal lymph node. Tongue manifested submucous congestion. Vascular dilatation detected in the wall of oesophagus. Stomach showed generally marked congestion and parasitic nodule with plasma cells and eosinophile leucocytes was detectable in *tunica propria* and submucosa. Severe post-mortem changes in small and large intestine: in the former a parasitic focus, and hyperplasia of lymphatic apparatus in the latter. In aorta and skeletal muscle no sign of abnormality. Increased interstitium of testicle with normal spermatogenesis.

4. Histological Changes of Brain

(In the descriptions, R indicates right side, L left side and the number indicates

the number of cut surface).

Lobus frontalis (L-3). Both arteries and veins in leptomeninges and cerebral parenchyma were dilatate, edematous and thick leptomeninges with slight loose lymphocyte accumulations which showed perivascular type around a few vessels of sulci. Lymphocytes and eosinophile leucocytes in blood vessels dominantly and some vessels in nervous tissue manifested edematous thickening of adventitia slight lympho- and siderocytic cell accumulation and dilatation of the VIRCHOW-ROBIN'S space.

Lobus frontalis (L-4). A round demarcated sclerotic focus found near to *sulcus rhinalis nasalis*. The focus situated from molecular to pyramidal cell layer of cortex, its center showed reticulate structure of connective tissue with numerous siderocytes and blood vessels in the focus were hyperplastic associated with wall thickening. In nervous parenchyma of the focus, glial cells with large light nucleus of spherical form and abundant protoplasm were increased and siderocytes were observed among these glial cells. Perifocally, thickening of blood vessels with small number of siderocytes was detected.

Corpus striatum (L-5). General conditions were similar to those of section L-3. A sclerotic round focus which was clearly demarcated was observed in the middle of pyramidal cell layer of *gyrus ectosylvius*. The focus made up of vascular hyperplasia and conspicuous siderocyte accumulation, perifocal tissue was a layer of homogeneous glial substance with poor nuclei and glial cells proliferated in outer zone of the homogeneous layer. Blood vessels near to the focus were accompanied by cellular accumulation. An extraordinary dilatation of lymphatic space, in which blood vessels with lymphocytes and macrophages rich in vacuoles were observable, was detected in white matter.

Lobus parietalis and interbrain (L-9). Thickening, vascular dilatation and loose, perivascular lymphocytic accumulation observed in leptomeninges, and calcareous globule in arachnoideal membrane. In leptomeninges of *sulcus hippocampi* and *nucleus medialis thalami* fresh hemorrhages were seen. Wall thickening, adventitial edema and appearance of siderocytes were visible in *thalamus opticus* and slight glial activity detectable perivascularly. The similar vascular changes of a few vessels were also noted in *hippocampus*. A sclerotic focus was discovered in sub-cortical white matter of *gyrus ectosylvius*; it was composed of thick-wall blood vessels, proliferated reticulate connective tissue and accumulated siderocytes. The focus was encircled by rather homogeneous glial layer; connective tissue which proliferated reticulately in the focal center passed through the glial layer outwards and vascular and parenchymatous siderocytic cell accumulations were demonstrated perifocally. In and out the focus, proliferation of glial cells was remarkable and amyloid bodies also were sporadically observed. An irregularly demarcated focus, in which dense proliferation of glial cells was detected at *nucleus hypothalamicus* and siderocytes were sporadically identified in the focus. Hyaline blood vessels with siderocyte accumulation were increased in the focus and reticulate structure of increased argyrophile fibers were identified in this area on the silver impregnated

section.

Lobus parietalis (L-10). A focus made up of reticulate tissue of proliferated blood vessels and collagen fibers with numerous siderocytes occupied the area which extended from inner cortex to white matter of *gyrus entolateralis*. The focus, on section stained for myelin sheath, could be definitely described as a clearly demarcated demyelinating focus in which several myelin sheaths were barely detectable. Fatty granules were contained within the protoplasm of siderocyte. Through the staining methods after both CAJAL and HOLZER, vigorous proliferation of CAJAL'S glial cells were identified. From peripheral to outer zone of the focus, CAJAL'S glial cells with abundant protoplasm and its projections were increased disorderly and resulted in anisomorphic gliosis. Axis cylinders rarely persisting at peripheral part of the focus frequently showed degeneration such as fusiform inflation and others. Perivascular lymphocyte accumulation attracted the attention in and out of the focus and extrafocal normal blood vessels were also accompanied by some macrophages with fat substance perivascularly. Three foci which had already become cystic were discovered in *gyrus cinguli*; its walls were homogeneous glial tissue interspersed with glial cells possessing giant nuclei and abundant protoplasm; vasculo-fibrous reticular tissues with remarkable siderocytes were enveloped in the center of the focus.

Lobus occipitalis (L-13). Perivascular cell accumulations composed of sidero- and lymphocytes were found around small and middle size blood vessels of meninges and cerebral substance. Three calcareous globules existed in meninges. A spherical demyelinated focus was revealed in white matter of *gyrus marginalis* and the focus showed a serious gliosis with siderocytes. Intrafocal blood vessels, of which the walls were thickened, were surrounded by siderocytes perivascularly and by macrophages which rarely phagocytosed fatty granules.

Lobus frontalis (R-3). On periphery of small and middle blood vessels in white matter, loose accumulations of lympho- and siderocytes were observed. Some calcareous globules were detected in leptomeninges.

Corpus striatum (R-5). General pathological conditions were similar to those in other areas. A sclerotic focus was localized in the area from cerebral cortex to white matter of *gyrus ectosylvius* and *gyrus cinguli* respectively. Glial cell proliferations were remarkable in the foci, perivascular sidero- and lymphocyte accumulations were revealed. Also, at the central part of the focus made up by proliferation of blood vessels, a high degree of cellular accumulation was detected. The regional cerebral cortex was atrophic, its surface was concurved and glial cells were present in large number. Blood vessels leading to the focus of *gyrus ectosylvius* were surrounded by cellular element and the VIRCHOW-ROBIN'S space dilated cystically. Subependymal glial cells were increased.

Corpus striatum (R-7). General changes were the same as the above. In cerebral nuclei, especially in *putamen*, vascular changes such as wall thickening, lymph space dilatation and perivascular cellular accumulation were rather frequent. Severe lymphocyte accumulations were observed on a few blood vessels in white

matter of *gyrus ectosylvius*.

Lobus parietalis (R-9). Two calcareous globules were noted in leptomeninges. A pathological focus not clearly demarcated was discovered in area from the deep layer of cerebral cortex to white matter of *gyrus ectosylvius*. Proliferated blood vessels and reticulation of entangled delicate argyrophile fibers were discovered in the focus. Thickening of vascular wall was indefinite and there were serious accumulations of lymphocytes and siderocytes around the blood vessels. In the focus, abundant CAJAL's glial cells above described proliferated, siderocytes and fat granule cells appeared and some HORTEGA's glial cells of various types were observed among them. Regressive changes of nerve cells were not very severe and some shadowy figures of nerve cells were scattered in the focus.

Lobus parietalis and interbrain (R-13). General conditions were the same as in the above areas.

Lobus occipitalis (R-16). A sclerotic focus was revealed in subcortical white matter; the focus was encircled by a glial covering layer accompanied with conspicuously proliferated glial cells; noticeable siderocyte accumulations were observed in the intrafocal vasculoplastic part.

Cerebellum. Leptomeninges showed edematous thickening and lymphocytes slightly infiltrated there. In cerebellar white matter, especially in medullary lamellae, thickening of blood vessels and slight appearance of macrophages were noted.

Midbrain. Leptomeninges of *corpora quadrigemina* was infiltrated by polymorphonuclear leucocytes locally and a calcareous globule was detected in another part. Aqueductus dilated and subependymal glial cells were increased.

Pons. Meningeal and vascular thickenings were observed.

Medulla oblongata. Blood vessels of leptomeninges greatly dilated associated with edematous thickening and perivascular lymphocyte accumulations; focal macrophage accumulations were somewhat noticeable. The blood vessels near to ventricular basis showed adventitial hyaline thickening, dilatation of the VIRCHOW-ROBIN's spaces and slight marginal gliosis.

IV. SUMMARY OF DESCRIPTIONS

As for the changes of viscera except the central nervous system, there were observed congestion of parenchymatous organs, anthracosis of the lungs and pulmonary hilus lymph nodes, dirofilariosis of the heart and formation of parasitic nodular foci in the walls of digestive tracts and lymph nodes in abdominal cavity. Same changes macroscopically demonstrated were identified by microscopical examinations of abdominal and thoracic viscera.

The brain, on the contrary, showed marked macroscopical changes. At the time of autopsy, the lateral ventricles were dilated with in-

creased fluid. Multiple focal small lesions could be found through careful examination after formalin fixation.

It was clarified by microscopy that macroscopical focal colouration, which was presumable as the persisting hemorrhagic focus, was due to the accumulation of macrophages with hemosiderin pigments. The focus manifested a scarred change; blood vessels, adventitial fibrous elements and macrophages, which are the mesodermal element, and the CAJAL's glial cells, which are the ectodermal element, proliferated and formed a sclerotic focus or glio-mesodermal scar. In most of the foci, blood vessels, collagen fibers and argyrophile fibers proliferated reticulately accompanied by numerous siderocytes. Large glial cells with light nucleus, abundant protoplasm and marked projections were increased in the mesh, and formed the foci of anisomorphic gliosis. CAJAL's impregnation method revealed abundant glial fibers in the foci. Demyelination was also remarkable in the foci. In and out of the focus, perivascular lymphocytic cell accumulations were observed, and blood vessels leading to the focus were often infiltrated by some siderocytes. Through the more detailed investigation it was, as expectable, proved that there were some foci of different histological stages among the foci. In the more scarred focus, glial tissue became a more homogeneous and stratified cluster in the central limited area. The focus became more clearly demarcated than in the usual state and the regional cerebral cortex showed atrophy also. The focus, finally, progressed until a cystic structure was constructed by the glial wall and vascular cluster with siderocytes in the center. In the more fresh focus it was less clearly demarcated and HORTEGA glial cells and gitter cells were scattered in the meshes of reticulately proliferated vascular fibrous structures together with CAJAL's glial cells. Fat granules were also confirmed in mesodermal pigment cells. A small number of nerve cells, myelin sheaths and axis cylinders were demonstrated in such focus.

In the meninges which were edematous and thickened, slight lymphocyte infiltration was observed and perivascular lymphocytic cell accumulation was often present in sulci. Wall of blood vessels in the nervous tissue and also in the meninges frequently showed thickening. Fibrous thickenings were confirmable in the adventitia of blood vessels which were occasionally attacked with hyaline changes of the wall; lymphocytes and macrophages with fat and pigment granules were demonstrated in the adventitia. The VIRCHOW-ROBIN's spaces were

generally dilated and in the brain stem, especially *medulla oblongata*, glial cell increase of considerable degree could be found around the thickened vessel.

V. DISCUSSION

Due to the insufficiency of detailed clinical data, it is regrettable that the authors were unable to comprehend fully the characters of the symptoms, but the animal seemed to have repeatedly manifested epileptic fits at other raising place before removal to Sapporo Zoo. The animal, therefore, was observed with great interest by the persons concerned in a search for the cause which would provoke such remarkable clinical symptoms.

It is a well-known fact that a glio-mesodermal scar of hemorrhagic or malactic focus in the nervous tissue has persisted even for years as a coloured focus. The fact that various histological stages of the focal lesions, such as from the comparatively fresh to the scarred, were discovered in the present case, is a matter of much interest. The authors consider that the focal lesions of same characters were provoked here and there in the cerebral tissue of the animal before death, and the epileptic fits were manifested at the time the foci occurred.

That hemorrhage played an important role in genesis of the lesion is easily presumed by the constant presence of numerous siderocytes. It requires careful consideration to conclude whether the lesions of this case are ascribable to simple hemorrhage or regressive change with hemorrhage. However, the authors consider that remarkable focal demyelination, degeneration of axis cylinders, accumulation of the gitter cells and mobilization of the microglia cells in the comparatively fresh focus indicate that the lesions had manifested primarily regressive changes of nervous tissue. Therefore it is considered reasonable to ascribe the lesions to degeneration of the nervous parenchyma with hemorrhagic tendency.

As to the causal genesis, in as much as the foci had been formed apparently at intervals during long time, the authors consider that the cause had affected the nervous tissue continuously and this deterioration had, at some definite time, caused the focal lesions to arise under certain conditions. The circulatory disturbances in meninges and cerebral substances confirmed morphologically as described above are spe-

cially worthy of attention in these circumstances. Among them the vascular lesions are incomprehensible as senile changes; the authors consider that chronic lymphatic congestion, so as to bring about dilatation of the lateral ventricles, had played a main role.

The authors critically compared the case, for the purpose of differential diagnosis, with the diseases characterized by hemorrhages or degeneration of the nervous tissues, such as "mouldy corn disease" of horse in U. S. A. by SCHWARTE et al. (1937), "encephalomalacia" in various domestic animals, especially with that of sheep and horses reported by YAMAGIWA and TAJIMA (1952), and human "multiple sclerosis". However, the lesions observed in these diseases were absolutely different from the authors' case in the character, distribution and extent of the lesions.

"Epilepsy" is a clinical term and quite various pathological changes can be found in various diseases clinically manifesting the epileptic symptoms. Epilepsy is usually, in human medicine, divided into two groups "genuine or idiopathic epilepsy" and "symptomatic epilepsy". As to the pathological findings of the former, sclerotic foci of *hippocampus* and marginal gliosis of cerebral cortex, as the chronic changes, and focal necrosis of the nervous tissue due to local functional disturbances of blood circulation, as the acute changes, are chiefly mentioned. Pertaining to the histopathology of the latter, on the other hand, various neurological lesions are demonstrated in the cases of infectious disease, intoxication, tumour, parasitosis, trauma, senile changes, embryonal or infantile encephalitis etc. The authors, therefore, are able to conclude that the case described in this report should be categorized to symptomatic epilepsy.

VI. CONCLUSIONS

The authors investigated a case of male lion, approximately 10 years old which manifested epileptic fits before death, and obtained neuropathologically some interesting results.

Aside from the brain conditions, severe visceral congestion was observed.

The brain, macroscopically, showed marked dilatation of the lateral ventricles, multiple presence of sclerotic coloured foci, from yellowish-brown to reddish-brown in colour, mainly distributed in subcortical white matter and inner layer of cerebral cortex.

Histologically, the lesions chiefly belonged to the scarred hemorrhage and were made up of reticulately proliferated blood vessels and fibrous element in the center accompanied by numerous siderocytes, and characterized by demyelination and remarkable proliferation of fibrous astrocytes. Comparatively fresh focus was also confirmed.

As to the morphogenesis, the lesions began with parenchymatous focal necrosis with hemorrhage, and chronic lymphatic congestion played an important role as the cause.

Histological changes explained the clinical symptoms.

The case should be categorized to the symptomatic epilepsy considering the character of lesions.

LITERATURES

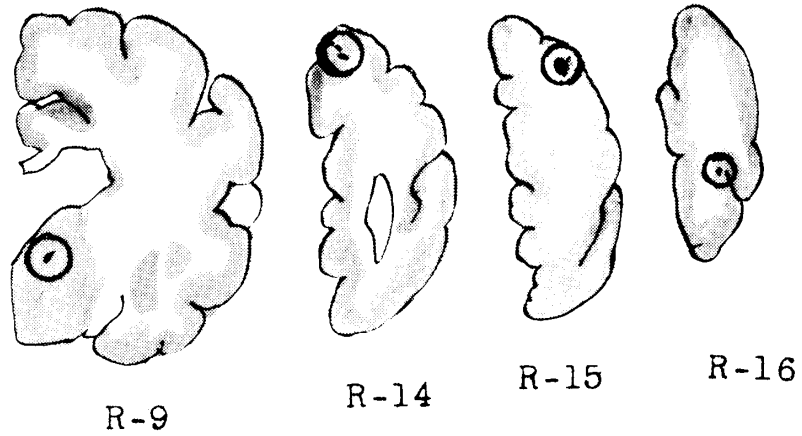
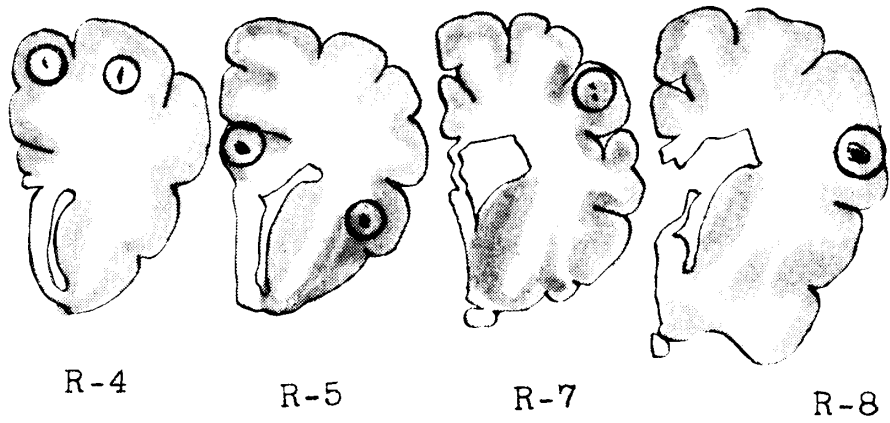
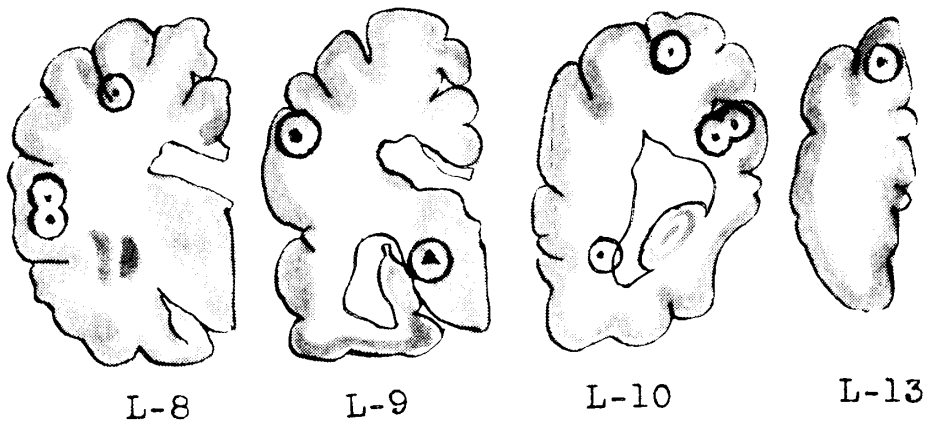
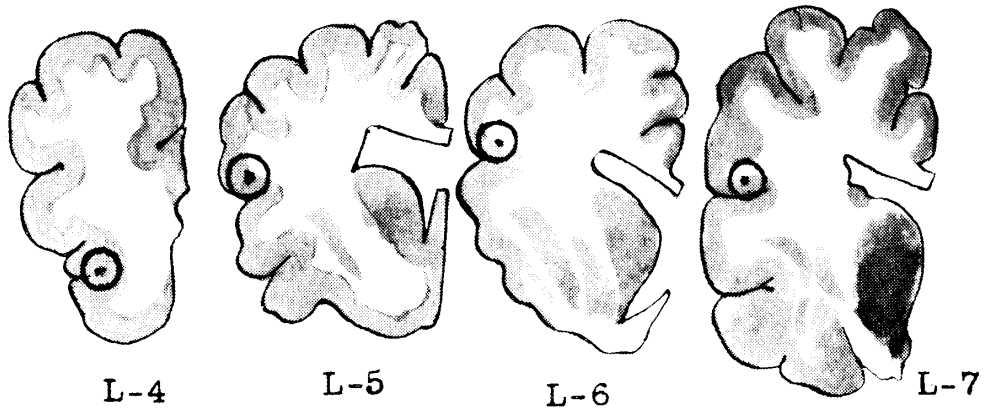
- 1) SCHWARTE, L. H. et al. (1937): *J. Amer. Vet. Med. Ass.*, **90**, 76.
- 2) SPIELMEYER, W. (1930): *Handb. Geisteskr.*, Bd. XI, Springer, Berlin.
- 3) YAMAGIWA, S. u. M. TAJIMA (1952): *Mem. Fac. Agr. Hokkaido Univ.*, **1**, 145 (Jap. with German abstract)

EXPLANATION OF PLATES

Plate I. Distribution of the focal lesions. The foci are encircled. L indicates left side, R right side and the number indicates the number of cut surfaces.

Plate II.

- Fig. 1.** R-5. A sclerotic focus with peripheral layer of the glial tissue and central mesodermal proliferation with siderocytes. Hematoxylin and eosin. $\times 80$.
- Fig. 2.** L-10. Proliferation of the argyrophile fibers in the focus. BIELSCHOWSKY'S silver impregnation. $\times 80$.
- Fig. 3.** L-10. Remarkable increase of the fibrous astrocytes of the focus. CAJAL'S glia stain. $\times 160$.
- Fig. 4.** L-10. Persisting degenerated axis cylinder in the focus. BIELSCHOWSKY'S silver impregnation for neurofibrile. $\times 320$.



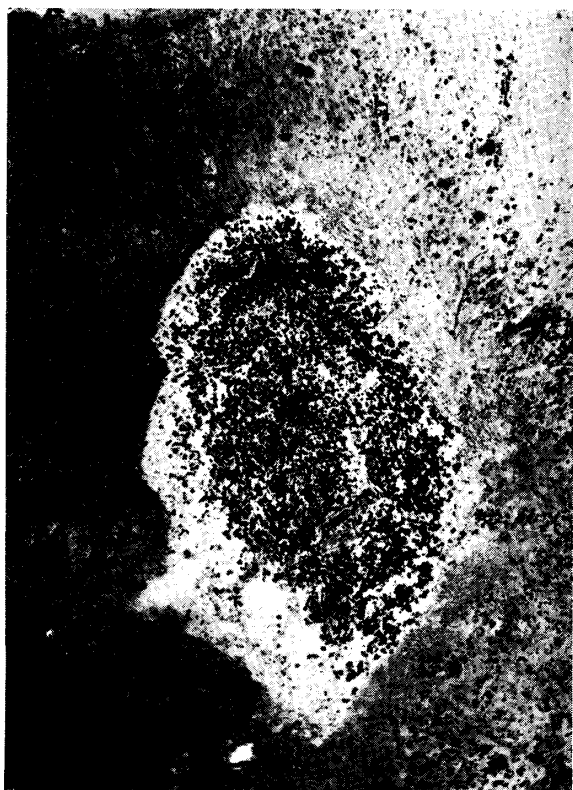


Fig. 1.

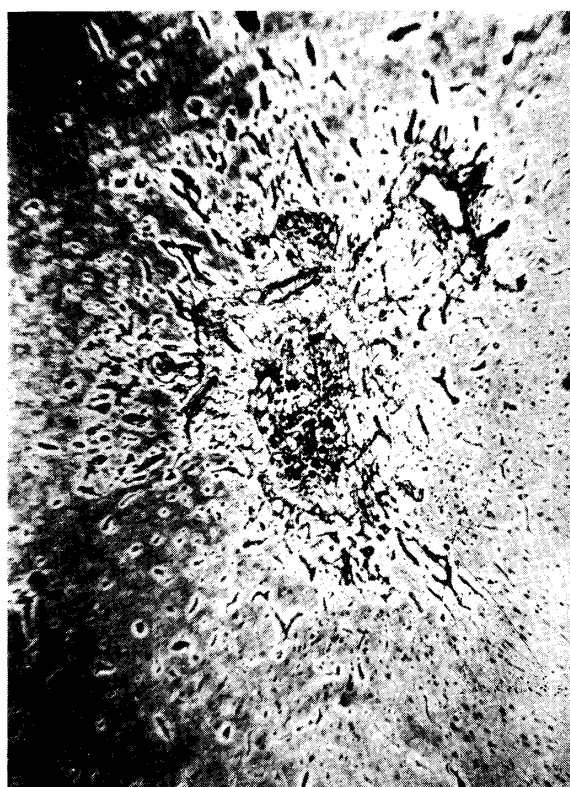

Fig. 2.

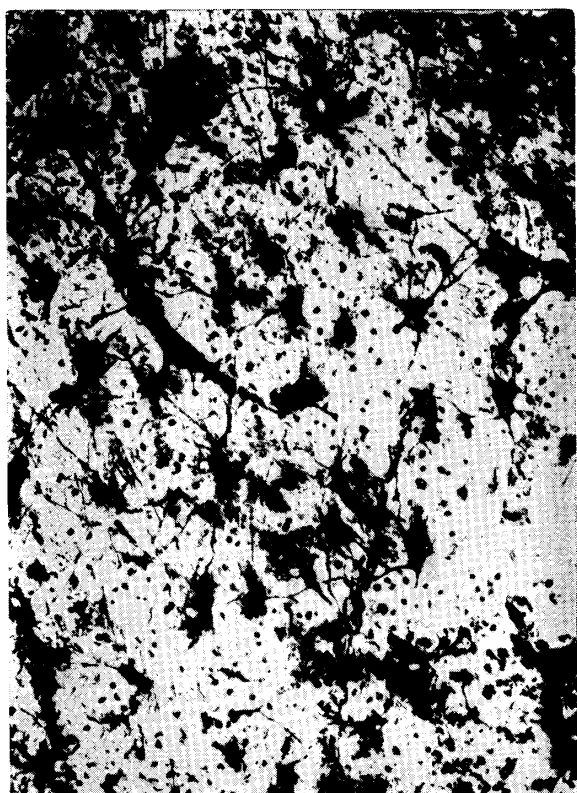

Fig. 3.

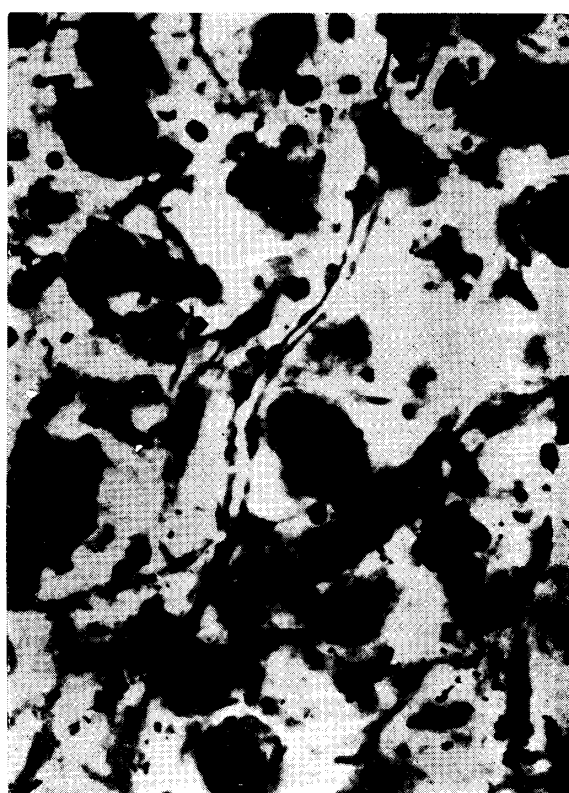


Fig. 4.