



# HOKKAIDO UNIVERSITY

Title	ON A CASE OF CANINE LINGUATULIASIS AND ITS ROLE AS THE INTERMEDIATE HOST
Author(s)	OHBAYASHI, Masashi; OHSHIMA, Kan-ichi
Citation	Japanese Journal of Veterinary Research, 2(2), 47-54
Issue Date	1954-08-20
DOI	<a href="https://doi.org/10.14943/jjvr.2.2.47">https://doi.org/10.14943/jjvr.2.2.47</a>
Doc URL	<a href="https://hdl.handle.net/2115/1654">https://hdl.handle.net/2115/1654</a>
Type	departmental bulletin paper
File Information	KJ00002372872.pdf



# ON A CASE OF CANINE *LINGUATULIASIS* AND ITS ROLE AS THE INTERMEDIATE HOST

Masashi OHBAYASHI and Kan-ichi OISHIMA

*Laboratory of Veterinary Pathology, Faculty of  
Veterinary Medicine, Hokkaido University,  
Sapporo, Japan*

(Received for Publication, May 27, 1954)

## I. PREFACE

The distribution of the tongue worm (*Linguatula serrata* FRÖLICH, 1789) in Japan has been hitherto conjectural and, therefore, no scientific report of the worm has been published in this country. The authors found recently in Sapporo city a canine case of visceral *Linguatuliasis* provoked by numerous nymph stage larvae. The worm was identified as *Linguatula serrata* through the investigations; the parasitological report was already been published.<sup>23)</sup>

*Linguatula serrata* is originally parasitic in the animals of *Canidae*, as the terminal host, mainly in large type of dog; sexually matured worm lives in nasal or frontal sinuses of the host. European fox and wolf are known as another host. The worm distributes in Europe, especially quite densely in the eastern areas including the U.S.S.R., in North America and Asia; the existence of the worm has been reported recently in New Zealand.<sup>8)</sup>

The worm, on the other hand, must have an intermediate host in its life cycle and various hosts are known including herbivorous and omnivorous mammals such as cattle, sheep, goat, swine and also human beings; but carnivorous mammals play a very poor role as the intermediate host to the worm, judging from the fact that only feline cases have been, rarely, described in this group.

Due to the existence of the above facts, the authors offer the present report of the discovery of the worm as the first one published from Japan and they have described pathological changes for the first reported case where a canine played a role as the intermediate host.

## II. MATERIALS AND METHODS

The case was 2 years old male pointer, without any career worthy of description except the experience of several times of hunting. Carcass of the animal was found in the early morning on October 31,

1953 and no sign of clinical symptoms had been manifested before the death. The animal was autopsied at our laboratory on October 31 after about 10 hours from death; histological examination was made according to the routine methods.

After formalin fixation, some materials of viscera with parasites were investigated to identify them parasitologically by Assist. Prof. J. YAMASHITA of the Laboratory of Zoology, Faculty of Agriculture, Hokkaido University.

### III. DESCRIPTIONS

#### 1. Macroscopical Changes

Autopsy number E. 1129. A carcass of emaciated large male dog. Visible mucous membranes congested, subcutaneous fat tissues poorly developed. Subcutaneous tissues congested and superficial lymph nodes normal in characters.

##### Abdominal cavity

Abdominal fluid slightly increased without any abnormality.

Major omentum covered the viscera, fat tissue of it poorly developed and many encysted parasites observable. The cysts measured 1-5.2 mm in diameter, thick orbicular in shape and slightly yellowish in colour. Some cysts were embedded in fat tissue which developed along blood vessels and others were scattered independently. The cysts, their number above fifty, showed diffuse distribution. The large cysts, in which the worm encysted bending in C-form, had thick firm wall with smooth surface. Removal of the worm from the cyst was difficult, because, in almost all cysts, the wall of both worm and cyst were close together without any other content and the body of worm was very weak. The worm was slightly transparent, cylindrical and white in colour. In the small cysts, existence of the worm was uncertain, some cysts contained only creamy yellowish white substances; extremely small cysts were hard and calcified.

Spleen not enlarged with thick capsule, on cut surfaces trabeculae well developed and follicles visible.

Liver normal in shape and size, rich in blood, parenchyma slightly clouded and lobular figures clear; some encysted worms right beneath the capsule and also in parenchyma.

Anterior mesentery congested with poorly developed fat tissues, smooth surface and some encysted worms. Mesenteric lymph nodes not enlarged, edematous, some small calcified foci on cut surfaces and in peripheral tissue a few encysted worms existed.

Posterior mesentery congested with poor fat tissues, smooth surface and an encysted worm.

No pathological changes in pancreas except congestion.

Stomach dilated with large amount of contents, serosa congested and smooth,

wall relaxed and mucosa congested.

Small and large intestine contained normal contents, serosa with smooth surface and dilated blood vessels, mucosa slightly congested and no abnormality on lymphoid apparatus.

No lesion in suprarenal glands with normal shape and size.

Perirenal fat tissues poorly developed with two encysted worms close to the renal capsule. Kidneys showed normal shape, size and consistency, small gray foci on surface, on cut surfaces parenchyma congested and slightly clouded and the gray foci invaded into parenchyma radiately. Mucosa of renal pelvis congested. A renal lymph node soyabean-size with cystic parenchyma due to occupation of encysted worms.

Mucosa of ureters and urinary bladder congested. No pathological sign on prostate glands and testicles.

Muscular tissue of diaphragm congested and three encysted worms on abdominal surface.

#### Thoracic cavity

Thoracic and pericardiac fluid normal. Pericardium and pleura congested with smooth surfaces.

Lung with smooth pleura and subpleurally several encysted worms with rather thin wall. Pulmonary parenchyma congested and edematous and also a few encysted worms in parenchyma. Bronchial mucosa congested and a large amount of foamy mucous substance in bronchial cavities. Pulmonary hilus lymph nodes not enlarged but congested and slightly anthracotic.

Heart with normal coronary fat tissue, epicardiac surface smooth and sub-epicardiac blood vessels dilatate. The right cardiac ventricle extremely dilated, all ventricles and auricles contained great quantities of tar-like blood clots, endocardium generally smooth and congested without any pathological focus and myocardium congested.

Oesophagus and aorta without lesions.

No pathological changes except congestion on tongue, tonsils, laryngo-pharyngeal mucosa and thyroid glands.

Mucosa of nasal cavities and frontal sinuses congested without any abnormal content and lesion.

Brain showed meningeal congestion and nervous tissue without focal lesions.

#### Patho-anatomical diagnosis:

1) Generalized visceral *Linguatuliasis*. 2) General congestion. 3) Dilatation of the right cardiac ventricle. 4) Gastric ectasia. 5) Interstitial focal nephritis.

#### 2. Microscopical Changes

As no differences of structure were found among the encysted worms located in various organs, their descriptions were represented by that of liver.

Liver congested especially periportally, reticuloendothelial cells activated. Cross sections of the encysted worm were observed subcapsularly without any tissue reaction. The cyst wall consisted of two layers; outer fibrous thin layer with slight accumulation of plasma cells and eosinophile leucocytes and inner homogeneous layer without nuclei. Nearby the worm folded membranous cast skin could be seen and it was regressively degenerated. In GLISSON'S sheath a small parasitic cyst, of which the wall was thick fibrous and the contents the cast skin.

Spleen atrophic, trabeculae and follicular arterioles thickened.

Kidney remarkably congested, renal tubules dilated frequently with serous hyaline substances and focal cell accumulations in interstitium. An encysted worm without histological reactions in the perirenal fat tissue.

Myocardium congested and no lesions on muscle fibers.

Lung markedly congested, edematous and slightly anthracotic. Bronchial epithelia showed high degree of mucous formation and desquamation and bronchial cavities contained large amounts of exsudate. In subpleura and parenchyma cross sections of three encysted worms without reactions. On one of the cross sections, the head of the worm with four hooks was confirmed. Apart from the parasitic cyst in pulmonary parenchyma, a small organized focus consisted of giant cell formation, vascularization and accumulation of eosinophile leucocytes.

Renal lymph node of soyabean-size was cystic with four cross sections of the encysted worms and lymphoid tissue was pressed outwards without reactions. No remarkable changes except slight lymphatic hyperplasia in mesenteric lymph node, but a calcified small focus could be seen in parenchyma and an encysted worm was found in peripheral tissue. Pulmonary hilus lymph node slightly anthracotic and edematous.

Pancreas congested. A small calcified parasitic cyst in mesentery. Thyroid gland congested. No lesions on oesophagus and stomach. Slight congestion of mucosa on small intestine. Large intestine congested and its solitary lymphoid nodules hyperplastic.

Major omentum showed no lesions except characteristic parasitic cysts.

Salivary gland congested. Testicle normal. Urinary bladder congested and its *tunica propria* slightly fibrous.

On the abdominal surface of diaphragm an encysted worm which was small and immatured was found.

Numerous acidophile granules in epithelial protoplasm of tongue.

Blood vessels of meninges and nervous tissue of brain dilated. Focal meningitis with accumulation of numerous eosinophile leucocytes in occipital lobe, but nervous tissue close to the meninges was intact.

#### IV. DISCUSSION

The authors investigated a case of generalized *Linguatuliiasis* as above described. The parasite was already identified and reported as

the nymph stage larva of *Linguatula serrata* FRÖLICH, 1789: the canine case described in the present paper had played a role as intermediate host for the parasite.

Larvae of the parasite can be found from various mammalian animals, especially from such organs as lung, liver, mesenteric lymph node, etc. of domestic animals. Many reports of larval cases have been also published hitherto by many investigators including such as, on bovine cases by V. BABES (1889), BUGGE (1927), GINSBURG & KORJASNOV (1928), BOGDASCHEW (1930, 1931), CARNEYATINI (1931) and IWANOFF (1933, 1934); on caprine cases by LURJE (1929), SYSAK & BYKOW (1930) and IWANOFF (1939), and on ovine cases by LURJE (1929).

HEYMONS & VITZTHUM (1935) listed the following 21 intermediate hosts of *Linguatula serrata*:

- |   |   |
|---|---|
| 1) <i>Erinaceus auritus</i> PALLAS        | 12) <i>Camelus dromedarius</i> L.         |
| 2) <i>Erinaceus aethiopicus</i> EHRENBERG | 13) <i>Dama dama</i> L.                   |
| 3) <i>Lepus cuniculus</i> L.              | 14) <i>Capreolus capreolus</i> L.         |
| 4) <i>Lepus europeus</i> L.               | 15) <i>Ovis aries</i> L.                  |
| 5) <i>Cavia porcellus</i> L.              | 16) <i>Capra hircus</i> L.                |
| 6) <i>Hystrix cristata</i> L.             | 17) <i>Bos taurus</i> L.                  |
| 7) <i>Epimys norvegicus</i> L.            | 18) <i>Bubalus buffelus</i> L.            |
| 8) <i>Felis catus</i> L.                  | 19) <i>Boselaphus tragocamelus</i> PALLAS |
| 9) ? <i>Felis sylvestris</i> SHREBER      | 20) <i>Bubalus buselaphus</i> PALLAS      |
| 10) <i>Equus caballus</i> auct.           | 21) <i>Homo</i>                           |
| 11) <i>Sus domesticus</i> auct.           |   |

It is clearly comprehensible that the intermediate hosts of *Linguatula serrata* are chiefly herbivorous mammals whilst carnivorous mammals play rare role, because only feline cases have been hitherto reported.

The dog, which is naturally the terminal host, was an intermediate host in the present case; it can also be considered as an exception, but the fact is of much interest.

As to the lesions of intermediate host, it has been described by many investigators that the larva forms a green or red-brown nodule and usually provokes many sorts of reactions on the host tissue. Although no tissue reaction was observed against the encysted worm in the present case, it is considered that the absence of reaction is due to difference of the host species and also development stage of the worm.

Finally the cause of death in this case become a subject of discussion, because no evidence that the parasitism had caused the death was confirmed histologically, that is, no severe lesions which might have

been provoked by the worms were present as above described. The authors, through the investigations of anatomical and histological changes, consider that the cause of death was a cardiac functional disturbance.

#### V. SUMMARY

The authors investigated a canine case of *Linguatubiasis* caused by numerous nymph stage larvae of *Linguatula serrata* FRÖLICH, 1789.

The worm were encysted and could be found in various visceral organs and serous membranes such as major omentum, liver, lungs, lymph nodes, mesentery, diaphragm, perirenal fat, etc. The worm provoked no histological reactions against the host tissue.

Although the existence of *Linguatula serrata* has not been hitherto reported scientifically, the authors confirmed it in the present paper.

It was established for the first time by the authors that the dog (*Canis familiaris* L.) can play a role as the intermediate host of *Linguatula serrata*.

#### ACKNOWLEDGMENT

On concluding this paper the authors wish to extend their gratitude to Assistant Professor J. YAMASHITA of the Laboratory of Zoology, Faculty of Agriculture, Hokkaido University, for his zoological identification of the parasite and also for his kind advice.

#### LITERATURES

- 1) BABES, V. (1889): *Zbl. Bakt.*, I, (Orig.), 5, 1.
- 2) BOGDASCHEW, N. (1930): *Tierärztl. Rdsch.*, 37, 401.
- 3) BOGDASCHEW, N. (1931): *Clin. Vet.*, 54, 71 [*Jb. Vet.-Med.*, 51, 1257 (1931)].
- 4) BUGGE, G. (1927): *Deuts. T. W.*, 35, 345.
- 5) BUGGE, G. (1927): *Berl. T. W.*, 43, 309.
- 6) CARNEVALINI (1931): *Clin. Vet.*, 54, 71 [*Jb. Vet.-Med.*, 51, 1257 (1931)].
- 7) GINSBURG, G. u. V. KORJASNOV (1928): *Trudy gosudarstv. Inst. eksper. Vet.*, 5, 59 [*Jb. Vet.-Med.*, 49, 1164 (1929)].
- 8) GURR, L. (1953): *N. Z. J. Sci. Tech. Ser. B.*, 35, 49 [*Vet. Bull.* 24, 22 (1954)].
- 9) HEYMONS, R. u. VITZTHUM, H. (1935): *Z. Parasitenk.*, 8, 1.
- 10) IWANOFF, X. (1933): *Jb. Vet. Med. Fak. Sofia*, 9, 203 [*Jb. Vet.-Med.*, 53, 610 (1933)].
- 11) IWANOFF, X. (1934): *Z. Infektkr. Haust.*, 45, 157.
- 12) IWANOFF, X. (1939): *Jb. Vet. Med. Fak. Sofia*, 14, 231 [*Jb. Vet.-Med.*, 66, 151 (1939)].
- 13) IWANOFF, X. (1939): *Jb. Vet. Med. Fak. Sofia*, 14, 156 [*Jb. Vet.-Med.*, 67, 391 (1940)].
- 14) KOCH, M. (1906): *Deut. Path. Ges.*, 10, 265.
- 15) KOCH, M. (1912): *Z. Fleisch- u. Milchhyg.*, 12, 291 [*Jb. Vet.-Med.*, 32, 343 (1912)].
- 16) LURJE, M. Z. (1929): *Z. Infektkr. Haust.*, 36, 193.
- 17) PILLARS, N. (1929): *Vet. J.*, 85, 307.
- 18) RATZ, S. v. (1892): *Zbl. Bakt.*, I, (Orig.), 12, 331.

- 19) SAGREDO, N. (1924): *Virch. Arch.*, **251**, 608.
- 20) SOLOVJOV (1929): *Z. nāucn. i prakt. Vet. Med.*, **10**, H. 6, 29 [*Jb. Vet.-Med.*, **49**, 1164 (1929)].
- 21) SONOBE, K. (1927): *Virch. Arch.*, **263**, 753.
- 22) SYSAK, N. u. W. BYKOW (1930): *A. Tierhkk.*, **61**, 114.
- 23) YAMASHITA, J. & M. OHBAYASHI (1954): *Mem. Fac. Agr. Hokkaido Univ.*, **2**, No. 2 (Japanese with English summary).

## EXPLANATION OF PLATES

## Plate I

- Fig. 1. Major omentum showing two parasitic cysts.  $\times 3$ .
- Fig. 2. Head of the parasite showing four hooks (H) and mouth (M).  $\times 35$ .
- Fig. 3. Head of the parasite.  $\times 35$ .
- Fig. 4. Section of the encysted parasite in major omentum showing cyst wall (W) and head of the parasite (P). Hematoxylin-eosin.  $\times 60$ .

## Plate II

- Fig. 5. Liver showing three cross-sections of the parasite (P) and its cast skin (C) right beneath the hepatic capsule. Hematoxylin-eosin.  $\times 35$ .
- Fig. 6. Subcapsular encysted parasite in liver showing the parasite and cast skin. Hematoxylin-eosin.  $\times 35$ .
- Fig. 7. A cross section of the parasite and cast skin in peripheral tissue of mesenteric lymph node. Hematoxylin-eosin.  $\times 35$ .
- Fig. 8. Mesenteric lymph node showing a calcified parasitic nodule with degenerated cast skin of the parasite. Hematoxylin-eosin.  $\times 60$ .

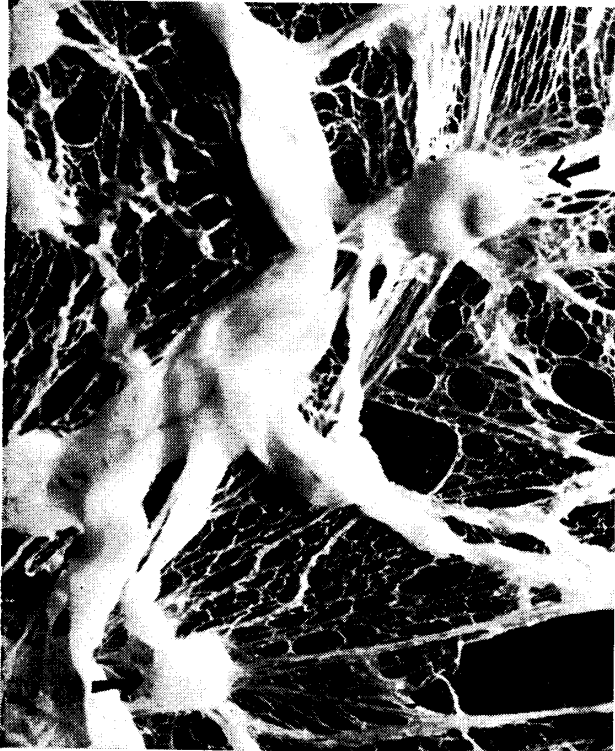

Fig. 1.

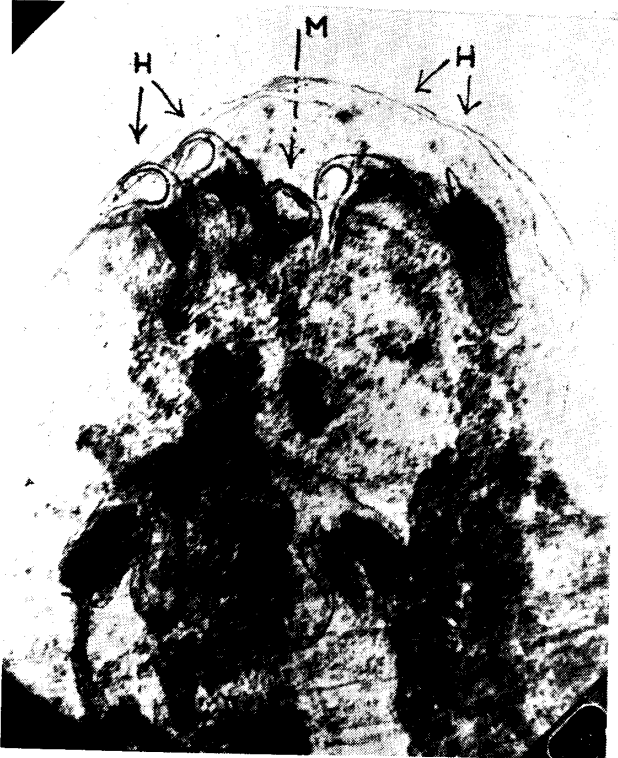
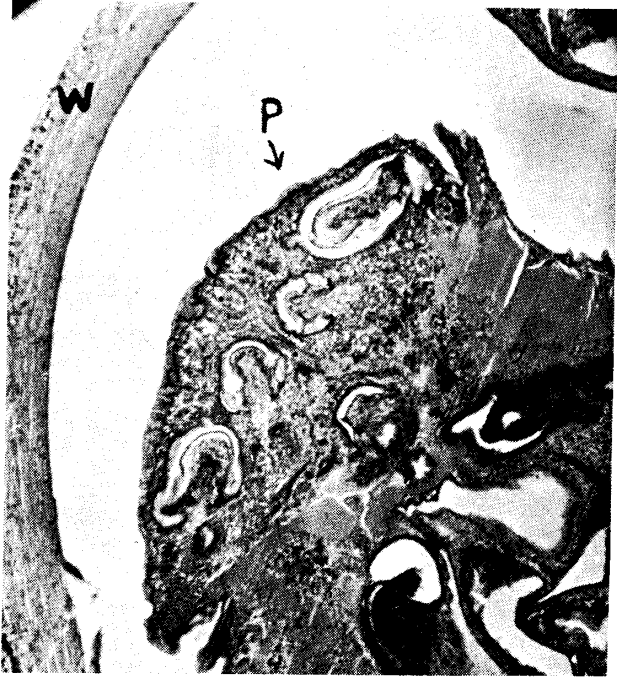
Fig. 2.



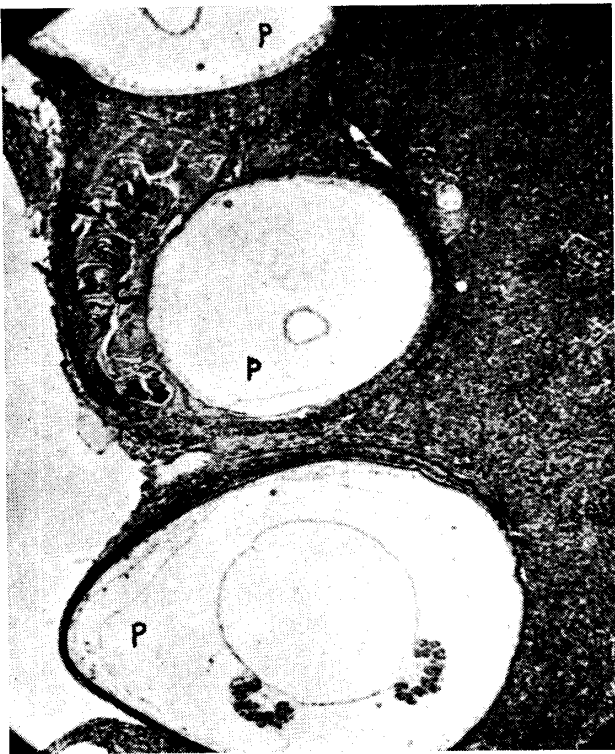


Fig. 5.

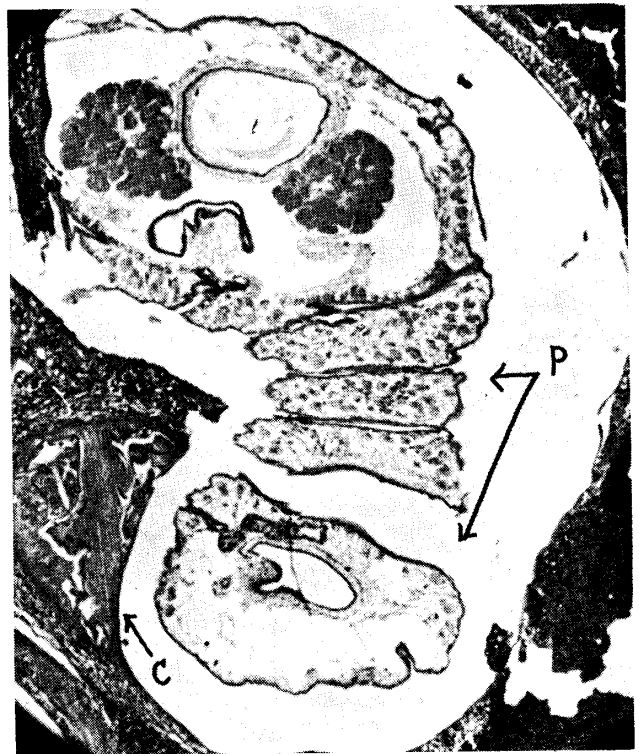

Fig. 6.

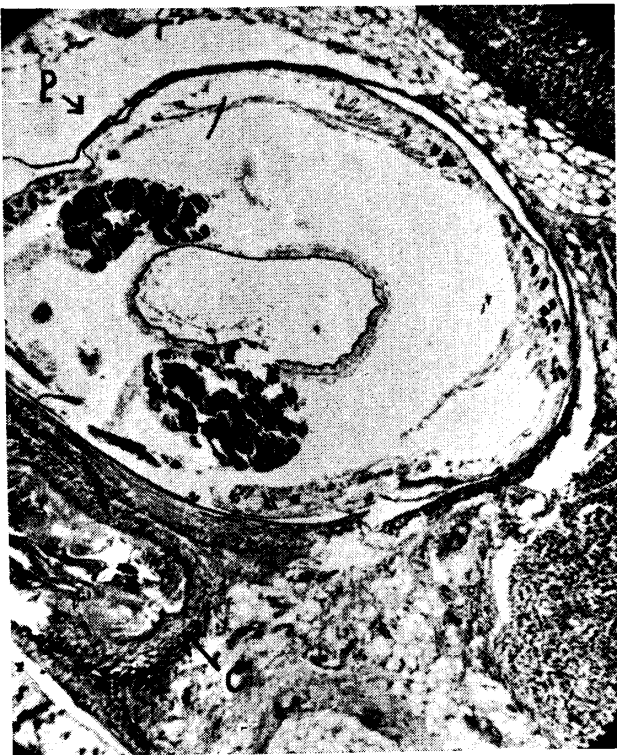

Fig. 7.

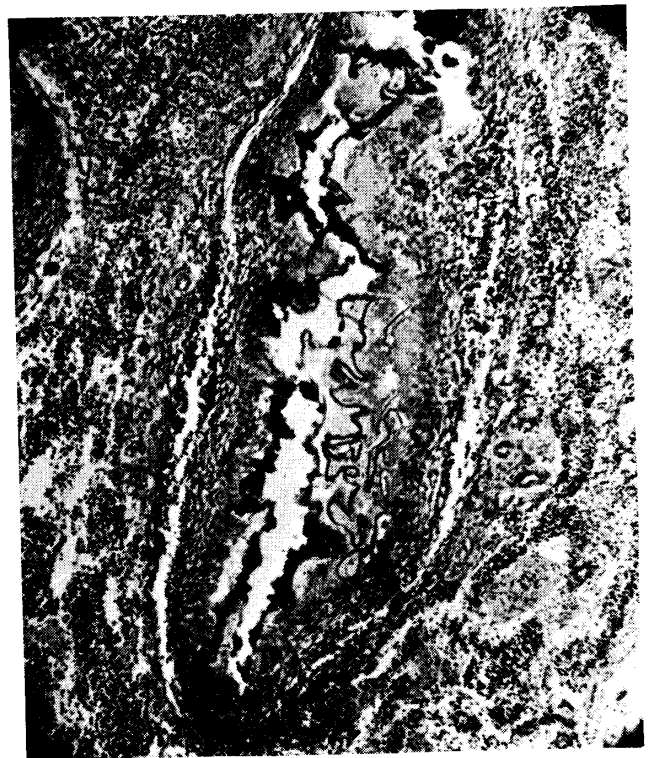

Fig. 8.