



HOKKAIDO UNIVERSITY

Title	STUDIES ON "KASEN" OF HORSES IN HOKKAIDO : I. RESULTS OBTAINED IN 1953
Author(s)	Nakamura, Ryoichi; Sonoda, Mitsuo; Too, Kimehiko et al.
Citation	Japanese Journal of Veterinary Research, 2(3), 109-116
Issue Date	1954-11-20
DOI	https://doi.org/10.14943/jjvr.2.3.109
Doc URL	https://hdl.handle.net/2115/1659
Type	departmental bulletin paper
File Information	KJ00002372899.pdf



STUDIES ON "KASEN" OF HORSES IN HOKKAIDO

I. RESULTS OBTAINED IN 1953

Ryoichi NAKAMURA¹⁾, Mitsuo SONODA¹⁾, Kimehiko TOO¹⁾
Hiroshi SATOH²⁾, Jiro YAMASHITA³⁾, Hitoshi ABE⁴⁾
Toshio TAKAMIYA⁵⁾, Tatsuro KUROSAKI⁵⁾
and Rokuro SHIBATA⁵⁾

(Received for Publication, August 5, 1954)

INTRODUCTION

It is well known, since olden times, that a chronic and stubborn skin disease of horses, namely "Kasen" called "Omushi", "Kaikai", "Surippo" or "Kayukayu", etc., is frequent among the horses in Hokkaido and Tohoku districts of Japan. Clinical syndromes with itchiness appear in early spring and become severe in summer, while they naturally disappear towards the cool season. All patients repeat the same course in every year. Affected regions may change to dermatitis in accordance with the results of rubbing themselves and sometimes there is developed an elephant-like skin. The true cause has remained uncertain and the therapeutic and preventive methods also have not yet been established, because this disease is not fatal and also the patient recovers naturally when winter comes.

There have been few reports published on this disease. KONDO et al. reported that it was caused by the microfilariae in blood stream. OGUNI found definite microfilariae in the true skin stratum and also confirmed the corresponding pathological changes in the same stratum of patients. He suggested that microfilariae may be larvae of *Setaria equina* and that they may be responsible for the causal agents of this disease. He obtained effective therapeutic results with 5~6 times injections of antimonyl derivates. KADOHASHI et al. thought that blood microfilariae

¹⁾ Laboratory of Veterinary Internal Medicine, Faculty of Veterinary Medicine, Hokkaido University, Sapporo, Japan.

²⁾ Laboratory of Veterinary Pathology, Faculty of Veterinary Medicine, Hokkaido University.

³⁾ Zoological Institute, Faculty of Agriculture, Hokkaido University.

⁴⁾ Veterinary Hospital of Ebetsu Agricultural Mutual Relief Association.

⁵⁾ Veterinary Hospital of Onbetsu Agricultural Mutual Relief Association.

may be the cause of this disease, and they showed that mixed applications of arsenic and antimonyl derivates were effective. ICHIOKA et al. reported that this disease was probably caused by the microfilariae of *Onchocerca* in the itchy skin and they recommended topical use of special ointments. SASAKI et al.^(6,7) regarded the special dermofilariae that did not live in the blood stream but live only in the true skin as the cause of this disease. SATO et al. and TANIGUCHI et al.^(9,10) stated respectively that the microfilariae of *Onchocerca cervicalis* may be causal agents of this disease and that Supatonin (1-diethyl carbamy1-4-methylpiperazine citrate)^(9,10) or Neostinal (antimonyl derivate) were very effective.

In the present paper are reported the results of the writers' investigation of the cause of "Kasen" of horses, a description of the therapeutic treatments of 35 cases, and a report on clinical, hematological, pathological and parasitological studies which were made.

ETIOLOGICAL EXAMINATIONS

1. Clinical Observations

Out of 35 cases used for this experiment, 23 had been bred in Onbetsu district and 12 in Ebetsu district. Black and brown were most frequent hair colors. They were pure bred or mongrel Percheron, 2~15 years old, including males and females and they were at pasture in summer. Signs of infectious anemia, clinically and hematologically, were not found in all cases at all. The initial attacks of

TABLE 1. *Relationship of the Degrees of Lesions on the Several Regions to Their Occurrences*

REGIONS	DEGREES				
	-	+	++	+++	###
Tail	0	3	5	18	9
Withers	1	9	12	12	1
Upper-neck	4	22	5(1)*	4(3)*	0
Shoulder	8	6	6	11	4
Rump	9	20	4	2	0
Lower-neck	14	12	5	4	0
Fore-head	14	18	3	0	0
Back	13	16	1	0	0
Cheek	33	1	1	0	0

Notes: - indicates no pathological changes.

+ ~ ### indicate degrees of cutaneous pathological changes.

* Dermofilariae were detected from these cases.

TABLE 2. Various Changes of Skin and Their Occurrences

SYMPTOM	DEGREES				
	-	+	++	##	###
Falling off of hair	1	12	12	9	1
Shortness of hair	1	22	7	5	0
Itchiness	0	2	11	13	9
Thickness	1	18	9	7	0
Crust	3	20	6	5	1
Swelling	4	23	3	5	0
Dandruff	4	28	3	0	0
Node	9	22	4	0	0
Heat	9	24	1	1	0
Exudate	25	9	0	1	0
Ulcer	25	9	1	0	0

Notes: - indicates no pathological changes.
 + ~ ### indicate degrees of changes.

this disease, in most cases, were found at the age of 2~3 years old, while a few cases appeared at their colt stage. One of the cases had 12 recurrences within a period of 13 years. Symptoms appeared from early May or from the middle of August and disappeared naturally from the end of September or from late October in every year. Nutrition of all cases was generally good and no hereditary relationships nor stable infections were recognized for its causation. The results of clinical observations were shown in tables 1 and 2 and figs. 1 and 2. Regions in the tails were usually attacked most seriously and next were the cervicals. In the initial stage of this disease, small papules were found accompanied by itchiness. Itchiness in all cases was very great, and in almost every case falling off or shortness of hair, crust, dandruff, small nodes, swelling, thickness and heat in the skin were conspicuous. Further, in some cases ulcer and exudate by rubbing themselves were observed. Eczematous features were found in all cases.

2. Hematological Observations

The number of erythrocytes and leucocytes was respectively 6.29 (4.38~7.88) million and 8,300 (4,800~15,600) on the average. The percentage of eosinophilic cells was found to increase over 5% in 19 cases (59.3%), and 6 cases of them showed a high increase rate of 10~13%. In other blood cells no significant changes were observed. No microfilariae were recognized in the blood streams of any of the patients by ISHII's method, while in normal 200 horses examined at Onbetsu as control, microfilariae were found in 4 cases or 2%. These micro-

filariae were suspected to be those of *Setaria equina* as indicated in fig. 3.

3. Bacteriological and Parasitological Observations

Bacteriological examination of the exudates of the lesions was carried out in 30 cases. Results indicated the presence of the following: *Staphylococcus albus* in 19, *Streptococcus pyogenes* in 1, *Staphylococcus* and *Streptococcus* in 3 and saprophytes in 7 cases.

SASAKI's method was used in the examinations of living microfilariae in small pieces of affected cutaneous tissues. Twelve cases in Ebetsu group were all negative, but 4 out of 23 cases in Onbetsu group there were detected respectively 1~6 microfilariae. These microfilariae, as indicated in fig. 4, were 0.22~0.24 mm in length and 0.0039~0.0045 mm in width with numerous granules within the whole body. However the detailed structure of their bodies were not sufficiently clear by GIEMSA staining to enable identification with certainty.

4. Histopathological Observations

Small pieces of cutaneous tissues obtained from the affected areas were employed for histological examinations of 32 cases. The materials were fixed in formalin and serial sections stained with hematoxylin and eosin were subjected to microscopic examination. Histopathological figures are shown in figs. 5~7.

Seventeen cases (53.1%) indicated eczematous lesions with various degrees of erosion, ulcer, hyperkeratosis and crust formation of epidermis, and some cases manifested marked neutrophilic accumulations in the germinal and papillary layer. Ten cases were examined under microscope again after treatments, however, the findings were almost the same in comparison with those before treatment. However, living dermofilariae were detected by parasitological examinations from the cutaneous materials of 4 cases, while no microfilaria was observed histologically. In most cases, however, slight infiltration of eosinophiles were seen.

THERAPEUTIC TREATMENTS

Stinal (sodium antimonyl-tartarate) was used intravenously for 21 cases, as indicated in table 3, at the rate of 3~5 mg Sb/kg of body weight per day for 5 days as one cure and was applied 2 or 3 cures with 3 or 5 days intervals. At the terminations of 2nd and 3rd cures itchiness in 6 (28%) and 2 (13%) cases decreased respectively, but all relapsed one or two weeks after the last medication.

Eight cases were treated with Neostinal (sodium antimony III bis-pyrocatechol-2, 4-disulfonate). Neostinal, as is shown in table 3, was injected intravenously in the amount of 3.3 mg Sb/kg of body weight per day for 5 days as one cure and was applied 2 or 3 cures as was done in stinal group. After the second and third cures of injections 3 (37%) and 2 (40%) cases became clinically lighter but all

TABLE 3. Results of Antimonyl Treatments

MEDICINE	AT ONE CURE		AT TWO CURES		AT THREE CURES		TOTAL NO. OF SLIGHT RECOV.	AFTER 1~2 WEEKS	
	No. of Horses	Slight Recov.	No. of Horses	Slight Recov.	No. of Horses	Slight Recov.		Recover	Relapse
Stinal	21	0	21	6 (28%)	15	2 (13%)	8 (38%)	0	21
Neostinal	8	0	8	3 (37%)	5	2 (40%)	5 (62%)	0	8

cases relapsed after treatments just as in stinal group. When parasitological examinations were conducted at the termination of treatments, living dermofilariae were found in 4 cases as was found also before the treatments.

DISCUSSIONS

Based upon the above described results, some criticisms will be offered on the cause of this disease in Hokkaido. Some authors^(3,4,5) supposed its cause to be microfilariae in the blood stream. But others^(1,6,8,9) believed it to be caused by some special dermofilariae, not the same as microfilariae, which live in the blood streams and are identified with *Onchocerca cervicalis*. Microfilariae in the skin tissues were also detected by the present writers but the frequency of their appearance was very low and also the numbers of the detected microfilariae respectively only 1~6. Those detected microfilariae have not yet been identified, but the writers recognize that this disease is ascribable to them. The characteristic symptoms of this disease are secondarily caused by rubbing, because the itchiness in the skin is usually very great and saprophyte infections will aggravate such symptoms. The determination of species name for such dermofilariae may throw light upon the reason why itchiness and secondary main pathological changes are limited only to the long hair regions and also upon the seasonal characteristic for the appearance of clinical symptoms.

In the therapeutic treatments using antimonyl derivates, beneficial results were not obtained, but treatments by various other methods as well as investigations of the causal agents will be continued.

SUMMARY

Clinical, hematological, histopathological and parasitological studies on "Kasen" of horses in Hokkaido were made by the authors.

The results thus obtained may be summarized as follows:

1. The disease made its appearance from early May to about the middle of August; symptoms became worse in summer, but they disappeared gradually with cool season and naturally disappeared in winter.
2. The first attacks of this disease were usually upon 2 to 3 years old animals, while the range was as wide as 1~15 years. Attacks were repeated every year and some of the animals showed 12 relapses.
3. This disease had nothing to do with species, sex, nutrition, breed or management nor was stable infection confirmed.
4. The patients were all pastured, and the tendency of increase in occurrences was observed in areas near rivers and swamps, but relationship with blood-sucking insects has not yet been clarified.
5. Attacked regions were found mostly in the long hair parts. Characteristic symptoms were severe itchiness and secondary eczema or dermatitis such as depilation, dandruff, erosion, ulcer, hyperkeratosis and crust formation as a results of the animals rubbing themselves.
6. In the bacteriological examinations in affected regions, *Staphylococcus* and *Streptococcus* were found in almost all cases, but no other special pathogenic microorganisms were detected.
7. Hematological examination showed that erythrocyte and leucocyte numbers were all within normal range, but eosinophiles were increased in most cases.
8. Living microfilariae ($0.22\sim 0.24 \times 0.0039\sim 0.0045$ mm) were detected from pieces of cutaneous tissues in 4 patients (11%). These microfilariae are not yet identified, because they were too few to examine their body structure in detail.
9. Histopathologically, 17 cases (53.1%) showed eczematous lesions and infiltrations of eosinophiles, however, microfilariae were not found in all cases.
10. Treatments with intravenous injections of antimonyl derivatives (Stinal and Neostinal) did not obtain beneficial results.

The authors wish to express their cordial gratitude to Prof. KUROSAWA, Dean of the Veterinary Faculty, to Prof. YAMAGIWA, Chief of Laboratory of Veterinary Pathology, who offered many kindly advices and also to the members of the Laboratory of Veterinary Hygiene & Microbiology who made the bacteriological findings. We are also indebted to Hokkaido Prefectural Authorities for the grants in aid to conduct this experiment. Further appreciation is expressed to the Gendai Pharm. Co. Ltd., for their kindness in willingly supplying drugs.

REFERENCES

- 1) ICHIOKA, T., N. NAKAMURA, M. ABE & Y. NODA (1951): *J. Vet. Med.*, No. 67, 484 & No. 69, 561 (Japanese).
- 2) ISHII, S. (1914): *Ôyojuigaku-zasshi*, 14, 205 (Japanese).
- 3) KADOHASHI, S. & Y. MIYAMOTO (1950): *J. Jap. Vet. Med. Ass.*, 3, 178 (Japanese).
- 4) KONDO, T. & R. UESHIMA (1928): *Chuojuigaku-zasshi*, 41, 981 (Japanese).
- 5) OGUNI, H. (1936): *Ôyojuigaku-zasshi*, 9, 235 (Japanese).
- 6) SASAKI, N. & K. SANO (1953): *J. Jap. Vet. Med. Ass.*, 6, 162 (Japanese).
- 7) SASAKI, N., M. SATO & K. SANO (1954): *Ibid.*, 7, 314 (Japanese).
- 8) SATO, K., S. HAYASHI & H. TANAKA (1954): *Jap. J. Parasit.*, 3, 199 (Japanese).
- 9) TANIGUCHI, M. & Y. YONEHANA (1953): *J. Vet. Med.*, No. 114, 631 (Japanese).
- 10) TANIGUCHI, M., H. OSHIDA, G. AZUMA & K. SHIGIHARA (1954): *Ibid.*, No. 132, 330 (Japanese).
- 11) TANIGUCHI, M. (1954): *J. Jap. Vet. Med. Ass.*, 7, 119 (Japanese).

EXPLANATION OF PLATES

PLATE I.

Figs.1 & 2. Characteristic symptoms.

Fig. 3. Microfilaria in blood. $\times 340$.

Fig. 4. Dermomicrofilaria from cutaneous tissue. $\times 550$.

PLATE II.

Fig. 5. Crust formation (c) and erosion (e) of epidermis.

Hematoxylin-eosin. $\times 45$.

Fig. 6. Erosion (e), hyperkeratosis (k) and accumulation of neutrophilic leucocytes in the germinal layer (n). Hematoxylin-eosin. $\times 45$.

Fig. 7. Higher magnification of the square part of the fig. 6 showing cell accumulation of neutrophilic leucocytes in the papillary layer.

Hematoxylin-eosin. $\times 80$.




Fig. 1.

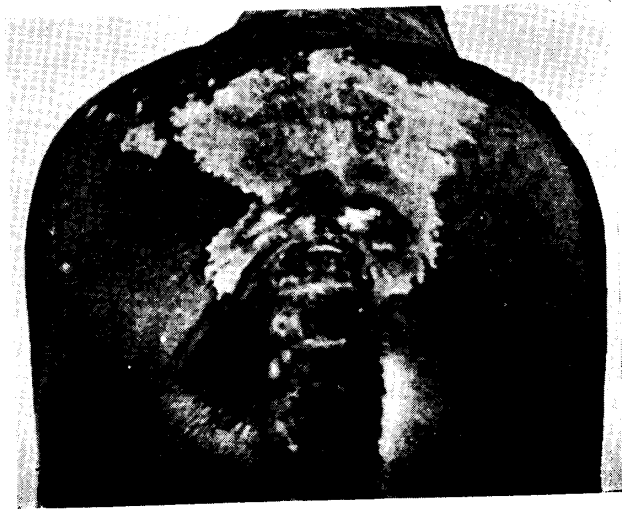


Fig. 2.

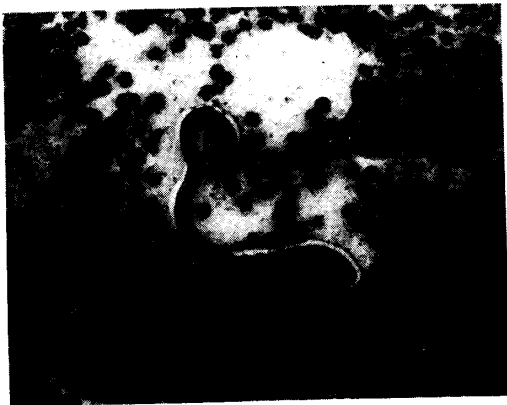

Fig. 3.

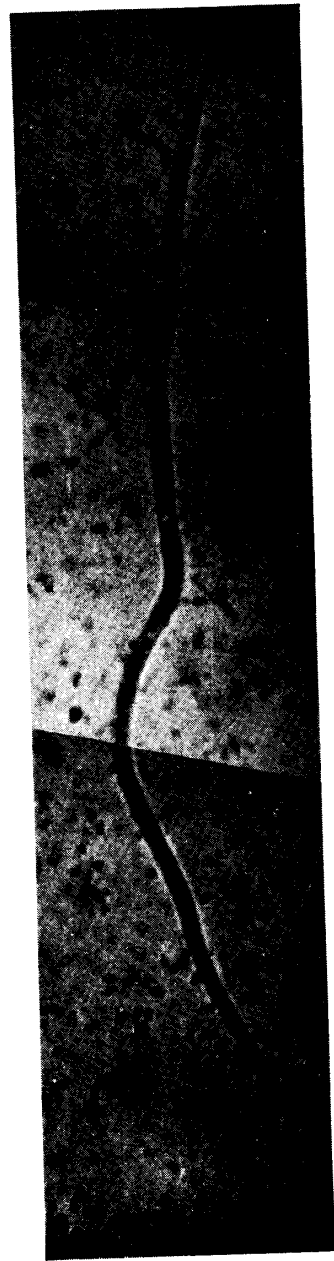

Fig. 4.

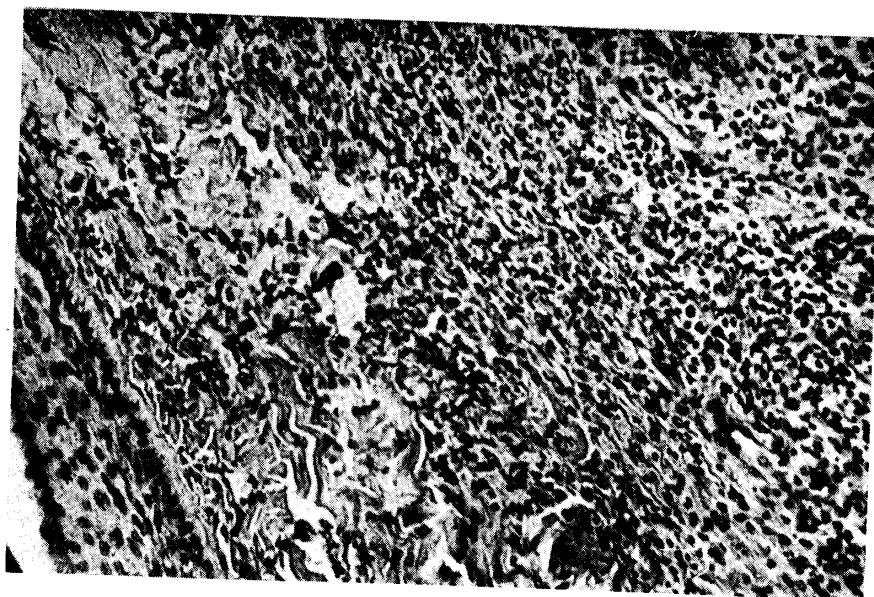


Fig. 7.

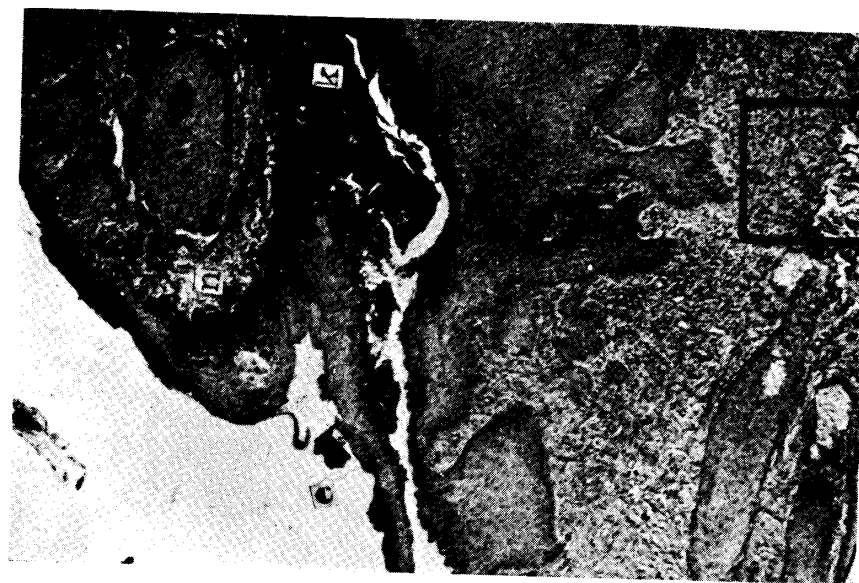


Fig. 6.

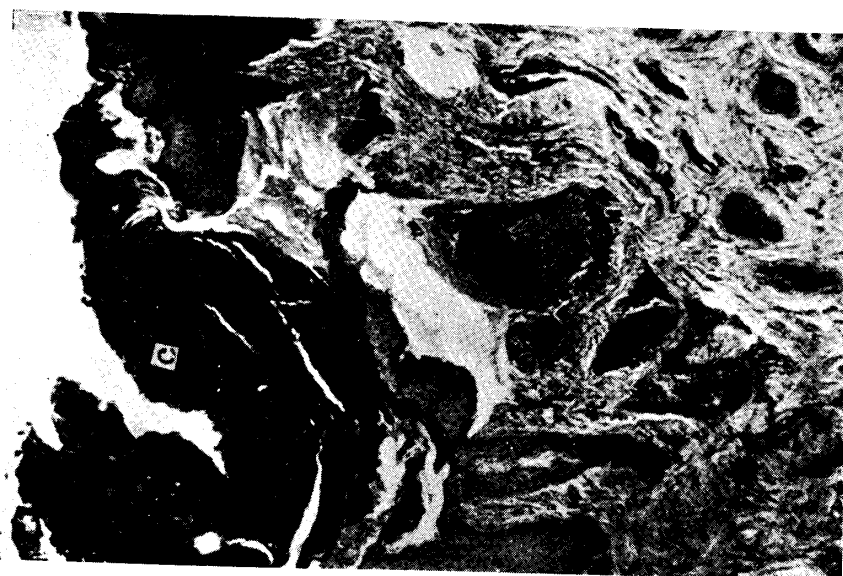

Fig. 5.