



HOKKAIDO UNIVERSITY

Title	COMPARATIVE PATHOLOGICAL INVESTIGATION ON ENCEPHALITIS OF DOMESTIC ANIMALS : ESPECIALLY ON THE EOSINOPHILIC ENCEPHALITIS OF SWINE AND DISTEMPER ENCEPHALITIS I
Author(s)	YAMAGIWA, Saburo
Citation	Japanese Journal of Veterinary Research, 3(2), 41-72
Issue Date	1955-08-10
DOI	https://doi.org/10.14943/jjvr.3.2.41
Doc URL	https://hdl.handle.net/2115/1667
Type	departmental bulletin paper
File Information	KJ00002372928.pdf



COMPARATIVE PATHOLOGICAL INVESTIGATION ON
ENCEPHALITIS OF DOMESTIC ANIMALS;
ESPECIALLY ON THE EOSINOPHILIC ENCEPHALITIS
OF SWINE AND DISTEMPER ENCEPHALITIS* I.

Saburo YAMAGIWA

*Laboratory of Veterinary Pathology, Faculty of Veterinary
Medicine, Hokkaido University, Sapporo, Japan*

(Received for Publication, April 30, 1955)

What role can comparative pathology play in the investigation of the encephalitic disease of domestic animals? The author, at this juncture, wishes to discuss this problem centering around the eosinophilic encephalitis of swine (*encephalitis eosinophila suis*)** and distemper encephalitis.

Professor W. SPIELMEYER, the author's respected instructor, in some works published in the later part of his academic life keenly criticized the tendency for some etiologists unjustly to over-emphasize the role of the lesions of central nervous system when studying encephalitic disease. The present author considers that circumstance is also recognized in our veterinary circle. To cite an example, many people are liable to imagine almost reflectively a picture of non-purulent encephalitis when they hear the name "virus disease". The author's major reason for drafting this report is to inquire into the role of comparative pathology in studying the encephalitis of domestic animals.

The author, therefore, wishes to arrange the results obtained from his observation of various cases of encephalitis during the past 20-odd years, being guided by R. VIRCHOW's words, "Zwar die Schädigungen spezifisch sind, nicht aber ihre Folgen am Organ", and also wishes to describe in succession the opinions on the above problems as entitled.

I.

The Sort of Reaction of Glia Cell The sort of reaction of glia cell can

* A special lecture delivered at the 38th Meeting of the Japanese Society of Veterinary Science on September 10, 1954 in Sapporo.

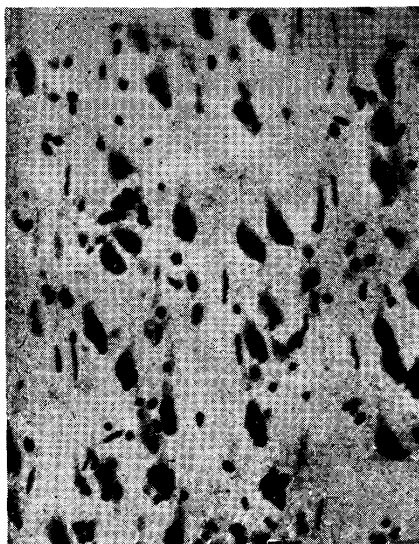
** Preliminary designation of a characteristic encephalitic disease of swine which was experienced by the author and others in Hokkaido and Tohoku districts (TAJIMA, M. & S. YAMAGIWA (1950): *Jui Chikusan Shimpo (J. Vet. Med.)*, No. 48,9). Thereafter a report was made on the disease which was called "epilepsy of piglet" and similar histological findings were observed [UEDA, A. (1950): *Conference on Veterinary Medicine and Zootechny in Obihiro*]. The author and co-workers have collected data on many more cases of this disease.

be described by dividing those reactions into two groups based upon the intensity of those reactions namely the degree of development of the glial foci and the density of distribution of the foci. Although encephalitic diseases can be divided into two such groups, it cannot be overlooked that there certain variations exist among different cases within each group.

a) *The Group with Intense Glial Reaction* The author does not intend to discuss the pure biological knowledge of viral diseases, e. g. rabies, especially the course of transmission of virus into the central nervous system or the propagation of a virus. He wishes to concentrate his attention upon the proliferation of glia cells and to consider empirically whether or not it is proper on the basis of the obtained histological figures to categorize the rabid virus into the group of so-called neurotropic viruses. It will also become a subject of discussion, the author considers, whether one should, in respect to rabies encephalitis, use the name "nodular encephalitis" through the modes of glial proliferation and classify rabies encephalitis into the same type en bloc as fowl plague encephalitis.¹⁾

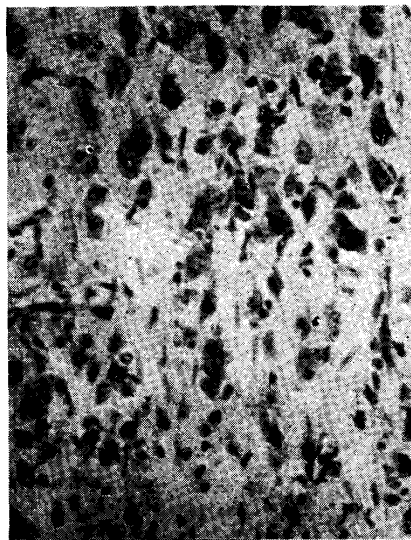
One can observe the diffused proliferation of microglia cell especially the rod cell element in the case of *paralysis progressiva* of man which is not so frequently observed in the domestic animals (Fig. 1). The author has once observed this mode of proliferation of microglia cells on the brain sections of distemper in Munich as illustrated in fig. 2.

FIG. 1.* *Paralysis progressiva* (Man)



Rod cell proliferation in cerebral cortex. EBERMANN (Forschungsanstalt für Psychiatrie, 327/33). NISSL.

FIG. 2. *Distemper Encephalitis* (Dog)

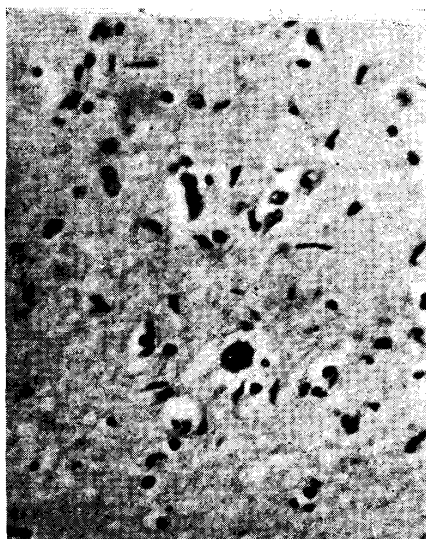


Rod cell proliferation in cerebral cortex. 198/35 (Forschungsanstalt für Psychiatrie). NISSL.

* With each figure is printed diagnosis, description, number of patient and staining method in order.

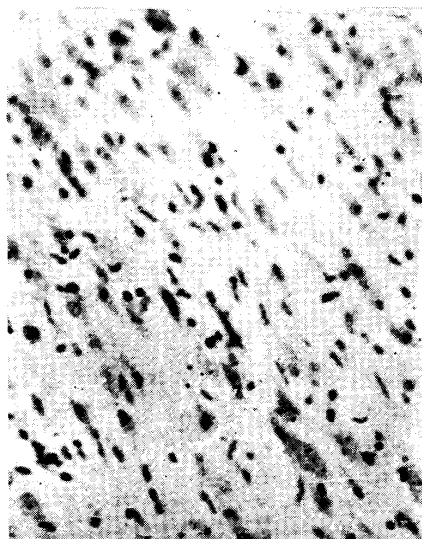
Diffused proliferation of rod cells was also seen in a few cases of Japanese equine encephalitis and rabies in considerably large area within a certain limitation (Figs. 3 & 4).

FIG. 3. *Japanese Equine Encephalitis*
(Horse)



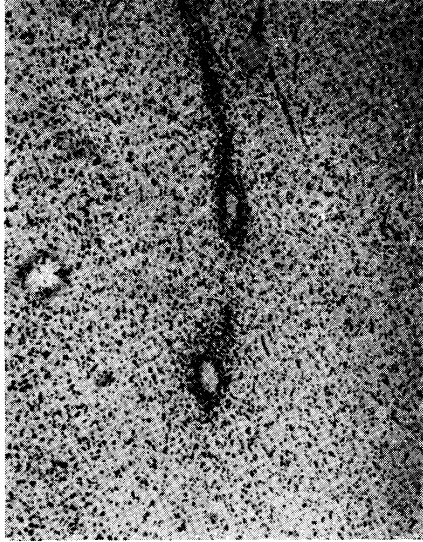
Rod cell proliferation in *hippocampus*. E. 203. NISSL.

FIG. 4. *Rabies Encephalitis* (Dog)

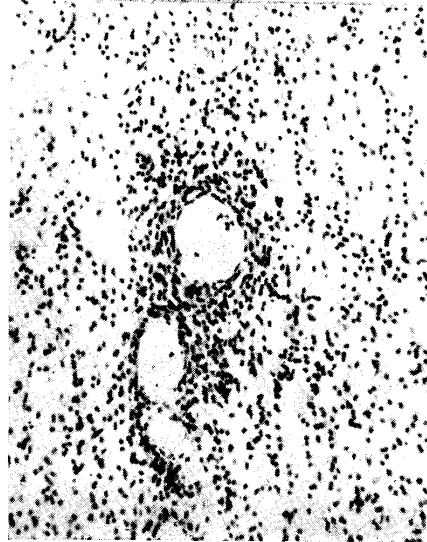


Vigorous proliferation of rod cells in cerebral cortex. No. 37. NISSL.

As one of the modes of glia cell proliferation, the perivascular type is known. The author has not yet found the pure form in encephalitis of domestic animals. This mode of glial proliferation is, however, well-known as a characteristic feature in such diseases as post-vaccinal and post-measled encephalitis (Figs. 5 & 6). At the focus of glial proliferation as shown by myelin sheath staining, the demyelination can be observed, but proliferative change is always more predominant than the demyelination and some cases are associated with round cell infiltration mainly comprising lymphocytes in perivascular lymph space. The relation between proliferative change and blood vessels is quite close and it has been reported that the sheath-shape proliferative figure of glia cells can be observed on serial sections right at the portion of vascular route. In other words, this mode of proliferation is remarkably different from that of nodular glia-proliferative focus, to be described below, in the relation between glial focus and blood vessel. Concerning the etiology of encephalitis of this type, on conclusive result has been obtained. It, however, can be said with some certainty that a sort of experimental encephalomyelitis obtained through the studies of KABAT et al., MORGAN and others since the experiments made on monkeys by RIVERS et al., shows considerable similarity to "Impencephalitis". It is very interesting that

FIG. 5. *Post-vaccinal Encephalitis* (Man)

Sheath-like proliferation of glia cells around small vessels in cerebral white matter. GUNTHER (Forschungsanstalt für Psychiatrie, 120/30). NISSL.

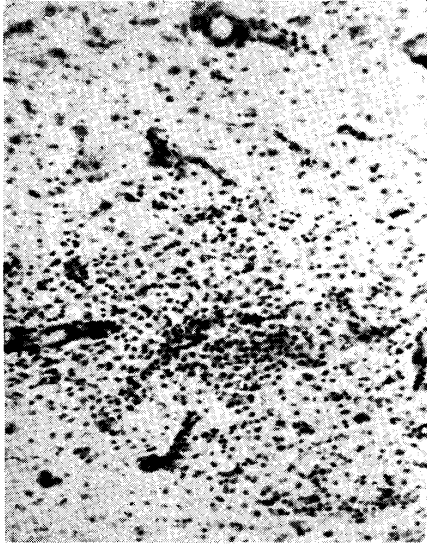
FIG. 6. *Post-vaccinal Encephalitis* (Man)

Perivascular glia proliferation around transverse sections of small vessel in cerebral white matter. GUNTHER (Forschungsanstalt für Psychiatrie, 120/30). NISSL.

W. SPIELMEYER, prior to the announcement of experiments on monkey by RIVERS et al., had emphasized that the "Impfencephalitis" is at least an encephalitis with specificity due to its characteristic lesions; further, he also considered an allergic mechanism and an activity of unknown viral agent in regard to the etiology. As to the encephalitis of domestic animals, the only finding obtained, at any rate, in the report of canine post-vaccinal paralysis concerning rabies by v. MÓCSY, JERVIS and others is similar to the description of "Impfencephalitis".

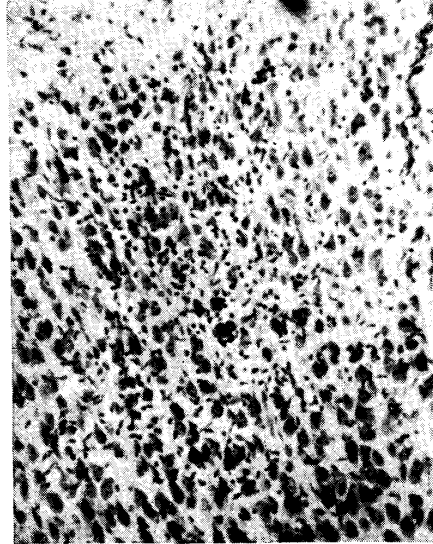
The glia cell reaction which is the most commonly observed in domestic animals is multiple focal glial proliferation. The author is now confirming the above fact with examples of Japanese equine encephalitis, rabies encephalitis, fowl plague encephalitis and listeriosis encephalitis. It is plain that the former three are provoked by viruses but listeriosis encephalitis is a bacillary disease. It is common that glia cell reaction appears as indistinctly demarcated spotted foci in the Japanese equine encephalitis and rabies, and in addition it associates with other inflammatory changes in most cases (Figs. 7 & 8). What is experienced together with this is nodular foci, of which the frequency of appearance seems to be less than that of the former. It is estimated that there are some foci which have plainly developed from neuronophagia but it is not always so (Figs. 9 & 10). The nodular glia foci of rabies will be discussed later.

FIG. 7. *Japanese Equine Encephalitis*
(Horse)



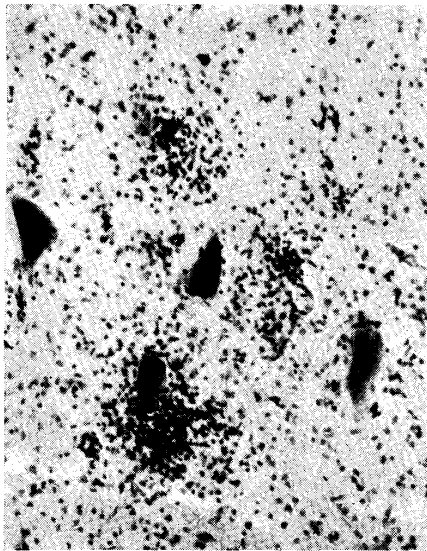
Patchy proliferation of glia cells in thalamic gray matter. Majority of glia cells with spherical shape. Pr. 2644. NISSL.

FIG. 8. *Rabies Encephalitis*
(Dog)




Patchy glia cell proliferation in cerebral cortex. Many rod cells and their round-shaped types. No. 99. NISSL.

FIG. 9. *Japanese Equine Encephalitis*
(Horse)



Nodular foci of glia cell proliferation in *intumescentia cervicalis* of spinal cord. Tendency of glia cell to form round type. Accompanied by small number of polymorphonuclear leucocytes. Pr. 2658. NISSL.

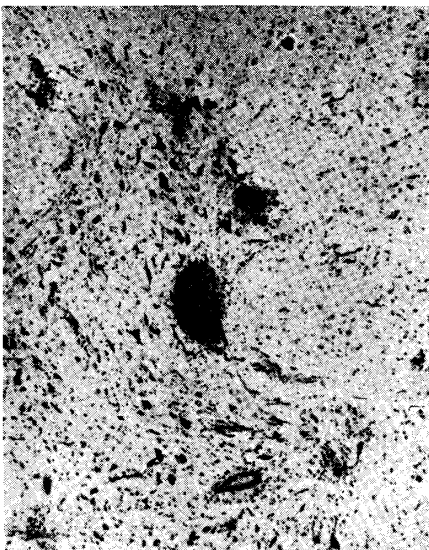
FIG. 10. *Japanese Equine Encephalitis*
(Horse)



Nodular glia cell focus in *mesencephalon*. Glia cells tend to round. Pr. 2841. NISSL.

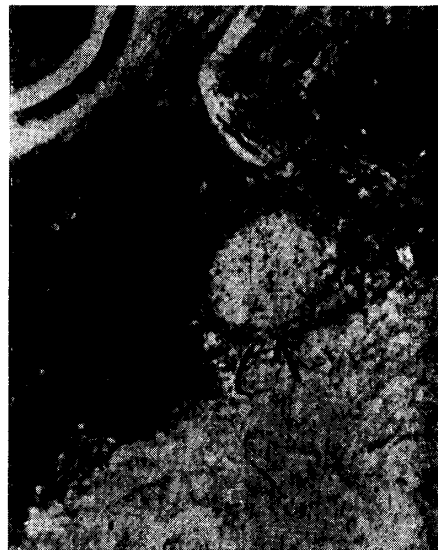What are now of the most interest are the histological changes in fowl plague encephalitis, in other words, multiple nodular glia proliferation; figure 11 shows the main features. However, it is limited, in most natural cases, and the indication of glia cell proliferation is very slight in the experimental case of initial passage and it cannot be proven except in a few cases. Demyelination is also proved at the same place of nodular foci in myelin sheath preparation but fatty destruction is very slight (Fig. 12).

FIG. 11. *Fowl Plague Encephalitis with Passage Virus*



Nodular proliferation of glia cells in the gray matter of spinal cord. Foci mainly composed of microglia cells contain oligodendroglia cells. Fairly large number of cells show karyorrhexis. D-strain, No. 873. NISSL.

FIG. 12. *Fowl Plague Encephalitis (Passage Virus)*



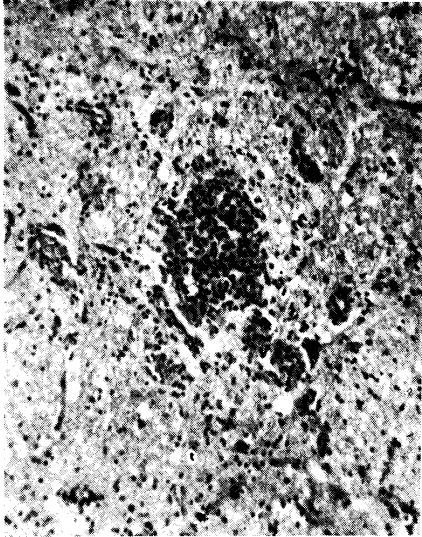
Demyelination at the nodular glia cell focus in the gray matter of *mesencephalon*. Chiba-strain, Pr. 3549. SPIELMEYER.

As to listeriosis, it is very hard to point out listeriosis when inflammatory changes are severe, but it is possible to identify glia cell proliferation as nodular or patchy foci of pure type depending on cases. The author considers it is worthwhile to draw attention because this lesion is attributed to bacilli (Figs. 13 & 14).

The above mentioned facts remind the author of the state of affairs which is experienced in the case of sepsis and endocarditis in the materials in human medicine.

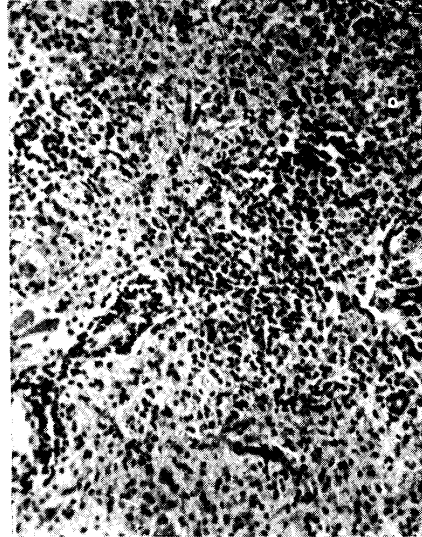
b) *The Case of Mild Glia Cell Reaction* First, hog cholera and rinderpest encephalitis can be used for comparison. Among other things, glia cell reaction including other inflammatory changes shows extreme weakness in the brain of

FIG. 13. *Listeriosis* (Sheep)



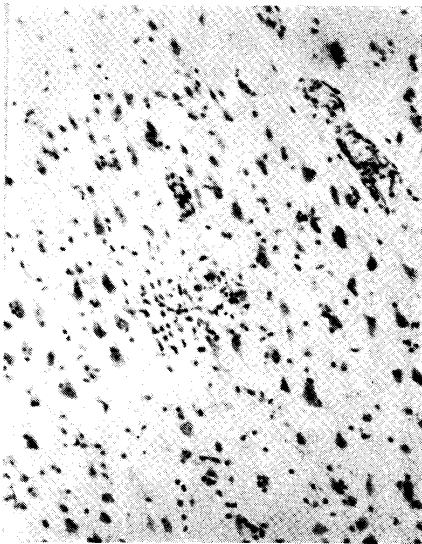
Pure nodular proliferation of glia cells in cerebellar white matter. Pr. 3307. Hematoxylin-eosin (H.-E.).

FIG. 14. *Listeriosis* (Sheep)



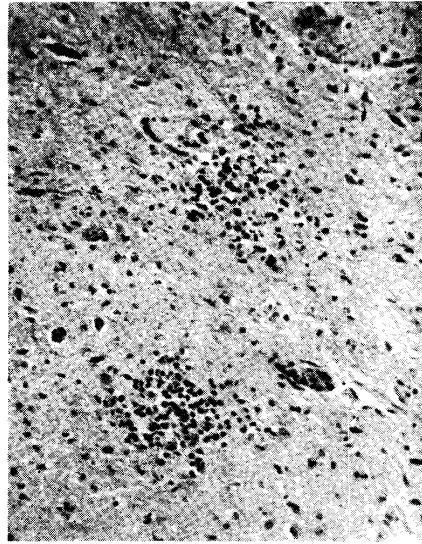
Patchy proliferation of glia cells in *medulla oblongata*. Foci made up of microglia cells and tendency of cells to form round types. Pr. 3304. H.-E.

FIG. 15. *Rinderpest Encephalitis*



Nodular glia cell focus composed of rod cells and its round shaped types. No. 600. NISSL.

FIG. 16. *Hog Cholera Encephalitis*



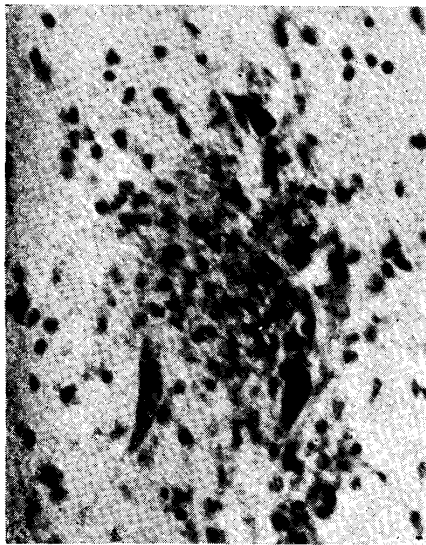
Nodular glia foci. Proliferated glia cells tend to round and some cells show karyorrhexis. Pr. 3180. H.-E.

rinderpest cases²⁾; there is similarly a low frequency of discovery of that reaction in the examined cases (Fig. 15). Therefore, the author cannot help hesitating to

put rinderpest in the same category with encephalitic disease. On the contrary, hog cholera³⁾ duly belongs to the encephalitic disease. However, amongst the inflammatory changes, it can hardly be said that glia cell reaction is predominant. It is not always easy to observe pure nodular foci by microscopy (Fig. 16).

The following are the findings on Newcastle disease. The author has previously stated that glia cell reaction is remarkably rare in field cases, also in the experimental case at the initial passage stage of fowl plague and that, in respect

FIG. 17. *Newcastle Disease Encephalitis (Passage Virus)*

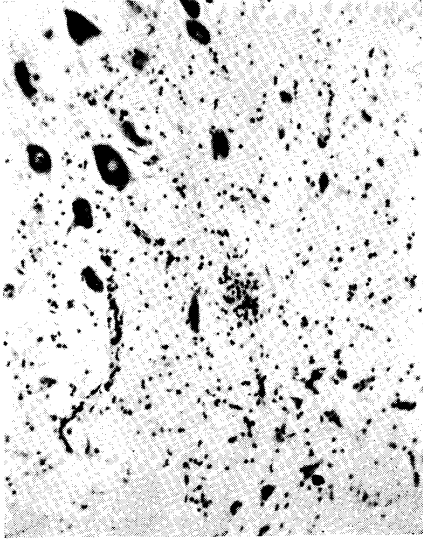


Nodular glia focus in *mesencephalon*. Proliferated cells tend to round. Phi-strain, No. 1155. NISSL.

to neurohistological changes, Newcastle disease is similar to fowl plague. According to the writer's experience, nodular foci which can be seen as typical in the fowl plague brain are exceptionally and very seldom observed and in addition the author was impressed that the most of the glia cell foci proved in those extremely few cases are poor (Fig. 17, cf. Fig. 11). At any rate, the author considers it noteworthy that the occurrence of glia cell reaction is one of the discrepancies of histological changes of central nervous system in the two similar infectious diseases. As to Newcastle disease, having no experience on the field case, the difference is not too clear to the author. Attention is drawn however to the fact that there plainly exists a remarkable pathological difference between the field case and experimental case inoculated with passage virus at least in the case of fowl plague.

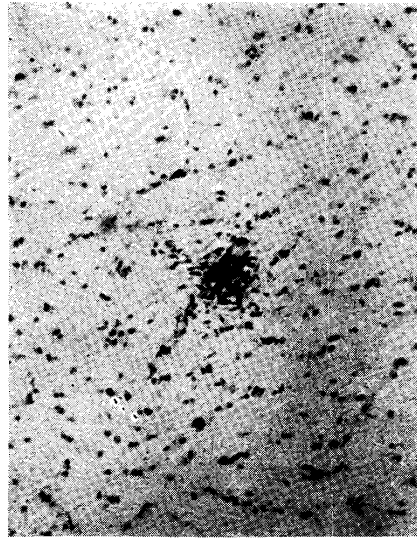
Rabies is considered to offer evidences similar to those above-mentioned.^{4,5)} As has been previously described, it is commonly known that most occurrences of glia cell reaction in the case of field rabies are recognized in the form of conspicuous patchy foci together with other inflammatory changes. But, contrary to the foregoing explanation, there is a wide difference in the one or two cases reported in literature, the findings of the author which were obtained in dead cases with paralytic symptoms resulting from vaccination and experimental cases inoculated with fixed rabies virus (dogs and calves). In other words, while inflammatory changes other than glia cell reaction are not worth consideration, glia cell reaction is also weak and it remains as much as can be done to point out minute nodular foci with difficulty (Figs. 18 & 19).

FIG. 18. A Case Died after Vaccination for Rabies



Nodular glioproliferation focus in cerebellar nucleus. No. 69. NISSL.

FIG. 19. Dead Case Inoculated with Rabies Fixed Virus (Dog)

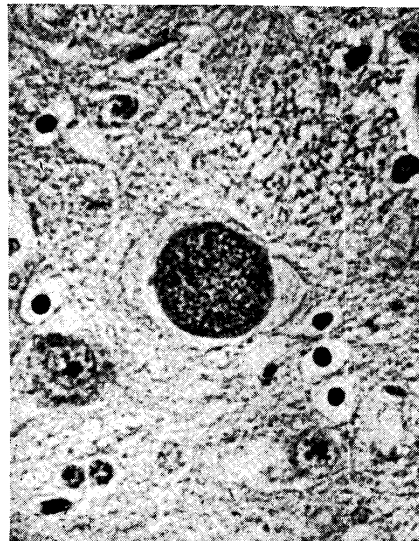


Nodular focus of proliferated glia cells in *medulla oblongata*. No. 9. NISSL.

It is worth-while, the author considers, to write about two or three histological changes in the brain of domestic animals which show slight glia cell reaction.

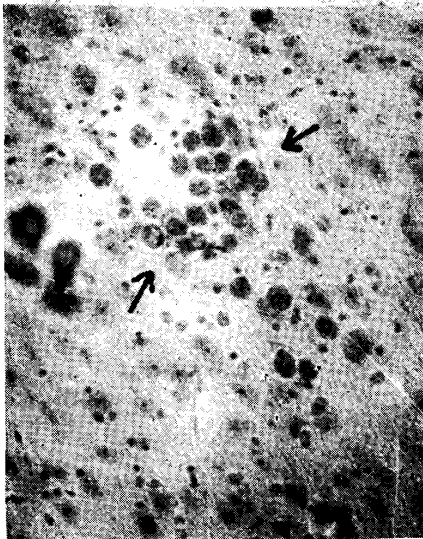
In the first place, a description will be presented of a brain invaded by *Encephalitozoon canis* (KANTROWITZ et LEWY) and a parasite which is similar to the former. The author has once stated that the histological change caused by parasites may have no relation with the respective encephalitic disease at the time when the histopathological changes occur in distemper and "epizootic fox encephalitis".⁶⁾ After that, P. COHRS⁷⁾ also reported about *encephalitis toxoplasmatica* in the case of dogs. The brain invaded by "parasites" which can be seen by microscope seems not uncommon to the author because many pathologists including himself have often encountered it in experimental animals such as dogs, rabbits and

FIG. 20a. Brain with Parasites (Sheep)



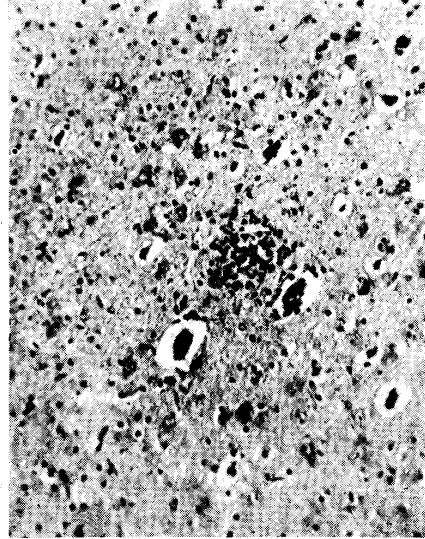
A parasite in cerebral cortex without histological reaction. Pr. 3485. H.-E.

FIG. 20b. *Canine Brain with Parasites*



Accumulation of parasites in cerebral cortex without histological reaction. 18'29 (Forschungsanstalt für Psychiatrie in München). H.-E.

FIG. 21. *Brain with Parasites (Sheep)*



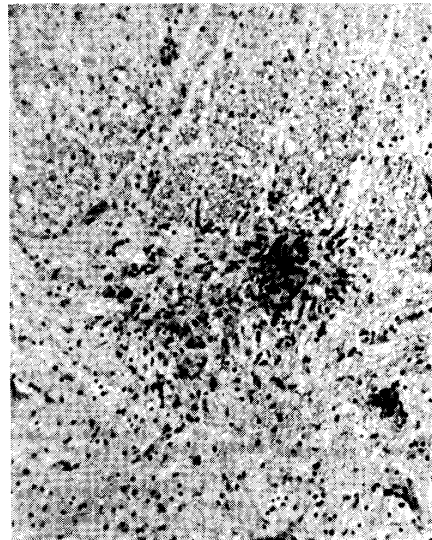
Nodular glia cell focus in the interior portion of cerebral cortex. Pr. 3485. H.-E.

FIG. 22. *Canine Contagious Hepatitis (H. c. c.)*



Nuclear inclusion body in an endothelial cell of blood capillary in cerebral tissue. Inclusion body is lightly acidophilic and irregularly elliptic. Pr. 3224. H.-E.

FIG. 23. *H. c. c.*



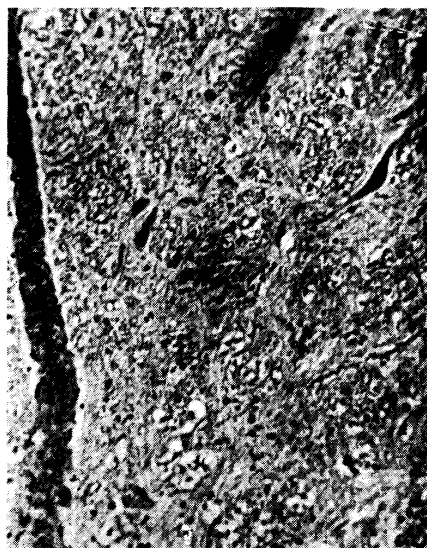Nodular glia cell focus in the gray matter of spinal cord. Pr. 3224. H.-E.

mice. The author has recently found the above-mentioned parasites in the brain of sheep; at that time it was observed that the tissue reaction was very slight and that there were only a few nodular glia cell foci though by microscopy parasites were found everywhere inside the brain (Figs. 20 a, 20 b & 21). Besides, the author also could observe the nodular glia cell foci together with the nuclear inclusion body in endothelia of blood capillaries, etc. in the brain of canine contagious hepatitis cases⁸⁾ (Figs. 22 & 23). Accordingly, although the author has been able to point out such glia cell reaction foci in his limited experiences regardless of what the etiological agent may be, it would not be proper, from the standpoint of clinical pathology, to categorize these diseases to encephalitic disease proper. This statement is in conformity with the findings in a brain of cattle with "bovine epizootic fever or bovine influenza" which has become as a problem recently in Japan. As was reported by TAJIMA and SUGANO⁹⁾ of this laboratory, minute nodular glia cell foci have already been proved in the brain stem of cases which manifested laryngo-pharyngeal paralysis that is clinically in close relation with this disease (Fig. 24). In this respect, various experiments have been directed to the isolation of the virus by many etiologists in Japan, but their clinicopathological findings are not so adequate as to satisfy the author and his co-workers. Therefore, it is not possible on the basis of present knowledge to identify what kind of etiological agent the cerebral lesion is connected with; it has already been stated by TAJIMA and SUGANO that the lesion, at least, is not sufficient to explain completely the remarkable symptoms of laryngo-pharyngeal paralysis.

After all, the present author considers that such above-described slight glia cell reaction appears even as local reaction not only in the encephalitic disease caused by virus but also in relation with other etiological agents. These facts have already been adequately described in the abundant records in the sphere of human medicine to which the author has previously made some reference. It is the author's desire to continue furthering knowledge in the cases of domestic animals.

As to the Mesodermal Reaction It is regarded that the mesodermal reac-

FIG. 24. *Bovine Epizootic Fever*

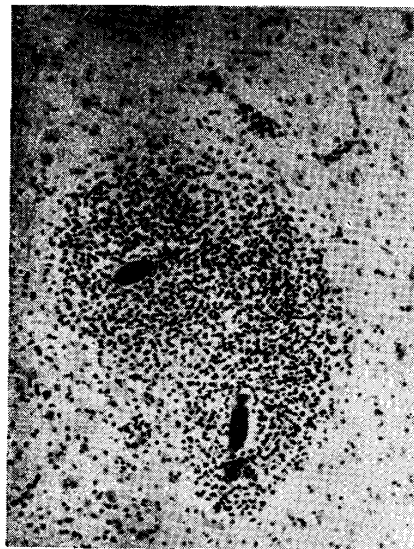

Nodular proliferation of glia cells in *medulla oblongata*.
No. 4. H.-E.

tion in the encephalitis of domestic animals, as far as our experiences are concerned, plays an important role within the histological inflammatory changes excepting the experimental cases by passage virus in fowl plague and rabies. This is why, in the field of veterinary pathology, the important changes of viral disease have been described in one text book after another under the diagnosed description of *encephalitis non-purulenta lymphocytaria*. The following are studies pertaining to the various kinds of mesodermal reaction in the domestic animals' cerebral lesion and also some discussion on the vascular connective tissue lesions in the diseases other than encephalitic disease such as those in the brain of equine infectious anemia.

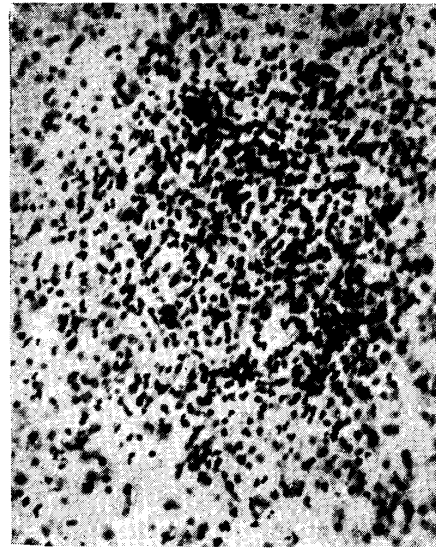
In the first place, some description will be made of the emigration of polymorphonuclear leucocyte to cerebral substance. The author has unfortunately not encountered many common suppurative encephalitic cases and what he actually knows are only the cases of strangles presented by TAJIMA and UEDA¹⁰⁾ of this laboratory and one each cases of dog and fox disseminated purulent encephalitis (Figs. 25 & 26). Purulent meningitis, however, has been experienced many times

FIG. 25. *Ecephalitis purulenta disseminata* (Dog)



Small abscess formation in *medulla oblongata*. Accompanying glia cell and bacillary emboli in the focus. No. 53. NISSL.

FIG. 26. *Encephalitis purulenta disseminata* (Fox)

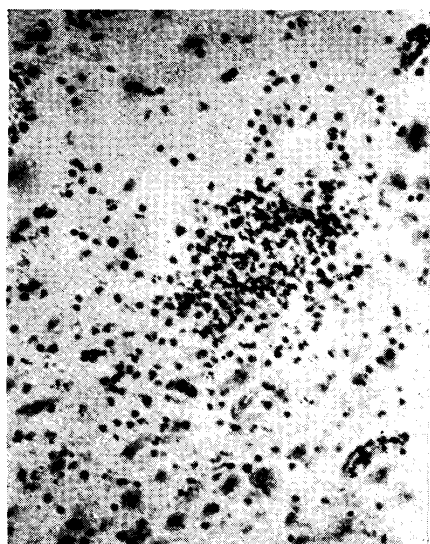


Fresh small abscess in *mesencephalon*. Glia cells lacking. Pr. 2609. NISSL.

in many kinds of animals. Anyway, the author admits the emigration of the normal polymorphonuclear leucocyte inside of the focus and at the portion of close contacted tissue regardless of cerebral substance and meninges so far as local or

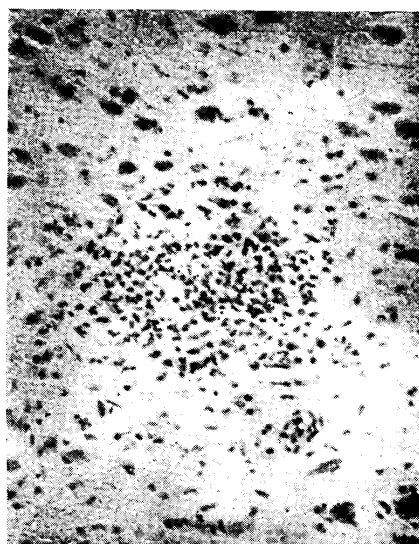
diffused suppurative foci are observed. There would be no problem in the foregoing stated findings due to the fact that it has already been proved clinicopathologically that they are, etiologically speaking, provoked by bacilli. Though the author is rather interested in the remarkable appearance of cerebral tissue reaction in two cases of disseminated purulent encephalitis, he could not have any chance to encounter the pure foci of glia cell accumulation as seen in the listeriosis encephalitis above mentioned. The author, at this juncture, would like to call attention to the emigration of polymorphonuclear leucocytes in Japanese equine encephalitis which according to the exhaustive studies of TAJIMA¹¹⁾ shows considerable indication in the initial stage of the contraction of the disease (Fig. 27). The author also has once experienced the emigration of polymorphonuclear leucocytes in an inoculated case with rabies fixed virus. In this case, it was

FIG. 27. *Japanese Equine Encephalitis* (Horse)



Diffused infiltration of polymorphonuclear leucocytes into the nerve parenchyma of temporal lobe cortex. Small abscess formation observable. E. 23. NISSL.

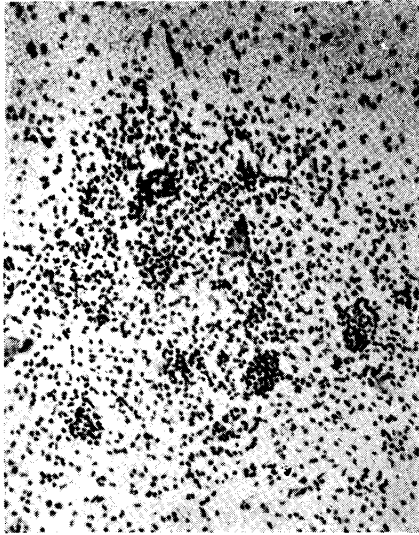
FIG. 28. *Canine Case Died after Vaccination for Rabies*



Infiltration of polymorphonuclear leucocytes in the cortex of parietal lobe. Emigration of polymorphonuclear leucocytes and small abscess formation with rod cell proliferation. NISSL.

noticed for two days between the contraction and death. Of course, there was no immediate relation between this feature and meningitis (Fig. 28). For reference, it may be said that the same feature was observed even in anterior poliomyelitis (Experimental case by FLEXNER; Fig. 29). Such emigration of leucocytes is always experienced also in human cases and it is very instructive that it should be re-

FIG. 29. *Poliomyelitis anterior*
(Experimental Monkey Case)



Polymorphonuclear leucocyte emigration in the anterior horn of spinal cord. Accompanied by glia cell proliferation and neuronophagia. 352/32 (Forschungsanstalt für Psychiatrie). NISSL.

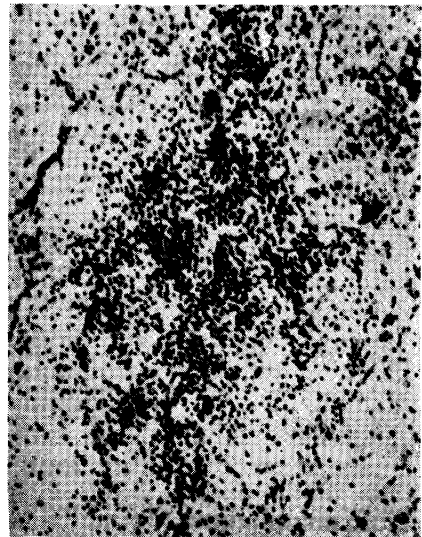
mesodermal cells and emigrated cells in vascular wall, perivascular lymph space and surrounding brain substance. It is common for the lesion to be formed regardless of the kind and size of blood vessel. It is well known that the histological change of this type, due to the fact that this change plays the main role in mesodermal reaction in many kinds of encephalitic diseases of domestic animals, has been considered important in the pathological diagnosis. However, in the animal inoculated by the passage virus of fowl plague and rabies fixed virus, this pathological change is either very slight or undiscernible under the microscope, and as already mentioned, it is the glia cell reaction that leads to the mesodermal reaction (Fig. 31). As to encephalitic disease

garded as one of the histological changes based upon virus infection.

Now, quoting purulent encephalitis, the author would give a short explanation of leucocyte emigration in listeriosis.¹²⁻¹⁴⁾ He has already explained how the participation of glia cell reaction in listeriosis and the emigration of leucocytes in listeriosis contributed greatly to forming essentially important tissue figure. It should not be overlooked that the emigration of leucocytes always participates in the changes exclusively without there being any rise or fall in their emigration which would correspond to the course of the changes as seen in inoculated case with rabies fixed virus (Fig. 30).

Vascular cell infiltration is the next topic which comes up for discussion. This is the lesion formed by locally proliferated

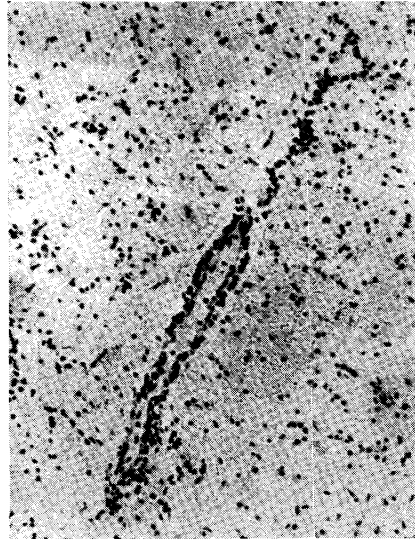
FIG. 30. *Listeriosis Encephalitis*
(Goat)



Emigration of polymorphonuclear leucocytes into nerve tissue in *mesencephalon* with mild proliferation of glia cell. Pr. 2670. NISSL.

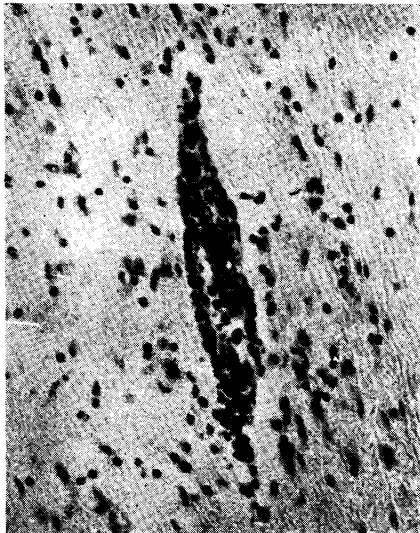
which is limited to each perivascular lymph lumen and of which the cellular proliferation and infiltration are not very active, the following can be used for reference: such as rinderpest (Fig. 32), hog cholera (Fig. 33), the field case of fowl plague (Fig. 34) and Newcastle disease (Fig. 35). However, these, due to the slight glia cell reaction as mentioned above, show a monotonic appearance of histopathological change, besides, the frequency of detection of this change is not high in the above-noted diseases except hog cholera. As to hog cholera, the ratio of detecting varies widely depending on the investigators but the investigation conducted by OHBAYASHI of this laboratory revealed that occurrence of encephalitic reaction reaches 94.4 % based on the material obtained from natural cases.

FIG. 31. *Canine Case Died after Rabies Vaccination*



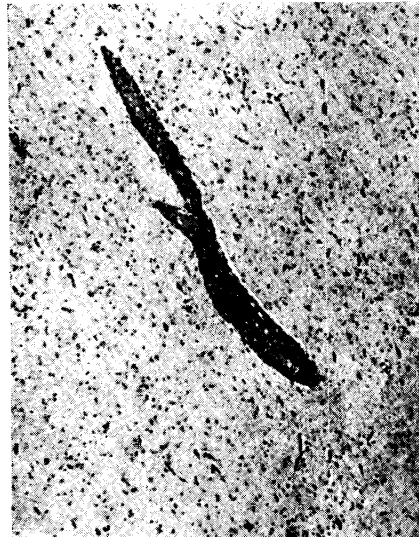Vascular cell infiltration in *medulla oblongata*. No. 68. NISSL.

FIG. 32. *Rinderpest Encephalitis*



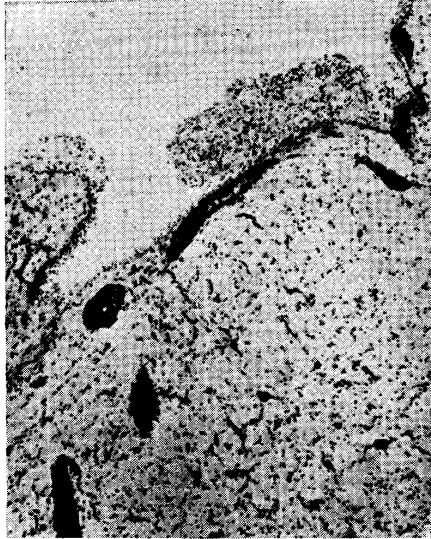Vascular cell infiltration in the posterior root of spinal cord. Accompanied by plasma cells. No. 599. NISSL.

FIG. 33. *Hog Cholera Encephalitis*



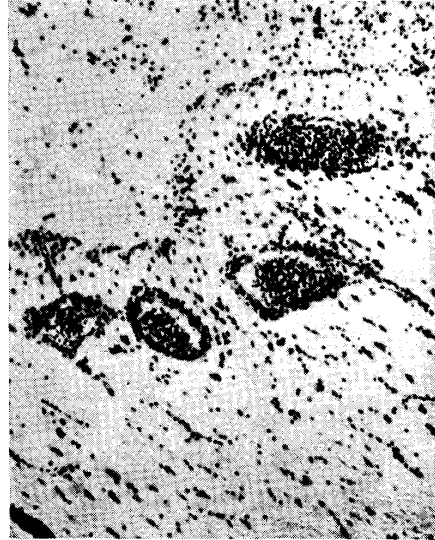
Vascular cell infiltration in *mesencephalon*. Main element with mononuclear round cells. Pr. 3193. H.-E.

FIG. 34. *Field Case of Fowl Plague*



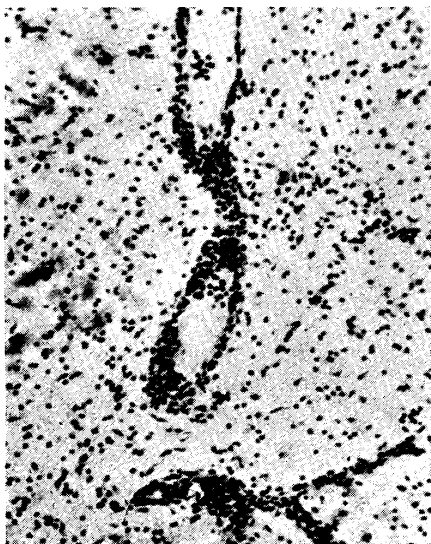
Vascular cell infiltration in *medulla oblongata*. Rich in plasma cells. No. 330. NISSL.

FIG. 35. *Newcastle Disease Encephalitis (Passage Virus Case)*



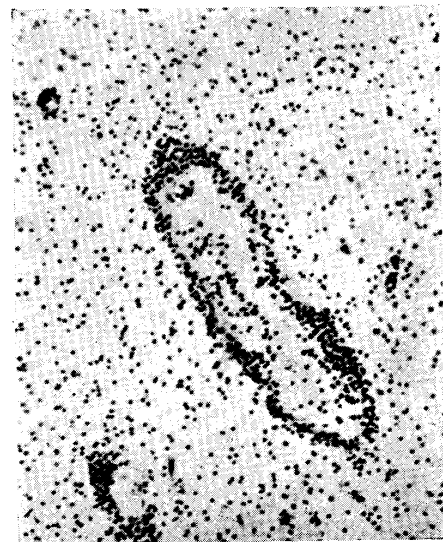Vascular cell infiltration in *mesencephalon*. Mainly composed of mononuclear round cells. Phi-strain, No. 1067. NISSL.

FIG. 36. *Rabies Encephalitis*



Vascular cell infiltration in *corpus striatum*. Pavementlike arrangement of plasma cells in perivascular lymph spaces. Mild glia cell proliferation in surrounding tissue. No. 12. NISSL.

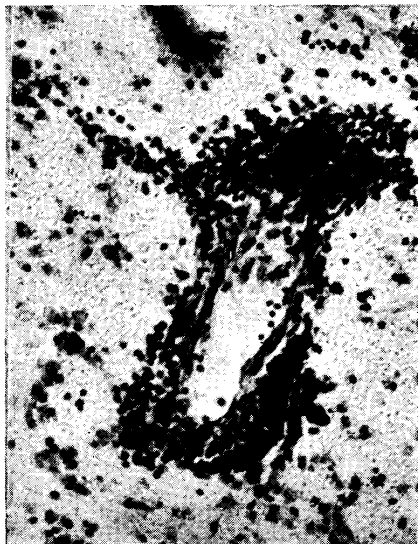
FIG. 37. *Japanese Equine Encephalitis (Horse)*



Vascular cell infiltration of congested vein branchlets in cerebral white matter. Associated with large number of polymorphonuclear leucocytes. E. 23. NISSL.

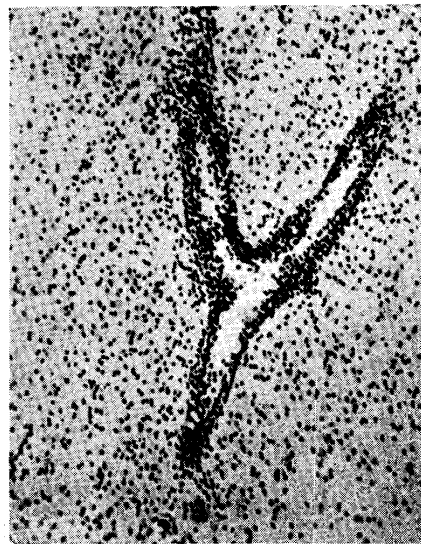
As the encephalitic disease of domestic animals in which cerebral lesion is fairly severe and which especially accompanies the perivascular cell infiltration, there are the Japanese equine encephalitis and field case of rabies. Due to the fact that the participation of glia cell reaction in focus formation is seen in many cases among them, histopathological findings are likely to cause remarkable complication. However, the monotonic histopathological changes are also sometimes encountered depending on examined case or locality of foci (Fig. 36). The cells which infiltrated perivascularly mainly consist of lymphocytes, plasma cells and large mononuclear cells but the remarkable participation of polymorphonuclear leucocytes has been seen in the leucocytic stage of the Japanese equine encephalitis and rabies (Figs. 37 & 38). The emigration of infiltrated cell into tissue,

FIG. 38. *Japanese Equine Encephalitis* (Horse)



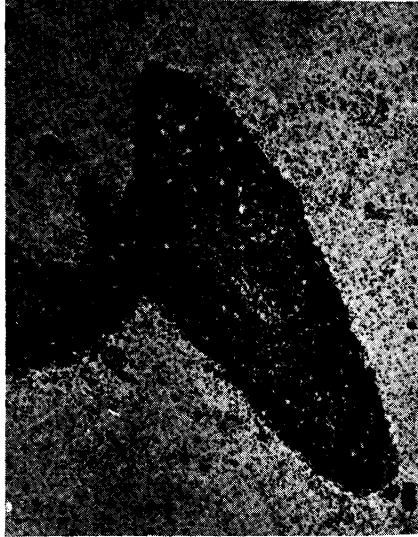
Vascular cell infiltration in *medulla oblongata*. Emigration of lymphocytes and plasma cells surrounding a small blood vessel. Pr. 2668. NISSL.

FIG. 39. *Rabies Encephalitis* (Dog)

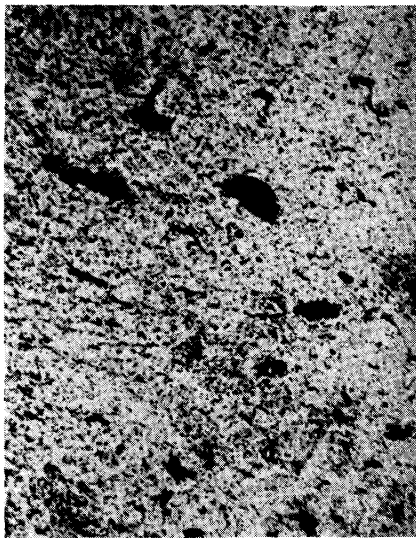


Vascular cell infiltration in *medulla oblongata*. Many polymorphonuclear leucocytes in perivascular lymph space and surrounding tissue. No. 37. NISSL.

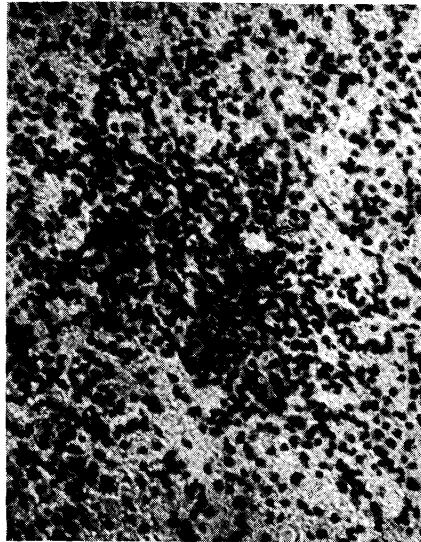as has already been described by TAJIMA on the Japanese equine encephalitis, is seen around the fine blood vessels of the gray matter on a small scale. It is normally hard to recognize an example in which infiltrated cells emigrate into nerve tissue in the case of a relatively large diameter artery which goes through white matter despite the fact that the perivascular lymph space is remarkably dilated by the infiltrated cells (Fig. 39). In order to explain the above description, the author here introduces a preparation of Borna disease which is a similar infectious disease (Fig. 40). This preparation is one of two cases supplied by Prof.

FIG. 40. *Borna Disease Encephalitis*

Vascular cell infiltration in the interior layer of cerebral cortex. Perivascular lymph space dilated by infiltrated cells. Cell accumulation in surrounding brain tissue is the cellular tissue infiltration of perivascular type around fine blood vessels. No. 3028 (Forschungsanstalt für Psychiatrie). NISSL.

FIG. 41. *Listeriosis Encephalitis*

Vascular cell infiltration in *medulla oblongata*. Many large or small abscesses indicated in the left half of visual field. Vascular cell infiltrations observable only in the right half. Tissues surrounding infiltration almost inactive. E. 218. NISSL.

Fig. 42. *Listeriosis Encephalitis*

Emigration of polymorphonuclear leucocytes into pontine parenchyma with glia cell proliferation. Almost scanty perivascular cell infiltration. Pr. 2670. NISSL.

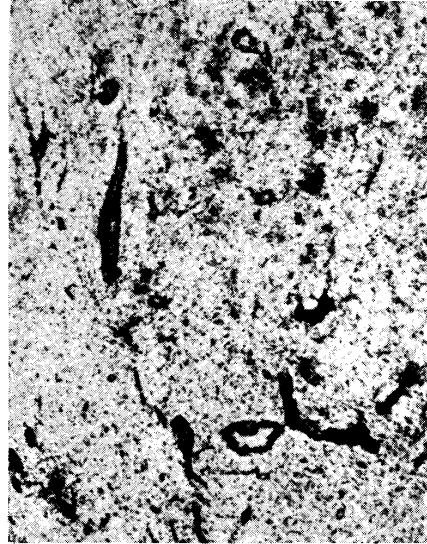
SPATZ. Diffuse proliferation of the rod cells was remarkably vigorous in this case. The predominant vascular cell infiltration is also observed in listeriosis. There is some need however to offer an explanation of the histopathological analysis of necrotic and destructive foci because there are some other things to be considered (Figs. 41~43).

At this juncture, the author feels a necessity to describe the neuropathology in equine infectious anemia.¹⁵⁾ This is because, in the first place, perivascular increase of cells is the foundation of cerebral changes and secondly, pathologists throughout the world have been interpreting cerebral change of equine infectious anemia as encephalitis on and after HOLZ, except TRAUTWEIN et al.¹⁶⁾ The author feels it is not necessary to explain his idea in detail since it has already been discussed in the report drafted

by the author and TAJIMA. In a word, as the perivascular increase of cellular

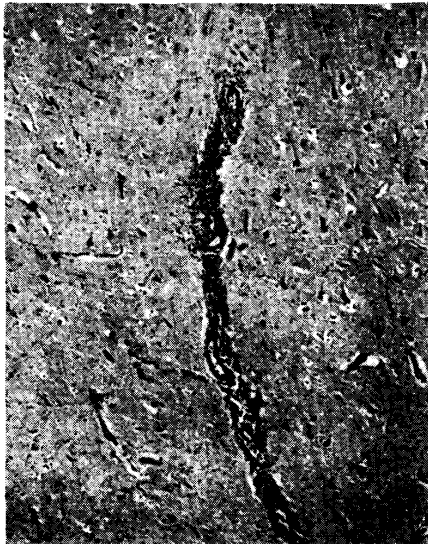element in the cerebro-spinal change of equine infectious anemia is seen in the medium and small branch arteries, it is clear at a glance under the microscope that there is much difference between the vascular cell infiltration of the Japanese equine encephalitis, rabies, etc. and that of the neurohistological change of equine infectious anemia. In addition to the above, the activity of glia cells, in glia cell reaction, which occurs in cooperation with the degenerative change of surrounding tissue based on the affection of cell increase is only recognizable (Figs. 44 & 45). As in the foregoing explanation, this is why the author defined the histological changes of brain in equine infectious anemia cases as a systemic simple proliferation which can be recognized

FIG. 43. *Listeriosis Encephalitis*




Vascular cell infiltration in the tissue adjacent to that shown in figure 42. Lymphocyte emigration and glia cell proliferation in perivascular tissue. Pr. 2670. NISSL.

FIG. 44. *Equine Infectious Anemia*



Increase of cells surrounding a small artery in brain basis cortex. T. 92. H.-E.

FIG. 45. *Equine Infectious Anemia*

Periaxonal cell increase with demyelination in the white matter of temporal lobe. Pr. 2597. SPIELMEYER.

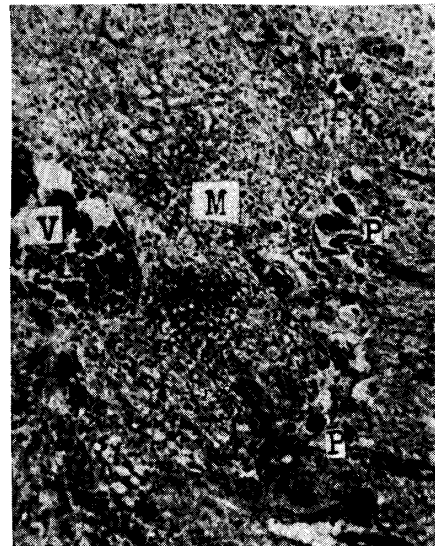
of the cases of both disease. However, it was ascertained that the mesodermal reaction, just like the case of glia cell reaction, is very weak except in the *pia mater* and parenchyma where enormous numbers of parasites were accumulated; the author has without any doubt noticed parasite or nuclear inclusion body within tissue on many occasions. Consequently, the author considers that parasite and nuclear inclusion body will not cause each independent encephalitic disease from the view point of neurohistopathological findings as already described together with glia cell reaction (Fig. 46, cf Fig. 20).

Necrotic Focus and Destructive Focus

The author has, on the preparation of encephalitis of domestic animals, encountered various sorts of circumscribed foci in respect to size of which the inflammatory reaction had participated in the fundamental focal

in the lympho-reticular tissue of periphery of artery and brain ventricular wall the same as in other organs and tissues. The author, therefore as a matter of course, leaves equine infectious anemia out of the group of encephalitic diseases in the discussion of the encephalitis of domestic animals in this paper.

Apropos of this juncture, the author will offer a word about the mesodermal reaction in parasite harbour or the brain of canine contagious hepatitis which have been previously explained. As for canine contagious hepatitis a detailed report will be published by FUJIMOTO of this laboratory. Anyway, the present author could observe the local hyperplastic focus of wall tissue of small blood vessel which mixed emigrated cell element in parenchyma and even *pia mater*

FIG. 46. *Toxoplasmosis* (Dog)

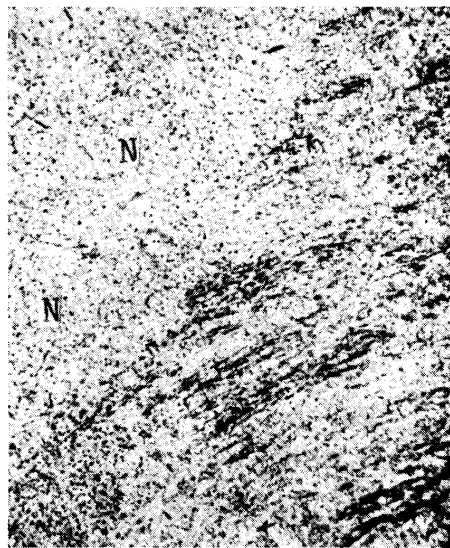
Parasites (P) in cerebral meninges. Severe exsudative meningitis (M) and dilated blood vessel (V). Pr. 822. H.-E.

necrosis and which can be found only under microscope. In addition, focal necrosis has been examined in various diseases of domestic animals other than encephalitic diseases of which the causes were unknown in most cases. However, as to the histogenesis of focal necrosis, a causal factor has been considered morphologically and functionally to depend upon the changes of blood vessels in the focus and locality or figure of the discovered foci. On the other hand, it should be realized that some cases exist in which it may not be possible to obtain a firm conclusion on matter how much study is devoted in an attempt to ascertain their causal factor. It should be kept in mind that the above-described perivascular lesion of "Impfencephalitis" and the focal glia cell reaction of Japanese equine encephalitis and rabies never fail to accompany demyelination phenomenon, but in these cases a fundamental factor of the histological picture is attributed to inflammatory tissue reaction.

To cite an instance, necrotic focus was found in three cases among 56 of Japanese equine encephalitis which occurred in Hokkaido. In the case shown in the figure, the circumscribed wet gelatinous focus was detected even macroscopically; it was yellowish gray in color with some transparency, clearly demarcated, little-finger tip in size and localized at the portion from *nucleus medialis thalami* to *nucleus lateralis thalami* of right cerebral hemisphere. Under microscope, a complete encephalomalacia was confirmed (Fig. 47). The other two cases showed wide necrobiotic focus which were observed in the cortex of *lobus frontalis* but no practical clearing process was observed. It is very interesting that an appearance of necrotic focus shows remarkable frequency in the case of human Japanese B encephalitis which is provoked by the same causal virus as Japanese equine encephalitis and has generally multiple character of occurrence of foci. Fortunately

necrotic foci are found in the brain of three human encephalitis cases which were presented by Dr. M. HAYASHI of Okayama Medical College about 10 years ago through Dr. INADA, chairman of the Encephalitis Research Committee. For the

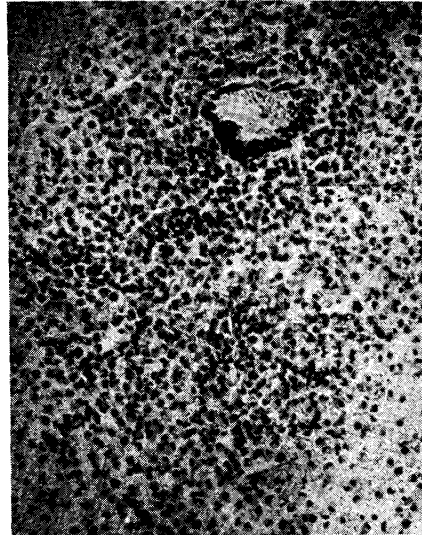
FIG. 47. *Japanese Equine Encephalitis*
(Horse)



Malactic focus (N) in thalamic gray matter with the accumulation of compound granule corpuscles. Vascular cell infiltration exists in the focus. Pr. 3023. SPIELMEYER.

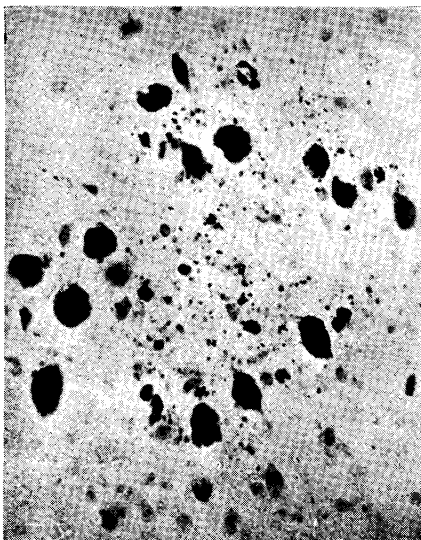
sake of comparison and reference one case is illustrated (Fig. 48). The author also added a picture of preparation of *encephalitis lethargica* ECONOMO to that of Japanese B encephalitis. The degenerative change appearing in *substantia nigra* in this encephalitic change is likewise regarded as a particularly important finding in relation to clinical symptoms (Fig. 49). Furthermore, reference to necrotic focus in the brain of Newcastle disease can be made. The author has investigated approximately 300 cases of fowl plague and Newcastle disease, but the brains with a pathological change which is considered to be the primary necrotic focus, as previously mentioned, were observed in only a few cases. In the figured focus (Fig. 50), there was a predominant participation of

FIG. 48. *Japanese B Encephalitis*
(Man)



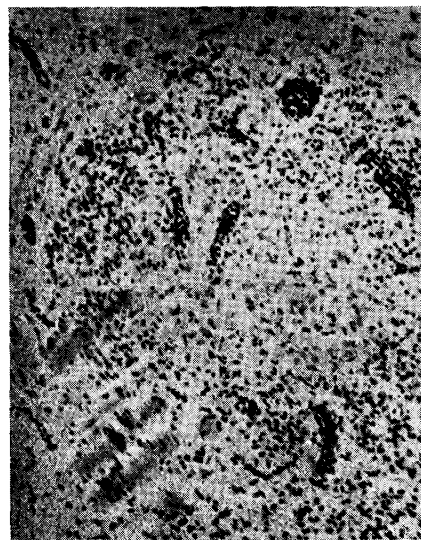
A malactic focus in *thalamus*. Vascular cell infiltration observable within the focus composed of compound granule corpuscles. SATO (Okayama Medical College). NISSL.

FIG. 49. *Encephalitis lethargica*
(Man)



Scattered black granules and granulo-phagocytic round cells indicating the necrosis of nerve cell in *substantia nigra*. KRENN (Forschungsanstalt für Psychiatrie). NISSL.

FIG. 50. *Newcastle Disease Encephalitis by Passage Virus*



A necrotic focus in *mesencephalon*. Phi-strain, No. 1675. NISSL.

proliferation of neuroglia and it already developed to a sclerotic focus in view of the cell analysis. In addition, malactic focus in different stage can be pointed out depending on changes. The author has also encountered a malactic focus in listeriosis similar to the preceding (Figure follows).

The above show the true aspect of necrotic foci which were observed by the author during the studies on the encephalitic diseases of domestic animals. As to causal genesis, an explanation is offered following the pathological changes in domestic animal cases which do not belong to encephalitic disease. However, it should be stressed that the above described necrotic focus has, as a peculiarity, a main causal factor in degeneration and necrosis, and glio-mesodermal reaction is no more than playing a secondary role despite the fact that the participation of degenerative mechanism in the local lesion is observed such as in the glia cell reaction of Japanese equine encephalitis, rabies, listeriosis, fowl plague and Newcastle disease, and also in small abscess of listeriosis and other cases.

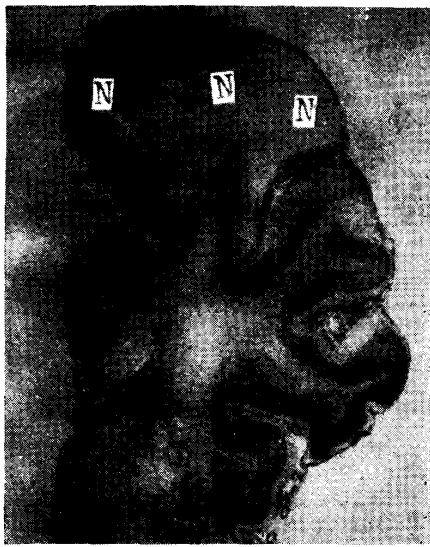The following is a comment of focal necrosis which is experienced in the investigation which showed no indication of encephalitic changes as histological findings. The comment has no relation with neuropathology of encephalitis of domestic animals, but since infectious disease, intoxication and deficiency disease have been pointed out as a cause of focal necrosis by many investigators, the author would like to describe the results obtained in his experiences in order to contribute to the etiological discussion of the unknown cause of encephalitic disease which will follow in the later part of this paper.

J. R. M. INNES¹⁷⁾ has suggested that his pathological investigation conducted on the sway back of lamb and distemper encephalitis was to a certain degree encouraging to the etiological study on human multiple sclerosis. The present author, however, has no intention to propose a solution of causal genesis so hastily as INNES who put a wide construction upon these diseases interpreting them as demyelinating diseases.

The author in the first place, will begin with those which are lacking in morphological change by which an adequate explanation can be given to the genesis of focal necrosis in nerve tissue. As to changes of this kind, they have been discussed for many years in human cerebral disease developing from infectious disease and intoxication as well as genuine epilepsy, symptomatic epilepsy, eclampsia, etc; in the domestic animals, the matter was once discussed by the present author in a report of which the subject was distemper encephalitis which belongs to encephalitic disease. Afterwards, together with TAJIMA,¹⁸⁾ the author made a detailed report as to encephalomalacia of sheep of which mass occurrence was observed in Manchuria and of horse experienced sporadically in Hokkaido; later cases were experienced in sheep and fox. The author feels no necessity to

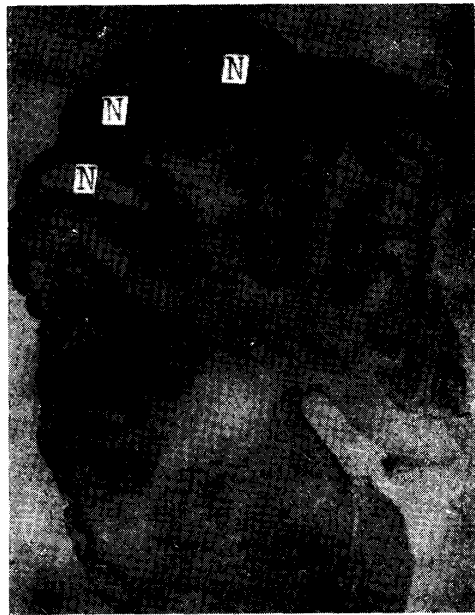
describe the histological changes in detail at this juncture but on the whole, a commonly obtained finding as a cerebral lesion is focal necrotic change which occupies the *pallium*, *cerebellum* and brain stem. In addition, according to the sequence of new and old changes, the focal lesion originates in a clearly demarcated focus of pallidness (Erbleichung SPIELMEYER's), then develops to the participation of various degrees of glio-mesodermal tissue reaction and finally develops into entirely necrosed focus (Figs. 51 & 52). In a sheep case, the author was able to

FIG. 51. *Encephalomalacia* (Sheep)



Cortical necrosis (N) in *lobus parietalis* lacking in marginal reaction. No. 15. NISSL.


FIG. 52. *Encephaloma'acia* (Sheep)



Cortical necrosis (N) in *lobus parietalis* with remarkable glio-mesodermal reaction at the periphery of focus. No. 13. NISSL.

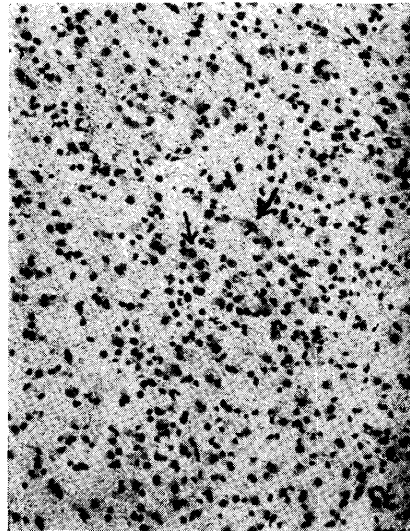
point out the *hippocampus* and cerebellar cortex as favorite localization points of lesions (Fig. 53). The author has adopted the theory of local functional disturbances of blood circulation as a cause of focal necrosis in agreement with SPIELMEYER. TAJIMA, in regard to the genesis of focal necrosis in Japanese equine encephalitis, adopts the same theory. As to the genesis of focal necrosis observed in the cerebral lesion shown above in the figures, there seem to be the same genesis as in cases of disturbances of blood circulation. The author, however, does not intend to adopt this histogenesis without deep consideration. Taking this opportunity, a preparation of a funicular spinal disorder (Funikuläre Spinalerkrankung, PAVIAN) of baboon will be presented as a reference; it was not actually studied by the author. This is a case of focal necrosis which is seen in the white

FIG. 53. *Encephalomalacia* (Sheep)



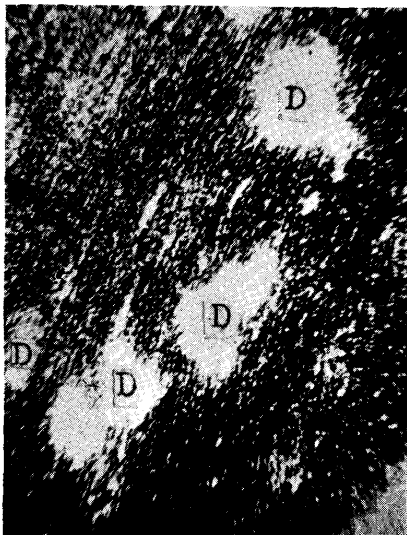
Widely distributed necrosis (N) in the pyramidal cell layer of *hippocampus*. No. 293. NISSL.

FIG. 54. *Funicular Spinal Disorder* (Funiculäre Spinalerkrankung PAVIAN) (Baboon)



Focal necrosis in cerebral white matter. Neuroglia cell proliferation (↑) with small number of glia cells. 7/32 (Forschungsanstalt für Psychiatrie). NISSL.

FIG. 55. *Funicular Spinal Disorder*



Focal necroses in cerebral white matter. Demyelination (D). 7/32 (Forschungsanstalt für Psychiatrie). SPIELMEYER.

FIG. 56. *Funicular Spinal Disorder*



Demyelination (D) in a portion of focal necrosis in the white matter of spinal cord. 7/32 (Forschungsanstalt für Psychiatrie). SPIELMEYER.

matter of the *telencephalon* and spinal cord. The both cases show demyelination but proliferation of glial tissue is not remarkable (Figs. 54, 55 & 56, cf. Fig. 50).

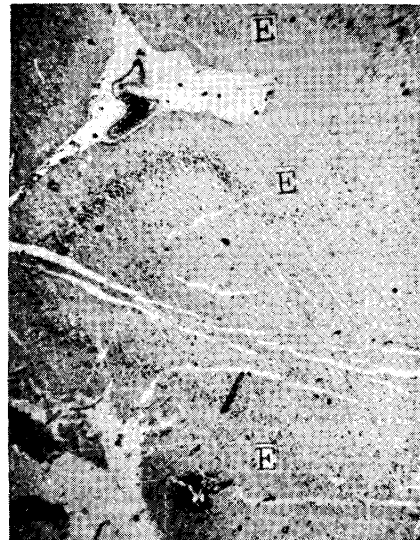
The following are findings obtained in the cases of fox and lion in which focal necroses and lesions of blood vessel wall as the morphological changes were simultaneously observed. As to the case of fox, FUJIMOTO of this laboratory is yet to announce his report but findings as to the case of lion have already been reported by OHBAYASHI and FUJIMOTO¹⁹⁾. For the case of fox, findings on 6 cases which died chiefly from so-called epilepsy are cited. The characteristic of changes is focal necrobiosis which belongs to focal pallidness (*Erbleichung*) and sometimes accompanies slight glio-mesodermal tissue reaction. With respect to the localization of lesion, it was always found in cortex of *gyrus rhinaria* and *corpora quadrigemina posterior* and was often recognized also in the dorsal and dorso-internal areas of *pallium*. As one special character of this studied case, there is degeneration of the wall of medium-sized blood vessels found within foci with hemorrhage; the degenerative blood vessels were observed as being embedded in hemorrhagic portion. However, since vascular changes are not always located in the portion with focal necrosis, it would be an appropriate thing to consider them together with the local functional disturbance of blood circulation in searching for a causal factor of focal necrosis (Figs. 57 & 58). In the case of lion, it is clearly known that repeated epileptic fits occurred before the death. The focus was as large as a rice grain showing slight yellowish brown or reddish brown

FIG. 57. *Encephalomalacia* (Fox)



Necrotic focus. Focal pallidness (*Erbleichung* SPIELMEYER's) in cerebral cortex. E. 1305. H.-E.

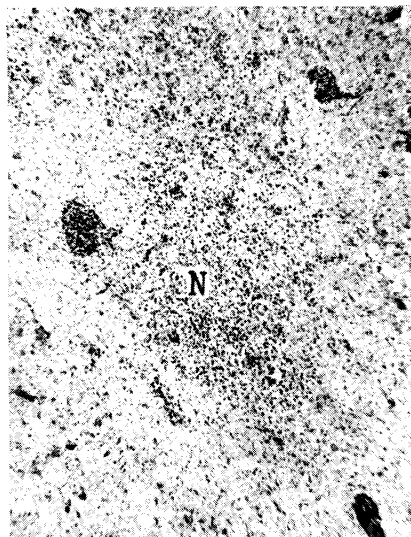
FIG. 58. *Encephalomalacia* (Fox)



Focal pallidness (E) in cerebral cortex. E. 1307. H.-E.

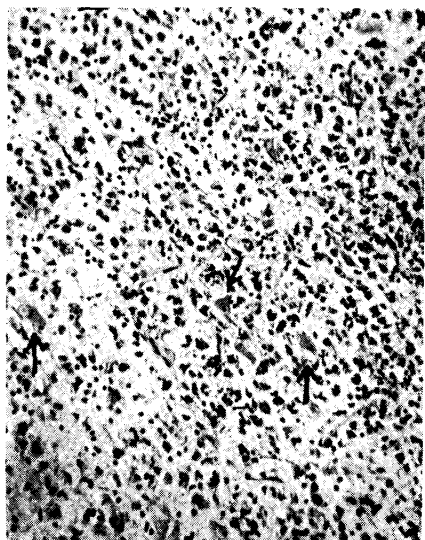
and more than twenty were counted. Many were observed between the deep layer of cerebral cortex and white matter, but were not found in brain stem. Sclerotic focal change participated in by glio-mesodermal reaction comprised the main body histopathologically (Figs. 59, 60 & 61). Though the foci generally retain a trace of hemorrhage, half cavernous foci are also noticeable. Atheromatous change is not found in any part of cerebral and meningeal blood vessels, however, the author sometimes encounters such in the periphery of medium-sized vessels which develop to the edematous change and of which the wall was thickened fibrously. As the dilatation of cerebral ventricles and increase of volume of cerebral fluid are conspicuous, the investigators have been indirectly attaching great importance to disturbance of the central blood circulation in explaining the genesis of focus.

FIG. 59. *Encephalomalacia* (Lion)



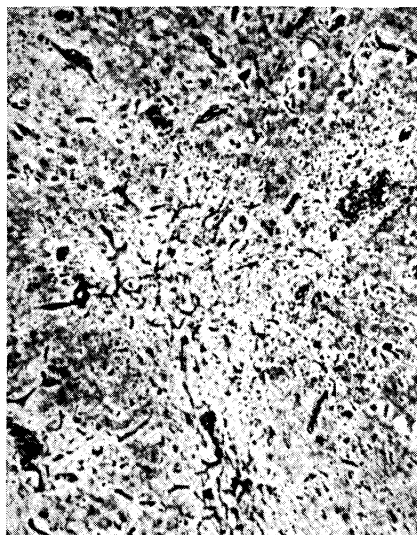
Focal necrosis (N) in the white matter of temporal lobe. Abundant siderocytes and compound granule corpuscles in the focus. Remarkable neuroglia cell proliferations interior and exterior of the focus. Lymphocyte infiltration at perifocal blood vessels. Pr. 3409. MALLORY.

FIG. 60. *Encephalomalacia* (Lion)



Necrotic focus. Macroglia proliferation (↑) within the focus shown in figure 59. Pr. 3409. MALLORY.

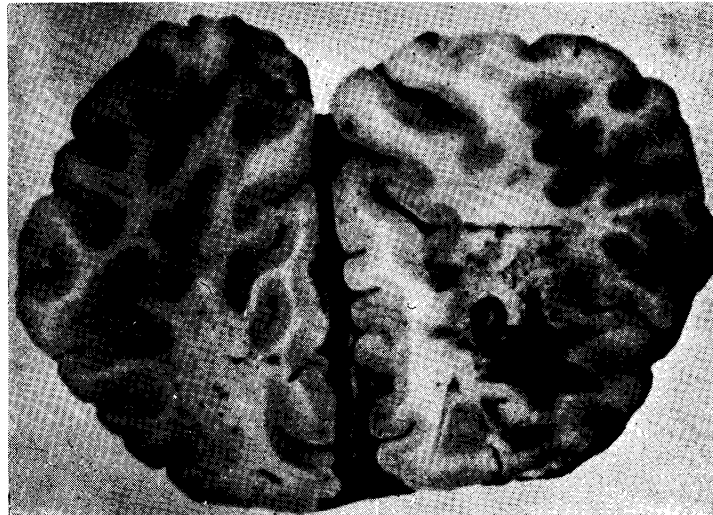
FIG. 61. *Encephalomalacia* (Lion)



Necrotic focus. Increase of argyrophilic fibers within the focus shown in figure 59. Pr. 3409. BIELSCHOWSKY.

The following is a presentation of the present author's views on destructive focus. An elemental factor of cerebro-spinal lesion in lumbar paralysis of sheep and staggers of horse,²⁰⁾ which was briskly discussed by the investigators in Pusan and Tokyo over ten years ago, is this very destructive focus now under consideration. It is only observed as a fine circumscribed focus with somewhat of wetness and a light yellowish-brown color in the white matter on the cross section of spinal cord, but in *medulla oblongata*, *cerebellum* and *cerebrum*, a relatively large-sized substance-defected focus accompanied by hemorrhage is often encountered. As a histological finding, sharply demarcated cavern and fissure formation is noted as an outstanding characteristic. However, within the lumina of such cavern and fissure, detrited substance mixed with fragments of blood vessel and other things such as compound granule corpuscles, erythrocytes and eosinophiles are retained. If fortunate, the student is able to detect larva of nematode macro- or microscopically in the portion of focus of substance defect (Figs. 62~64).

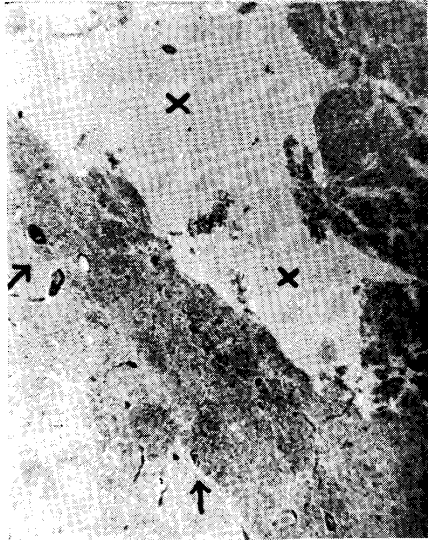
FIG. 62. *Setariasis* (Horse)



Destructive focus on a frontal cut surface of *telencephalon*. A parasite (*Setaria digitata*) and a cavern with hemorrhage in white matter.

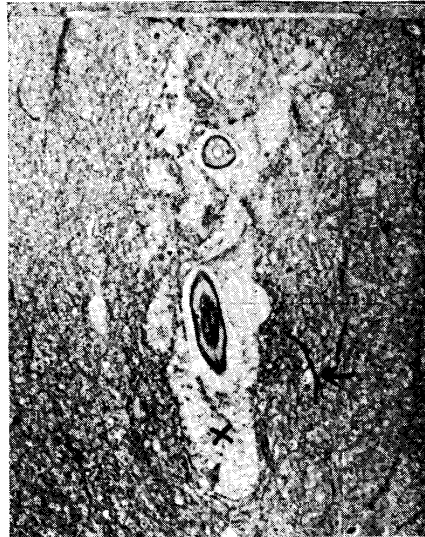
The ratio of such discovered cases is much less in spinal cord than in brain. To date the present writer has not met with a favorable opportunity to observe a case with remarkable lesion of brain stem, etc., and rapid mortal course in the investigation of lumbar paralysis. Also, the author has an experience not to find the parasite microscopically for a long time which fact may be attributed to the fact that the object of investigation was mainly the lesion of spinal cord. At

FIG. 63. *Setariasis* (Sheep)



Destructive focus (X) in the white matter of insular area. Pericavernous vascular cell infiltration (↑). No. 8. H.-E.

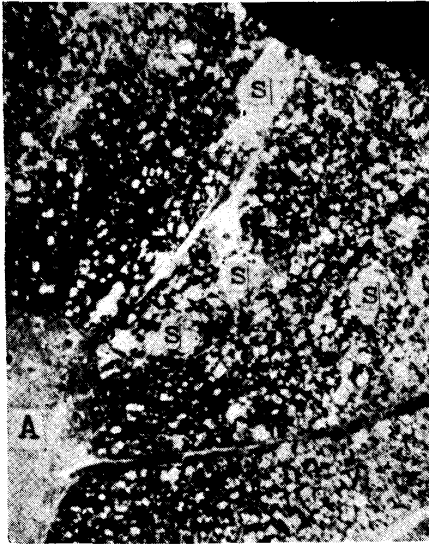
FIG. 64. *Setariasis* (Sheep)



Destructive focus (X) in the white matter of spinal cord. Two cross sections of *Setaria* in cavern. Pericavernous vascular cell infiltration (↑). No. 27, H.-E.

any rate, since lumbar paralysis and staggers are not accompanied by any anatomical change which can be a subject for discussion in human apoplectic cases, it is plain that a similar case of cavern and fissure formations, other than in a case of experimental mechanical trauma of the central nervous system, which is provoked by these causes, cannot be obtained except in cases of the lumbar paralysis of Ceylon goat contained in a recent report by INNES.²¹⁾

There is another important pathological focal change in the spinal cord of lumbar paralysis. In consequence of the existence of such change, the author could with difficulty ascertain the role of destructive focus as it should be deduced through his experiences in etiological investigation. It is no more than the focus of secondary degeneration which is attributed to the destructive focus (Fig. 65). This degenerative focus, depending on the localization of the destruction not only in but also surrounding the destructive focus, can be observed as an elongated lesion ascendantly or descendantly. Accordingly, in the course of microscopical investigations on the numerous histological section preparations of spinal cord of lumbar paralysis, it is very common that degenerative focus may become a nucleus of many problems. The author had once quoted funicular spinal disorder as a reference in defining the pathology of lumbar paralysis. The etiology of funicular spinal disorder has not yet been solved and the author is not too familiar

FIG. 65. *Setariasis* (Sheep)

Foci of secondary degeneration (S) in the white matter of spinal cord. A: anterior horn. No. 12. SPIELMEYER.

with this sort of disease. However, the author still considers, in recalling the past, that there would be not much significance in comparing spinal cord lesion of baboon case to degenerative focus of lumbar paralysis. That is because the degenerative focus of lumbar paralysis is entirely a secondary product from the view point of the nature of the lesion itself, while the lesion of funicular spinal disorder is a primary focal necrosis (cf. Figs. 54~56 & 65).

Symptomatic Inflammation To cite an example, perivascular round cell infiltration which is often observed in the area surrounding a destructive focus other than secondary degenerative focus on the occasion of investigation on the section preparations of lumbar paralysis is nothing


else than a case which belongs to symptomatic inflammation (symptomatische Entzündung) supported by SPIELMEYER and others. In line of this indication, perivascular cell infiltration which appears to have no relation with focus itself is also observed, and a part of it seems to be influenced directly by parasite; but the observer should remember that it is nothing but a simple local inflammatory change (Figs. 63 & 64, already shown). In this meaning, as to the etiology of lumbar paralysis, the author had strongly stressed that it is not an encephalomyelitis caused by virus, etc., at the time when brisk discussions were exchanged in the veterinary world. KIMURA and NIIMI,²²⁾ however, who had investigated this lumbar paralysis at Pusan interpreted in their report in 1939 that perivascular cell infiltration is not only always caused subsequently to spongy malactic focus (our so-called "destructive focus") but also vascular cell infiltration is sometimes independent and an accompanying malactic focus can exist. They also defined, as to the cause of lumbar paralysis, that parasite (nematode or *Microsporidia*) often observed in the foregoing stated section is at least not a main cause of this disease and admitted after all that such cerebral change is *meningoencephalitis non-purulenta*. In addition, particular attention should be paid to the fact that deflection focus (our so-called "degenerative focus") is in this report handled as a relatively fresh status of spongy malactic focus and is not regarded as a secondary product. On the other hand, in the report of 1940,²³⁾ KIMURA and NIIMI

diagnosed this change as *encephalomyelomalacia disseminata (cum encephalomyelitis non-purulenta disseminata)* and stated that the larva of *Setaria* mostly detected at the location of change has the most important etiological significance. From the view point of wording, their nomenclature would be understood to mean a complication of encephalomalacia and encephalitic disease, but it would be an appropriate thing for us to recall that they have once defined it as encephalomalacia; however they were always stressing and attaching great importance to inflammatory change which has a possibility of being non-purulent encephalomyelitis.

At any rate, it is clear that they have been making a great effort to interpret perivascular cell infiltration among other things. The theory of "setariasis" was finally established by definite results obtained by other investigators who conducted experiments in our veterinary circle and the writer, on the occasion of the veterinary meeting held in 1934, congratulated them for their success with a sincere heart. In the report completed and announced by the author and SHOHO²⁴⁾ in the next year, it was possible to define a primary significance to destructive focus and also a secondary one to degenerative focus.

Pertaining to symptomatic inflammation, the author hereby presents another interesting finding which was observed in listeriosis. In an effort to find a character of listeriosis encephalitis in complicated inflammatory change developed in a portion of brain stem, difficulty has been encountered in handling perivascular cell infiltration. The author was encouraged to find a way to explain perivascular cell infiltration, after conducting minute investigation on all preparations in drafting this report, by the fact that the main body of histological change of listeriosis encephalitis is interpreted to exist in the small abscess formation observed in parallel with the tissue emigration of polymorphonuclear leucocyte. As to the perivascular cell infiltration as shown in the figure, the majority of such cases are observed to occur near by small abscess and such fact is regarded as nothing but a change which has a reactive character contrary to focal tissue change. In other words, the author

FIG. 66. *Listeriosis Encephalitis*
(Sheep)



Symptomatic inflammation. Focus (F) made up of compound granule corpuscle accumulation and vascular cell infiltration (i) adjacent to focus. Pr. 3298. H.-E.

proposes to regard perivascular cell infiltration as a symptomatic inflammation which has a relation with small abscess, without depending on the previous general idea which interprets it as so-called partial phenomenon of non-purulent encephalitis together with glia cell reaction, a portion of inflammatory change (Fig. 66).

(continued)