



# HOKKAIDO UNIVERSITY

Title	STUDIES ON THE DEVELOPMENT OF THE EMBRYONIC OVARY IN SWINE, CATTLE AND HORSE
Author(s)	SAKAI, Tamotsu
Citation	Japanese Journal of Veterinary Research, 3(4), 183-194
Issue Date	1955-12-15
DOI	<a href="https://doi.org/10.14943/jjvr.3.4.183">https://doi.org/10.14943/jjvr.3.4.183</a>
Doc URL	<a href="https://hdl.handle.net/2115/1680">https://hdl.handle.net/2115/1680</a>
Type	departmental bulletin paper
File Information	KJ00002372973.pdf



# STUDIES ON THE DEVELOPMENT OF THE EMBRYONIC OVARY IN SWINE, CATTLE AND HORSE

Tamotsu SAKAI

*Laboratory of Veterinary Surgery, Faculty of  
Veterinary Medicine, Hokkaido University,  
Sapporo, Japan*

(Received for Publication, Oct. 28, 1955)

## INTRODUCTION

Many studies have been made to date on the embryonic development of ovary because of its close relation with the several embryology and prosperity of a tribe. The works concerning the fetal ovary of cattle and horse are, however, fewer in number as compared to those of swine and only the reports by BASCOM, VAN BEEK and COLE et al. are found. These reports described the embryonic development of the ovary in the above mentioned animals, but did not go into a comparative studies of the interstitial tissue of the fetal ovary and as to the argyrophile fibers only studies on human fetal ovary made by KOYAMA and HÖRMANN are to be found.

It is generally known that the body structure and the habits of these members of the ungulate are very different and that each structure of their sex organs, especially the ovaries, shows distinctive features anatomically and histologically.

It is considered that a synthetic study on the embryonic development of fetal ovary will give a solution for the tribal peculiarity of general body structure. The author has made the studies described below in an attempt to find an explanation to some of the questions on fetal ovary.

## MATERIALS AND METHODS

The materials, fetal ovaries, mostly obtained from the Sapporo slaughter-house were shown in table 1.

TABLE 1. *Materials Examined*

SPECIES	BREED	NO. OF EXAMINED CASES
Swine	Middle Yorkshire	116
Cattle	Holstein-Friesian	30
Horse	Mongrel Percheron	40

These embryos were measured in the crown-rump-length, divided into 12 stages according

TABLE 2. *Relation between Crown-Rump-Length and Age of Embryo*

STAGE	SWINE		CATTLE		HORSE	
	C.-R. Length (cm)	Age (day)	C.-R. Length (cm)	Age (day)	C.-R. Length (cm)	Age (day)
1	N/A	10	2	25	4	30
2	N/A	20	3~6	50	5~7	60
3	1.0~2.5	30	7~10	75	8~12	90
4	2.6~4.9	40	11~17	100	13~20	120
5	5.0~8.5	50	18~22	125	21~31	150
6	8.6~11.5	60	23~33	150	32~43	180
7	12.0~15.5	70	34~49	175	44~55	210
8	16.0~18.5	80	50~65	200	56~72	240
9	19.0~20.5	90	66~75	225	73~90	270
10	21.0~23.5	100	76~80	250	91~97	300
11	24.0~26.5	110	81~87	275	98~105	330
12	27.0~28.5	120	88~95	300	106~110	360

N/A indicates no available material.

to their age (Table 2) and observed macroscopically and histologically.

The age of the embryo was decided upon the crown-rump-length in the reports of OSAWA, JUNG and SCHMALTZ. The site of the fetal ovaries was determined and their weight, volume and volume rate per unit weight were studied. After fixation with 10% formol or CARNOY's fluid, the ovaries were embedded in paraffin. The sections were stained by BÖHMER's haematoxylin-eosin, VAN GIESON's collagenous fiber, WEIGERT's fiber and GÖMÖRI's silver nitrate impregnation methods.

## RESULTS AND DISCUSSION

### 1. Macroscopical Observations

*Site of ovary* Fetal ovary was joined to the mesonephros with connective tissue until approximately the 5th period (crown-rump-length 7 cm) of the 12 stages in swine, the 4th period (11 cm) in cattle and the 3rd period (8.5 cm) in horse. Thereafter it settled in the *pelvis major* after the 8th (17 cm), 5th (21.5 cm) and 5th (27.5 cm) periods respectively. The settlement of ovary in horse was comparatively earlier than that in cattle and swine. The author considers that due to the fact that swine embryo has a larger mesonephros than the others, this finding will have important significance in the embryonic development of the ovary.

*Weight of ovary* The changes in ovary weight are shown in chart 1 taking the maximum average weight in each animal as 100.

The swine ovary increased in weight with the change of the crown-rump-

length, but in cattle it increased gradually up to the 8th period and then rapidly. In all of the horse cases, the ovary increased in weight gradually up to the 5th period, reached its maximum at the 8th, thereafter decreased and indicated a value similar to that at the 6th in the last period. This proves that the development of the cords of PFLÜGER and interstitial connective tissue are coincident; that is, the changes of weight of the ovaries in swine and cattle take the same direction.

COLE et al. report that the enlargement of the fetal ovary in horse is due to the increase of the interstitial cells in number and size, and that the increase of ovary weight at the 6~7th stages and the decrease at the later stages are attributable to the relation between the hormones of the *corpus luteum* and placenta in mother mare.

The author, therefore, would like to conduct further observations to throw light upon problems based upon histological findings.

*Volume of ovary* The changes in ovary volume are shown in chart 2. The maximum average volume is taken as 100. The volume of the fetal ovaries in swine and cattle increased in as approximate straight line, but in horse it showed change similar to that in its weight.

CHART 1. Changes in Weight of Embryonic Ovary

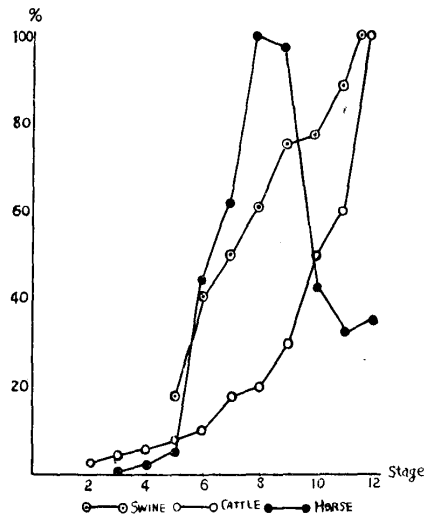


CHART 2. Changes in Volume of Embryonic Ovary

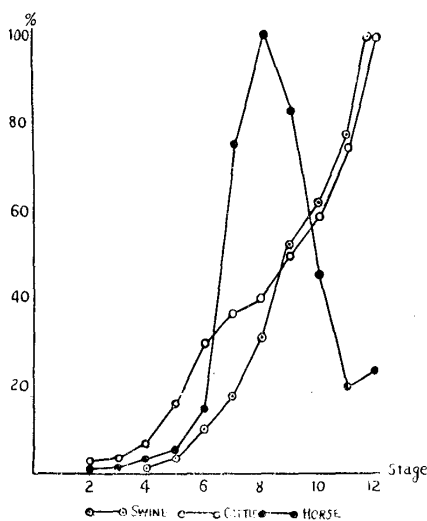
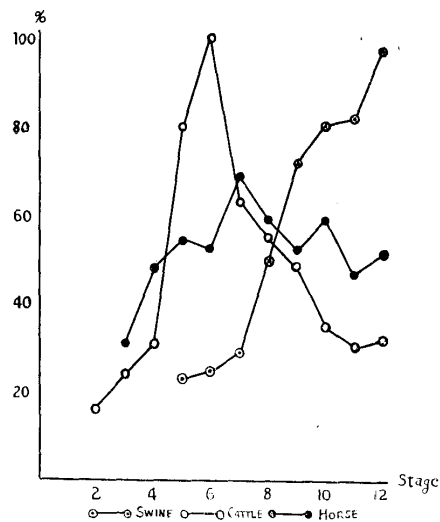


CHART 3. Changes in Volume of Embryonic Ovary per Unit Weight



*Volume of ovary per unit weight* The changes in the ovary volume per unit weight are shown in chart 3 in which the average value of the 6th period in cattle is taken as 100.

In swine, the volume per unit weight was increased in as approximate straight line concomitant with the increase of the crown-rump-length; that is, its density was decreased. In cattle the density was decreased rapidly up to the 6th period and thereafter showed an increase. The change of the density in horse ovary was less than that in swine and cattle throughout the whole period of 12 stages.

## 2. Histological Observations

*Period of differentiation of sex gland* WALDEYER reported that an anlage of the sex gland was a mass of connective tissue covered by the germ-epithelium and the anlage was not yet sexually differentiated in the first period. YAMADA, however, noted that the sex gland of the swine embryo was already differentiated at the stage of 2.33 cm in crown-rump-length. BASCOM also made a similar finding in 2.5 cm cattle embryo.

The author observed that the ovary of swine embryo in 3.1 cm and ovaries of both cattle and horse embryo in 3.5 cm showed histological evidence of sexual differentiation. The embryo in each animal finished sexual differentiation at approximately 3.5 cm which is on or about the 30th day in gestation as shown in table 2. Though the gestation period differs in swine, cattle and horse, these animals make the sexual differentiation of fetal ovary at about the same period in point of both size and age of embryo.

The author, therefore, considers the above stated findings very interesting facts in view of the later part of the development of the fetal ovary.

*Germinal epithelium* The fetal ovaries of these animals were covered by a single layer of germinal epithelium throughout the whole embryonic period. At the first period the epithelium and the epithelial cell increased its density and height in company with the enlargement of the crown-rump-length of embryo. The cell became cylindrical and its nucleus settled in the basal part of the cells after the middle period.

In horse, the tissue in the surface of the ovary was replaced by germinal epithelium and covered with connective tissue layer after the 8th period. The mass of germinal cells protruded and invaded into the cortex and formed the cords of PFLÜGER. At the same time some germinal cells were differentiated into primary oocytes. In this period, the crown-rump-length of the embryo was 3.1 cm in swine, 6 cm in cattle and 5 cm in horses. The number of primary oocytes was large in swine and very small in horse.

*Cords of PFLÜGER* The primary stage of the cords of PFLÜGER was in the 4th period of gestation in swine, the 1st~2nd period in cattle and horse respectively while the fetal crown-rump-length was as stated above. The cords of PFLÜGER in swine appeared following one other depending upon the period in gestation, but the age of embryo was 30~40 days in these three tribes and did not indicate remarkable difference. The most developed stage of the cords of PFLÜGER was the 6~7th period in swine (14 cm in crown-rump-length), the 4th period in cattle (15 cm) and horse (17 cm).

The cords appeared as a comparatively broad tube in swine and cattle. On the other hand, the horse's was like a fine cord, lacking in cells. The degeneration of the cords began at the same time as the formation of the primary follicle. Though the vestiges of cords in the swine and cattle were found only on the surface of the cortex at the later period, that in the horse yielded relatively distinct histological findings.

With regard to the above differences, the author considers that interstitial cells which occupied the fetal ovaries in the horse controlled the differences of cords of PFLÜGER during the pregnant period. In addition, these differences attract the author's attention in relation with the development of the mesonephros and interstitial cells, peculiarity of the ovary's structure and the *corpus luteum* functions of the mother.

*Development of primary follicle* Primary follicle was formed by the cords of PFLÜGER separated by connective tissue that invaded from the boundary between cortex and medulla in ovary and was formed by a primary oocyte which has a single layer of germ cells in its surrounding. A primary follicle appeared in 9.7 cm fetal swine (6th period), 15 cm cattle (4th period) and 20 cm horse (5th period). The most developed primary follicle, in swine, was found in the 8th period—18.5 cm of fetus in length—and occupied the cortex of the ovary. On the contrary, in cattle, this structure most developed in the 7th period when the fetal length was 40.5 cm; the number of primary follicles showed a maximum at that time it was less than the swine's. In horse, they showed a slight increase in number after the period (40 cm) then indicated an outstanding decrease as compared to the number in the other animals.

SCHÖFFER reports that the primary follicle of the fetal ovary of horse exists in a group or separately like cords in the cortex. However, the present author's study, those of swine and cattle were observed in a group at the most developed period, gradually decreased in number thereafter and existed isolatedly inside of connective tissue. The existence of the primary follicle in the fetal ovary of horse, different to the above, was observed sporadically having appearance similar to the cords. The epithelium of the follicle was composed of several round cells at the first period; the number increased until the forming of layers with the growth of the fetus. The development of these layers was much more

clear in cattle than in the other animals and formed the *stratum granulosum* at the 12th period. *Tunica folliculi* consisted of *tunica externa* and *interna*. The former appeared when the epithelial cells of the follicle made 2~3 layers and although there were 2~3 strata at the last period in the cow, there was only a single layer in the sow and mare. The latter appeared when it formed *stratum granulosum* which was observed only in cattle. The glassy membrane appeared when the cells of *theca folliculi externa* and *interna* made two to several strata. Furthermore, at the time when the cells of the external and internal layers came to form in more than 2 strata, the *zona pellucida* appeared around the oocyte.

As mentioned above, the development of the follicle was the most active in cattle and moreover, the mature follicle appeared at the last period. In swine, however, the follicle remained as a primary follicle throughout the whole period of pregnancy. In horse, the development of follicles was very slow; of them the majority maintained the shape of a primary follicle except for the development in the last period of the degeneration of interstitial cells. Consequently, the author regards that the apparent tribal differences in the development of follicle of these 3 animals have significance as well as the development of the cords of PFLÜGER.

*Atresia of follicle* The atresia of the follicle of the fetal ovary was found only in cattle; its occurrence fell into 2 types, one with absorptive degeneration and the other with vacuolar one. The former was found at the 12th period (95 cm) with the indications of degeneration of cells of the *stratum granulosum* which contained atrophied nuclei, the absorption of the entirely decayed substance of each cell by the blood vessels which made a remarkable progress in the space between the *stratum granulosum* and the internal layer of the follicle, and the filling up of the connective tissue cells over the vestige of diminution. In the latter observation, recognized in the material of 103 cm length, there was no change in the layers of the follicle and the *stratum granulosum* while oocytes were diminished with the formation of a great vacuole.

This finding just described is very similar to the observations made in cow by VAN BEEK and those in guinea pig by SAKAIDA. As to the origin of the cells of the young connective tissue in the former type 1, SCHOTTLÄNDER and KOYAMA have attributed it to the cells of the internal layer of the follicle and HÖRMANN to the cells of the external layer. In this regard, the observations of the author are approximately similar to those of SCHOTTLÄNDER.

*Medullary cords* The medullary cords in fetal ovary of swine and cattle preceded the cords of PFLÜGER in appearance. They occupied a great part of the medulla at the first stage but showed a rapid degeneration in parallel with the degeneration of the cords of PFLÜGER and remained as cell vestiges in the 12th period. The ovary of fetal horse in 3 cm did not show differential genital gland. It was connected with the masses of cells, equivalent to the medulla,

which filled up its germinal epithelium. What differentiated these masses of cells from the germinal epithelium is that the masses of cells possessed nuclei lacking in chromatin with slightly stained protoplasm as well as with irregularly shaped frame of cell membrane.

The accumulated portion of the mesenchymal cells which were derived from mesoderm formed the medullary cord and the other portion differentiated into connective tissue. Accordingly this fact coincides with the findings in the ovary of fetal swine, the dissimilation of medullary cord to connective tissue and the difficulty in discriminating the medullary cord from connective tissue.

From the fact that the medullary cord forms cylindrical epithelium cord in swine and medullary tube in cattle and that the medullary cord is originated in the same category of the mesoderm and mesonephros, it is unreasonable to consider the medullary cord as the remainder of mesonephros. Therefore, it is natural that MATSUYAMA reports as to the connection of the medullary cord cell with the primary follicle formation and that B. M. ALLEN also notes its origin in germinal epithelium. With regard to the origin of the medullary tube, it is considered to be arise from mesenchyme rather than to be the remainder of mesonephros.

*Interstitial cell* BASCOM reported that interstitial cells were not found at any stage in the medulla of the ovary of fetal cow and were seldom found in the internal and external layer of follicles only after 82 cm of fetal length. He further stated that they are very much similar to connective tissue cells. E. ALLEN also studied the embryonic history of interstitial cells in pig and rabbit; he reported that the abundant cells in the testis and the few in the ovary of pig embryo disappeared at about 3.5 cm of fetal length. The author could not find the appearance of the cells in his cow and swine materials. The ovaries of fetal horse during the most part of the pregnancy period consisted of an almost solid mass of interstitial cells which effected the weight and volume of the fetal ovary. These cells were present in very young fetus; in their first appearance they were distributed as small island-like clumps throughout the medullary portion of the ovary. The author has observed such arrangement of these cells in the ovary of fetal horse with crown-rump-length from 4 to 8 cm (from 1st to 3rd period). The size of the fetal ovary showed its maximum when the crown-rump-length reached 56 to 72 cm at the 8th period. In after the 9th period (73 cm), these cells began to degenerate from the surface of the cell clumps and the medullary portion was reduced which caused decrease in the weight and volume of the ovary.

YAMADA stressed that the interstitial cells originate in the germinal epithelial cells; FRIEDMANN et al. reported that the fixed cells of the connective tissue were transitive to these cells. KUBO, however, noted that they were differentiated from the medullary cords. According to the present author's finding, it seems that they are not originated

from the differentiated germinal epithelial cell but from the undifferentiated cell which is the mesenchymal cell, so he cannot support FRIEDMANN's finding. As for the function, AIMÈ explained that the internal secretion of these cells might cross the placental barrier and establish an equilibrium with the maternal luteal tissue. COLE et al. also reported that they are connected with the hormones of the *corpus luteum* and placenta.

The author's histological study also revealed as unquestionable that these cells were connected with the function of the internal secretion, that is, the fetal ovaries, during the major portion of the pregnant period, consisted of these cells which showed an active proliferation and internal secretion.

*Development of fibers in cortex and medulla of ovary* Though the boundary between the cortex and medulla was not clear in the first period, at which time the former was much more narrow than the latter, it gradually became clear along with the development of the embryo. In the cases of swine and cattle, the cortex was wider than the medulla in the last period; however, in horse, though the cortex gradually became wider along with the degeneration of the interstitial cells, it was no more than one-tenth of the width of medulla even at the last period.

Though the interstitial tissue was very loose at the first period, it changed into a massed tissue by a vigorous proliferation of the mesenchymal cells and connective tissue. That is, it formed a stratum of the connective tissue between the cortex and medulla. In the cortex, it separated the cords of PFLÜGER and extended up to the under side of the germinal epithelium surrounding the primary follicles and then formed the *tunica albuginea*. In the medulla, contrary to the above, interstitial tissue filled up the crevices of the medullary cords by turning into the connective tissue of the mesenchymal cells and by dissimulation of medullary cord cells. It formed the medulla's stroma. The development of interstice and stroma is different depending on each animal. The connective tissue in the ovary of fetal horse showed a remarkable development as compared to other's; it invaded into the medulla forming a trabecula-like structure, but it formed the thick *tunica albuginea* in the cortex.

The fibers in the cortex and medulla of ovary were composed principally of argyrophile fibers with a few collagenous ones but no elastic fiber. The fine argyrophile fibers were found centering around the boundary between the cortex and medulla of 3.1 cm (4th period) swine, 3.5 cm (2nd period) cow and 5 cm (2nd period) horse ovary. They developed toward the surface of the ovary surrounding the cords of PFLÜGER with the growth of the embryo and reached the under side of the germinal epithelium in 14 cm of swine (7th period), 12 cm cow (4th period) and 17 cm horse (4th period). Therefore, these fibers separated the cords of PFLÜGER, isolated the primary follicles and formed a thick bundle

under the germinal epithelium and in the deep portion of the cortex. These argyrophile fibers in swine and cattle which are rich in the cords of PFLÜGER and primary follicles were comparatively fine making a small net, but were coarse in horse. These fibers, however, penetrated into the medulla as in the cortex and surrounded the medullary cords and interstitial cells. Though the medullary cords of swine and cattle were abundant in fibers and were as well developed as the cortex, the cells of medullary cords were comparatively degenerated at an early period. In the case of the fetal ovary in horse, the development of these fibers in the medulla was outstanding exclusively in the connective tissue which is distributed like a trabecula. The collagenous fibers were few, they were found in the thickened argyrophile fibers at the last period; the fetal ovary of horse had a plenty of such fibers in comparison with the other animals.

Pertaining to the relation between the argyrophile and collagenous fibers, AKAZA stated that the argyrophile fiber was fine collagenous in nature and there was a difference in the manner of staining depending on the size of the fiber. The present author, however, considers that the former is a preliminary stage of the latter because the black fibers change into dark brown and are then stained with VAN GIESON'S liquid while the argyrophile fibers show some gradation.

*Blood vessel* The blood capillary was found in the ovary of 3.1 cm swine (4th period), 6 cm cattle (2nd period) and 5 cm horse fetus (2nd period). There were many capillaries on the boundary between the cortex and medulla. They contained erythroblasts. The artery was found in the ovary of 7.5 cm of swine fetus (5th period), 17 cm of cattle (4th period) and 8 cm of horse (3rd period) and in these periods, the erythroblasts were not found. As mentioned above, the development of the blood vessels of horse ovary is remarkable comparing with other's. This is a matter of course for the fetal ovary of horse during the greater part of the pregnancy period is made up of a mass of interstitial cells which possess a vigorous internal secretory function.

#### SUMMARY

In an attempt to clarify the peculiarity of the structure and function of ovary in swine, cattle and horse, the author has made comparative studies on the development of the fetal ovary dividing the pregnant period into 12 stages (Table 2). His obtained results may be briefly stated as follows:

1. The fetal ovary connected with the mesonephros in the first period gradually moves and settles in the *pelvis major* in the middle stages. The settlement of swine ovary is slower as compared to that of cattle and horse. This seems to be related to the size and rise and fall of the mesonephros.
2. The changes in weight and volume of the fetal ovary show a tribal

peculiarity. The ovary increases its weight and volume showing an approximate straight line together with the growth of the embryo in swine and cattle, but, in the horse it shows a distinct increase up to approximately the 8th stage and thereafter decreases (Charts 1 and 2).

3. The density of the fetal ovary decreases in keeping with the weight and volume in swine; it decreases up to the middle period and thereafter increases in cattle. No remarkable changes have been observed in horse (Chart 3).

4. The differentiation of the sex gland appears in the about 30 day old embryo in cattle, horse and swine without indicating any tribal difference.

5. The cords of PFLÜGER are differentiated from the germinal epithelium. The development of the cords of the swine is more distinctive than that of the others. The degeneration of the cords begins with the beginning of growth of the primary follicle and these are only found as a vestige in the last period in swine and cattle, but are comparatively distinct in horse.

6. Cattle demonstrate the development of the primary follicle, more clearly than the others. Many primary follicles are observed in swine, but are few in horse showing a little increase after the 7th period (crown-rump-length 40 cm).

7. The follicle atresia of the fetal ovary is found only in catttle; it takes 2 forms, absorptive and vacuolar degeneration.

8. Medullary cords are formed by a part of the mesenchymal cells derived from the mesoderm. Though medullary cords swarm with the greater part of medulla at the 1st period, they are only discriminated as vestiges of the cells in the 12th period in swine and horse.

9. Interstitial cells originate in the indifferentiated germinal epithelial cell, that is, in the mesenchymal cell. They are found only in the fetal ovary of horse which is made up of an almost solid mass of interstitial cells during the major portion of the pregnancy period; these cells are concerned with internal secretion.

10. The connective tissue in the cortex and medulla of ovary takes reticular form of which the fibers are rich in argyrophile fiber with a few collagenous and no elastic fibers.

11. The development of the blood vessels of the ovary of horse is more clear than the others. Erythroblasts in the vessels disappear at the time of appearance of artery.

12. The macroscopical changes of the fetal ovary which showed a tribal peculiarity are explained histologically. That is, in horse, the changes of the weight and volume connected with rise and fall of the interstitial cells and the stability of the density are due to the tissue which is equalized by the interstitial cells. The changes of the density of the ovary of cattle depend on the augmenta-

tion of tissue by the development of primary follicles into mature follicles. On the other hand, in swine, it seems that the connective tissue becomes loose because of the degeneration of the PFLÜGER'S cords and the state of repose of the primary follicles.

As indicated in the foregoing explanation, it is considered that the peculiarity of the embryonic development in swine, cattle and horse ovaries is related to the postnatal changes of the ovary, the hormone of the placenta and the rise and fall of the mesonephros.

The author is greatly indebted for the kind advice of Professors R. KUROSAWA, S. YAMAGIWA, K. TAKAHATA and T. INUKAI liberally given throughout the course of his studies.

## REFERENCES

- 1) AKAZA, S. (1922): *Nihon-byôrigakkai-zasshi*, 6, 6 (Japanese).
- 2) AIMÈ, P. (1907): *Arch. Zool. Exper. et Gyn.*, 7, 95.
- 3) ALLEN, B. M. (1904): *Amer. J. Anat.*, 3, 89.
- 4) ALLEN, E. (1930): *Amer. J. Anat.*, 46, 1.
- 5) BASCOM, K. F. (1923): *Amer. J. Anat.*, 31, 223.
- 6) COLE, H. & G. H. HART (1933): *Anat. Rec.*, 56, 3.
- 7) HÖRMANN, C. (1907): *Arch. f. Gyn.*, 82, 619.
- 8) JUNG, P. (1937): *Zeitschr. f. mik. Anat. Forsch.*, 41, 27.
- 9) KOYAMA, N. (1930): *Jûzenkai-zasshi*, 35, 1081 (Japanese).
- 10) KUBO, T. (1928): *Nihon-fujinkagakkai-zasshi*, 23, 10 (Japanese).
- 11) MATSUYAMA, S. (1930): *Sëikai-zasshi*, 52, 39 (Japanese).
- 12) OSAWA, T. (1932): *Chûô-jûigaku-zasshi*, 45, 465 (Japanese).
- 13) SAKAIDA, H. (1932): *Nihon-fujinkagakkai-zasshi*, 17, 1786 (Japanese).
- 14) SCHOTTLÄNDER, J. (1891): *Arch. f. mik. Anat.*, 37, 192.
- 15) SCHÖFFER, A. (1911): *Arch. f. Gyn.*, 94, 491.
- 16) SCHMALTZ, R. (1911): *Struktur d. Geschlechtsorgane d. Haustiere.*
- 17) VAN BEEK, W. F. (1924): *Zeitschr. f. Anat. u. Entwick-gesch.*, 71, 185.
- 18) WALDEYER, W. (1870): *Eierstock u. Ei.*, Leipzig.
- 19) YAMADA, N. (1929): *Sëikai-zasshi*, 48, 81 (Japanese).

## EXPLANATION OF PLATES

## PLATE I.

## — Fetal Swine Ovary —

- Fig. 1. Primary stage of cords of PFLÜGER—3.1 cm in crown-rump-length (4th period). × 260.  
 Fig. 2. Medullary cords—3.1 cm (4th period). × 260.  
 Fig. 3. Argyrophile fibers in cortex and medulla—3.1 cm (4th period). × 130.  
 Fig. 4. Argyrophile fibers surrounding cords of PFLÜGER—14 cm (7th period). × 260.  
 Fig. 5. Primary follicles—18.5 cm (8th period). × 130.  
 Fig. 6. Argyrophile fibers in cortex—18.5 cm (8th period). × 130.

## PLATE II.

- Fig. 7. Argyrophile fibers in medulla—18.5 cm (8th period). × 130.  
 Fig. 8. Primary follicles—25 cm (11th period). × 260.

## — Fetal Cattle Ovary —

- Fig. 9. Cords of PFLÜGER under germinal epithelium—6 cm (2nd period). × 260.  
 Fig. 10. Argyrophile fibers in cortex and medulla—23 cm (6th period). × 130.  
 Fig. 11. Primary follicles in cortex—30 cm (6th period). × 260.  
 Fig. 12. Primary stage of *stratum granulosum*—80 cm (10th period). × 260.

## PLATE III.

- Fig. 13. Follicle—95 cm (12th period). × 130.  
 Fig. 14. Argyrophile fibers in cortex—95.5 cm (12th period). × 130.  
 Fig. 15. Atresia of follicle (absorptive degeneration)—95.5 cm (12th period). × 130.  
 Fig. 16. Atresia of follicle (vacuolar degeneration)—103 cm (12th period). × 130.

## — Fetal Horse Ovary —

- Fig. 17. Primary stage of sexual differentiation—3 cm (1st period). × 260.  
 Fig. 18. Primary stage of cords of PFLÜGER—5 cm (2nd period). × 260.

## PLATE IV.

- Fig. 19. Primary stage of interstitial cells—5 cm (2nd period). × 260.  
 Fig. 20. Argyrophile fibers in cortex—8 cm (3rd period). × 260.  
 Fig. 21. Primary stage of primary follicles—18 cm (4th period). × 260.  
 Fig. 22. Argyrophile fibers in boundary between cortex and medulla—40 cm (6th period). × 260.  
 Fig. 23. Degenerated interstitial cells—95 cm (10th period). × 260.  
 Fig. 24. Cords of PFLÜGER primary follicles and *tunica albuginea* in cortex—106 cm (12th period). × 130.

