



HOKKAIDO UNIVERSITY

Title	ON AN UNSUCCESSFUL ATTEMPT OF SERIAL PASSAGE OF EQUINE INFECTIOUS ANEMIA VIRUS IN THE SHEEP
Author(s)	MIURA, Shiro; SATO, Gihei; MIYAMAE, Takeo
Citation	Japanese Journal of Veterinary Research, 4(4), 143-146
Issue Date	1956-12-25
DOI	https://doi.org/10.14943/jjvr.4.4.143
Doc URL	https://hdl.handle.net/2115/1698
Type	departmental bulletin paper
File Information	KJ00002373090.pdf



ON AN UNSUCCESSFUL ATTEMPT OF SERIAL PASSAGE OF EQUINE INFECTIOUS ANEMIA VIRUS IN THE SHEEP

Shiro MIURA, Gihei SATO and Takeo MIYAMAE

*Laboratory of Epizootiology, Faculty of Veterinary
Medicine, Hokkaido University, Sapporo, Japan*

(Received for publication, October 20, 1956)

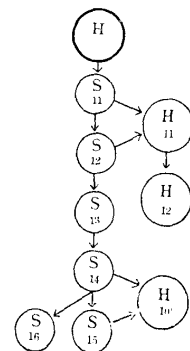
It seems sure that nobody has tried a serial passage of equine infectious anemia (E. I. A.) virus in the sheep. The authors, working on the foundation laid by their previous experiments,^{1,2)} undertook to secure a blind passage of this virus in lambs. Though the initial purpose of the experiment was not achieved, some suggestive results were obtained as described briefly in this report.

EXPERIMENT

The virus employed in this experiment was withdrawn from a field case of E. I. A. at the febrile stage. Test sheep numbered 11~16 were 7~9-month old Corriedale male lambs weighing 27~34 kg. Lamb No. 11 (1st transfer) received subcutaneously 63 ml of virus serum. On the 7th day after the inoculation it was slaughtered. A mixed saline emulsion was prepared from its spleen, liver, kidney, lung, brain, testicle, bone-marrow and lymphonodi in the same way as described in the preliminary report.¹⁾ The emulsion was centrifuged at 2,000 r. p. m. for 5 minutes and to the supernatant was added 1,000 units of penicillin and 500 units of streptomycin per ml. One hundred ml of the supernatant was introduced subcutaneously into the second lamb (No. 12). Thus the blind passage was carried on up to the 5th transfer with an interval of 7 days and with supernatant of tissue emulsion made in each case by the above-described procedure. For the 5th transfer, 2 lambs were used. One of them was sacrificed on the 7th day following the injection and the other was kept under observation for about 50 days.

When the blind passage had reached to the 5th transfer, the present workers searched for the virus in the material from the lambs of the 1st, 2nd, 4th and 5th transfer. For this purpose 3 foals Nos. 10~12 ascertained not infected with E. I. A. prior to the experiment were used. They received subcutaneously 400 ml of supernatant of tissue emulsion prepared from the above-described lambs. The organs and tissues collected from each lamb had been stored at about -30 C for 20~280 days prior to the preparation of emulsion. The outline of the entire experiment is indicated

FIG. 1. Outline of Experiment



H...Horse
S...Sheep(Lamb)

schematically in figure 1.

As shown in figures 2~7, lambs revealed no evident indications of E. I. A. in clinical and hematological findings. Moreover in the post-mortem examinations no pathognomonic alterations due to E. I. A. were demonstrated.

FIG. 2. *Lamb No. 11*
(1st transfer)

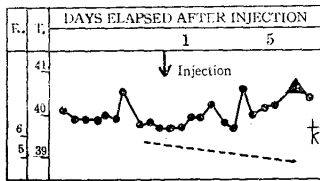


FIG. 3. *Lamb No. 12*
(2nd transfer)

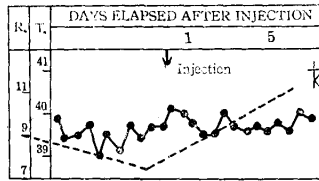


FIG. 4. *Lamb No. 13*
(3rd transfer)

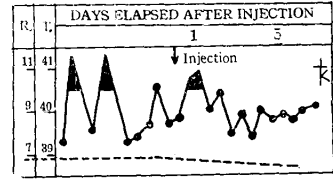


FIG. 5. *Lamb No. 14*
(4th transfer)

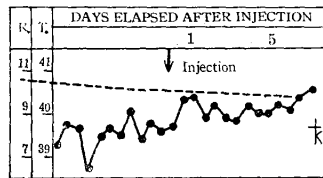


FIG. 6. *Lamb No. 15*
(5th transfer)

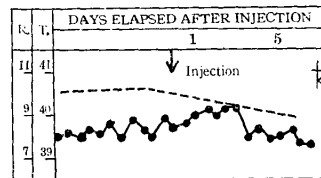
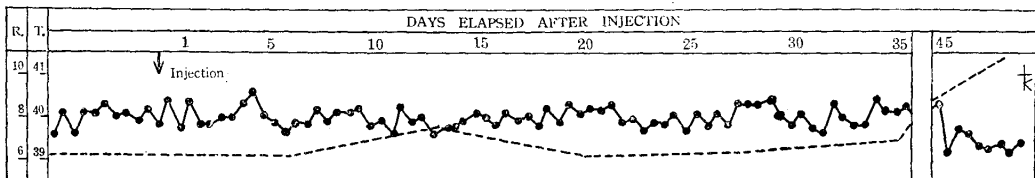


FIG. 7. *Lamb No. 16* (5th transfer)

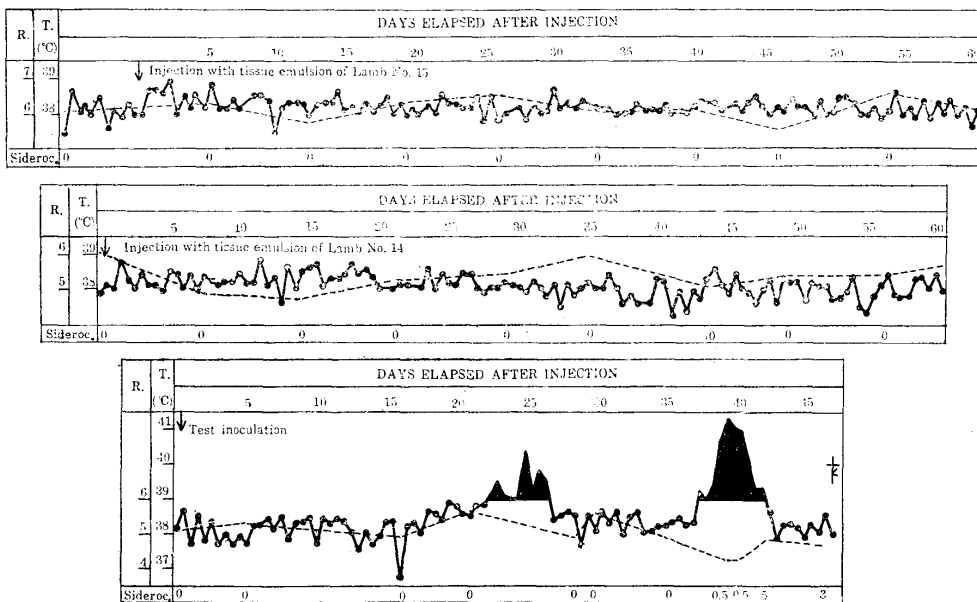


R ... Number of red blood cell in million
T ... In centigrade

Horse No. 10 receiving the tissue emulsion of lamb No. 15 (5th transfer) developed no clinical, hematological or biopsic changes during the initial observation period of 60 days. Therefore, super-injection with tissue emulsion of lamb No. 14 (4th transfer) was made and clinical and hematological examinations were continued for 60 days thereafter. However, the animal manifested no signs of infection with E. I. A. Biopsic histology of this horse also failed to suggest the presence of the infection. On the other hand, horse No. 10 revealed typical symptoms and hematological and histological changes of the disease within 45 days after the test inoculation with known virus of E. I. A.

Horse No. 11 was injected subcutaneously with supernatant of tissue emulsion prepared from lamb No. 12 (2nd transfer). The animal remained normal in clinical and hematological behaviour and in histology by biopsy for the initial observation period of 60 days. The horse, thereafter, received emulsion supernatant of lamb No. 11 (1st transfer). On the clinical and hematological examinations of the animal conducted during the following 119 days the authors did not find any sign of infection of E. I. A., though the histological

FIG. 8. Horse No. 10



Sideroc. ... Siderocyte number in 10 thousand leucocytes

FIG. 9. Horse No. 11

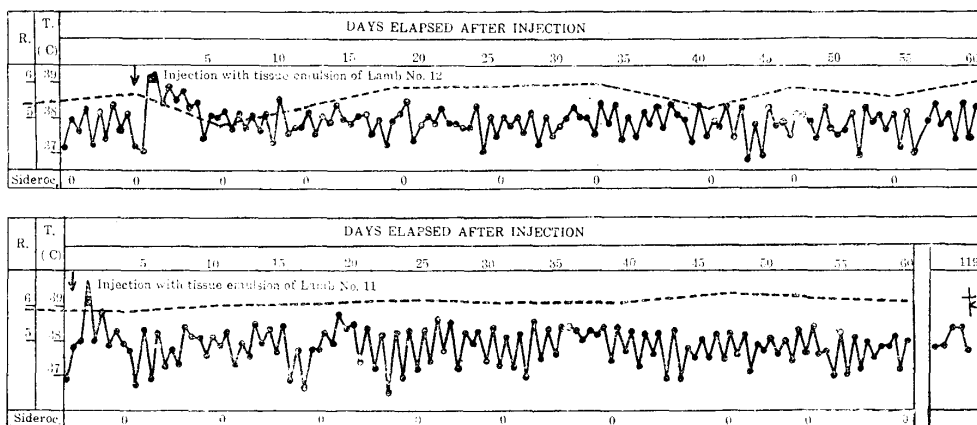
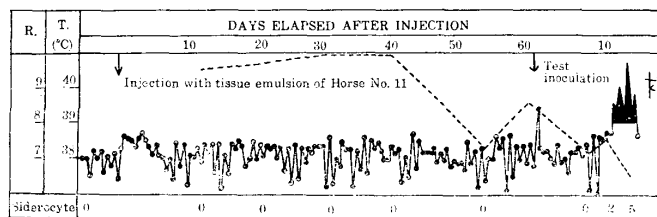


FIG. 10. Horse No. 12



findings by means of biopsy in that period offered suspicious of the disease. Accordingly, horse No. 11 was sacrificed and its tissue emulsion was introduced into a normal horse, No. 12. The horse also remained healthy for 60 days of observation. On the 61st day subsequent to the injection, the animal received the challenge virus which produced typical E. I. A.

Finally, it is to be reported that the present workers failed to detect the E. I. A. virus in any of the lambs of the 1st, 2nd, 4th and 5th transfers.

CONSIDERATION

The finding of the present experiment that E. I. A. virus was eliminated from the lamb within 7 days after the administration of the virus seems contradictory to the previously reported fact that the virus remained detectable for 77 days at least. What was the cause of the contradictory results? One of the most important factors that brought the contrariety seems to be possible difference in infectivity or persistency of the virus strain in animals other than solipeds. The present virus serum was obtained shortly before employment from a field case of E. I. A. On the other hand, the virus strain from which the virus serum in the previous experiment was derived was obtained from a stock strain that has been kept for several years by horse passage. Anyhow, it seems desirable to perform some investigations in order to answer the above-noted question.

The present work was conducted by grant of the Hokkaido Prefectural Government and a Grant in Aid for Miscellaneous Scientific Research of the Ministry of Education. The authors would like to express their thanks to the authorities concerned. They are also indebted to Prof. YAMAGIWA, Prof. NAKAMURA and their coworkers for the hearty support in the histopathological and clinical investigations.

REFERENCES

- 1) MIURA, S., G. SATO, T. MIYAMAE, K. HIRATO, K. SHIMIZU, R. NAKAMURA & M. SONODA (1954): *Jap. J. vet. Res.*, **2**, 55.
- 2) MIURA, S., G. SATO & T. MIYAMAE (1955): *Ibid.*, **3**, 136.