



# HOKKAIDO UNIVERSITY

Title	Non-responsiveness to gefitinib in a patient with lung adenocarcinoma having rare EGFR mutations S768I and V769L.
Author(s)	Asahina, Hajime; Yamazaki, Koichi; Kinoshita, Ichiro et al.
Citation	Lung Cancer, 54(3), 419-422 <a href="https://doi.org/10.1016/j.lungcan.2006.09.005">https://doi.org/10.1016/j.lungcan.2006.09.005</a>
Issue Date	2006-12
Doc URL	<a href="https://hdl.handle.net/2115/17005">https://hdl.handle.net/2115/17005</a>
Type	journal article
File Information	LC54-3.pdf



## **CASE REPORT**

### **Non-responsiveness to Gefitinib in a patient with lung adenocarcinoma having rare EGFR mutations S768I and V769L**

Hajime Asahina, MD; Koichi Yamazaki, MD, PhD; Ichiro Kinoshita, MD, PhD; Hiroshi Yokouchi, MD, PhD; Hirotoshi Dosaka-Akita, MD, PhD; and Masaharu Nishimura, MD, PhD

From First Department of Medicine (Dr. Asahina, Dr. Yamazaki, Dr. Yokouchi, and Dr. Nishimura), Department of Medical Oncology (Dr. Kinoshita, Dr. Dosaka-Akita), Hokkaido University School of Medicine, Sapporo.

#### **Correspondence to:**

Hajime Asahina, MD

First Department of Medicine, Hokkaido University School of Medicine

North 15, West 7, Kita-ku, Sapporo 060-8638, Japan

Tel (81) - 11 - 706 - 5911

FAX (81) - 11 - 706 - 7899

E-mail:hajime.asahina@nifty.ne.jp

## Summary

Mutations in the tyrosine kinase domain of epidermal growth factor receptor (EGFR) are associated with clinical responsiveness to EGFR tyrosine kinase inhibitors (EGFR-TKIs) in patients with non-small cell lung cancers (NSCLCs). However, certain rare EGFR mutations including S768I are reported to confer less in-vitro sensitivity to gefitinib, an EGFR-TKI, than major mutations such as exon 19 deletions and L858R, and even the wild-type counterpart. Here, we report the first case of adenocarcinoma of the lung in which the patient had rare mutations S768I and V769L and was treated with gefitinib. Disease progressed during six weeks of treatment. This case suggests that in vitro sensitivity to gefitinib correlates with distinct clinical responsiveness to gefitinib in various types of EGFR mutations.

**Key words**

epidermal growth factor receptor (EGFR); mutation; non-small cell lung cancer (NSCLC); gefitinib; chemotherapy; first-line therapy

## 1. Introduction

Recently, somatic mutations in the tyrosine kinase (TK) domain of the epidermal growth factor receptor (EGFR) gene were reported to exist in a subset of non-small cell lung cancers (NSCLCs).<sup>1-3</sup> These mutations are closely correlated with favorable clinical responsiveness to EGFR-tyrosine kinase inhibitors (EGFR-TKIs). It was also demonstrated that two major types of mutations, exon 19 deletions and L858R, enhanced TK activity in response to EGF and increased the *in-vitro* sensitivity to an EGFR-TKI, gefitinib. In addition to these two types of mutations, various rare mutations have been identified;<sup>4-10</sup> however, in *in-vitro* studies, some of these mutations (including S768I) conferred less sensitivity to gefitinib than the two major types of mutations, and even its wild-type counterpart.<sup>11</sup> Because of lower frequency of these novel mutations, clinical information of their relationships with drug responsiveness is very limited so far. We herein report a case of a patient with adenocarcinoma of the lung who exhibited two such rare mutations, S768I and V769L, and was treated with gefitinib.

## 2. Case report

A 61-year-old male patient was admitted to our hospital in May 2005 after undergoing resection of a metastatic brain tumor from lung adenocarcinoma. He was a current heavy smoker who had 70 pack-year of smoking index. His chest CT scan revealed a 36-mm nodule in the right S<sup>1</sup> with multiple miliary metastasis in both lung fields (Fig. 1a,b). He also exhibited contralateral mediastinal lymphadenopathy, bilateral adrenal gland metastasis, and sacroiliac joint metastasis. His disease was accordingly staged as cT4N3M1, stage IV. Thrombocytopenia was also evident (platelet count < 100,000 / ul) and bone marrow aspiration revealed myelodysplastic syndrome. Taking the patient's general condition and opinion into account, we offered him gefitinib treatment at an oral dose of 250 mg daily as first-line therapy.

The nine-week Gefitinib administration period included a

three-week interruption, during which the patient underwent radiation therapy for residual brain tumor. However, despite over six weeks of gefitinib administration, chest and abdominal CT revealed enlargement of the primary lesion and pulmonary and adrenal metastases. These lesions were therefore thought to be resistant to gefitinib and the response was evaluated as progressive disease according to the RECIST criteria (Fig. 1c,d). However, as his functional status had not declined and he wanted chemotherapy, combination chemotherapy with carboplatin (AUC 5, day 1) and weekly paclitaxel (70 mg/m<sup>2</sup>, day 1, 8, 15) was administered. After two cycles of this chemotherapy, remarkable shrinkage of both primary and metastatic lesions was observed on chest and abdominal CT, leading to partial response (PR) (Fig. 1e,f). He continues to receive chemotherapy as of February 2006.

We obtained written informed consent to investigate EGFR mutations and EGFR copy number in his NSCLC tissue. Genomic DNA was isolated from two sections of paraffin-embedded tissue of the resected brain metastasis using a DNeasy Tissue kit (Qiagen, Valencia, CA, USA) according to the manufacturer's instructions. Exons 18 to 21 were amplified using primers and conditions previously reported.<sup>2</sup> PCR products were purified using a PCR purification kit (Qiagen) and sequenced directly using an Applied Biosystems BigDye Terminator kit v3.1 with an ABI PRISM 310 Genetic Analyzer (Applied Biosystems, Foster City, CA, USA). These sequencing reactions were performed in both forward and reverse directions from two independent amplification products. Sequencing analysis revealed that there were no major mutations such as G719X in exons 18, exon 19 deletions, and L858R in exon 21. However, double point mutations of S768I and V769L (AGCGTG to ATCTTG in sense direction, Fig. 2a and CACGCT to CAAGAT in antisense direction, Fig. 2b) were detected in exon 20. EGFR copy number per cell was investigated by FISH using the LSI EGFR SpectrumOrange/CEP 7 SpectrumGreen probe (Vysis, Abbott Laboratories, IL, USA), according to a published protocol and

classification.<sup>12</sup> This case had EGFR amplification, since more than 15 copies of EGFR per cell in  $\geq 10\%$  of analyzed cells were observed (Fig. 3).

### 3. Discussion

To the best of our knowledge, this is the first reported case of a patient with the rare mutations S768I and V769L treated with gefitinib. The relationship between EGFR mutations and sensitivity to EGFR-TKI in NSCLCs remains controversial.<sup>1-10,13</sup> Although multiple studies have shown striking correlation between these factors,<sup>1-3,5,8-10</sup> a correlative study in a large clinical phase III trial, BR21, showed no significant association of EGFR mutations with responsiveness to erlotinib or with survival after this agent was administered.<sup>13</sup> One possible reason for such a discrepancy could be that different mutations have different effects on response to EGFR-TKIs. In most of the former studies, over 90% of the mutations were exon 19 deletions and L858R,<sup>1-10</sup> whereas half of the mutations consisted of other sporadic and rare mutations in the latter study.<sup>13</sup>

S768I, a mutation in exon 20 of EGFR, is one of those rare mutations. Retrospective analyses of EGFR mutations using surgical specimens that have demonstrated such mutations have included that by Huang *et al.*<sup>5</sup> (revealing S768I) and that by Kosaka *et al.*<sup>4</sup> (demonstrating S768I and V769L). However, the clinical responsiveness of EGFR-TKIs to these mutations has not been shown.

In *in-vitro* studies, various mutations were shown to have the distinctive phosphorylation patterns of several C-terminal Tyrosine (Tyr) residues of EGFR and different sensitivities to gefitinib when they were stably transfected to a NSCLC cell line.<sup>11,14</sup> Some of these mutations, including S768I, are hyperphosphorylated on the Tyr 1045 residue, which is known to recruit Cbl to EGFR and to lead to Cbl-mediated receptor multi-ubiquitination, and are refractory to EGF-induced ubiquitination and degradation.<sup>15-17</sup> Gefitinib causes less growth-suppressive effects on cells expressing these mutations

than those expressing exon 19 deletions or L858R mutations and even those expressing the wild type counterpart.<sup>11</sup> Although the role of V769L mutations in the responsiveness to gefitinib remains to be examined *in vitro*, clinical responsiveness of the present case with S768I mutation was consistent with the previously-shown *in-vitro* biological phenotype and gefitinib sensitivity of this mutation.

The observed EGFR gene amplification in this case is intriguing because increased gene copy number of EGFR are reported to be associated with higher response rate and better survival to EGFR-TKI.<sup>12,13</sup> Taken together with *in-vitro* finding that S768I mutation shows less gefitinib sensitivity than wild-type<sup>11</sup>, amplification of the mutant allele with such low sensitivity, S768I, may not overcome resistance to gefitinib.

Since this is a case report, multiple factors other than two EGFR mutations S768I and V769L in this case might be associated with resistance to gefitinib. One of the possible factors is his smoking status. K-ras mutations are associated with heavy smoking and gefitinib resistance.<sup>18</sup> Although his K-ras status has not been examined, he might have the K-ras mutation since he was a heavy smoker. Another possible factor is the presence of HER2 (ErbB2) mutations. Although HER2 mutations in lung cancer are rare, they have also been reported to be associated with the resistance to another EGFR-TKI, Erlotinib.<sup>19</sup> Heterogeneity of the tumor might also affect the clinical response, since his mutational analysis was done using a surgical sample from one of the metastatic sites.

#### **4. Conclusion**

Despite the limitations of a case report, this case is an example of a patient with different EGFR mutations who demonstrated distinctive clinical responsiveness to EGFR-TKIs and in whom *in-vitro* sensitivities correlated with clinical responsiveness to EGFR-TKIs. Additional functional and clinical analyses for various EGFR mutations are accordingly warranted.

## **5. Conflict of interest statement**

None declared.

## REFERENCES

- [1] Lynch TJ, Bell DW, Sordella R, et al. Activating mutations in the epidermal growth factor receptor underlying responsiveness of non-small-cell lung cancer to gefitinib. *N Engl J Med* 2004;350:2129-39
- [2] Paez JG, Janne PA, Lee JC, et al. EGFR mutations in lung cancer: Correlation with clinical response to gefitinib therapy. *Science* 2004;304:1497-1500
- [3] Pao W, Miller V, Zakowski M, et al. EGF receptor gene mutations are common in lung cancers from “never smokers” and are associated with sensitivity of tumors to gefitinib and erlotinib. *Proc Natl Acad Sci U S A* 2004;101:13306-11
- [4] Kosaka T, Yatabe Y, Mitsudomi T, et al. Mutations of the Epidermal Growth Factor Receptor Gene in Lung Cancer: Biological and Clinical Implications. *Cancer Res* 2004;64:8919-23
- [5] Huang SF, Liu HP, Tsai SF, et al. High Frequency of Epidermal Growth Factor Receptor Mutations with Complex Patterns in Non-Small Cell Lung Cancers Related to Gefitinib Responsiveness in Taiwan. *Clin Cancer Res* 2004;10:8195-203
- [6] Marchetti A, Martella C, Felicioni L, et al. EGFR Mutations in Non-Small-Cell Lung Cancer: Analysis of a Large Series of Cases and Development of a Rapid and Sensitive Method for Diagnostic Screening With Potential Implications on Pharmacologic Treatment. *J Clin Oncol* 2005;23:857-65
- [7] Shigematsu H, Lin L, Takahashi T, et al. Clinical and Biological Features Associated With Epidermal Growth Factor Receptor Gene Mutations in Lung Cancers. *J Natl Cancer Inst* 2005;97:339-46
- [8] Tokumo M, Toyooka S, Shimizu N, et al. The Relationship between Epidermal Growth Factor Receptor Mutations and Clinicopathologic Features in Non-Small Cell Lung Cancers. *Clin Cancer Res* 2005;11:1167-73
- [9] Han SW, Kim TY, Hwang PG, et al. Predictive and Prognostic Impact of Epidermal Growth Factor Receptor Mutation in Non-Small-Cell Lung Cancer Patients Treated With Gefitinib. *J Clin*

Oncol 2005;23:2493-501

[10] Mitsudomi T, Kosaka T, Endoh H, et al. Mutations of the Epidermal Growth Factor Receptor Gene Predict Prolonged Survival After Gefitinib Treatment in Patients with Non-Small-Cell Lung Cancer With Postoperative Recurrence. *J Clin Oncol* 2005;23:2513-20

[11] Chen YR, Fu YN, Lin CH, et al. Distinctive activation patterns in constitutively active and gefitinib-sensitive EGFR mutants. *Oncogene* 2006;25:1205-15

[12] Cappuzzo F, Hirsch FR, Rossi E, et al. Epidermal growth factor receptor gene and protein and gefitinib sensitivity in non-small cell lung cancer. *J Natl Cancer Inst* 2005;97:643-55

[13] Tsao MS, Sakurada A, Cutz JC, et al. Erlotinib in lung cancer - molecular and clinical predictors of outcome. *N Engl J Med* 2005;353:133-44

[14] Greulich H, Chen TH, Feng W, et al. Oncogenic Transformation by inhibitor-Sensitive and -Resistant EGFR Mutants. *PloS Medicine* 2005;Oct 4;2(11):e313

[15] Levkowitz G, Waterman H, Ettenberg SA, et al. Ubiquitin ligase activity and tyrosine phosphorylation underlie suppression of growth factor signaling by c - Cbl / Sli - 1. *Mol Cell* 1999;4:1029-40

[16] Haglund K, Sigismund S, Polo S, et al. Multiple monoubiquitination of RTKs is sufficient for their endocytosis and degradation. *Nat Cell Biol* 2003;5:461-6

[17] Mossesson Y, Shtiegman K, Katz M, et al. Endocytosis of receptor tyrosine kinases is driven by monoubiquitylation, not polyubiquitylation. *J Biol Chem* 2003;278:21323-6

[18] Sugio K, Uramoto H, Ono K, et al. Mutations within the tyrosine kinase domain of EGFR gene specifically occur in lung adenocarcinoma patients with a low exposure of tobacco smoking. *Br J Cancer* 2006;94:896-903

[19] Wang SE, Narasanna A, Perez-Torres M, et al. HER2 kinase domain mutation results in constitutive phosphorylation and activation of HER2 and EGFR and resistance to EGFR tyrosine kinase inhibitors. *Cancer Cell* 2006;10:25-38

## Figure Legends

### Figure. 1

Chest CT before gefitinib administration shows a 36 mm nodule in the right S<sup>1</sup> (a) with miliary metastases in both lung fields (b). After six weeks of gefitinib administration, enlargement of both the primary (c) and miliary metastatic lesions (d) was observed. After combination chemotherapy, CT shows remarkable shrinkage of both the primary (e) and miliary metastatic lesions (f).

### Figure. 2

(a) The forward sequence of exon 20 of EGFR showed mutations of 2303 G to T and 2305 G to T. (b) The reverse sequence of the same site shows mutations of 2303 C to A and 2305 C to A. Both results indicate amino acid substitutions S768I and V769L.

### Figure. 3

FISH was performed with the EGFR (red)/CEP7 (green) probe. Total nuclear DNA was stained with 4'6'-diamidino-2-phenylindole (Blue). Increased red clusters in each nucleus showed EGFR amplification.

Fig. 1

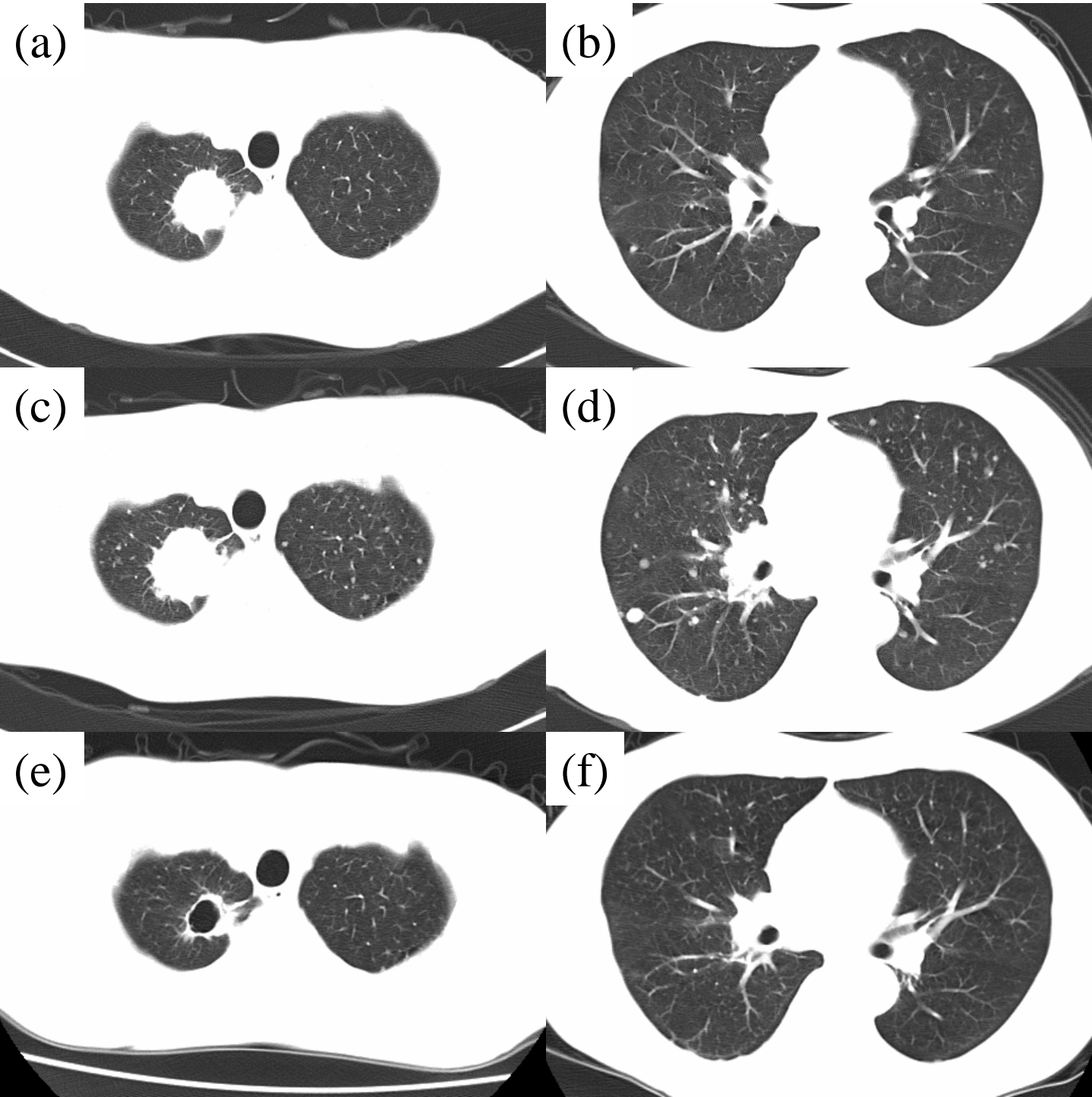
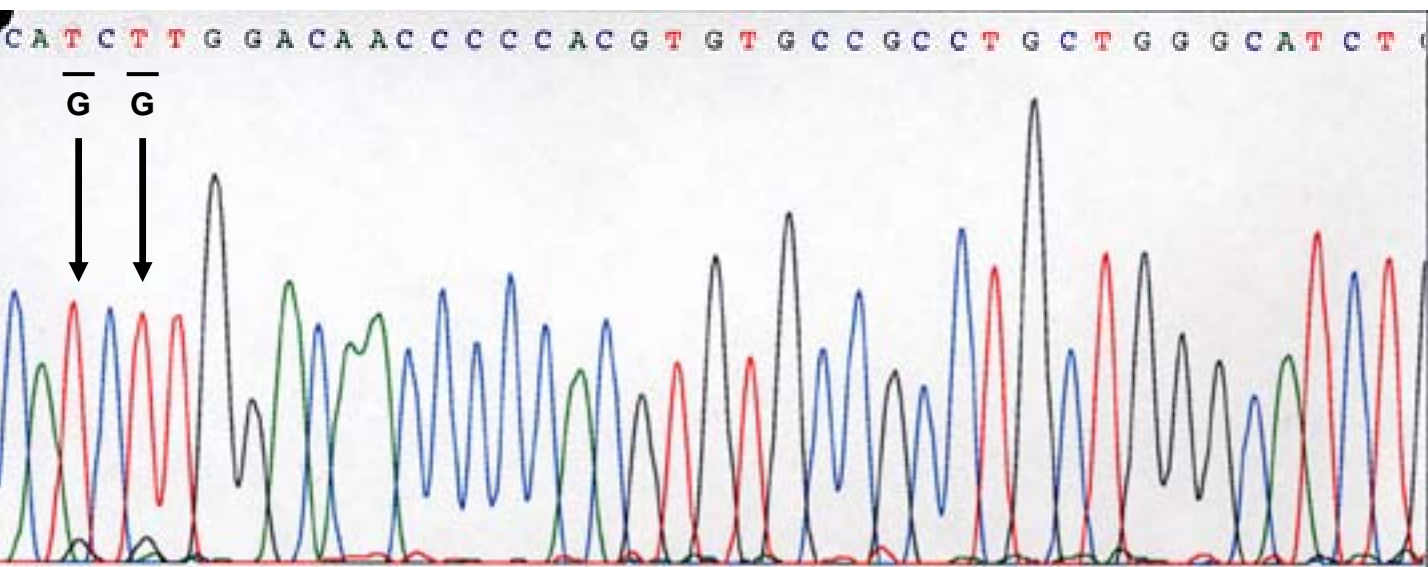


Fig. 2

(a)



(b)

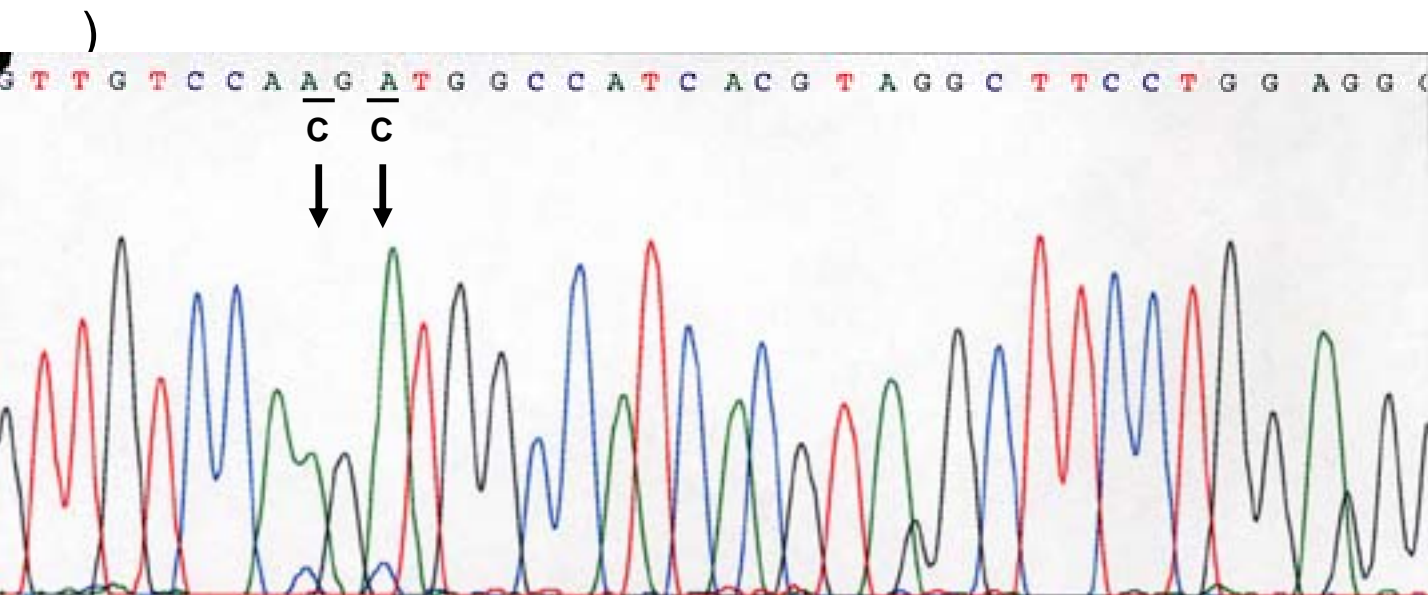


Fig. 3

