



Title	ON DAUGHTER CYSTS OF COENURUS SERIALIS GERVAIS, 1847
Author(s)	YAMASHITA, Jiro; OHBAYASHI, Masashi; KONNO, Seiji
Citation	Japanese Journal of Veterinary Research, 5(1), 14-18
Issue Date	1957-03-25
DOI	https://doi.org/10.14943/jjvr.5.1.14
Doc URL	https://hdl.handle.net/2115/1702
Type	departmental bulletin paper
File Information	KJ00002373101.pdf



ON DAUGHTER CYSTS OF *COENURUS SERIALIS*
GERVAIS, 1847

JIRO YAMASHITA, Masashi OHBAYASHI
and Seiji KONNO

*Department of Parasitology, Faculty of Veterinary
Medicine, Hokkaido University, Sapporo, Japan*

(Received for publication, January 12, 1957)

It is well known that the *Multiceps serialis* is a parasite in the intestinal tract of the dog, fox and jackal and as a bladder worm called *Coenurus serialis* its larva occurs in the subcutaneous tissues or intramuscular connective tissues chiefly of the rabbit and hare. The larva has also been found from man, baboon and mandril. This parasite is cosmopolitan; in Japan it is common in the hare.

In general the term "coenurus" is used for a large type of bladder worm in which a number of invaginated and developing holdfasts are present and is different from "hydatid" in which there are daughter cysts budded off from the germinative membrane. The authors have collected many individuals of *C. serialis* from various regions in Japan and Manchuria over a period of many years. The characters of all those cysts have fitted the definition of "coenurus". Recently, however, the authors have found 2 coenuri in which small cysts are contained. This finding is new to Japan.

Here it is proposed to describe the morphological characters of these coenuri, especially a very interesting new fact found in the daughter cysts.

DESCRIPTION

Recently both preserved and fresh materials of coenuri collected from the hares, *Lepus timidus ainu* BARRETT-HAMILTON, were examined. Two examples of coenuri contained daughter cysts were found.

The 1st Case:

A coenurus was taken from the subcutaneous tissues of the right shoulder of a hare captured in Teine Village situated between Sapporo and Otaru, Hokkaido, in July, 1953. The hare was kept in the Zoological Institute, Faculty of Agriculture, Hokkaido University; it died in May, 1956. The coenurus is elliptical in shape and 3.5×5.0 cm in size. The scolices are about 250 in number; they occur in roughly linear groups. Within the cyst, 26 small ones, 2.0~2.8×1.6~2.4 mm in size, are free from the inner wall of the mother bladder individually. Three other small cysts are found hanging down from the inner wall of the mother bladder. Every daughter cyst has only 1 scolex respectively; their appearance are like *Cysticercus*.

The 2nd Case:

It was taken from the intramuscular connective tissues of a hare which was killed at the foot of Mt. Akaiwa near Otaru by Mr. I. SASAKI, a hunter who lived in Otaru City, in July, 1953; The animal was sent to this department. Among 6 coenuri, 1 coenurus, 6.5×2.4 cm in size, having a gourd-shaped narrow part, contained 42 small daughter cysts. Among these, 6 cysts, 5~9×2~8 mm in size, are floating separately within the lymphoid fluid of the mother bladder while the others present an appearance like bunches of groups separated into 4 groups, consisting of 2, 7, 11 and 16 small cysts. These small cysts forming the groups are 2~3.5×2~3 mm in size, and each of them is interconnected with a membranous narrow stem respectively, while one is free from the wall of the mother cyst and floats within the lymphoid fluid. The most of floating and hanging cysts evaginate scolices.

The daughter cysts would seem to be formed by invagination of the mother cyst wall and consequent pinching off from the inner surface of the mother bladder. By histological observation, the structure of the wall of mother bladder containing the daughter cysts is found similar to that of the normal cyst of a coenurus, while the wall of a daughter cyst is very different from that of the mother bladder. Histologically the daughter cyst wall is similar to the structure of the mother cyst wall turned inside out. That is, the homogeneous thin cuticular layer is inside and the thin parenchymatous tissue is outside in daughter cyst wall. This is a very interesting and important finding.

The rostellar hooks are 28 to 32 in number; large and small ones are alternately arranged in two rows. Their shape is as shown in Fig. 1. The authors measured the size of the rostellar

FIG. 1. *Rostellar Hooks from Daughter Cyst (A) and Mother Cyst (B)*

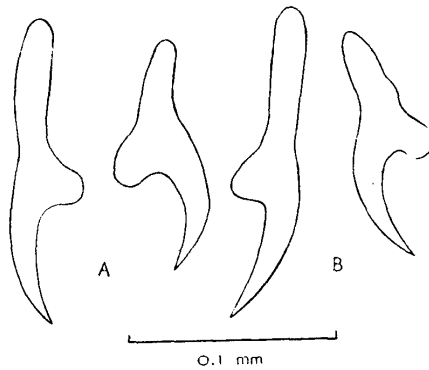


FIG. 2. *Diagram of Measurement of Rostellar Hooks*

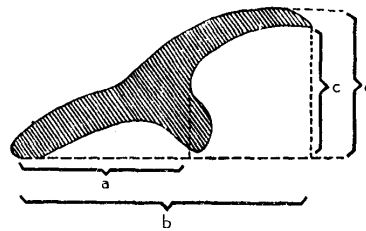


TABLE 1. *Dimensions of Rostellar Hooks in μ*

CYSTS	LARGE HOOKS				SMALL HOOKS			
	a	b	c	d	a	b	c	d
Mother	88	148	60	72	64	100	56	64
	88	148	64	72	60	100	52	68
	88	144	64	76	60	104	56	64
Daughter	88	144	60	76	64	104	60	68
	88	144	64	76	60	100	52	64
	88	148	60	72	60	100	56	64

Designations correspond to those in Fig. 2.

hooks by the method, as shown in Fig. 2, used by RANQUE and NICOLI (1955). Dimensions of daughter cysts in table show only those of large, medium and small cysts, from the measurements by the authors. Consequently, the difference between mother and daughter cysts in number, size and shape of rostellar hooks are not visible. Also it is clear that the rostellar hooks of the daughter cysts develop completely and that they are similar without distinction according to the size of the cyst. These bladder worms are identified with *Coenurus serialis* GERVAIS, 1847.

DISCUSSION

The daughter cyst formation of the bladder worms has been well known for long only in hydatid, while recently it has become known that such a formation occurs infrequently also in the other bladder worms.

On *Coenurus serialis* in the rabbit, NEUMANN (1908) stated that the bladder offers a peculiarity which is never present in *Coenurus cerebralis* by budding, either on its inner or outer surface, it sometimes produces bladders which originated like itself and are endowed with the property of originating scolices in every respect similar to those of the mother bladder. According to the present authors' study, sometimes the *Coenurus serialis* is able to bud off daughter cysts by stalk certainly as NEUMANN says, while the wall of a daughter cyst is different from that of the mother cyst in histological structure as above mentioned. It is abnormal.

In man, about 20 cases of coenurus infection have been recorded mainly in France and Africa. They are often abnormal types of coenurus. Deformation of the scolices is generally absent in unilocular cysts, but in the case of the multilocular cysts it has excited remark. So the present authors feel that in an abnormal site and an abnormal host the bladder worms may fail to exhibit a normal morphology.

What appears to be a case of external budding on the part of a bladder worm was described by HOLDOBER (1937) under the term *Cysticercus multiiformis*. It was found in Germany in the subcutaneous connective tissue of a fox. There was an interconnected mass of bladders of various size, showing varying degrees of budding usually from the pole opposite the holdfast. CRUSZ (1948) had added considerably to knowledge of *Cysticercus* development. He describes in detail a process of annular constriction of *C. pisiiformis* where by two or even three separate individuals are produced, the posterior individuals however being without a holdfast. A specimen of *C. tenuicollis* is described which contained many daughter cysts in various stages of development and one being fully developed. On the basis of such recent discoveries, old knowledge of the bladder worms should be reviewed.

SUMMARY

1. The authors have found *Coenurus serialis* in which many daughter cysts are contained, occurring in the subcutaneous tissues of hares. This finding is new to Japan.

2. Morphological and histological descriptions of the daughter cysts are presented.

3. A new important fact is described, that the histological structure of the daughter cyst wall is similar to that of the mother bladder turned inside out.

4. Because of recent discoveries, the authors feel that the old knowledge of various bladder worms should be reviewed and the daughter cyst should be examined histologically.

The authors wish to express their gratitude to Mr. I. SASAKI and Mr. H. MORI for kindness in supplying materials. Thanks are extended to Mr. KITAMURA for his cooperation in taking photos.

REFERENCES

- 1) CRUSZ, H. (1948): *J. Helminth.*, **22**, 165.
- 2) HOLLDOBER, K. (1937): *Z. Parasitenk.*, **9**, 527.
- 3) NEUMANN, L. G. (1908): A treatise on the parasites and parasitic diseases of the domesticated animals, New York.
- 4) RANQUE, J. & R. NICOLI (1955): *Ann. Parasit. hum. comp.*, **30**, 22.
- 5) RAPER, A. B. & G. C. DOCKERAY (1956): *Ann. trop. Med. Parasit.*, **50**, 121.
- 6) WARDLE, R. A. & J. A. MCLEOD (1952): *The Zoology of Tapeworms*, Minneapolis.

EXPLANATION OF PLATES

PLATE I.

- Fig. 1. Three individuals in normal type of *C. serialis*.
- Fig. 2. Showing some daughter cysts separated from and kept in mother bladder and also many scolices of the inner surface of mother bladder in the 1st case.
- Fig. 3. The 2nd case, occurring in the intramuscular connective tissues of the right shoulder of a hare.
- Fig. 4. The same case separated from tissues. Showing many daughter cysts and scolices of mother bladder.
- Fig. 5. An interconnected mass of daughter cysts floating within lymphoid fluid of mother bladder.
- Figs. 6~8. Showing histological structure of the cyst wall. 6, mother bladder; 7 & 8, daughter cysts and near scolex.

PLATE II. Rostellar hooks. Figs. 9 & 10, mother bladder; 11~14, daughter cysts.

- Fig. 9. In oblique view.
- Figs. 10 & 13. Removed from a scolex respectively.
- Fig. 11. Regular arrangement, front view.
- Fig. 12. In oblique view.
- Fig. 14. In oblique view, pressed somewhat strongly.

