



HOKKAIDO UNIVERSITY

Title	DISCOVERY OF A CASE OF TRICHINOSIS IN JAPAN
Author(s)	OHBAYASHI, Masashi; SATOH, Hiroshi
Citation	Japanese Journal of Veterinary Research, 5(2), 39-42
Issue Date	1957-06-25
DOI	https://doi.org/10.14943/jjvr.5.2.39
Doc URL	https://hdl.handle.net/2115/1705
Type	departmental bulletin paper
File Information	KJ00002373110.pdf



DISCOVERY OF A CASE OF TRICHINOSIS IN JAPAN

Masashi OHBAYASHI and Hiroshi SATOH

*Department of Parasitology and Department of Veterinary
Pathology, Faculty of Veterinary Medicine,
Hokkaido University, Sapporo, Japan*

(Received for publication, May 2, 1957)

Trichinosis is caused by *Trichinella spiralis* (OWEN, 1835), RAILLIET, 1895 which is widely distributed in various areas of the world. This nematode can be found in Asia and canine cases have also been observed in Manchuria²⁾. In Japan, however, there has been no case reported with proof of trichina cyst. The present authors could recently discover a case of canine muscle trichinosis in Sapporo; a description of the case is presented in this report.

Trichinosis is one of the dangerous invasion-diseases in humans and animals. Therefore, in Japan, those who are concerned with medicine, especially public health, should give careful consideration to this disease.

DESCRIPTION

Clinical History The case was a mongrel male dog, 7 years old. The dog was born in Nanae Village, southern Hokkaido and passed its puppy period in Hakodate. At the age of 1 year and a half, the animal was transferred to Sapporo. It was suffered from so-called transmissible canine veneral granuloma and died on April 22, 1953, two days after an operation for tumors. Recently, the formalin-fixed materials preserved in the Department of Veterinary Pathology were re-examined in detail and trichinosis was ascertained.

Anatomical Findings In addition to the lesions of veneral granuloma, some pathological changes were discovered; dilatation of the right cardiac ventricle, epicardiac petechiae, chronic passive hyperemia in various organs and hemorrhagic infarction in the spleen. No trichinous foci were observed macroscopically.

Histological Findings Reserved muscle tissues were the tongue and a piece of cutaneous muscle.

Tongue Sporadic presence of trichina cysts was ascertained, tissue reaction against the cyst was very slight. The number of cysts in the cross section preparation of the middle part of the tongue was more than 10. Each cyst always enclosed one larva; the capsule was homogeneous and hyalinous; sections of coiled larva were found in the cyst and degenerated muscle detritus with large or small nuclei sometimes existed within the cyst. The cyst was situated with its long axis parallel to the muscle fiber. Pericyclic connective tissue reaction was very slight even if it existed at all. Some cysts had groups

of fatty cells at the poles, but the differentiation between that fat and the proper interstitial fatty tissue was not easily determined. No calcification was found in the cyst.

Cutaneous muscle Trichinous cysts were detected as well as in the tongue muscle.

Myocardium Multiple myodegeneration was remarkable showing small or large foci. The muscle fibers in the focus showed hyaline waxy degeneration, hydropic degeneration, basophilic granular metamorphosis, fragmentation or segmentation, and disappearance of striations. Together with those regressive changes, interstitial edema and hyperemia existed accompanied by slight cell proliferation and neutrophile leucocyte infiltration.

Other organs Subacute glomerulonephritis was found in the kidney. Other lesions observed macroscopically were also confirmed histologically.

Morphology of the Larva Although collection of the larvae from the fixed tissue materials was not easy, removal of the cysts and larvae under the microscope and digestion by pepsin were carried out.

The size of 4 cysts was 0.36×0.20 , 0.32×0.20 , 0.36×0.20 and 0.34×0.16 mm respectively, however, these cysts were somewhat contracted by the mounting chemicals. The larva coiled spirally; its anterior end was more slender than the posterior and the transverse annulation of the cuticle was clear. The internal structure was not very distinct, but the characteristic esophagus, intestinal tract and gonad were distinguishable. The esophagus was about two-thirds of the body in length (Table 1).

TABLE 1. *Measurement of Larva* (mm)

LENGTH OF BODY	WIDTH OF BODY	LENGTH OF ESOPHAGUS
0.98	0.027	0.66
1.16	0.039	0.83
1.12	0.036	0.77

DISCUSSION

Trichinella spiralis has been known since old times in various countries; it has been studied widely and minutely by various authors. Supreme efforts to eradicate trichinosis have been made. The existence of trichinosis, however, is still found in many countries; for example, human and animal trichinosis is detectable in the U. S. A.³⁾ The existence of the trichina worm has been denied absolutely in Japan, but the occurrence of the worm in this country has been shown by the present authors' discovery. Trichina worm causes a disease dangerous to both humans and animals, therefore it cannot be overlooked at the time of meat inspection. The necessity of paying more attention to trichinosis should be stressed in the future.

As to the cause of death in the present case, from the pathological view point, it can be said that multiple myocardiac degeneration played a leading role.

Then, the difference between the lesions which occur in such a case and the changes which have been described in trichinosis by some authors becomes a subject of discussion. In the present case, it is obvious that the trichina cyst in the tongue muscle fully developed and the pericystic tissue reaction had already ceased. Therefore, giving consideration to the absence of calcification of cyst capsule, considerable time had elapsed since the invasion, but the cyst was not very old, that is to say, the case had reached a subacute stage in regard to trichinosis. The myocardiac lesion can be considered to be fresh. It is consequently risky to consider trichinosis unqualifiedly as the decisive cause of myocardiac degeneration.

CONCLUSION

It has been said that the *Trichinella spiralis* does not exist in Japan. However, the authors could discover muscle trichinosis in the dog as the first case.

The authors wish to express their cordial gratitude to Prof. S. YAMAGIWA and Prof. J. YAMASHITA for their helpful advice.

REFERENCES

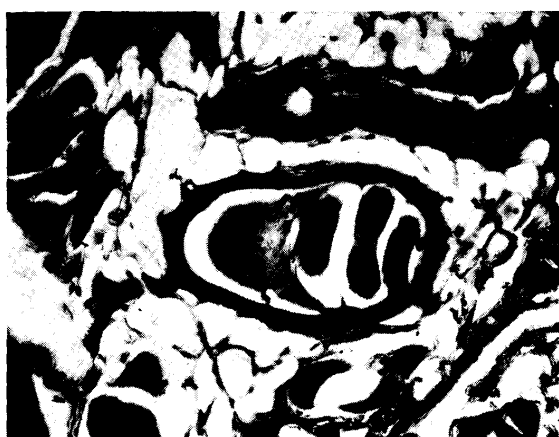- 1) GOULD, S. E. (1945): Trichinosis. C. C. THOMAS, Springfield.
- 2) YUKAWA, C. (1934): *Manshû Jûichikusan Gakkai Zasshi*, **16**, 155 (in Japanese).
- 3) ZIMMERMANN, W. J., L. H. SCHWARTE & H. E. BIESTER (1956): *Amer. J. publ. Hlth.*, **46**, 313.

EXPLANATION OF PLATE

- Figs. 1~3. *Trichina* cysts in the tongue muscle. Hematoxylin-eosin. $\times 125$.
Fig. 4. *Trichina* cyst. Glycerin-gelatin-mounted. $\times 125$.
Fig. 5. *Trichina* larva. Lacto-phenol-mounted. $\times 200$.
Fig. 6. *Trichina* larva. Gum-chloral-mounted. $\times 200$.



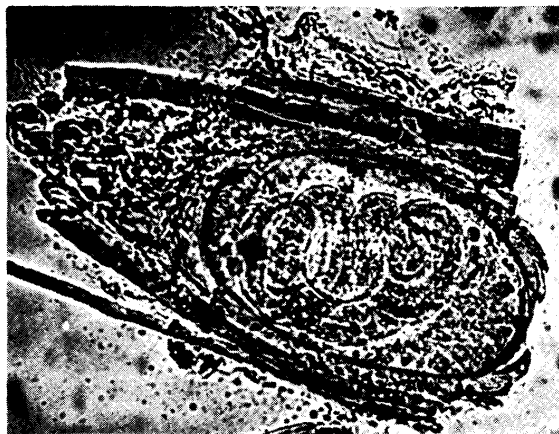1



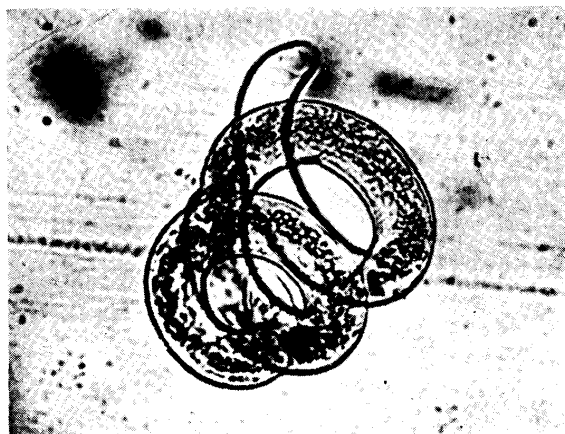
2



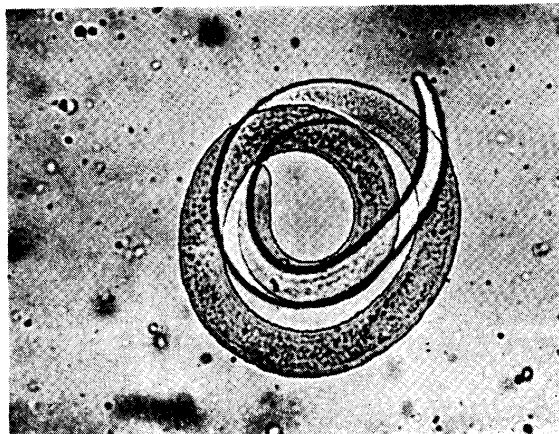
3



4



5



6