



# HOKKAIDO UNIVERSITY

Title	STUDIES ON INFECTIOUS CANINE HEPATITIS I. : HISTOPATHOLOGICAL STUDIES ON SPONTANEOUS CASES
Author(s)	FUJIMOTO, Yutaka
Citation	Japanese Journal of Veterinary Research, 5(2), 51-70
Issue Date	1957-06-25
DOI	<a href="https://doi.org/10.14943/jjvr.5.2.51">https://doi.org/10.14943/jjvr.5.2.51</a>
Doc URL	<a href="https://hdl.handle.net/2115/1707">https://hdl.handle.net/2115/1707</a>
Type	departmental bulletin paper
File Information	KJ00002373112.pdf



# STUDIES ON INFECTIOUS CANINE HEPATITIS I. HISTOPATHOLOGICAL STUDIES ON SPONTANEOUS CASES

Yutaka FUJIMOTO

*Department of Veterinary Pathology,  
Faculty of Veterinary Medicine,  
Hokkaido University, Sapporo, Japan*

(Received for publication, May 2, 1957)

## INTRODUCTION

Since the nosological identification of infectious canine hepatitis or *Hepatitis contagiosa canis* (H. c. c.) by RUBARTH (1947) in Sweden, many works have been published one after the another in many countries. For example, in U. S. A.<sup>6,8,11,17,33,37,39</sup>, Great Britain<sup>21,43,45,53,60,61</sup>, Australia<sup>73</sup>, Belgium<sup>23</sup>, Switzerland<sup>51,63,70</sup>, Germany<sup>13,59</sup>, Holland<sup>1</sup>, Italy<sup>14,54</sup>, France<sup>28</sup>, Hungary<sup>46</sup>, Morocco<sup>53</sup>, Canada<sup>38</sup>, Brazil<sup>22</sup> and Russia<sup>10</sup>.

In Japan, the first four cases of H. c. c. were autopsied by the present author and co-workers in 1951 and their reports were made in 1952<sup>25</sup> and 1953<sup>26,27</sup>. After that, autopsied spontaneous cases of the disease in this laboratory reached 14 in number including dogs (11 cases) and foxes (3 cases) by 1955.

On the other hand, the occurrence of human epidemic hepatitis was recently reported in Okayama Prefecture. With such international prevalence of the disease, the problems of clinical medicine, pathology, epidemiology and etiology of the disease have become topics of active discussion.

Under such circumstances, at the symposium on "Etiology and pathology of epidemic hepatitis" of the 2nd Meeting of Jap. Soc. Virology in October 1954, the present author's chief and teacher Prof. YAMAGIWA presented a general review of H. c. c. and forewarned of the prevalence of the disease.

In 1955, OSAMURA et al.\* reported the isolation of H. c. c. virus from the present author's 2 spontaneous cases, serial transmission experiment on puppies and complement fixation test of the disease. At the same time, OCHI et al.\*\* found one spontaneous case of H. c. c. in Tokyo and made transmission experiments with this material. They also compared the disease set up by known H. c. c. virus strains with their isolated one. At the same time, MOCHIZUKI et al.\* demonstrated one spontaneous case of H. c. c. which they encountered in Osaka.

\* The 39th Meeting of Jap. Soc. Vet. Sci. in April 1955.

\*\* The 3rd Meeting of Jap. Soc. Virology in April 1955.

Hereupon, studies on H. c. c. have gradually become active and they now seem to be prevalent throughout Japan. Therefore, the presence of the disease is repeatedly confirmed.

Hitherto, the disease has been confused with toxic liver dystrophy<sup>7,12,40,44 64</sup>, canine distemper<sup>18)</sup> and enzootic fox encephalitis<sup>29-39)</sup>. But now it is obvious that H. c. c. is different from canine distemper and is the same disease as enzootic fox encephalitis caused by the same virus<sup>71-73)</sup>.

However, pathological reports on the disease are scarce in Japan. The present author hitherto could not fully understand this disease on account of his poor materials. However, up to date, 14 spontaneous cases have been experienced as well as a large number of experimental cases; accordingly the writer's pathological knowledge concerning the disease has greatly increased. In the present studies the pathological findings of spontaneous cases are to be described.

#### MATERIALS AND METHODS

Materials for the investigations, as listed in table 1, consist of a total of 14 cases including dogs (11 cases) and foxes (3 cases). During the period of 5 years (1951~1955) in which these materials (14 cases) were collected, 263 cases (dogs and foxes) were subjected to postmortem examination at our Department. An incidence showed 5.32% in our necropsy material. All organs were thoroughly investigated except 2 cases of foxes which

TABLE 1. *Summary of Investigated Materials*

CASE NO.	AUTOPSY NO.	DURATION OF ILLNESS	TERMINATION	DATE OF AUTOPSY	ANIMAL	AGE	SEX	BREED	LOCATION
1	3069	8 days	†	1951 20/II	dog	2M	♀	Shepherd	Sapporo
2	F407	14 "	"	" 11/X	fox	7M	"	Silver	Shin-totsukawa
3*	3224	3~4 "	"	" 11/XII	dog	6M	♂	Setter	Sapporo
4*	3225	" "	"	" 13/XII	"	"	♀	"	"
5*	3226	" "	"	" "	"	"	♂	"	"
6*	3227	" "	"	" "	"	"	♀	"	"
7	F 1	? "	"	" /XII	fox	?	?	Silver	Shin-totsukawa
8	F 2	" "	"	" "	"	"	"	"	"
9	3394	7 "	"	1953 6/IV	dog	2Y	♂	Crossbreed	Sapporo
10**	3634	2 "	"	1954 20/I	"	6M	"	Tosainu	"
11**	3538	3 "	"	" 8/II	"	5M	"	Shepherd	"
12	3607	2~3 "	"	1955 9/II	"	5Y	"	"	"
13	3644	7 "	"	" 6/X	"	1Y	"	Airedale terrier	"
14	3656	3 "	"	" 5/XI	"	14M	"	Crossbreed	"

\* Litter, \*\* Cases from which H. c. c. virus strains were isolated by OSAMURA et al.<sup>58)</sup>

were examined on only the brain tissue. All cases subjected to bacteriological examination showed negative results.

After macroscopical observations, materials were fixed promptly in 10% formalin, some of them in Zenker's fluid and Carnoy's fluid. Paraffin or frozen sections were prepared. Sections were stained chiefly with hematoxylin-eosin, WEIGERT stain for elastic fiber, VAN GIESON stain for collagen fiber, GÖMÖRI's or PAP's methods of BIELSCHOWSKY-MARESCH's silver impregnation for argyrophile fiber and Sudan III for neutral fat. On the other hand, histochemical observations were made by such means as Feulgen technique, pyronin-methylgreen stain, ribonuclease test, thionine stain, MCMANUS's PAS method and phloxin-tartrazin stain.

## RESULTS

### Clinical Pictures

The duration of the disease (period from the time the animal shows signs of sickness to death) was 2~14 days in author's spontaneous cases, especially most of cases died with the rapid course of the disease (2~4 days). H. c. c. occurred chiefly in young animals; most cases were under one year old. The youngest animal was 2 months, the oldest 5 years. Owing to the rapid course of the disease, death occurred before the owner became aware of the symptoms, or came to the hospital for consultation (Nos. 3, 4, 5 & 6).

The following symptoms were observed in the peracute cases of which symptoms were found and cases with more protracted lethal course. The symptoms observed in the first place were apathy, anorexia, polydipsia and high fever (40~41°C). Nasal discharge, cough, diarrhea and vomiting were often observed. The icteric coloration of conjunctivae (No. 12), and icteric urine (No. 10), marked inflation of the abdomen (No. 1) and petechial hemorrhages in the gingiva (No. 9) were rarely observed in the respective cases. In the last stage of the disease, the body temperature fell and diarrhea with sometimes hemorrhagic character were seen. Some cases showed dystasia and unconsciousness (No. 14). Sometimes animals manifested increased pulse and respiration rates and finally died.

In the cases of foxes the nervous symptoms were conspicuous. Dyspnea, convulsions and tonic-clonic spasms in the extremities were often observed. They manifested encephalitic symptoms. These symptoms could hardly be seen in dogs.

### Postmortem Findings

The subcutaneous connective tissue, especially at the submaxillary, neck, forepart of shoulders and brisket, hypo-gastric portion and flanks were moist, gelatinous and sometimes dark red in color owing to the blood resorption in the cut surface. Ascites was thin, clear, slightly yellowish and sometimes bloody color (75%). The increase of ascites is one of the important findings of the disease.

A pronounced edematous swelling (0.6 cm, No. 3) in the subserosa of the gall-bladder was also one of the most characteristic findings (67%). In many cases, fine fibrinous deposits on the surface of the gall-bladder wall were found. This edema was sometimes accompanied by hemorrhages, so the gall-bladder wall showed a dark-red or pure black in color.

The thymus and pancreas showed marked interstitial edema with sometimes hemorrhages and gelatinous appearance. In both organs, edema was observed in 75 and 45% of frequency respectively. The change which attracted attention to a certain extent was the subserous edema around the portal regions. *Lnn. portarum* as well as *Lnn. duodenales* showed outstanding edematous swelling. Dilatation and stagnation were certainly observed around the lymph vessels. Edema was often seen in the mesenterium and its lymph nodes, mediastinum and its lymph nodes, heart valves, tissue around the aortae and its lymph nodes, subserous tissue of the digestive canals and tissue around the meninges.

The liver was sometimes enlarged in size. The surface had a mottled pattern of lobular figure which was more visible than in normal condition. The organ was light yellowish-brown or reddish-brown in color, but sometimes a dark red due to the greatly increased blood contents. The capsule was tense, and sometimes white membranous or thin fibrinous threads were precipitated on the surface of the liver. The fibrinous coating in *Incissurae interlobares* was often adhered, but was easily exfoliated. On the cut surface of the liver, the central veins were dilated and the lobuli design was distinct. As a rule, the blood content in the liver was increased and especially in centrolobular region; the pattern on the cut surface was more distinctly visible than in normal organ due to the dark reddish-brown color of the central part of the lobule or light yellowish-brown color of the peripheral part with a reticular configuration. The author sometimes encountered findings similar to those in cases of yellow or red liver dystrophy.

The spleen was sometimes enlarged in 66% of cases. The blood content of the organ was usually rich. Its cut surface bulged and was dark red or black. The trabeculae and Malpighian bodies were indistinct, but sometimes the latter was distinct.

The tonsils were often moist and congested with petechial hemorrhages. In about half of the cases, the tonsils were enlarged.

The heart sometimes showed a dilatation of the right side and subendocardiac hemorrhages were found frequently.

In the lungs, characteristic lesions were not encountered, but congestive edema and catarrhal bronchopneumonia were often observed.

On the other hand, hemorrhagic gastro-enteritis, the enlargement of intestinal lymph follicles and subserous edema were clearly seen. The parasites encountered in author's materials were mainly *Toxocara canis*, then *Ancylostoma caninum*, *Trichuris vulpis* and *Dipylidium caninum*.

In the central nervous system, meningeal congestion, edema around the tissue of meninges and petechial hemorrhages in the brain parenchyma were observed. The bone marrow in many cases showed red marrow and no remarkable changes. Icterus in the conjunctivae, the mucosa of the mouth and the subcutaneous tissue were also observed (Nos. 9~13). In a few cases, general icterus were noted.

#### Histological Findings

LIVER: The author classified the liver lesions as follows: 1) Parenchymal cell degeneration, 2) Inflammatory cell reaction, 3) Activity of reticulo-endothelial cells, 4) Circulatory disturbances, 5) Nuclear inclusions.

Histological features are listed in table 2. The outline of the findings of the disease may be analytically described under three general heads as follows.

1) Parenchymal changes

*Central and midzonal necrosis*: Degenerative changes in the liver cells appeared predominantly in the central and midzonal areas of the lobules, but some of them extended into the peripheral areas and some of them were independently distributed as irregular lesions. Most cases represented central necrotic or necrobiotic foci except the few which did not accompanied these lesions (Nos. 2 & 14). Usually the border of the centrolobular necrotic focus was sharply demarcated from the better-preserved peripheral lobules. The sinusoids in the liver were distended, especially often causing the compression of the central liver cell cords (central congestive edema). "Dissociation" of liver cells was usually noted and the cells became more or less rounded and swollen. Some of the cytoplasm had fine granulated vacuoles; cell boundaries became more indistinct, whilst the cytoplasm assumed a more marked eosinophilic character and broke into small pieces. Degenerative changes were especially conspicuous in the cell nuclei in which karyorrhexis was most noticeable. Pyknosis and hyperchromatosis of the nuclear membrane were also observed. The latter changes were frequently noted in the better-preserved peripheral lobules with nuclear inclusions. In the centrolobular parts of the liver, regressive changes were, in some cases, so intensive that most of the liver cells were completely necrotized and lost; such areas were occupied by erythrocytes as hemorrhages and the DISSE's spaces were markedly dilated. In more protracted cases, intensive necrotic foci were often observed and incidence of the inclusion bodies were decreased in parallel to these lesions. In one case of the liver (No. 9), the author observed a toxoplasma colony accompanied by hepatitis.

*Eosinophilic necrosis*: Single necrotic liver cells distributed in the liver lobules were characterized by increased eosinophilia of the cytoplasm and pyknosis, karyorrhexis and sometimes loss of nuclei. These changes have already been described by AXENFELD and BRASS as "eosinophil degeneration." These changes were observed at any stage of hepatitis, but especially it seemed to occur in an early stage of the disease. This fact was confirmed in author's experimental cases (2nd report). Isolated liver cells become round with pyknotic nucleus and marked eosinophilic cytoplasm, then the cells demonstrate shrinkage, the nucleus becoming more hyperchromatic and smaller. Finally, the nucleus undergoes karyorrhexis and disappears leaving small homogeneous-spherical and intensely-acidophilic bodies in the blood or in the DISSE's spaces. Such a body is positive by PAS method. Pentose nucleic acid (PNA) in this body was decreased or almost completely lacking.

*Cytoplasmic basophilia of hepatic cells*: It is already known that cytoplasmic basophilia of hepatic cells indicates change in pentose nucleic acid (PNA)<sup>21,74</sup>. Parallel to the degenerated cellular changes, PNA of liver cells decreased or disappeared in the centrolobular parts in almost all cases of the disease. It seems that this change is one of the characteristic changes of the disease.

*Polysaccharide reaction in hepatic cells*: In relatively intact liver cells, no remarkable increase nor decrease of PAS positive granules could be observed, but degenerated cell area showed positive to PAS reaction and was distinctly demarcated from adjacent area. Macrophages in sinusoids were often positive in PAS reaction. Hyalinous droplets which

showed positive to PAS reaction were detected in the liver cells and sinusoids (hyaline degeneration).

*Fatty degeneration of hepatic cells:* Fatty degeneration of hepatic cells was often conspicuous in the necrotic areas, but the degree was not always parallel to the necrosis. Fine fatty droplets were frequently observed in the endothelium and macrophages. In some of the liver cells, fine granular fatty droplets which were stained orange with Sudan III especially in the degenerated liver cells were markedly observed (Nos. 5 & 9).

*Nuclear inclusions:* Acidophilic or basophilic nuclear inclusions were seen in the nuclei of liver cells. This is the most important finding for the diagnosis of H.c.c. Inclusions appeared in both necrotic and non-necrotic peripheral intact areas. A large number of inclusions could often be found in the degenerating cells. In the acute fatal cases, inclusions were observed in large number, but in the protracted fatal cases, the rate of appearance showed a downward tendency. These inclusions contained desoxyribonucleic acid (DNA) and ribonucleic acid (RNA).

## 2) Interstitial changes

*KUPFFER cell and sinusoidal cell proliferation:* Increase, swelling and mobilization of KUPFFER cells and sinusoidal endothelium were conspicuous in all cases. Mitosis was often observed in the actively proliferated cases. As a rule, the cytoplasm of these cells was rich in RNA. Many of the macrophages had erythrocytes or hemosiderin deposits, fat and cellular fragments in the cytoplasm. Sometimes marked hemosiderosis was observed in a few cases. Regressive changes of these cells were conspicuous; cells often contained nuclear inclusions.

*Inflammatory component in the interstitium:* It was characterized by infiltrating chiefly mononuclear cells, mixed with polymorphonuclears, and lymphocytes was diffuse and very extensive. Plasma cells could not be found in the sinusoids in the present cases. Appearance of polymorphonuclear cells was variable according to the stage of the disease, but they are apt to appear in the centrolobular area as an inflammatory reaction in the marked necrotic lesions.

*Changes in GLISSON'S capsule:* As a rule, edema and hemorrhages were conspicuous. Dilatation and stagnation of the lymph vessels were usually clearly recognizable. The larger vessels (*V. portae* and *V. interlobularis*) always were greatly dilated and endothelia with frequent nuclear inclusions were swollen. The cellular infiltration was relatively slight in the periportal areas, but infiltrating cells were made up chiefly of histiocytes mixed with lymphocytes, sometimes plasma cells and macrophages. Near the periportal area, a granulomatous proliferation of endothelial cells was found (No. 5). No proliferation or formation of bile ducts were seen, but in some cases connective tissue proliferation was observed in the periportal areas (Nos. 10, 11, 12 & 13). In only one case (No. 12), the annular muscle bundles in the wall of *Vv. hepaticae* were prominent in the lumen of the vessels and in one case (No. 13), marked histiocytic proliferation was observed.

*Reticulin disturbances:* Despite an apparently severe destruction of the liver cells, the reticular fibers of the liver were found to be intact. But in the cases with marked centrolobular hemorrhages (Nos. 9, 10, 12 & 13), the argentophil character had been partly lost. Proliferation and thickness of reticular fibers were not observed.

*Bile thrombi*: Bile thrombi and bile stagnation were found in 5 cases. In 3 of them (Nos. 5, 6 & 9), fine granular bile pigments were observed in the liver cells.

*Nuclear inclusions*: KUPFFER cells and sinusoidal endothelium contained a large number of nuclear inclusions. Especially the cells containing inclusion bodies were usually degenerative. The various-sized inclusions were oval or elliptical in shape coinciding with the shape of the nucleus. The wall of the nucleus was rich in chromatin and inclusions became to be surrounded by a light halo. In general, a nucleolus was more indistinct than liver cells.

### 3) Circulatory disturbances

The blood content in the liver was increased in all cases and the larger vessels (*V. portae*, *V. hepatica*), central veins, interlobular veins and sinusoids were very dilated chiefly centrolobularly. Hemorrhages were often found in centrolobular regions coinciding with central necrosis and in the GLISSON'S capsule. The dilatation of DISSE'S spaces, due to the marked lymph stagnation, was noted in almost all cases except one (No. 4). In such cases serous exudation and often minor local fibrinous precipitations were conspicuous. Fibrin thrombi which showed a positive reaction to WEIGERT'S fibrin stain, often occurred in the centrolobular parts of the DISSE'S spaces. The fibrinous precipitations found on the liver capsule have been regarded as a manifestation of a "*perihepatitis fibrinosa*."

**SPLEEN** The blood content in the spleen was usually increased. Hemorrhages were often observed in the Malpighian bodies and the trabeculae. The Malpighian bodies were edematous and atrophic because of a great increase of blood in the pulp. They were often enlarged; lymphocyte accumulation and pyknosis were found in the germinal center. A histiocytic cell proliferation and an increase of rounded enlarged cells were conspicuously observed around the follicles. Hemorrhages and regressive changes were frequently observed. Lysis of reticular fibers was observed in the cases in which liver destruction markedly appeared. In the red pulp, reticulum cells had become rounded and lay loosely in the tissue isolated from each other. Many of these macrophages had erythrocytes and hemodiserin deposits in the cytoplasm. In the red pulp emigration and the focal accumulation of polymorphonuclear leukocytes were often encountered. Regressive changes occurred not only in the Malpighian bodies, but also in the red pulp where karyorrhexis, pyknosis and hyalinization were conspicuous. Characteristic nuclear inclusions were observed in the reticulum cells, endothelium and adventitia cells in the walls of the sheathed arteries. Inclusions occurred rather frequently though the occurrence was less in extent than in the liver. The occurrence of inclusions varied according to the stage of the disease and individual.

**LYMPH NODES** The extent of changes was variable according to the individual lymph node. Coinciding with the gross appearance, lymph nodes histologically showed lymph stagnation, blood resorption and marked dilatation of the medullary and marginal sinuses. Especially, the edema in the hilus and that around the tissue of the lymph nodes were usually conspicuous and hemorrhages were often found in the follicles and trabeculae. The enlargement shown by the lymph nodes must partly be attributed to the increase of reticulo-cellular elements. In the germinal center of the lymphoid follicles, regressive nuclear changes were often found. The same changes simultaneously occurred in the

medullary cords and endothelial cells often accompanied by a large number of leukocytes. Nuclear inclusions were noticeable in the sinus endothelium, reticulum cells and vascular endothelium.

**KIDNEYS** The glomeruli were enlarged; they contained swelling endothelial cells often with nuclear inclusions and sometimes leukocytes. BOWMAN'S capsule was often dilated; it contained serous exudation (*glomerulonephritis acuta*). Nephrosis was often observed. In a few cases (Nos. 12 & 13), fine granular fat droplets were found presenting orange color with Sudan III stain in the convoluted tubules and HENLE'S loop though most of the cases showed negative results. The fatty degeneration of kidneys is not a characteristic changes of this disease. In the same cases, interstitial nephritis, congestion, edema and occasional hemorrhages were often found.

**TONSILS** The tonsils usually showed hyperemia, edema and sometimes hemorrhages. The lymphoid follicles were enlarged and showed necrobiosis. The proliferation of the reticulo-endothelial cells with regressive changes and increase of macrophages were found to a marked degree. Polymorphonuclear infiltration frequently occurred. Nuclear inclusions were represented in the epithelial cells with necrobiotic nuclear changes, vascular endothelium and reticulum cells.

**ADRENAL GLANDS** Sometimes focal necrobiosis was found in the *zona fasciculata* and infiltration was also found. Endothelial cells in the sinusoids as well as the parenchymal cells of the adrenal gland cortex showed swelling and often contained nuclear inclusions.

**HEART** The myocardium usually showed congestion and hemorrhages in the subendocardium, subepicardium and intermuscular tissue. Nuclear inclusions were sometimes found in the endothelial cells of the large myocardiac vessels and in those of the endocardium.

**LUNGS** The lungs usually showed hyperemia and edema. The lung alveoli were markedly dilated and often rich in cells such as proliferated histiocytes, swollen and increased endothelial cells, together with large numbers of polymorphonuclear leukocytes and lymphocytes (*Alveolitis* or *alveolar pneumonia*). Edema occurred distinctly in the peribronchial and perivascular connective tissue. In some cases, inflammations such as catarrhal or suppurative bronchitis or bronchopneumonia and focal pneumonia were observed. In one case (No. 2) hemorrhagic infarct and other hemorrhages were observed. Nuclear inclusions were found in the bronchial and vascular endothelium; especially in case 4 they were conspicuous.

**OTHER ORGANS** The thymus showed marked interstitial edema, sometimes with hemorrhagic character. The interlobular connective tissue of the pancreas as well as the thymus was edematous and sometimes showed a hemorrhagic character. In the stomach, a submucous edema was often found. Hyperplasia of lymph follicles, submucous hemorrhages and histiocytic cell proliferation were also demonstrated. In the small intestine, hemorrhagic or catarrhal enteritis and subserous edema were often observed. The enlargement of the lymph follicles and activity of the reticulum cells, with occasional necrobiotic changes were also noticed. In the large intestine, catarrhal colitis, enlargement of solitary follicles, proliferation of histiocytes and hemorrhages often with karyorrhectic changes were also observed. The nictating membrane in some cases often contained nuclear

inclusions in the epithelial cells, vascular endothelium and histiocytes. The bone marrow was congested and rich in mature or immature polymorphonuclear cells and macrophages. In some cases megakaryocytes either showed reduction in number, and usually regressive changes, or were entirely absent. Nuclear inclusions were also found in the endothelium and reticulum cells. Both in the brain and spinal cord, passive hyperemia and perivascular or subpial hemorrhages were usually noted. The endothelial cells in the vessels were often swollen and frequently showed regressive changes with nuclear inclusions. In some cases mononuclear cells—adventitia cell derivatives—, were accumulated in the perivascular tissues in the *pia mater* the wall of which often showed thickness. Serous effusions subpially and in VIRCHOW-ROBIN'S spaces were conspicuously noticeable. Sometimes a granulomatous or perivascular cell infiltration was found around the small or medium

TABLE 2. *Histological Features of the Disease Found in the Liver*

DESCRIPTION OF CHANGES		CASE NO.													
		1	2	3	4	5	6	9	10	11	12	13	14		
Parenchymal changes	Central necrosis	##	-	##	+	##	##	##	##	##	##	##	##	-	
	Peripheral necrosis	+	-	+	-	+	+	+	+	+	+	+	+	-	
	Eosinophilic necrosis	++	++	++	+	++	+	++	++	++	++	++	++	+	
	Dissociation	++	##	++	±	##	++	++	++	##	##	++	++	-	
	Swelling of cells	++	++	++	+	+	+	++	++	+	++	+	+	+	
	Atrophy of cells	-	-	+	+	+	+	+	+	+	+	+	+	+	
	Fat infiltration	++	-	+	±	##	±	##	++	±	++	+	+	+	
Interstitial changes	R. E. S. cell stimulation	++	++	##	++	##	##	##	++	++	##	##	+		
	Pigmented phagocytes	+	++	-	-	++	++	++	+	+	++	-	+		
	Mononuclear cells	+	+	++	+	+	++	++	+	+	##	##	+		
	Polymorphonuclears	++	+	++	++	##	++	+	+	-	+	+	+		
	Lymphocytes	+	+	+	+	+	-	++	+	+	+	+	+		
	Bile thrombi	-	-	+	+	++	++	++	-	-	-	-	-		
	Reticulin disturbance	-	-	±	-	-	-	+	+	-	+	+	-		
Circulatory disturbances	Cell infiltration in G. capsule	±	-	-	+	+	+	++	+	+	++	##	+		
	Hemorrhages	-	++	++	+	++	##	##	++	+	##	##	-		
	Edema	-	-	##	+	+	+	+	++	++	+	++	+		
	Dilatation of sinusoids	+	++	+	+	++	++	++	++	++	##	++	++		
	Dilatation of DISSE'S spaces	+	+	+	-	++	+	+	++	+	++	++	++		
	Fibrin	-	+	++	+	+	++	++	++	++	+	##	+		
	Inclusions	Hepatic cells	++	##	##	++	##	##	+	++	##	++	##	+	
Endothelium		++	++	##	++	##	##	+	++	##	++	##	+		

Materials: cases Nos. 7 and 8 were not available.

R. E. S. cell: Reticulo-endothelial cell.

sized vessels. Regressive changes were often evident in nerve cells and vascular endothelium. Sometimes polymorphonuclear cells accompanied these changes. Glia cell reaction was relatively slight, but nodular glia cell foci were frequently distributed in the brain and *medulla oblongata*. No differences between fox and dog cases could be detected histopathologically in the central nervous system, but hemorrhages were conspicuous in case 2.

TABLE 3. *Frequency of Nuclear Inclusions in the Various Cells*

CELLS	CASE NO.													
	1	2	3	4	5	6	7	8	9	10	11	12	13	14
Liver parenchymal cells	++	##	##	++	##	##			+	++	##	++	##	+
Liver endothelium	++	++	##	++	##	##			+	++	##	++	##	+
Spleen endothelium	-	+	+	-	-	-			-	+	++	-	-	-
Spleen reticulum cells	+	+	++	-	+	+			-	++	++	-	+	-
Spleen adventitia cells	-	+	-	-	-	-			-	+	+	-	-	-
Glomeruli endothelium	++	+	+	+	+	+			-	+	++	+	+	-
Myocardium endothelium	-	+	-	+	+	+			-	-	+	-	-	-
Bronchial epithelium	-	-	-	##	+	-			-	-	-	-	-	-
Lung endothelium	-	+	+	##	+	-			-	+	++	-	-	-
Tonsil epithelium		-	+	++		++			-	-	++	-	-	-
Tonsil endothelium, reticulum cells		-	+	++		++			-	-	+	-	-	-
Lymph node endothelium	-	-	##	++	+	+			-	-	+	-	+	-
Lymph node reticulum cells	+	+	##	++	++	+			-	+	+	-	+	-
Adrenal endothelium		-	++	++		++			-	-	+	-	-	-
Adrenal cortex epithelium		-	++	++		++			-	-	+	-	-	-
Brain endothelium	-	++	+	-	+	+	+	+	-	+	+	-	-	-
<i>Membrana nictitans</i> epithelium												++		
Bone marrow endothelium, reticulum cells					+	+								

#### DISCUSSION

The 14 cases investigated, which were histopathologically diagnosed as H.c.c., were taken from 263 autopsied spontaneous cases at our Department, during the 5 year period, 1951~1955. All cases showed acute or subacute fatal course. The duration of the disease was 2~14 days; most cases showed a 2~4 day rapid course. H.c.c. occurred most frequently in animals less than one year old. Symptoms in dogs differed from these in foxes, the latter showing conspicuous encephalitic symptoms.

In the gross examination, circulatory disturbances seemed to have played the leading part in the disease. One of these was edema and the other was hemor-

rhages. The former was found in the wall of the gall-bladder, the pancreas, the portal root and the portal lymph nodes; in the abdominal cavity sero-hemorrhagic exudation had most often occurred. Edema was often seen in the subcutaneous tissue and the tissue around the body lymph nodes. The thymus and pericardiac mediastinum usually showed a remarkable edema. The latter, hemorrhages, regularly occurred in almost all parts of the body. Passive and active hyperemia in all parts of the body were also important changes. The author considers that the primary changes of an edema are due to liver destruction. The edema in DISSE's spaces occurs after centrolobular hepatic necrosis. Simultaneously, an edema occurs in GLISSON's capsule and the dilatation of periportal lymph vessels becomes conspicuous. An edema was also found in the *Lnn. portarum*, *Lnn. duodenales*, the pancreas and the subperitoneum. RUBARTH<sup>(65)</sup> pointed out that the edema of the gall-bladder wall is probably related to the edema of the liver. According to SUDLER, lymphatic vessels in the *T. subserosa* of the gall-bladder are well-developed and communicate with the large superficial vessels coming from the liver. The subserous tissue in the gall-bladder wall is loose and therefore permits a more abundant accumulation of edema than in the liver (RUBARTH<sup>(65)</sup>). A pronounced subserous edema in the gall-bladder wall is considered as a characteristic change in H. c. c.

The mechanism of hemorrhages in the disease has been considered as injury in the wall of the blood capillaries. But in some cases of acute fatal course, the author observed focal necrosis and degenerative changes in megakaryocytes in the bone marrow. These changes suggest a factor of hemorrhages due to disturbances of the thrombocytic system, but it is not reasonable that all hemorrhagic changes in the disease be attributed directly to these changes. Hitherto, hemorrhages were the most important changes noted in the enzootic fox encephalitis (GREEN et al.), but the author considers that the thrombocytic disturbance, a factor of hemorrhage, has not been studied sufficiently up to date. The hemorrhagic character of this disease was a frequently observed finding, as RUBARTH<sup>(65)</sup> has pointed out.

Other main changes observed were *hepatilis parenchymatosa*, *perihepatitis fibrinosa*, and enlargement of the spleen, the lymph nodes and the tonsils.

Histopathologically, the changes caused by the disease are classified as follows.

- 1) Parenchymal degeneration, such as centrolobular hepatic necrosis, nephrosis, necrobiotic or necrotic foci in the spleen, the lymph nodes, the adrenal cortex, the tonsils, submucous lymph follicles in the intestine and the bone marrow,
- 2) Activity of reticulo-endothelial system, such as mobilization and swelling of reticulo-endothelial cells,
- 3) Circulatory disturbances, such as edema, congestion and hemorrhages,
- 4) Nuclear inclusions, which are characteristic of the disease, occur

in almost all the germinal layers. That is, inclusions occur in the endothelium (mesoderm), adventitia cells, reticulum cells (mesenchym), liver cells, bronchial epithelium (entoderm), and epithelium in the tonsils and *membrana nictitans* (ectoderm).

The liver was enlarged or normal in size. The blood content in the liver was almost always increased. In the cut surface, the lobuli design was distinct. Histologically, circulatory disturbances such as hyperemia, edema and hemorrhages as well as regressive changes were conspicuous. Lacunose dilatation of the sinusoids and blood effusion into the DISSE's spaces were generally marked in the centrolobular parts of the liver. Central hemorrhages were often observed with central hepatic necrosis. Hemorrhages often occurred in the GLISSON's capsule. In almost all cases, fibrinous thrombi and wide-meshed or coarse networks of fibrin deposits are seen in the sinusoids and DISSE's spaces. In some cases a fibrinous coating was found in the liver capsule as a *perihepatitis fibrinosa*.

Regressive changes, as a rule, took the form of diffuse hepato-cellular necrosis, mainly in the central and midzonal areas of the liver lobules.

This finding differs from experimental cases or cases in the most early stages, for in these cases eosinophilic necrosis is not accompanied by large focal necrosis. In epidemic hepatitis in man, loss of large tracts of liver cells, leaving a rim of surviving cells in the lobule, is very rarely seen in biopsy specimens (MALLORY). In autopsy cases, some authors have commented on the possibility that agonal changes (POPPER) or agonal and post-mortem processes modify the histological picture (DIBLE). It seems that the autolytic and eosinophilic necrotic processes occur independently and simultaneously. In the spontaneous cases now under discussion, such process took an acute or subacute course. Most of the spontaneous cases showed in the form of central and midzonal necrosis, though eosinophilic necrosis also occurred. This plays the leading part in liver necrosis. Eosinophilic necrosis occurs in any stage of the disease, but is more commonly found early on the disease.

As to the formation of central hepatic necrosis, the author could hardly consider that these changes are due only to agonal or post-mortem process. HJÄRRE considered that central necrosis which is found in some viral diseases, probably does not occur by direct viral action. It is due to hypoxemia. For example, it is believed that central hepatic necrosis in equine infectious anemia occurs due to the simultaneous action of hypoxemia and some dynamic factor of circulation owing to the weakness of the heart. The central hepatic necrosis in H.c.c. occurs due to the simultaneous anemia and the circulatory disturbances which occurred. It is of interest that these explanations demonstrated conversely the presence of non-central hepatic necrosis in H.c.c. as well as in equine

infectious anemia. But the author considers that the occurrence of eosinophilic necrosis is due to direct viral action because of the presence of nuclear inclusions in an earlier stage.

Following the central hepatic necrosis and then hypoxydosis, *liquor diapedesis* occurs in the wall of the blood capillaries. Then an accumulation of edema in the DISSE's spaces occurs. ALTMANN pointed out that the liver damage is primary and *liquor diapedesis* is secondary.

Hepatic edema occurs secondarily, and then subserous edema in the gall-bladder and characteristic various forms of edema in the disease occur one after another.

Despite severe parenchymal degeneration, destruction of the reticular fibers is slight. But some parts of the fibers lost their argentophil character. Proliferation of the fibers could not be observed.

In the necrotic areas, disappearance or decrease of basophilia (PNA) in the hepatic cells occurred. On the contrary, PAS-positive granules were observed in the hepatic cells. The finding of the disappearance or decrease of PNA is identical with MIYAKE's finding of epidemic hepatitis in man and OBEL's finding of the toxic liver dystrophy of swine. Fatty degeneration is not always characteristic, though in some cases it appeared frequently. Most cases showed fine granulated fat droplets in the KUPFFER cells and endothelial cells. Vacuolated degeneration which did not consist of fat was often found.

Occasionally, centrilobular cells contain droplets of "hyaline" material. Sometimes the cells are swollen with droplets. These materials are remarkably positive to PAS staining.

POPPER mentions that the striking "dissociation" of the liver cells certainly appears more prominent in the patient who had a "prolonged agonal" period in epidemic hepatitis. It is of interest that the striking "dissociation" was found without central necrosis in the most prolonged fox cases.

Bile thrombi was found in 5 cases, but did not always coincide with clinical icterus. It seems that icterus is not a characteristic change in H.c.c.

Inflammatory cell reactions occurred after parenchymal degeneration. The composite cells were predominantly mononuclear, mixed with polymorphonuclear leukocytes and lymphocytes. It is difficult to determine what these cellular elements of the mononuclear cells are, but the author considers that these cells are the reticulo-endothelial derivatives and transitional forms of macrophages. RUBARTH<sup>(65)</sup> and DE MONBREUN described them as "mononuclear cells" and COWDRY and SCOTT as "macrophages." In epidemic hepatitis, WOOD described them as "mononuclear phagocytes" and LUCKÉ and MALLORY as "mononuclear forms-reticulo-endothelial derivatives."

Activity of reticulo-endothelial cells, such as mobilization of KUPFFER cells and sinusoidal mononuclear phagocytes are found in all stages of the disease.

Regressive changes often occurred in these cells as well as in hepatic cells. Nuclear inclusions frequently were found in these degenerative cells.

The changes of the disease are markedly similar to those of toxic liver dystrophy<sup>7,12,40,44,64</sup> with the exception of nuclear inclusions.

Activity of reticulo-endothelial cells was observed not only in the liver cells, but also in all parts of the body.

The spleen showed acute congestion and proliferation of the reticulo-endothelial cells. Focal necrosis was frequently found in the splenic pulp and Malpighian bodies often with hemorrhages. Nuclear inclusions frequently occurred in the endothelial cells, reticulum cells and often in adventitia cells in the wall of the sheathed arteries.

The kidneys showed enlargement and congestion of the glomeruli, and nuclear inclusions were often found in the glomerular endothelium. Acute glomerulonephritis and nephrosis were commonly observed. POPPENSIEK and BAKER pointed out that interstitial nephritis is often found as an evidence of viral discharge. But these changes are only observed in a few of the present cases. In some of them fatty degeneration was marked in the convoluted tubules and HENLE'S loop, but most cases were indistinct. These changes are not characteristic of the disease.

The myocardium showed congestion and hemorrhages. Sometimes nuclear inclusions were clearly discernible in the endothelium of the endocardium and various vessels.

In the lungs, congestive edema often occurred. Alveolar pneumonia, suppurative and catarrhal bronchopneumonia, and focal pneumonia were often found.

Acute lymphadenitis was usually notable. This was characterized not only by edema, blood resorption, lymphoid hyperplasia and mobilization of reticulo-endothelial cells with nuclear inclusions, but occasionally by occurrence of focal necrobiosis.

Acute tonsillitis occurred as well as lymphadenitis. Nuclear inclusions were found in the epithelial cells of the mucosa and reticulo-endothelial cells.

In the adrenal cortex, focal areas of necrosis and nuclear inclusions in the parenchymal cells and vascular endothelium with polymorphonuclear infiltration were often found.

In the *membrana nictitans*, nuclear inclusions were found in the epithelial cells of the mucosa.

In the central nervous system, meningeal congestion and edema, and minor hemorrhages in the parenchymal tissue were macroscopically observed. Histolo-

gically serous effusions in the subpial areas and in VIRCHOW-ROBIN'S spaces, with hyperemia and hemorrhages, have often been observed. In some cases, the adventitial cells were proliferated and appeared to have increased in number in the perivascular areas of meninges. Sometimes perivascular cuffs were found in the small or medium sized vessels in the parenchyma. Minor foci of glial proliferation were also observed in the brain and the *medulla oblongata*. These changes were extremely slight in quality and quantity. It is not reasonable to regard these changes as encephalitis. Regressive changes in the walls of the blood vessels and hemorrhages in every part of the brain were often found. It seems that degeneration of nerve cells in a secondary change caused by hemorrhages.

In fox cases, in spite of the manifestation of marked encephalitic symptoms, histological pictures showed no essential differences from dog cases. To judge from these changes, it would seem that enzootic fox encephalitis, which GREEN and his co-workers investigated, and H.c.c. are the same disease.

This disease takes acute or subacute lethal course and resembles fulminant hepatitis in man<sup>17)</sup>.

AMANO<sup>18)</sup> has already pointed out that protracted epidemic hepatitis in man becomes liver cirrhosis or liver fibrosis. On the contrary, many veterinary workers have not found indications of chronic liver changes from H.c.c. Only HODGMAN and LARIN reported having encountered extensive residual liver damage, loss of liver cells, and distension of the sinusoids several months after the dogs had recovered clinically. AMANO<sup>18)</sup> regarded the cause of the yellow liver dystrophy as hepatitis.

The differential diagnosis of canine toxic liver dystrophy and H.c.c. is due to the presence of intranuclear inclusions. This author considers it possible that recovered cases of H.c.c. exist in cases of toxic liver dystrophy. To determine whether or not this may be, further investigation is needed.

In the differential diagnosis of the disease, that there are definite differences between H.c.c. and canine distemper in inclusions; the differentiation between the two diseases is not always difficult.

No matter what the changes in the central nervous system are, changes in the internal organs are definitely characteristic.

The differential diagnosis between H.c.c. and leptospirosis, anaphylactic, and other types of shock will not be mentioned in this paper as the matter was treated in earlier reports.

## SUMMARY

The author from the histopathological approach investigated a total of 14 spontaneous cases of H.c.c., including cases in foxes.

In the postmortem material rendered available in this laboratory during the period 1951~1955, H.c.c. has occurred in 5.32% of the cases (14/263).

All cases which showed acute or subacute lethal course were investigated. The duration of the disease was 2~14 days, generally a 2~4 day rapid course.

In the postmortem picture of H.c.c., circulatory disturbances play the leading part in the disease. Edema and hemorrhages were usually conspicuous. The former was found in the wall of the gall-bladder, the pancreas, the portal root and the portal lymph nodes: in the abdominal cavity sero-hemorrhagic exudation was often present. Edema was often seen in the subcutaneous tissue and the tissue around the body lymph nodes. The thymus and pericardiac mediastinum usually showed a remarkable edema. The latter regularly occurred in almost all parts of the body. On the other hand, acute parenchymatous hepatitis, acute fibrinous perihepatitis, enlargement of the spleen, tonsillitis, lymphadenitis, congestive edema in the lungs, occasional catarrhal bronchitis or bronchopneumonia, and hemorrhagic gastroenteritis were observed.

Histopathologically, the changes caused by the disease are classified as follows:

- 1) Parenchymal degeneration, such as centrolobular hepatic necrosis, nephrosis, necrobiotic and necrotic foci in the various organs,
- 2) Activity of reticulo-endothelial system,
- 3) Circulatory disturbances, such as edema, hyperemia and hemorrhages,
- 4) Characteristic nuclear inclusions (containing DNA and RNA) occur in various cells in almost all the germinal layers.

Eosinophilic necrosis in the liver is not pathognomonic, but it is a characteristic finding of the disease. This change is observed at any stage of the disease, but especially it seems to occur in the early stage. Regressive parts of the liver showed decrease or disappearance in PNA. On the contrary, the cytoplasm of reticulo-endothelial cells in sinusoids are rich in PNA. Fatty degeneration of liver and kidneys is not a characteristic finding of the disease. Despite an apparently severe destruction of the liver cells, the reticular fibers of the liver are found to be intact, but in some cases the argentophil character has been partially lost. Proliferation and thickness of the fibers were not observed. Icterus is not always characteristic of the disease. In one case, the author observed mixed infection of toxoplasma (No. 9).

The changes in the central nervous system were not encephalitic changes. In fox cases, in spite of the manifestation of marked encephalitic symptoms, histological pictures showed no essential differences from dog cases.

The author wishes to express his gratitude to Prof. YAMAGIWA for his kind direction and for his review of this study.

The author also owes his success in reporting to the members of the Department of Veterinary Hygiene and Microbiology, Faculty of Veterinary Medicine, Hokkaido University, for their bacteriological examination.

## REFERENCES

- 1) AKKER, S. v. d. (1952): *Tijdschr. Diergeneesk.*, **77**, 168 [*Vet. Bull., Weybridge*, **23**, 149 (1953)].
- 2) ALTMANN, H. W. (1949): *Frankfurt. Z. Path.*, **60**, 376.
- 3) AMANO, S., H. YAMAMOTO, S. DOHI & F. ICHIDA (1950): *Saishin Igaku*, **10**, 784 (in Japanese).
- 4) AMANO, S. (1952): *Tr. Soc. Path. Jap.*, Edit. region., **41**, 16 (in Japanese).
- 5) AXENFELD, H. & K. BRASS (1942-1942): *Frankfurt. Z. Path.*, **57**, 147 [RUBARTH, S.<sup>65</sup>].
- 6) BORGMAN, A. R., J. E. MOSIER & R. D. BARNER (1950): *N. Amer. Vet.*, **31**, 397 [*Vet. Ext. Quart. Univ. Pa.*, **57**, 36 (1957)].
- 7) CELLA, F. (1936): *Nuova Vet.*, **14**, 244 [*Jber. VetMed.*, **61**, 183 (1937)].
- 8) CHADDOCK, T. T. (1947): *Vet. Med.*, **42**, 475.
- 9) CHAPMAN, M. P. (1948): *N. Amer. Vet.*, **29**, 162.
- 10) CHERNYAK, V. Z., O. A. KUPRITE & L. P. VLASOVA (1955): *Veterinarya, Moscow.*, **32**, 59 [*Vet. Bull., Weybridge*, **25**, 624 (1955)].
- 11) COFFIN, D. L. (1948): *J. Amer. vet. med. Ass.*, **112**, 355.
- 12) COHRS, P. (1929): *Tierärztl. Rdsch.*, **35**, 53, 82.
- 13) COHRS, P. (1952): *Dtsch. tierärztl. Wschr.*, **59**, 114.
- 14) CORSICO, G. (1952): *Atti Soc. vet.*, **6**, 208 [*Vet. Bull., Weybridge*, **24**, 69 (1954)].
- 15) COWDRY, E. V. & G. H. SCOTT (1930): *Arch. Path.*, **9**, 1184 [RUBARTH, S.<sup>66</sup>].
- 16) CRAIGE, J. E. (1950): *Vet. Med.*, **45**, 81.
- 17) DAVIS, C. L. & W. A. ANDERSON (1950): *Ibid.*, **45**, 435.
- 18) DEMONBREUN, W. A. (1937): *Amer. J. Path.*, **13**, 187.
- 19) DIBLE, J. H. (1951): *Brit. med. J.*, **1**, 833.
- 20) EMSLIE, J. W. (1950): *Vet. Rec.*, **62**, 128 [*Vet. Ext. Quart. Univ. Pa.*, **57**, 36 (1957)].
- 21) FARBER, E., D. KOCH-WESER, P. B. SZANTO & H. POPPER (1951): *Arch. Path.*, **51**, 399.
- 22) FERRI, A. G. (1952): *Rev. Fac. Med. vet., S. Paulo*, **4**, 573 [*Vet. Bull., Weybridge*, **25**, 232 (1955)].
- 23) FLORENT, A. & J. LEUNEN (1949): *Ann. Méd. vét.*, **93**, 225 [*Vet. Bull., Weybridge*, **21**, 365 (1951)].
- 24) FREUDIGER, U. (1951): *Schweiz. Arch. Tierheilk.*, **93**, 404 [*Vet. Ext. Quart. Univ. Pa.*, **57**, 36 (1957)].
- 25) FUJIMOTO, Y., M. OHBAYASHI & T. ONO (1952): *Jui-chikusan-shinpo*, No. 86, 388 (in Japanese).

- 26) FUJIMOTO, Y., M. OHBAYASHI & T. ONO (1953): *Tr. Soc. Path. Jap.*, **42**, 91 (in Japanese).
- 27) FUJIMOTO, Y., M. OHBAYASHI & T. ONO (1953): *Jap. J. vet. Res.*, **1**, 125 (in Japanese with English summary).
- 28) GORET, P., L. JOUBERT & A. BUFFET (1950): *Bull. Acad. vét. Fr.*, **23**, 305 [*Vet. Ext. Quart. Univ. Pa*, **57**, 36 (1957)].
- 29) GREEN, R. G., N. R. ZIEGLER, H. O. HALVORSON, B. B. GREEN & E. T. DEWEY (1928): *J. Bac.*, **15**, 47.
- 30) GREEN, R. G. & E. T. DEWEY (1929-1930): *Proc. Soc. Exp. Biol. & Med.*, **27**, 129.
- 31) GREEN, R. G., N. R. ZIEGLER, B. B. GREEN & E. T. DEWEY (1930): *Amer. J. Hyg.*, **12**, 109.
- 32) GREEN, R. G. (1931): *Ibid.*, **13**, 201.
- 33) GREEN, R. G., N. R. ZIEGLER, E. T. DEWEY & J. E. SHILLINGER (1931): *Ibid.*, **14**, 353.
- 34) GREEN, R. G., M. S. KATTER, J. E. SHILLINGER & K. HANSON (1933): *Ibid.*, **18**, 462.
- 35) GREEN, R. G., N. R. ZIEGLER, W. E. CARLSON, J. E. SHILLINGER, S. H. TYLER & E. T. DEWEY (1934): *Ibid.*, **19**, 343.
- 36) GREEN, R. G. & J. E. SHILLINGER (1934): *Ibid.*, **19**, 362.
- 37) GREEN, R. G., N. R. ZIEGLER, J. E. SHILLINGER, E. T. DEWEY & W. E. CARLSON (1935): *Ibid.*, **21**, 366.
- 38) GREEN, R. G., B. B. GREEN, W. E. CARLSON & J. E. SHILLINGER (1936): *Ibid.*, **24**, 57.
- 39) GREEN, R. G. (1940): *Vet. Med.*, **35**, 365.
- 40) HARBITZ, F. (1940): *Norsk VetTidsskr.*, **8**, 329 [RUBARTH, S.<sup>65</sup>].
- 41) HJÄRRE, A. (1953): *Dtsch. tierärztl. Wschr.*, **60**, 141.
- 42) HODGMAN, S. F. J. & N. M. LARIN (1953): *Vet. Rec.*, **65**, 447.
- 43) INNES, J. R. M. (1949): *Ibid.*, **61**, 173.
- 44) JOEST, E. (1921): [RUBARTH, S.<sup>65</sup>].
- 45) JOSHUA, J. O. (1950): *Vet. Rec.*, **62**, 566 [*Vet. Ext. Quart. Univ. Pa*, **57**, 36 (1957)].
- 46) KAPP, P. (1954): *Acta vet., hung.*, **4**, 453.
- 47) KAWAI, H. & S. AKASHI (1954): *Tr. Soc. Path. Jap.*, **43**, 649 (in Japanese).
- 48) LUCKÉ, B. & T. MALLORY (1946): *Amer. J. Path.*, **22**, 867.
- 49) MALLORY, T. B. (1947): *J. Amer. med. Ass.*, **134**, 655.
- 50) MARTIN, L.-A., P. GORET, J. HINTERMANN & G. DOUX (1952): *Bull. Acad. vét. Fr.*, **25**, 388. [*Vet. Bull., Weybridge*, **23**, 544 (1953)].
- 51) MARTINONI, F. (1950): *Schweiz. Arch. Tierheilk.*, **92**, 655 [*Vet. Ext. Quart. Univ. Pa*, **57**, 36 (1957)].
- 52) MIYAKE, M., M. OKUDAIRA & H. NAORA (1953): *Acta Path. Jap.*, **3**, 161.
- 53) MONTGOMERIE, R. F. (1950): *Vet. Rec.*, **62**, 114 [*Vet. Bull., Weybridge*, **21**, 365 (1951)].
- 54) NARDELLI, L. (1950): *Zooprofilassi*, **5**, 529 [*Vet. Bull., Weybridge*, **21**, 615 (1951)].
- 55) OBEL, A.-L. (1953): *Acta path. microbiol. scand., Suppl.*, **94**.

- 56) OCHI, Y., S. KONISHI, S. YAMAMOTO & F. SASAKI (1955): *J. Jap. vet. med. Ass.*, **8**, 383.
- 57) OCHI, Y., S. KONISHI, T. TAKIZAWA, T. IKEGAMI, S. YAMAMOTO, K. ISHIDA & A. SATO (1956): *Zbl. VetMed.*, **3**, 55.
- 58) OSAMURA, K., K. HIRATO, K. SHIMIZU & M. SOEKAWA (1957): *Jap. J. vet. Res.*, **5**, 27.
- 59) PALLASKE, G. & CH. KRETZSCHMAR (1953): *Berl. Münch. tierärztl. Wschr.*, **66**, 155, 171.
- 60) PARRY, H. B. (1950): *Vet. Rec.*, **62**, 559 [*Vet. Bull., Weybridge*, **21**, 614 (1951)].
- 61) PAY, T. W. F. (1950): *Ibid.*, **62**, 551 [*Vet. Bull., Weybridge*, **21**, 614 (1951)].
- 62) POPPER, H. (1948): *Arch. Path.*, **46**, 132.
- 63) POPPENSIEK, G. C. & J. A. BAKER (1951): *Proc. Soc. exp. Biol., N. Y.*, **77**, 279.
- 64) RUBARTH, S. (1938): *Nord. med. Tidskr.*, **15**, 355 [*Jahresb. VetMed.*, **67**, 103 (1940-1941)].
- 65) RUBARTH, S. (1947): *Acta path. microbiol. scand.*, Suppl., 68.
- 66) SAXER, E. (1948): *Schweiz. Arch. Tierheilk.*, **90**, 565 [*Vet. Bull., Weybridge*, **20**, 281 (1950)].
- 67) SIEDENTOPF, H. A. & W. E. CARLSON (1949): *J. Amer. vet. med. Ass.*, **115**, 109.
- 68) SMITH, L. T. (1951): *Amer. J. vet. Res.*, **12**, 38.
- 69) STORM, R. E. & W. H. RISER (1947): *N. Amer. Vet.*, **28**, 751.
- 70) STÜNZI, H. (1950): *Schweiz. Arch. Tierheilk.*, **92**, 354 [*Vet. Bull., Weybridge*, **21**, 147 (1951)].
- 71) SVENKERUD, R. R. (1952): *Nord. VetMed.* **4**, 1 [*Vet. Bull., Weybridge*, **22**, 634 (1952)].
- 72) SVENKERUD, R. R. (1952): *Ibid.*, **4**, 133 [*Vet. Bull., Weybridge*, **22**, 634 (1952)].
- 73) SVENKERUD, R. R. (1952): *Ibid.*, **4**, 273 [*Vet. Bull., Weybridge*, **22**, 634 (1952)].
- 74) SZANTO, P. B. & H. POPPER (1951): *Arch. Path.*, **51**, 409.
- 75) SUDLER, M. T. (1901): *Johns Hopkins Hosp. Bull.*, **12**, 126.
- 76) WHITTEM, J. H. & D. C. BLOOD (1949): *Aust. vet. J.*, **25**, 166 [*Vet. Bull., Weybridge*, **20**, 280 (1950)].
- 77) WOOD, C. D. A. (1946): *Arch. Path.*, **41**, 345.
- 78) YAMAGIWA, S. (1955): *Virus*, **5**, Suppl., 64. (in Japanese).

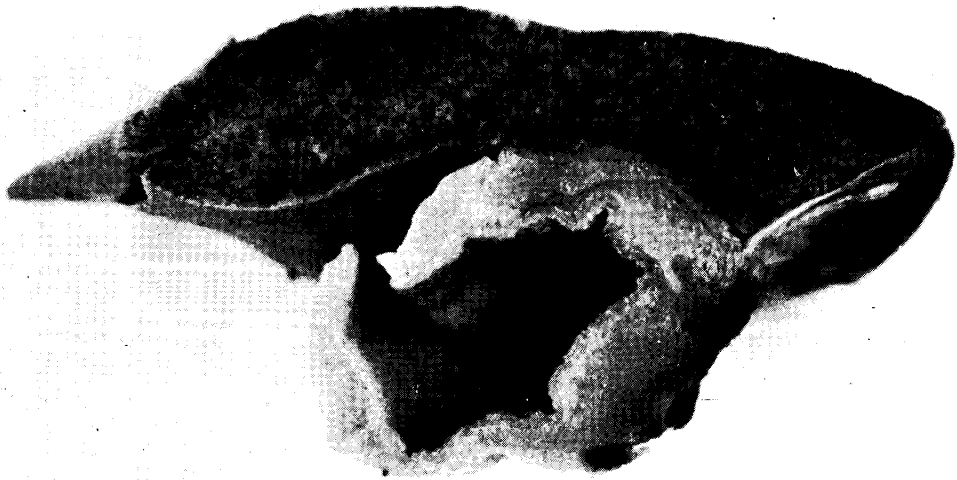## EXPLANATION OF PLATES

## PLATE I.


- Fig. 1. Case No. 3. Subserous edema in the gall-bladder.  $\times 2$ .  
Fig. 2. Case No. 1. Central hepatic necrosis. Hematoxylin-eosin stain (H.-E.)  $\times 50$ .  
Fig. 3. Case No. 12. Lacunose dilatation of the sinusoids of the liver. H.-E.  $\times 200$ .  
Fig. 4. Case No. 3. The reticulin pattern of the liver. Impregnation method.  $\times 50$ .  
Fig. 5. Case No. 3. Alveolar pneumonia. H.-E.  $\times 50$ .

## PLATE II.

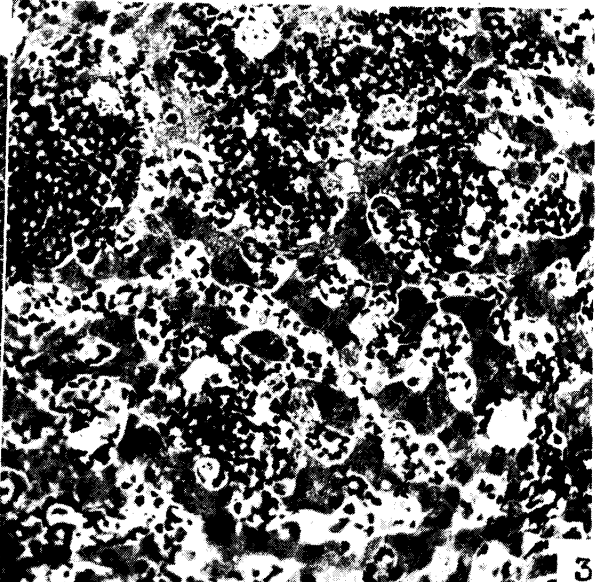
- Fig. 6. Case No. 5. Liver cells and endothelial cells with nuclear inclusions. B: Bile thrombi. H.-E.  $\times 800$ .  
Figs. 7 & 8. Case No. 1. Eosinophilic necrosis (E) in the liver cell. H.-E.  $\times 900$  and  $\times 800$  respectively.  
Fig. 9. Case No. 6. Bile thrombi (B) in the liver. H.-E.  $\times 800$ .  
Fig. 10. Case No. 4. Nuclear inclusions in the bronchial epithelium. H.-E.  $\times 800$ .  
Fig. 11. Case No. 2. Nuclear inclusions in the endothelial cells in the blood vessels of the brain. H.-E.  $\times 900$ .  
Fig. 12. Case No. 2. Nuclear inclusion in adventitial cell in the spleen. H.-E.  $\times 800$ .  
Fig. 13. Case No. 3. Nuclear inclusion in reticulum cell in the lymph node with catarrhal lymphadenitis. H.-E.  $\times 800$ .  
Fig. 14. Case No. 5. Nuclear inclusion in endothelial cell in the bone marrow. H.-E.  $\times 800$ .



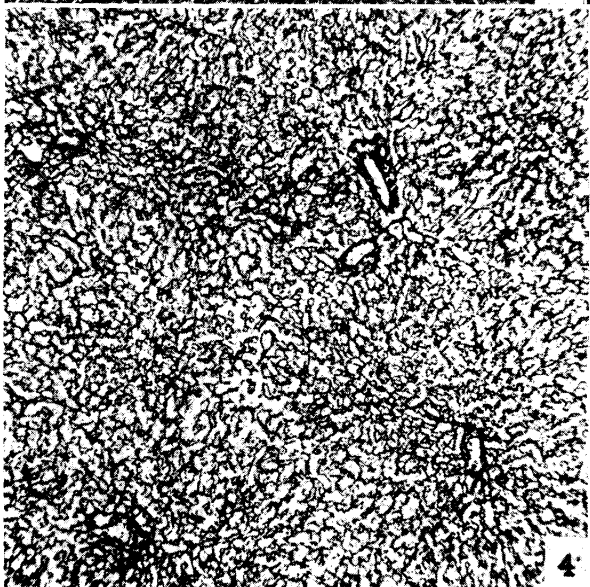
1




2



3



4



5

