



# HOKKAIDO UNIVERSITY

Title	CHANGES OF ARGYROPHILE FIBERS IN LIVER OF EQUINE INFECTIOUS ANEMIA CASES
Author(s)	YAMAGIWA, Saburo; ONO, Takeshi; ONO, Hitoshi et al.
Citation	Japanese Journal of Veterinary Research, 5(3), 112-122
Issue Date	1957-09-25
DOI	<a href="https://doi.org/10.14943/jjvr.5.3.112">https://doi.org/10.14943/jjvr.5.3.112</a>
Doc URL	<a href="https://hdl.handle.net/2115/1714">https://hdl.handle.net/2115/1714</a>
Type	departmental bulletin paper
File Information	KJ00002373124.pdf



## CHANGES OF ARGYROPHILE FIBERS IN LIVER OF EQUINE INFECTIOUS ANEMIA CASES

Saburo YAMAGIWA, Takeshi ONO, Hitoshi ONO  
and Haruhiko KITAYAMA

*Department of Veterinary Pathology,  
Faculty of Veterinary Medicine,  
Hokkaido University, Sapporo, Japan*

(Received for publication, July 29, 1957)

### PREFACE

Equine infectious anemia (I. A.), judging from its progression, was classified into the acute and chronic I. A. or into the acute, subacute and chronic I. A. from its beginning; the chronic I. A. has been considered as the one continued beyond the acute and subacute cases. DOBBERSTEIN (1934)<sup>1,2)</sup> has reported that the pathological changes of the disease are characterized by the histiocytic reaction, the lymphoid-cellular reaction and the fibrillar reaction depending on the progression of the disease. In other words, he considered as the characteristic of chronic I. A., the increase of the argyrophile fibers of liver, spleen and other organs. LEINATI and PIENING reported the disease later and supported the above theory in compliance with their investigations conducted on the kidney, heart and lymph node. LUDEWIG (1955) reported that the characteristic of chronic I. A. lay in the increase of argyrophile fibers in the entire organs.

The classification into the acute and chronic I. A. originally depends on the length of entire course of the disease. The present authors are, for the below stated reasons, unable to agree with the discussions on the pathology of I. A. using the terms "acute" and "chronic" which have been used in the above.

1) It is hard to find accurately when the animal was infected by the disease in a naturally infected case.

2) Even though clinical symptoms such as the recurrence of fever after the continuation, anemia and other symptoms are similar to those in acute lethal cases even in the long course of disease, many cases can clearly be segregated from the acute cases in a true sense in terms of pathological changes.

The authors have the confidence to say that the descriptions depending on individual cases which have been reported by them over the period of the past several years will clearly present an explanation to the above fact. The authors have been using the terms "the acute, subacute, chronic and relapsed type" from

the standpoint of pure patho-morphology in discussing the changes of I. A. (the previous reports<sup>13-21)</sup> can be used as references in connection with changes of each type).

The authors have the intention to make a detailed report on pathological changes of argyrophile fibers of liver at this time. Taking a general view of the materials, some cases exceptionally take a chronic course of development and then show acute or subacute type changes of I. A. in their cyto- and histological preparations. In some cases, the changes of liver in the chronic type I. A. are proved in the lethal case of I. A. In short, the authors have, in this report, tried to clarify whether or not the duration of disease determines the increase of argyrophile fibers in the liver of I. A.

## MATERIALS INVESTIGATED AND METHODS

### 1. Materials Investigated

Of the materials of I. A. stored in the authors' laboratory, 177 cases autopsied in the laboratory, 13 cases in slaughter houses, 13 autopsied cases which required diagnosis and 60 cases of slaughtered healthy horses were used. In 203 cases of I. A., histological investigations were conducted on all possible organs and the I. A. was classified into the acute type, subacute type, chronic type or relapsed type (Table 1). Control cases were also investigated for the various ages between 1 to 20.

TABLE 1. *I. A. Cases Investigated (203 Cases)*

TYPE	NO. OF CASES SLAUGHTERED	NO. OF CASES DIED
Acute	24	29
Subacute	24	64
Chronic	24	19
Relapsed	3	16

### 2. Methods

Materials were all fixed with 10% formalin solution. A few sheets of sections were prepared in the thickness of 5~7 $\mu$  from each paraffin block, and were stained with following methods, after being pasted on slide glasses or kept as free sections depending on the purpose.

1) OKA's and GÖMÖRI's modifications of BIELSCHOWSKY-MARESCH's impregnation method for argyrophile fibers.

2) Azan staining (HEIDENHAIN's modification).

3) VAN GIESON staining.

4) Hematoxylin-eosin staining.

## RESULTS OF INVESTIGATIONS

## 1. Argyrophile Fibers in the Liver in Normal Horses

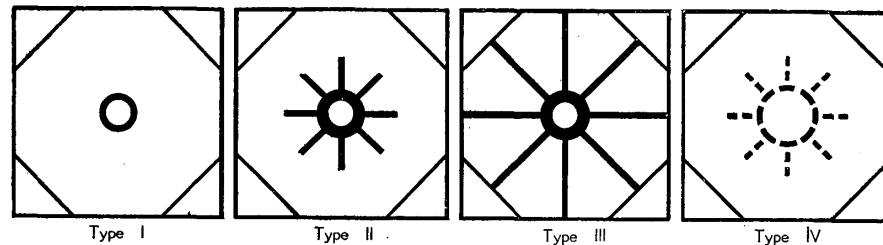
The existence of the argyrophile fibers in liver was already known in the middle of the 19th century. That structure was given the name "Gitterfaser" (lattice fiber) by OPPEL in 1889, but there has been no definite opinion on its true nature up to date. The authors, in this report, avoid discussion on this point and have described the lattice fiber tube (Gitterrohr) as comparatively thick "main fibers (radial fibers)" which run from central vein to the periphery of lobule and thin "transverse fibers (encircling fibers)" which are derived from the main fibers.

In the impregnated preparations of liver of 60 control cases, as STROH and ZIEGLER (1925) pointed out, individual cases showed variety of thickness even though almost no difference by ages was found. The authors made a classification as follows mainly according to the thickness of radial fibers (Fig. 1).

- 1) Those which run regularly all over the lobule with equal thickness (Type I).
- 2) Those which run regularly increasing their thickness centering around the central vein (Type II).
- 3) Those which increase their thickness all over the lobule (Type III).

Of 60 control cases, 44 cases belong to type I, 13 adult cases age over 4 to type II and 3 animals aged over 16 years to type III, but there existed no conspicuous differences in the quantity of radial fibers as well as of the encircling fibers. The livers in 3 cases which belong to type III had diminished in size macroscopically.

FIG. 1. *Schema of Changes of Argyrophile Fibers*



## 2. Argyrophile Fibers in the Liver in I. A. Horses

## 1) Acute Type I. A.

Of 53 cases of I. A. which belong to this type, 51 cases showed non-increase of argyrophile fibers while 2 cases showed increase judging from the changes of these fibers qualitatively and quantitatively. In classifying the above, 18 cases showed type I, 26 cases showed type II, 2 cases type III and 7 cases type IV (Fig. 1); type IV cases showed conspicuously coarse radial fibers at the portion surrounding the central vein and also showed fragmentation and disappearance of encircling fibers there of which no indications were seen in the control cases.

Non-increased cases: In the 18 cases belonging to type I, the preparations stained

by hematoxylin-eosin revealed the expansion of sinusoids and remarkable dynamic activity of reticuloendothelial cells. Of these 18 cases, five showed the existence of centrolobular necrobiotic foci and intralobular small necrotic foci, but the foci in each case were fresh; the fibers showed nearly no changes and showed a slightly irregular pattern as compared to type I in control cases. Of the 26 cases which belong to type II, 19 showed remarkably expanded central veins and sinusoids adjacent to them together with a dynamic activity of reticuloendothelial cells; the remaining 7 cases showed intralobular necrobiotic foci. Of those 7 cases, necrobiotic foci indicated the disappearance of fibers and coarseness of perifocal fibers in 2 cases and showed no remarkable changes in the other 5 cases. All of the 7 cases which belong to type IV showed widely extended centrolobular necrotic foci and showed an active movement of reticuloendothelial cells. The fragmentation and disappearance of radial fibers in addition to remarkable coarseness of remaining fibers were noticed at the same time with focal necrobiosis as changes of fibers.

Increased cases: Argyrophile fibers slightly increased in number were seen in 2 cases, of which both showed generally coarsened fibers intralobularly (Type III). One of the above 2 cases was a 20-year-old horse which showed fresh focal parenchymal degeneration and obvious activity of reticuloendothelial cells, also its argyrophile fibers showed diffused coarseness and slight increase. In the other case, many of the liver cells contained vacuoles in compliance of a dynamic activity of reticuloendothelial cells; the lobule showed the increase of the tissue of GLISSON'S sheath and the size of the lobule conversely decreased. In the changes of argyrophile fibers, remarkably coarsened radial fibers were conspicuous. Both in the first and in the second of these 2 cases, the changes of fibers in the foci of parenchymal degeneration were not different from those in other parts.

## 2) Subacute Type I. A.

The liver changes of the subacute type I. A. are characterized by parenchymal degeneration, dynamic activity of reticuloendothelial cells and the increase of L-cells<sup>s)</sup> (a sort of so-called lymphoid cells). The classification of 88 cases investigated, based upon the findings of argyrophile fibers as in the acute type I. A. cases, put them into two groups of 70 and 18 cases which, respectively, showed non-increased argyrophile fibers and increased argyrophile fibers. It was also found that 21 cases belonged to type I, 35 cases type II, 3 cases type III and 29 cases type IV.

Non-increased cases: Of 21 cases which fell into type I category, 6 cases showed intralobular necrobioses, and did not indicate any change in fibers which appeared the same as in the fairly normal liver. Of 32 cases in type II, the existence of necrobiotic foci chiefly in the surroundings of the central vein was observed in 21 cases; highly dilated central veins and their surrounding sinusoids and atrophied hepatic cells were observed in 11 cases. Amongst those 21, in 2 cases, a complete disappearance of fibers was observed in intralobular cellular small foci. Without exception, 17 cases which belong to type IV showed the existence of widely extended necrosis around the central vein. In addition, in parallel with such parenchymal desolation, the fragmentation and disappearance of argyrophile fibers and the coarseness of remained fibers were noticed.

Increased cases: The 18 cases which showed the increase of argyrophile fibers

comprise 3 cases which showed diffusely coarsened argyrophile fibers (Type III) and 15 cases which showed the increase of argyrophile fibers. These cases should be classified in types II and IV. In the latter group, widely extended necrotic foci and remarkably dilated centrolobular sinusoids existed, liver cells were atrophied or had disappeared, sinusoidal endothelia were swollen and sinusoidal lumina contained macrophages and L-cells. The radial fibers in necrotic focus were conspicuously increased in thickness and showed increase of numbers, fragmentation and disappearance, and the remaining fibers were generally increased in thickness. At the same time, cellular small foci scattered intralobularly were observed in 3 cases. Of these 3 cases, two showed the disappearance of fibers in foci but the other still retained fibers. In the 3 cases which belong to type III, the coarseness of fibers was rather more outstanding than the increase of argyrophile fibers. Especially in one case, lobule decreased its size accompanying a slight proliferation of GLISSON's sheath tissue.

### 3) Chronic Type I. A.

The static activity of reticuloendothelial cells and the increase of r-cells (those used to be called lymphoid cells or lymphocytes in I. A. literature) are the characteristics of the chronic type I. A. The 43 cases examined by the authors were broken down to 34 cases which did not show increase of numbers of argyrophile fibers, 9 cases including those suspected of showing increase in argyrophile fibers. The 43 cases were further assorted, on the basis of the findings of argyrophile fibers, as 16 cases in type I, 17 cases in type II, 7 cases in type III and 3 cases in type IV.

Non-increased cases: Thirty two cases of the 34, which were categorized as types I and II, showed similar findings to those of a fairly normal liver. Eighteen out of these, however, showed the existence of cellular small foci in the lobule, but except 2 cases did not show the existence of fibers in the cellular small foci. Those remaining 2 cases fell into the category of type IV with the following indications on the hematoxylin-eosin-stained preparations, viz., desolated foci surrounding central veins, sinusoids which contained r-cells and a small number of macrophages with hemosiderin, increased sinusoidal endothelial cells with swelling attaching on the wall.

Increased cases: Different from the cases of increased argyrophile fibers in the subacute type I. A., only 2 cases showed the increase of fibers which characterize either type II or type IV, and the remainder increased in thickness of argyrophile fibers all over the lobule with the increase of number (Type III). In the latter cases, central veins and sinusoids were generally dilated and liver cell cords became slender as individual cells decreased in size. Sinusoids were bent meanderingly, expanded lumina were filled with erythrocytes which were mingled with r-cells and a small number of macrophages with phagocytosis. Sinusoidal endothelia also became swollen attached to the walls, many of the nuclei became pale and the endothelia showed a marked increase of number. In connection with the picture of argyrophile fibers, radial fibers increased in thickness and were bent meanderingly but encircling fibers increased in number as if they were enveloping liver cells. In 2 cases, cellular small foci scattered in the lobule were observed. Argyrophile fibers in foci, however, disappeared and the fibers surrounding foci increased

in thickness. Remarkable changes of fibers, however, such as marked coarseness, fragmentation and disappearance were invisible circumscribedly. In one each case which belong to type II and type IV, one in type II showed the existence of old necrotic foci surrounding the central veins, a remarkable increased thickness of argyrophile fibers with partial fragmentation, and slight increase of the number generally. The other case exhibited marked centrilobular congestion and coarseness of centrilobular radial fibers with fragmentation. In other portions, encircling fibers were slightly increased.

#### 4) Relapsed Type I. A.

The present authors have already, in respect to the changes in this type, reported separately in detail the characteristics of liver changes, viz., that the parenchymal degeneration and dynamic activity of reticuloendothelial cells are participating in the static activity of reticuloendothelial cells and increase of r-cells. Viewing the argyrophile fibers of 19 cases presently investigated, one sees that 16 cases showed no increase of number and 3 cases showed a slight increase. These 19 cases can be classified into 4 cases in type I, 8 cases in type II, 2 in type III and 5 type IV.

Non-increased cases: Hematoxylin-eosin-stained preparations revealed that 10 out of 16 cases permitted the existence of necrobiotic foci around the central veins and that 4 cases showed the existence of cellular foci or small necrotic foci in the lobules. According to the classification based on argyrophile fibers, 16 cases comprised 4 cases in type I, 7 cases in type II and 5 cases in type IV in which remarkable coarseness, fragmentation and disappearance of fibers were observed in accordance with the presence of centrilobular necrobiotic foci.

Increased cases: Three cases were diagnosed as chronic type I. A. by means of liver biopsies which were conducted one or two times while the animals were alive but died later with high fever and severe anemia. Case Nos. 1 and 2 indicated the appearance of newly-formed fresh necrotic foci of various sizes in the lobules and also showed a conspicuous dynamic activity in reticuloendothelial cells in addition to the chronic type I. A. changes as seen in liver biopsy preparations. According to the pictures of argyrophile fibers, in addition to a slight increase of fibers, one noted the coarseness of fibers around the central veins in case No. 1 (Type II) and the increase of thickness of radial fibers all over the lobules in case No. 2 (Type III). Both cases showed no abnormal findings of fibers in fresh necrotic foci. Case No. 3, however, showed marked dynamic activity of reticuloendothelial cells which would not be observed in liver biopsy preparations, and also showed the conspicuous coarseness of argyrophile fibers (Type III).

#### DISCUSSION

Reports on the connection of argyrophile fibers in I. A. liver, began with those of ZIEGLER (1923) and STROH and ZIEGLER (1925) who encountered remarkably increased argyrophile fibers of chronically progressed I. A. cases and named them as cases of "Gitterfasersklerose" (lattice fiber sclerosis). Reports by DOBBERSTEIN (1934)<sup>2)</sup>, LUDEWIG (1935), NEMEC (1939), SUGANO (1953) and ICHIKAWA et al.

(1955) followed. LUDEWIG and NEMEC considered the increase of argyrophile fibers as a characteristic of I.A. which had become chronic I.A. as DOBBERSTEIN also did. SUGANO, in his report, described the degeneration of argyrophile fibers pointing out degenerative changes which had been conventionally neglected by many authors in discussing I.A. changes. ICHIKAWA et al. stated that the acute type I.A. manifested the increase of thin argyrophile fibers and the chronic type I.A. the increase of thick argyrophile fibers which were resulted from serous inflammation in DISSE's spaces.

The present authors would like to discuss the following questions concerning argyrophile fibers:

- 1) How much increase of argyrophile fibers can be observed in I.A. liver ?
- 2) Can the increase of fibers be regarded as a characteristic of chronically progressed I.A. as pointed out by DOBBERSTEIN and others or can it not ?
- 3) Do I.A. changes show histiocytic reaction, lymphoid-cellular reaction and fibrillar reaction in order according to the progress of I.A. cases or do they not ?

Of 203 cases investigated in the present study, 20 cases showed the acute and subacute type I.A. of increased argyrophile fibers including those suspected cases; 12 cases showed the chronic and relapsed type I.A.

In 53 cases of the acute type I.A., argyrophile fibers were increased in 2 cases with remarkable coarseness of fibers all over the lobules; especially in case No. 1, 20-year-old animal, there were seen the atrophy of liver cells and collagenization of radial fibers. Case No. 2 showed slight increase of GLISSON's sheath tissue accompanying atrophied lobules. Considering that such changes are different from those in the acute type I.A., the authors are of opinion that there is no increase of argyrophile fibers in the acute type I.A. The increase of thin fibers in DISSE's spaces as described by ICHIKAWA et al. (1955) could not be seen by the authors despite the observation of existence of remarkable expansion of spaces throughout their investigation. In 7 cases of non-increased argyrophile fibers, the fragmentation and disappearance of argyrophile fibers were noticed as SUGANO (1953) had pointed out. However, from the fact that there are still 12 cases which do not show any changes in argyrophile fibers regardless of the appearance of necrotic foci, it can be concluded that argyrophile fibers degenerate following the degeneration of parenchymal cells due to the strong resistant character of the fibers.

Fifteen out of 18 cases of increased argyrophile fibers in the subacute type I.A. showed the coarseness of radial fibers surrounding the central veins and the partial fragmentation of fibers (type II and IV), and besides showed the increase of argyrophile fibers. Of 70 cases of non-increased argyrophile fibers, 49 cases

could be classified also into types II and IV and the increase of argyrophile fibers had a close relation with centrolobular necrotic foci in many cases, which are noteworthy facts. Based on such findings as those mentioned above, the authors consider that the majority of examples of increase of fibers in the subacute type I. A. were resulted from the reparative mechanism against the destructure of tissue.

As for the chronic type I. A., only 9 out of 43 cases permitted the increase of argyrophile fibers. Of the 9 cases, 7 showed the thickened radial fibers and encircling fibers all over the lobules. Generally there was no marked increase conversely and many showed slight diffused increase. These findings are completely different from the findings on the fibers in the subacute type I. A. Many small necrotic foci such as those detected by SUGANO are observed in this type of disease but small fresh necrotic foci as well as large ones showed no change of fibers and the fibers also exhibited fragmentation and disappearance in old foci. In addition there was no increase of fibers on the walls of foci, which play a reparative role in the opinion of the authors. At any rate the increase of argyrophile fibers can be ascertained even though such cases were few in number. It still remains as a problem whether the above noted facts are characteristic of the chronic type I. A.

In the cases of the relapsed type I. A., 3 out of 19 cases showed the increase of argyrophile fibers. LÜBKE (1952) and DOBBERSTEIN<sup>2)</sup> reported that the increase of argyrophile fibers or cirrhotic changes which can be regarded as previously existed lesions are the characteristic of relapsed case. The present authors, however, could notice only a slight increase of the fibers in only 3 cases among those which they ascertained by liver biopsy to be relapsed type I. A.

As for changes such as coarseness and the increase of argyrophile fibers seen in such I. A., general congestion and erythropenia, from the general viewpoint, and the congestion of liver, dilatation of sinusoids, liver cell necrosis, etc., from the local viewpoint, should be taken into consideration. The authors are reminded of the above particularly in interpreting the degeneration of argyrophile fibers in the acute and subacute type I. A. which showed severe parenchymal degeneration and the coarseness and increase of fibers in cases which occurred in considerably long courses of the disease. Even though many of the chronic type I. A. cases took a long progression, those which showed increase of argyrophile fibers were few; in such cases, the fibers were diffusely increased and the coarseness and increase of the fibers were frequently accompanied by the remarkable expansion of sinusoids and atrophy of parenchymal cells. In order to interpret such findings, factors such as cardiac weakness and chronic congestion of the liver should be taken into consideration and changes of argyrophile fibers in other organs should

also be studied as pointed out by LUDEWIG.

Based on the above described investigations, the authors would like to conclude as follows:

As it is clear in the changes of argyrophile fibers, among individual types of I.A. changes, there is no transition during the course of the disease particularly in the chronic type I.A. In other words, improper studies on the difference of tissue reactions due to the difference of individuality of animals make it hard to understand I.A. changes in the end.

#### CONCLUSION

1. In order to compete with DOBBERSTEIN's theories that the chronically progressed I.A. take the form of three different stages in its progress as histiocytic reaction, lymphoid-cellular reaction and fibrillar reaction and the characteristic of chronically progressed I.A. lies in the increase of argyrophile fibers, the present authors undertook to study the changes of argyrophile fibers in the liver in I.A.

2. The I.A. materials investigated were 53 cases of the acute type, 88 cases of the subacute type, 43 cases of the chronic type and 19 cases of the relapsed type totaling 203 cases, the property of authors' laboratory and 60 cases slaughtered healthy horses as the control ones.

3. As the results of investigations, excepting 2 cases of increased argyrophile fibers which are regarded as non-I.A. changes, the authors noticed there was no increase of argyrophile fibers in the acute type I.A. cases and that the decrease of argyrophile fibers was accompanied by the destruction of parenchymal tissues and coarseness of remaining fibers in 7 cases.

4. In the subacute type I.A., 70 cases showed non-increase of argyrophile fibers and 18 cases increase of the fibers. Forty-nine out of the non-increased argyrophile fiber cases showed fragmentation and disappearance of fibers and coarseness of the remaining fibers in their large intralobular necrotic foci. On the other hand, the increase of argyrophile fibers was regarded as a reparative mechanism which particularly resulted from the destruction of parenchymal tissue.

5. In the chronic type I.A., the number of cases which showed increase of argyrophile fibers was 9 including those suspected; the suspected cases showing diffused coarseness and increase of argyrophile fibers were 7 in number. Such increase of argyrophile fibers cannot be indubitably considered as a characteristic of the chronically progressed I.A. Looking at this increase as a change of tissue occurring in "the chronic type I.A.", it has another significance.

6. In the relapsed type I.A. cases, 16 showed no increase of argyrophile fibers but 3 cases did.

7. The existence of increase of argyrophile fibers in authors' materials

cannot be overlooked as I. A. changes. Two types in the increase of argyrophile fibers—the reparation of the destroyed parenchymal tissue and the response to continual dilatation of sinusoids—bear important relation to the mode of the increase of argyrophile fibers; such types of increase also have relations to the types of I. A. In conclusion, there is no transition between the acute and subacute types I. A. and the chronic type I. A. from the standpoint of changes in argyrophile fibers in the liver.

## REFERENCES

- 1) DOBBERSTEIN, J. & H. WILMES (1934): *Berl. tierärztl. Wschr.*, **50**, 161.
- 2) DOBBERSTEIN, J. (1934): *Ibid.*, **50**, 192.
- 3) ICHIKAWA, O., R. ISHITANI, H. YONEMURA, D. SHIBATA, Y. OGURA, M. TAMANAMI & T. HORIUTI (1955): Experimental Report on Equine Infectious Anemia I., Hokkaido, 149.
- 4) LEINATI, L. (1929): *Berl. tierärztl. Wschr.*, **45**, 17.
- 5) LÜBKE, A. (1952): *Virchows Arch.*, **322**, 187.
- 6) LUDEWIG, J. (1935): *Inaug.-Diss., Hannover* [*Vet. Bull., Weibridge*, **6**, 127 (1936)].
- 7) NEMEC, W. (1939): *Berl. Münch. tierärztl. Wschr.*, Jg. 1939, 687.
- 8) OHSHIMA, K. (1954): *Jap. J. vet. Res.*, **2**, 73.
- 9) PIENING, C. (1935): *Berl. tierärztl. Wschr.*, **51**, 355.
- 10) SCHERMER, S. (1927): *Arch. wiss. prakt. Tierheilk.*, **55**, 121.
- 11) STROH, G. & M. ZIEGLER (1925): *Z. Infektkr. Haustiere*, **27**, 47 & 141.
- 12) SUGANO, S. (1953): *Inaug.-Diss., Hokkaido* (in Japanese).
- 13) YAMAGIWA, S. (1950): Equine Infectious Anemia (Edited by KASAI, I, 133, Tokyo (in Japanese).
- 14) YAMAGIWA, S. (1952): *Jûi Chikusan Shinpô*, No. 83, 245 (in Japanese).
- 15) YAMAGIWA, S., T. ONO, Y. FUJIMOTO & M. OHBAYASHI (1952): *Ibid.*, No. 93, 713 (in Japanese).
- 16) YAMAGIWA, S., Y. FUJIMOTO, M. OHBAYASHI & T. ONO (1952): *Ibid.*, No. 95, 813 (in Japanese).
- 17) YAMAGIWA, S., M. OHBAYASHI, T. ONO & Y. FUJIMOTO (1952): *Ibid.*, No. 96, 863 (in Japanese).
- 18) YAMAGIWA, S. (1952): *Jap. J. vet. Sci.*, **14**, 523 (in Japanese).
- 19) YAMAGIWA, S., T. ONO, Y. FUJIMOTO & M. OHBAYASHI (1952~1953): *Jûi Chikusan Shinpô*, No. 99, 1013, No. 102, 3, No. 104, 103, No. 105, 153 (in Japanese).
- 20) YAMAGIWA, S., T. ONO, Y. FUJIMOTO, M. OHBAYASHI & S. MORIMOTO (1953): *Ibid.*, No. 108, 303, No. 110, 403, No. 112, 503 (in Japanese).
- 21) YAMAGIWA, S., Y. FUJIMOTO, M. OHBAYASHI, T. ONO & K. OHSHIMA (1955): *Jap. J. vet. Res.*, **2**, 83 & 129.
- 22) ZIEGLER, M. (1923): *Z. Infektkr. Haustiere*, **24**, 242 & 261.

## EXPLANATION OF PLATES

## PLATE I.

- Fig. 1. K 38, acute type I. A., non-increased. No remarkable changes of argyrophile fibers in centrilobular necrobiotic foci.  $\times 140$ .
- Fig. 2. Pr. 2124, subacute type I. A., non-increased. Widely extending centrilobular necrotic focus with fragmentation and disappearance of argyrophile fibers there.  $\times 140$ .
- Fig. 3. Pr. 2266, chronic type I. A. Coarseness of radial fibers (Type III).  $\times 250$ .
- Fig. 4. Pr. 12, subacute type I. A., increased. Remarkable increase and coarseness of fibers in parallel with focal necroses.  $\times 140$ .
- Fig. 5. Magnification of fig. 4. Increased coarse fibers taking irregular arrangement.  $\times 250$ .
- Fig. 6. Pr. 1408, subacute type I. A., increased. Increase of argyrophile fibers and disappearance and fragmentation of fibers in cellular small foci.  $\times 140$ .

## PLATE II.

- Fig. 7. Magnification of fig. 6. Note fragments of fibers in cellular small foci and slight coarseness of perifocal fibers.  $\times 250$ .
- Fig. 8. Pr. 2188, chronic type I. A., increased. Fairly no changes in argyrophile fibers in and out of fresh cellular small foci.  $\times 70$ .
- Fig. 9. Pr. 2920, relapsed type I. A., increased. Increase of encircling fibers and large and small fresh necrobiotic foci without changes of fibers.  $\times 250$ .
- Fig. 10. Pr. 357, chronic type I. A., increased. Coarseness of radial fibers and diffused increase of encircling fibers; sinusoids are filled with erythrocytes and liver cell cords are slender.  $\times 250$ .

(The section preparations of liver shown in the above pictures were treated by BIELSCHOWSKY-MARESCH's silver impregnation method for argyrophile fibers).

