



HOKKAIDO UNIVERSITY

Title	STUDIES ON ECHINOCOCCOSIS VI : SECONDARY ECHINOCOCCOSIS MULTILOULARIS IN MICE
Author(s)	YAMASHITA, Jiro; OHBAYASHI, Masashi; KONNO, Seiji
Citation	Japanese Journal of Veterinary Research, 5(4), 197-202
Issue Date	1957-12-25
DOI	https://doi.org/10.14943/jjvr.5.4.197
Doc URL	https://hdl.handle.net/2115/1721
Type	departmental bulletin paper
File Information	KJ00002373136.pdf



STUDIES ON ECHINOCOCCOSIS VI.
SECONDARY *ECHINOCOCCOSIS MULTILOCULARIS* IN MICE

JIRO YAMASHITA, MASASHI OHBAYASHI
and SEIJI KONNO

*Department of Parasitology, Faculty of Veterinary Medicine,
Hokkaido University, Sapporo, Japan*

(Received for publication, October 22, 1957)

In preceding papers the authors have described experimental cases of echinococcosis which belong to the unilocular echinococcosis caused by the Australian strain of *Echinococcus granulosus*. In connection with the fact that the echinococcus can be classified into two types, unilocular and multilocular, monism and dualism have been attributed to the causal worm of the disease. RAUSCH with his coworkers and VOGEL made it clear that the cestode species causative to the multilocular or alveolar type of echinococcosis is the *Echinococcus multilocularis* LEUCKART, 1863 (syn. *Echinococcus sibiricensis* RAUSCH & SCHILLER, 1954), not the conventional *Echinococcus granulosus* (BATSCH, 1786). YAMASHITA, one of the present authors, on the other hand, reported the human multilocular echinococcosis which was introduced to Rebus Island in Japan from the Commander Islands by way of the Kuril Islands. It can be said without doubt that the *Echinococcus* strain in Rebus is as same as *Echinococcus multilocularis* reported by RAUSCH and SCHILLER from St. Lawrence Island in the Bering Sea.^{15,19)}

The present authors undertook to carry out their own experiments on the multilocular echinococcosis type in parallel with those of unilocular type. Under such circumstances, they were the fortunate recipients of a live red-backed vole (*Clethrionomys rutilus*) recently sent from Dr. RAUSCH in Anchorage, Alaska after having been experimentally infected by *Echinococcus multilocularis*. Therefore, they administered the scolices of this vole material orally to dogs for the purpose of obtaining the adult cestodes and eggs; then various experiments were tried. At the same time with the oral infection experiment in dogs, the authors also carried out an experiment on secondary echinococcosis. The objects of the experiment were (1) comparison of the results obtained from their experiment with those of unilocular type and (2) the trial of passage in experimental animals using the scolices.

According to the literature, as the experimental method, the scolices obtained from the hydatid cyst had been inoculated into experimental animals by various

routes. In such experiments, however, materials of unilocular type echinococcosis were mainly used. Among many reports on the secondary echinococcosis, there is to be found only one description by RAUSCH (1954) pertaining to the experiment of the multilocular type.

The authors, in this report, deal with the results obtained from their experiment on secondary echinococcosis in mice.

MATERIALS AND METHODS

A male red-backed vole, *Clethrionomys rutilus*, was sent to the authors' laboratory from Dr. RAUSCH on December 22, 1956. The animal was captured in the suburbs of Anchorage, Alaska and approximately 4 months had elapsed after the oral infection by the eggs of *Echinococcus multilocularis*. On dissecting, the animal showed severe infection of multilocular hydatid disease; the tumor-like foci were localized in the liver, omentum, mesenterium, inner surface of the abdominal wall, surrounding tissues of pelvic organs, etc. A free-existing hydatid mass was also found in the peritoneal cavity. In the thorax, only one minute focus was observed on the inner surface of thoracic wall.

The inoculum was made by light grinding of the above-noted hydatid mass in the liver in a mortar adding physiological saline solution; the aliveness of scolices was ascertained.

Every mouse, dd-strain and weight about 20 g, was given injection by glass pipette after a 2 mm cut had been made in the skin and the number of scolices injected was 200~300 respectively. As for the intraperitoneal cases, 6 mice were given injection into the abdominal cavity at the portion of abdominal wall about 1 cm posterior to the last left costa. Three subcutaneous cases were also given injection into the subcutaneous tissue at the left post-scapular area. The animals were sacrificed within about 4 months at considerable intervals. The foci were examined macroscopically and by a magnifier, and many section preparations were made for microscopical investigations.

RESULTS

1. Intraperitoneally Injected Cases (I. P. Cases)

Macroscopical findings: All cases showed the existence of hydatid foci. The foci were very minute nodules and were distributed only in the abdominal organs. The focus was 0.2~4.5 mm in diameter, generally spherical, yellowish-white in color and considerably hard. The small number of large foci showed a minute semi-transparent point in the center. The foci were scattered superficially in the organs and none was observable deep in the parenchymal tissue. They were distributed in the liver and other various abdominal and pelvic organs as shown in table 1. The liver always showed the multiple occurrence of foci especially on the diaphragmatic face. The most frequent occurrence—9 foci—in the liver was observed in case No. 1 (Fig. 1).

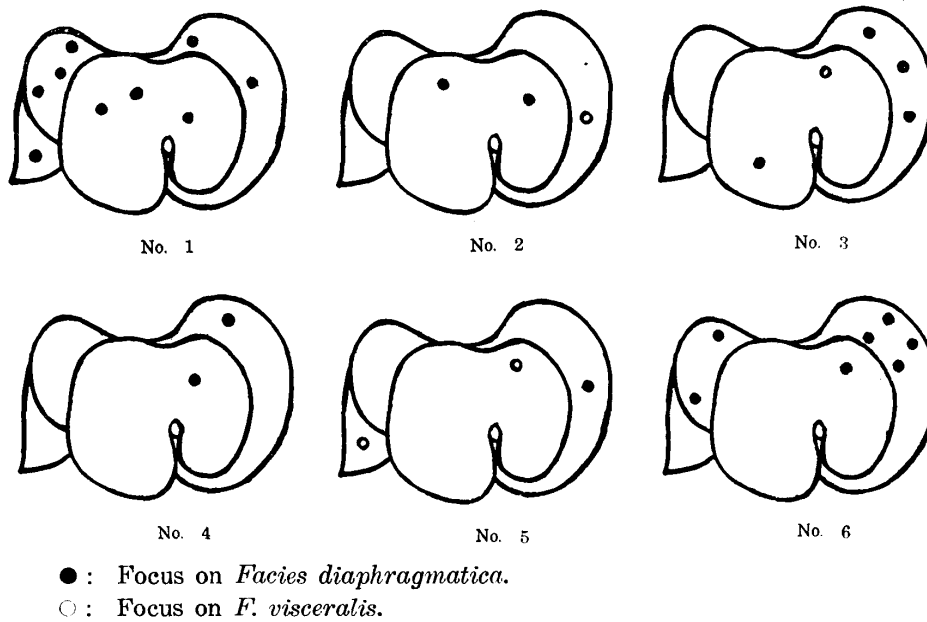
TABLE 1. *Distribution of Hydatid Foci*

METHOD OF INJECT.	CASE NO.	COURSE (DAYS)	LIVER	MESEN-TERIUM	OMENTUM	DIA-PHRAGM	LIG. GASTRO-LIENALE	LIG. LATUM UTERI	ABDOM. WALL	SUBCUTIS	OTHER ORGANS AFFECTED
I. P.	1	33	○	○	○	○	•	○	•	•	Spleen
"	2	33	○	•	•	•	•	○	•	•	Lymph node
"	3	65	○	○	○	○	○	○	○	•	Freely
"	4	65	○	○	•	•	○	•	○	•	Ileum
"	5	117	○	•	•	•	•	•	○	•	•
"	6	118	○	•	•	•	○	•	•	•	Pancreas
S. C.	1	33	•	•	•	•	•	•	•	○	•
"	2	33	•	•	•	•	•	•	•	○	•
"	3	117	•	•	•	•	•	•	•	○	•

I. P.: Intraperitoneal injection.
 S. C.: Subcutaneous injection.
 ○: Positive occurrence.

In case No. 3, three small yellowish-white masses, which freely existed in the abdominal cavity, were found; their sizes were 0.8×1.6, 0.7×1.5 and 2.5×3 mm respectively.

FIG. 1. *Distribution of Hepatic Foci in I. P. Cases*



Microscopical findings: The above-described hydatid foci mainly had the structure

of a nodule with granulation tissue reaction; eosinophile necrotic substance was seen in the central portion, its surrounding tissue was proliferated granulation tissue with lympho- and hystiocytic cell accumulation and frequently with giant cells. There were no eosinophile leucocytes. In the majority of central necrotic tissues, on the section preparations, there existed the calcareous corpuscles, undulate or circinate cuticular layers and shadow figures of scolex. A few nodules showed cholesterolin deposition (Cases No. 3 & 4). The nodules were localized superficially and the granulation tissue somewhat invaded into the parenchymal tissue. Multiple occurrence of nodules was seen in the diaphragm of case No. 1.

Cyst formation with a scolex was discovered in only one hepatic focus of case No. 2.

Freely existing masses in the abdominal cavity of case No. 3 were very interesting. Their histological structure was similar to that of an adult cestode; fine reticular parenchymal tissue, numerous calcareous corpuscles, thin culticle, etc. were distinguishable.

2. Subcutaneously Injected Cases (S. C. Cases)

Macroscopical findings: Hydatid foci could be recognized as yellowish-white nodules in the subcutaneous tissues alone. The findings of three experimental cases were: No. 1, one nodule of 0.6 mm diameter in the right hypogastric area, one of 0.7 mm size in the left scapular and one of 0.5 mm in the right parietal; No. 2, six nodules of 0.1~1 mm in a row between the right scapular and neck, one of 0.7 mm in the right scapular; No. 3, four of 0.5 mm in the left posterior thoracic.

Microscopical findings: There was no fundamental difference between I. P.- and S. C.-Cases in regard to the histological structure of the nodular focus. The necrotic central portion with shadow figures of scolices and cuticular layers and calcareous corpuscles was surrounded by proliferated connective tissue layer which showed lympho- and histiocytic cell accumulation. One cystic focus with a few scolices was found in case No. 2.

DISCUSSION

In regard to the experiments on secondary echinococcosis, as already noted, the investigators in the past have been limited to experiments on unilocular type echinococcosis. The results have been reported of experiments, in which so-called hydatid sands obtained from the unilocular hydatid cysts of the sheep, horse, swine, etc. were inoculated into experimental animals by various routes. From the past reports concerning the unilocular type, it is known that the mouse and rabbit are susceptible and that well-developed hydatid cysts can be detected. That is to say, when the scolices are injected into the abdominal cavity of mice or rabbits, the hydatid cysts develop in the liver and peritoneum^{1-5,7,8,11,18)} and in some cases the foci can be seen deep in the parenchymal tissue of the liver⁹⁾. The infection of mice by subcutaneous injection has been also reported¹⁸⁾; injections into the trachea⁴⁾, alimentary canal^{1,2,9)} and pleural cavity¹⁰⁾ have been tried by the investigators.

As for the experiment on the multilocular type, the present authors can refer to a description made by RAUSCH⁽²⁾. He injected the material with a few scolices into the abdominal cavity of a vole. The animal was killed 160 days later and an ovoid mass measuring 10×15 mm was found free in the abdominal cavity. This mass consisted essentially of proliferated subgerminal membrane tissue and normal-appearing vesicles were presented only peripherally. In vole cases orally infected by the eggs, indeed, it is a well known fact that originally developed hepatic foci of the multilocular type frequently spread to the abdominal organs such as the mesenterium, omentum, etc. showing secondary metastatic development.

In the present experiment, the characteristics of hydatid focus are considerably different from those of above-mentioned unilocular type. As far as the mouse experiment is concerned, in conclusion, it can be said that the scolex injected intraperitoneally or subcutaneously has a tendency to die at an early stage of development and, before long, organization takes place. The various conditions of the experiment must be taken into consideration, however, the authors are justified in concluding that there exists a considerable difference between the unilocular and multilocular types.

The findings of the minute masses freely existing in the abdominal cavity of I. P. case No. 3 are very interesting for the authors; the histological structure is similar to that of the adult cestode. This fact cannot be found to have been noted in the literature. It can be considered that the scolex takes a developmental course to the adult stage in a culture medium of abdominal fluid of the host animal.

SUMMARY AND CONCLUSION

The authors investigated the secondary echinococcosis in mice which were given injection intraperitoneally and subcutaneously with the material of *Echinococcus multilocularis* obtained from a red-backed vole, *Clethrionomys rutilus*.

It was concluded that the injected scolex has a strong tendency to die in a comparatively early stage of development and to be organized; these facts are different from the results obtained from experiments with the unilocular type as reported in the literature of parasitology. The authors also recognized that the scolex will occasionally develop into the adult tissue in the peritoneal fluid.

The authors wish to express their gratitude to Dr. R. RAUSCH, Arctic Health Research Center, Public Health Service, U. S. Department of Health, Education and Welfare, Anchorage, Alaska. He kindly supplied an artificially infected vole.

REFERENCES

- 1) BACIGALUPIO, J. (1933): *C. R. Soc. Biol.*, **114**, 89.
- 2) BACIGALUPIO, J. (1933): *Ibid.*, **114**, 390.
- 3) BRUMPT, E. (1949): *Précis de Parasitologie*, 6. Ed., 767~771, MASSON, Paris.
- 4) DE COOMAN, P. E. (1940): *Vlaam. diergeneesk. Tijdschr.*, **9**, 107 [*Helminth. Abstr.*, **9**, 120 (1941)].
- 5) COUTELEN, F. (1936): *C. R. Soc. Biol.*, **121**, 730.
- 6) COUTELEN, F., J. CALLOT & C. DESPORTES (1939): *Ann. Parasit. hum. comp.*, **17**, 4 [*Vet. Bull., Weybridge*, **9**, 860 (1939)].
- 7) COUTELEN, F., D. LECROART & G. COCHET (1939): *Ibid.*, **17**, 162 [*Vet. Bull., Weybridge*, **9**, 860 (1939)].
- 8) DÉVÉ, F. (1933): *C. R. Soc. Biol.*, **114**, 455.
- 9) DÉVÉ, F. (1933): *Ibid.*, **114**, 669.
- 10) DÉVÉ, F. (1938): *Ibid.*, **128**, 160 [*Zbl. Bakt. I. Ref.*, **133**, 168 (1939)].
- 11) HOSEMANN, G., E. SCHWARZ, J. C. LEHMANN & A. POSSELT (1928): Die Echinokokkenkrankheiten, Neue Deutsche Chirurgie, Bd. 40, 42~56, F. ENKE, Stuttgart.
- 12) RAUSCH, R. (1954): *J. infect. Dis.*, **94**, 178.
- 13) RAUSCH, R. & E. L. SCHILLER (1954): *J. Parasit.*, **40**, 659.
- 14) RAUSCH, R. & E. L. SCHILLER (1956): *Parasit.*, **46**, 395.
- 15) RAUSCH, R. & J. YAMASHITA (1957): *Proc. helm. Soc. Wash.*, **24**, 128.
- 16) VOGEL, H. (1955): *Deuts. med. Wschr.*, **60**, 931.
- 17) VOGEL, H. (1955): *Rev. Ibér. Parasit.*, Tom. extraord., 443.
- 18) DE WAELE, A. & E. DE COOMAN (1938): *Ann. Parasit. hum. comp.*, **16**, 121 [*Vet. Bull., Weybridge*, **9**, 860 (1939)].
- 19) YAMASHITA, J. (1956): *Jap. J. vet. Res.*, **4**, 64.

EXPLANATION OF PLATE

- Fig. 1. Scolices in the inoculum obtained from artificially infected red-backed vole. $\times 140$.
- Fig. 2. I. P. No. 1. Perimetric nodule showing cuticular layer and giant cells. Hematoxylin-eosin stain (H.-E). $\times 110$.
- Fig. 3. I. P. No. 1. Nodule in diaphragm showing granulation tissue with giant cell. H.-E. $\times 110$.
- Fig. 4. I. P. No. 1. Hepatic nodule with dead scolices, cuticular layer and calcareous corpuscles. H.-E. $\times 110$.
- Fig. 5. I. P. No. 3. Hepatic nodule with cholesterolin deposition. H.-E. $\times 110$.
- Fig. 6. I. P. No. 2. Hepatic cystic focus with one scolex. H.-E. $\times 110$.
- Fig. 7. I. P. No. 3. Freely existing mass showing structure similar to adult cestode. H.-E. $\times 110$.
- Fig. 8. S. C. No. 1. Subcutaneous nodule with dégenerated scolices, calcareous corpuscles and cuticular layers. H.-E. $\times 110$.

