



HOKKAIDO UNIVERSITY

Title	STUDIES ON ECHINOCOCCOSIS VII. : ON THE DEVELOPMENT OF ECHINOCOCCUS MULTILOCULARIS IN THE TAPEWORM STAGE
Author(s)	YAMASHITA, Jiro; OHBAYASHI, Masashi; KITAMURA, Yukitoshi
Citation	Japanese Journal of Veterinary Research, 6(2), 89-92
Issue Date	1958-06-30
DOI	https://doi.org/10.14943/jjvr.6.2.89
Doc URL	https://hdl.handle.net/2115/1730
Type	departmental bulletin paper
File Information	KJ00002373159.pdf



STUDIES ON ECHINOCOCCOSIS VII.
ON THE DEVELOPMENT OF *ECHINOCOCCUS MULTILOCULARIS*
IN THE TAPEWORM STAGE

Jiro YAMASHITA, Masashi OHBAYASHI
and Yukitoshi KITAMURA

*Department of Parasitology, Faculty of Veterinary Medicine,
Hokkaido University, Sapporo, Japan*

(Received for publication, March 31, 1958)

The authors, in a preceding report, described the development of *Echinococcus granulosus* in dogs. There are two types, unilocular and multilocular or alveolar, in hydatids. Also there are two opinions whether monism or dualism is shown in the species the causal worm of the hydatid. H. VOGEL (1957) has made morphological investigation of the tapeworms obtained from dogs, foxes and cats within 28 to 98 days after infection of human and vole's multilocular hydatid cysts from Southern Germany; identified this species with *Echinococcus multilocularis* LEUCKART, 1863. Also he has stated that this species and *E. sibiricensis* RAUSH and SCHILLER, 1954 from Alaska morphologically resemble each other to such a degree that they can be judged one single species.

The present investigation was undertaken with a view to understanding the morphological aspects of the tapeworm of the multilocular hydatid in stages earlier and later than those studied in VOGEL's investigation; another purpose was to obtain data for a comparison with *E. granulosus*.

MATERIALS AND METHODS

A dog was fed the parts of hydatid cyst of a red backed-vole, *Clethrionomys rutilus*, sent from Dr. R. RAUSCH in Anchorage, Alaska. The vole was captured in the suburbs of Anchorage; approximately 4 months had elapsed after the oral infection by the eggs of Alaskan *Echinococcus* tapeworm. The dog was killed and dissected on the 290th day after infection. Two other dogs were fed the hydatid cyst of a vole, *Clethrionomys rufocanus bedfordiae* which is common in Hokkaido, Japan. The infection of this vole had been done by ingestion of eggs occurring in the feces of the dog which had been fed the parts of the material from Alaskan vole mentioned above, and 140 days had elapsed after ingestion of the eggs. These dogs were killed and dissected on the 15th and 17th day after infection.

The present investigation was carried out in the same manner as that of *E. granulosus* which has been described in this journal, Vol. 4, No. 3.

RESULTS

On the 15th day after infection Numerous small young worms were found in the duodenum and anterior part of the jejunum of the experimental dog. The tapeworm of this stage consists of 3 segments including a scolex and 2 proglottids. The development of the sexual organ of the 2nd proglottid or the last one is pretty well in common, and in some specimen it is very well. In the 1st proglottid the sexual organ is still traceable.

On the 117th day after infection The strobila consists of 5 segments including a scolex and 4 proglottids; the tapeworms showed the aspect of the adult worms. In the 1st proglottid the sexual organ is traceable or unrecognizable; in the 2nd one it becomes more clear and in some specimens the testes are recognizable; the 3rd one shows the aspects of a mature proglottid; in some specimens the uterus has become sacciform to harbor many granular rudiments of eggs while testes and other organs are still recognizable; in the last one a gravid structure appears, the uterus is sacciform almost without lateral sacculations and contains many eggs. The testes are located almost behind the level of the genital pore which is situated in front of the center or the anterior third of the margin of proglottid; their number ranges from 15 to 30. Rosteller hooks are 26 to 36 in number.

On the 290th day after infection The appearance of the sexual organ is the same as in the above stage. The strobila has not become much larger than that of the specimen on the 117th day after infection.

By the fecal examination the eggs of the tapeworm were first discovered on the 30th or 35th day after infection in dogs. Size of eggs are from 29.5 to 40.5 μ by 27.5 to 39.5 μ in the specimens which were stained with DELAFIELD's hematoxylin after fixing with 70% alcohol or reserved in 10% formalin.

Comparative dimensions of the developing tapeworms The size of the strobilae, hooks, suckers and rostella are shown in table 1.

TABLE 1. *Size of Each Part of Body*

PART OF BODY	DIMENSION		
	Day after Infection		
	15th	117th	290th
Strobila	0.50~1.10 (0.95)	1.80~2.80 (2.20)	2.20~3.12 (2.53)
Hook	Large	25.0~28.0 (26.0)	28.8~31.3 (29.3)
	Small	22.0~25.0 (23.0)	23.8~27.0 (24.7)
Sucker	44.4~59.2 (50.4)	74.0~88.8 (78.9)	81.4~100.7 (87.5)
Rostellum	59.2~74.0 (66.8)	81.4~103.6 (94.8)	96.2~111.0 (105.1)

Remarks: Strobila in mm, All others in μ ; In parenthesis average.

The proportions of the development of the tapeworms depend upon the average dimensions on the 15th, 117th and 290th day after ingestions of the scolices within the

hydatid cyst. These proportions are as follows: 1 : 2.3 : 2.7 in strobila; 1 : 1.13 : 1.2 in large hook, 1 : 1.07 : 1.14 in small hook; 1 : 1.6 : 1.7 in sucker; 1 : 1.4 : 1.6 in rostellum. The increment of strobila of the tapeworm is not so remarkable as in *Echinococcus granulosus*.

SUMMARY AND CONCLUSION

The authors investigated the development of the tapeworm in dogs on the 15th, 117th and 290th day after oral infection by the Alaskan vole strain of multilocular hydatid cyst.

The development of the sexual organ is very rapid; it shows almost mature form while the strobila consists of 3 segments including a scolex and 2 proglottids on the 15th day after ingestion of hydatid cyst. The eggs of the tapeworm were first found in the feces of dogs on the 30th or 35th day after infection. There is a shade of difference between the two tapeworms on the 117th and 290th day after infection. Most of the worms, in these stages, consist of 5 segments including a scolex and 4 proglottids. Some of them, in the 3rd proglottid, have a bladder-like uterus just like that of the 4th proglottid or last one, but their eggs appear to be only granules without characteristic chitinous shells or embryophores. Broadly speaking, this species matures earlier than *E. granulosus*.

The difference between this species and *E. granulosus* will be established in a succeeding paper in detail.

REFERENCES

- 1) RAUSCH, R. & E. L. SCHILLER (1950): *J. Parasit.*, **40**, 659.
- 2) VOGEL, H. (1957): *Z. Tropenmed. u. Parasit.*, **8**, 404.
- 3) YAMASHITA, J., M. OHBAYASHI & S. KONNO (1956): *Jap. J. vet. Res.*, **4**, 113.

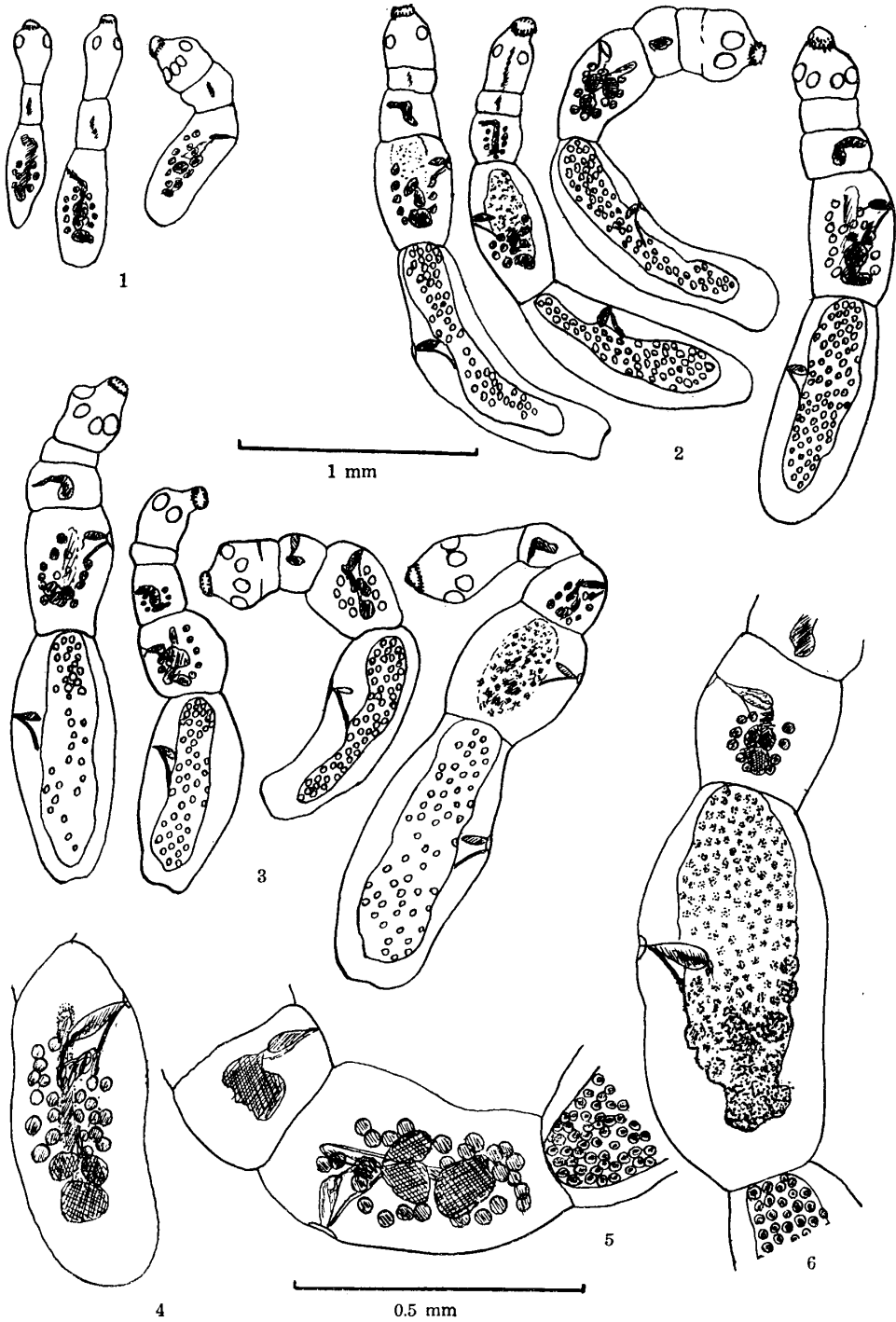
EXPLANATION OF PLATES

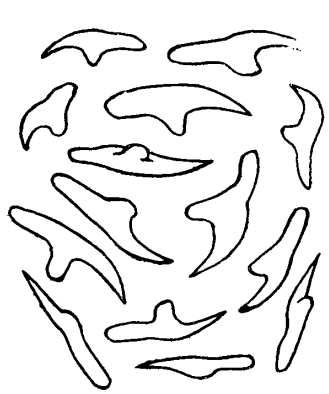
PLATE I.

- Figs. 1~3. Comparison of the size and structure of strobila on the 15th, 117th and 290th day after ingestion of the scolices within hydatid cyst. The drawing of the excretory canal is omitted.
- Fig. 4. Well-developed sexual organ of the last proglottid of a certain specimen on the 15th day after infection.
- Fig. 5. Sexual organ of the 2nd, 3rd and 4th or last proglottids occurring in common on the 117th day after infection.
- Fig. 6. Sexual organ of each proglottid of a certain specimen on the 117th day (the similar figure is also noticeable on the 290th) after infection.


PLATE II.

- Figs. 7~10. Comparison of the size and shape of hook at 4 stages. 7, scolices within the cyst; 8~10, on the 15th, 117th and 290th day after infection respectively.
- Figs. 11~13. Comparison of the size of sucker at each of above tapeworm stages.
- Figs. 14~16. Comparison of the size of rostellum at each of the above stages.






7




8


0.05 mm




9



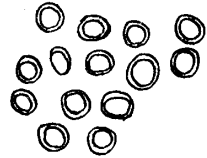
10




11



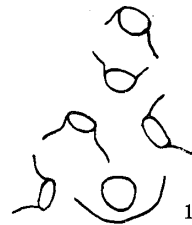12



13

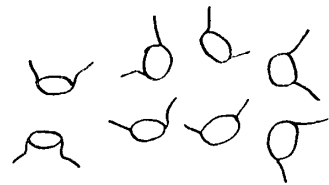


14



15

1 mm



16