



HOKKAIDO UNIVERSITY

Title	STUDIES ON TOXOPLASMOSIS I : AN OUTBREAK OF TOXOPLASMOSIS AMONG HARES (LEPUS TIMIDUS AINU) IN SAPPORO
Author(s)	SHIMIZU, Kiheiji
Citation	Japanese Journal of Veterinary Research, 6(3), 157-166
Issue Date	1958-11-15
DOI	https://doi.org/10.14943/jjvr.6.3.157
Doc URL	https://hdl.handle.net/2115/1735
Type	departmental bulletin paper
File Information	KJ00002373187.pdf



STUDIES ON TOXOPLASMOSIS I.
AN OUTBREAK OF TOXOPLASMOSIS AMONG HARES
(*LEPUS TIMIDUS AINU*) IN SAPPORO

Kiheiji SHIMIZU

*Department of Hygiene and Microbiology,
Faculty of Veterinary Medicine,
Hokkaido University, Sapporo, Japan*

(Received for publication, July 14, 1958)

INTRODUCTION

In Japan, the first case of natural infection with *Toxoplasma* was discovered by HIRATO in two racoon-dogs in the vicinity of Sapporo in 1939. Before this, in 1910, S. v. PROWAZEK described the occurrence of a new form *Toxoplasma talpae* in the liver smear of a Japanese mole which was collected by Dr. MINE in Kyushu. The organism was ovoid with the long diameter from 7 to 10 microns and the shorter 2 to 5 microns.

A case of naturally infected toxoplasmosis of the dog has been noted by HAMADA in Sapporo. YAMAMOTO et al. succeeded to isolate the organism in mice from a cat and two dogs naturally infected in Tokyo. SHIMAZAKI also reported the isolation of *Toxoplasma* in a Norway rat (*Rattus norvegicus*) collected in Fukushima Prefecture. SATO et al. noted four cases of pigs which seemed to be infected with the parasite; they isolated *Toxoplasma* with mice in two pigs out of four.

Pertaining to human infections, MIYAGAWA et al. and MIYAZAKI and HIRAOKA reported the isolation of the parasite in cerebrospinal fluid of the hydrocephalus and the demonstration of pseudocysts in a focus of ventricle wall of the brain in several cases of toxoplasmic encephalitis.

Thus, in Japan, from the epidemiological point of view, the survey on a variety of hosts within this country has become intensive.

Recently the author encountered the occurrence of toxoplasmosis among hares which were confined in a small wire-netting pasture in Sapporo.

Observations on these cases of naturally occurred toxoplasmosis are to be described in the present paper.

DESCRIPTIONS

1. Incidence

At the time of occurrence, total 13 hares—8 adult, 5 slightly more than 1 month old—

were kept in a confined area of about 80 square meters of a field fenced several feet high with iron net. In the next areas several pairs of the vole (*Clethrionomys rufocanus bedfordiae*) were being kept in the same way as is indicated in chart 1.

The general conditions of the living environment looked to be clean and healthy. Changes which occurred in the number of the hares after May 21, 1955 are listed in table 1.

The present enzootic occurred during the period of late summer (August 15th) to early autumn (September 11th). The most severe infections were observed one after another

TABLE 1. *Cases of Toxoplasmosis among Hare Group*

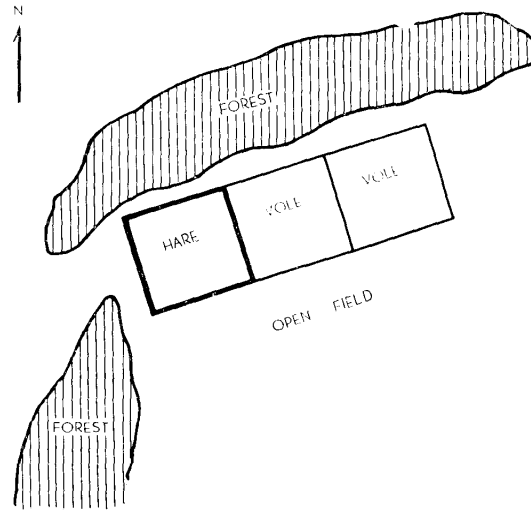
DATE	LOCATION OF CAPTURED	NO. INTRODUCED	NO. DEAD	NO. REMOVED ARTIFICIALLY	TOTAL NO. REMAINED
May 21, 1955	Yoichi	2	.	.	2
" 1956		.	.	1	1
May 24	Sapporo	2	.	.	3
28		.	.	2	1
June 11	Tobetsu	2	.	.	3
Aug. 11	Hayakita	2	.	.	5
Sept. 10		.	1*	.	4
Oct. 23	Yoroushi	6	.	.	10
Sept. 16		.	.	1	9
Dec. 27		.	1*	.	8
Jan. 12, 1957		.	1*	.	7
Feb. 6		.	1*	.	6
Mar. 20		.	1*	.	5
June 26	Sapporo	3	.	.	8
July 6		2**	.	.	10
9		3**	.	.	13
Aug. 15			1 A	.	12
20			1 A	.	11
Sept. 3			1 A	.	10
4			1 A	.	9
6	Toxoplasmosis		1 A	.	8
7			1 A	.	7... Case No. 1
8			1 Y	.	6... Case No. 2
9			.	1 Y	5
11			1 A	.	4... Case No. 3

Remarks * indicate the one died from symptoms other than Toxoplasmosis.

** indicate the hares born during the observation period.

A—Adult, Y—Young (Same with the hares marked **)

CHART 1. *Environmental Conditions of the Pasture where Hares Were Fed*



in September. After this, outbreak of this disease completely stopped. These data are listed in table 1.

Eight hares out of 13 had revealed the symptoms and all died. In this outbreak, it seems to be very interesting that the adult hare suffered in very high percentage (7 out of 8 -87.5%), compared with that of the young (1 out of 5 -20%), although there seem to be no very great morphological and physiological differences between the adult and young at that time. The way, through which the parasites were introduced remained unknown. However, it may be reasonable to think that there was some carrier among the hare group which was introduced last (on June 26, 1957) rather than to believe the carrier to be a vole which had occasionally entered the hare area through a tunnel in the earth since the preceding year.

2. Clinical Signs

The hare infected with this disease is noticed to be dull of movement and to show lack of attention to the surrounding, diarrhea, loss of appetite, edema of the head and salivation. Foamy saliva adhering around mouth was noticed in some cases. These symptoms appeared several days before death, however some of them were scarcely recognized by the keeper. The disease seems to run an acute course and all hares were found dead. All hares which showed some symptoms invariably suffered death. There were no slightly infected or recovered cases. In the cases studied, nervous manifestations were not observed.

3. Autopsy Findings

The author could examine only 3 cases. They exhibited almost similar macroscopical changes. The most characteristic changes were observed in the lung—marked edematous swelling, much serosanguineous fluid in the chest and pleural cavity, and reddish foamy

exudates in the bronchial tubes also in the trachea.

The liver was enlarged and swollen. In some cases submiliary greyish white foci were scattered. The spleen and the mesenteric lymph node also showed follicular swelling. Small necrotic foci, sometimes hemorrhages were also seen in the spleen. The kidney was congested. No increase of the abdominal fluid was observed in these cases.

Histopathological evidences indicated acute necrotic changes. Brief descriptions in each case are listed in table 2. The most characteristic changes were the necrotic lesions distributed throughout the body, multiple intralobular necrotic foci in the liver, necrotic foci in the spleen and sometimes in the brain.

These findings and also the comparatively good nutritional conditions evidently suggest that the disease had run an acute course.

TABLE 2. *Histopathological Findings of the Hares Examined*

ORGANS	CASE NO. 1	CASE NO. 2	CASE NO. 3
Lung	Congestion and edema with necrotic foci	Bronchopneumonia catarrhalis acuta	Alveolitis catarrhalis
Liver	Multiple intralobular necrotic foci	"	"
Spleen	Necrotic foci in pulp	"	Sporadic necrobiotic foci in pulp
Kidney	Nephrosis	"	Congestion
Mesenteric lymph node	Necrotic lymphadenitis	"	"
Brain and spinal cord	Not examined	Necrotic focus	Congestion and hemorrhages

4. Etiological Investigations

At first, bacteriological examinations by blood agar plate culture threw no light on the etiology; however, by the microscopical inspections of the GIEMSA stained smear prepared from each organ, the author could diagnose the cases as toxoplasmosis.

5. Parasites Encountered in the Organ Smears

Various shaped parasites were extracellularly observed in the GIEMSA stained smear preparations. Round, oval, lemon, semilunar or crescentic shaped organisms were commonly encountered; they were approximately 1.3μ to 3.1μ by 2.8μ to 5.3μ in size. In the cytoplasm of the parasites which are stained well basophilic, several vacuoles could be seen (Fig. 1). Parasites in pair which suggested longitudinal fission were also visible (Fig. 2). Moreover, except the terminal colony (Pseudocyst) in tissue cell, extracellular spherical masses of parasites which contained 8 to more than almost 80 individuals were encountered in the lung, spleen and the mesenteric lymph node. Especially in the lung

of case No. 3, all parasites encountered were seen in this form. They are about 11 μ to 15 μ sized spherical mass (Figs. 3~6). In addition, the author could observe several figures that indicated the parasites scattered around the nucleus of the tissue cell, suggesting that there had been a rupture of the cell membrane (Figs. 8 and 9).

Distribution of the parasites in the animal body of these 3 cases were also studied by using the GIEMSA stained smear; distribution is listed in table 3. In the liver, lung, spleen and mesenteric lymph node, extremely many organisms were observed, however very few in the kidney or in the brain. Case No. 2 exhibited parasitemia. In the ascites of cases Nos. 2 and 3, and in the thoracic fluid of case No. 3, no parasites could be detected by this method.

TABLE 3 *Distribution of the Parasite in the Animal Body*

MATERIALS EXAMINED	CASE NO. 1	CASE NO. 2	CASE NO. 3
Liver	###	##	##
Lung	++	##	##
Spleen	##	##	++
Kidney	+	+	—
Mesenteric lymph node	##	##	++
Heart blood	—	+	—
Brain	not examined	+	+
Peritoneal fluid	”	—	—
Thoracic fluid	”	not examined	—
Urine	”	—	—

Remark: +~### indicate the number of parasite in the organ smear.

6. Attempt to Isolate the Parasite

To isolate *Toxoplasma*, intraperitoneal and intracerebral inoculations were made into white mice of N I H Reg. Strain, including 2 rabbits. Table 4 gives detailed descriptions on mouse inoculations in the first passage. The observation period was 3 weeks in the 1st and 2nd generation, and 2 months in the succeeding ones.

In spite of the fact that inoculations were performed within 8 hours after detection of the death, except in hare No. 1 of about 60 hours, no death occurred in mice during the 3 weeks observation period. After the end of the observation period, all mice were autopsied and subinoculated.

Postmortem finding and the microscopical examination of the organ smears from each group of the 1st and 2nd passages showed negative. After the 3rd passage was performed, careful reexamination was made on the organ smear from the 2nd passaged mice and a small number of the parasite could be detected in the peritoneal smear of 1 mouse (Chart 2).

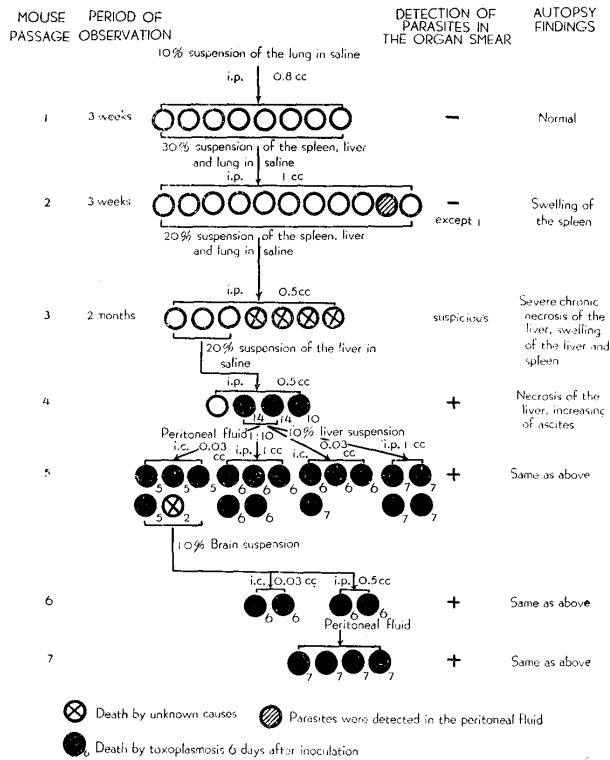
In the 3rd generation group of mice inoculated with the lung material from hare No. 3,

TABLE 4. *Inoculums for the 1st Passage and Results after 5th Serial Passages of Mice*

HARE NO.	MATERIAL	HOURS ELAPSED TO INOCULATION	ROUTE	DOSIS	NO. OF MICE	RESULT
1	30% suspension of the liver, spleen and mesenteric lymph nodes	about 60	i. p.	0.2	10	negative
2	40% suspension of the liver	about 5	i. p.	0.2	10	negative
	"		i. c.	0.02~0.03	10	negative
3	10% suspension of the spleen	about 8	i. p.	0.2	10	negative
	20% suspension of the liver		i. p.	0.8	7	negative
	"		i. c.	0.02~0.03	7	negative
	10% suspension of the lung		i. p.	0.8	7	positive

Remark: All suspensions were made in physiological saline.

CHART 2. *Course of Isolation of the Parasites in the Hare No. 3*



the autopsy findings of the 3 mice which remained alive showed the similar severe swelling of the liver and spleen and the severe suppuration of the liver, however, peritoneal fluid was not increased. By passaging these materials, the author succeeded to isolate the *Toxoplasma* in the 4th generation as indicated in chart 2.

Experiments with the other passage groups were stopped after the 5th generation because of their negative results.

The present strain showed high virulence for mice since isolation and death always occurred within a few days by intraperitoneal inoculation of the infected materials. Allantoic or yolk sac inoculation to the embryonated eggs also caused death and produced numerous white yellow plaques on the chorioallantoic membrane. The immune rabbit sera by this parasite were demonstrated to contain high titre of cytoplasm modifying antibody to the RH Strain. Their virulences to the laboratory animals other than mouse and serological examinations will be discussed in detail at some future opportunity.

DISCUSSION

The hitherto geographical known distribution of toxoplasmosis in hare was chiefly confined to Sweden and Denmark. In these countries, it is said that the incidences are observed mostly in cold season such as January~March and toxoplasmosis occurs only in isolated cases. Although it is not clear how many natural infections among hares may be in the wild of Hokkaido, the present data will suggest the possibility of the infections in the wild.

The present outbreak is considered to be somewhat characteristic because of its occurrence in warm season, not in cold and of its successive occurrence within a period of ten days. The environmental conditions may be something different in Hokkaido compared with Sweden and Denmark.

It was also very interesting that susceptibility of the hares to this parasite was very distinct by age—the adult hares more sensitive than the young (the former 7/8-87.5%, the latter 1/5-20%).

The clinical course and the pathological findings coincided completely with the data already reported. Owing to the lack of serological investigations, the author has no answer to whether or no there were any subclinical or slightly infected cases among the remaining hares.

Pertaining to the isolation of the parasite in the hare, at first HÜLPHER et al. in Sweden failed to isolate the parasite owing to the oldness of the materials, however, afterwards CHRISTIANSEN succeeded to isolate 4 strains by mouse inoculation in Denmark by using fresh organ materials within 24 hours after death.

The present author also could succeed in isolation of the causal parasite after 4 serial blind passages of the lung suspension in one case by using fresh organ materials taken within 5 and 8 hours after death. It is a well ascertained

that the isolation of *Toxoplasma gondii* is usually not so difficult if fresh inocula are used. As the cause of difficulty of isolation encountered in the present case, the virulence of this hare strain may enter into the problem. Concerning this point, it is generally accepted the parasites isolated from severe cases of human toxoplasmosis are highly virulent and strains from latent infections in animals are frequently low in virulence for mice. In the present study, the rate of isolation was very low despite the fact that the inocula were prepared from fresh severe cases except hare No. 1.

With the virulence of the parasites, also the sensitivity of each pure bred mice strain to *Toxoplasma* should be systematically examined in future for the sake of easy isolation of the parasites.

SUMMARY

A severe outbreak of toxoplasmosis was observed in a hare ranch (*Lepus timidus ainu*) in Sapporo. The data obtained are summarized as follows:

1. Outbreak occurred in rather warm season during the period of August 15~September 11, 1957.
2. Out of 13 hares including 8 adult and 5 about 1~2 months old, total 8 had succumbed one after another within a short period.
3. Infection rate was higher in adult (7 out of 8—87.5%) than in young (1 out of 5—20%). No subclinical or latent infections were recognized clinically.
4. Disease runs a very acute course without representing any nervous symptoms.
5. Autopsy findings exhibited the necrotic changes completely in coincidence with those already reported.
6. Parasites were demonstrated heavily in the liver, spleen and mesenteric lymph node by the GIEMSA stained smear. The isolation of the parasites was successful in 1 case after 4 successive inoculations to mice.
7. The present observation in hare was the first reported in Japan.

The author wishes to express his sincere thanks to Prof. HIRATO, chief of the Department of Hygiene and Microbiology, for his kind direction and review, and to Mr. UEDA and Mr. SHIBATA, technical officials of the Hokkaido Branch of the National Government Forest Experiment Station, for their kind supply of materials and also for their whole-hearted assistance. Grateful acknowledgement is made to Prof. YAMAGIWA and Dr. OHSHIMA of this Faculty for their kind instruction about the histopathological findings.

REFERENCES

- 1) CHRISTIANSEN, M. (1948): *Medlemsbl. danske Dyrlaegeforen.*, 93 [*Zbl. Bakt. I. Ref.*, **147**, 66 (1949~50)].
- 2) CHRISTIANSEN, M. (1949): *Nord. VetMed.*, **1**, 935 [*Vet. Bull., Weybridge*, **22**, 96 (1951)].
- 3) CHRISTIANSEN, M. & SHIM, J. C. (1951): *Lancet*, **260**, 1201.
- 4) HAMADA, S. (1951): *J. Jap. vet. med. Ass.*, **4**, 339 (in Japanese).
- 5) HIRATO, K. (1939): *Jap. J. vet. Sci.*, **1**, 544 (in Japanese with English summary).
- 6) HÜLPHERS, G., LILLENGEN, K. & RUBARTH, S. (1947): *Svensk VetTidskr.*, **52**, 295 [*Vet. Bull., Weybridge*, **19**, 478 (1949)].
- 7) BORG, K. (1953): *Proc. 15th Int. vet. Congr., Stockholm*, Part 1, Vol. 1, 406.
- 8) MIYAGAWA, Y., Z. NAGAHORI, I. MIYAKAWA, S. SHINOHARA, D. ISHIWAKA, S. TANUMA, H. MITA & H. INAKAMI (1954): *Shinryo-no-jissai*, **5**, 575 (in Japanese).
- 9) MIYAZAKI, I. & T. HIRAOKA (1956): *Jap. Med. J.*, No. 1697, 41 (in Japanese).
- 10) PROWAZEK, S. (1910): *Arch. Schiffs- u. Tropenhyg.*, **14**, 297.
- 11) SATO, H., Y. SAHEKI, I. OHISHI, K. MUTO & J. MIYAMOTO (1958): *Proc. 45th Meet. Jap. Soc. vet. Sci., Tokyo* (in press) (in Japanese).
- 12) SHIMAZAKI, M. (1956): *Jap. J. Bact.*, **11**, 450 (in Japanese).
- 13) YAMAMOTO, S., K. ISHIDA & K. FUJIWARA (1955): *Jap. J. vet. Sci.*, **17**, 13.
- 14) YAMAMOTO, S., K. ISHIDA, K. FUJIWARA, S. ITO & K. UEDA (1955): *Ibid.*, **17**, 79.

