



# HOKKAIDO UNIVERSITY

Title	NEURO-HISTOPATHOLOGICAL STUDIES ON SO-CALLED "ENCEPHALITIS EOSINOPHILICA SUIS"
Author(s)	SATOH, Hiroshi
Citation	Japanese Journal of Veterinary Research, 9(2), 41-115
Issue Date	1961-07
DOI	<a href="https://doi.org/10.14943/jjvr.9.2.41">https://doi.org/10.14943/jjvr.9.2.41</a>
Doc URL	<a href="https://hdl.handle.net/2115/1746">https://hdl.handle.net/2115/1746</a>
Type	departmental bulletin paper
File Information	KJ00002373299.pdf



# NEURO-HISTOPATHOLOGICAL STUDIES ON SO-CALLED “ENCEPHALITIS EOSINOPHILICA SUIS”

Hiroshi SATOH

*Department of Veterinary Pathology,  
Faculty of Veterinary Medicine,  
Hokkaido University, Sapporo, Japan*

(Received for publication, Feb. 6, 1961)

## INTRODUCTION

Since 1948, in Japan, a disease of the central nervous system, mainly affecting young swine and bringing on circular movement, convulsions, epileptiform seizures, etc. as cardinal cerebral symptoms to the animals, has newly appeared in the limelight in conjunction with epidemics of Japanese equine encephalitis<sup>37)</sup>. After a little while, great importance being attached to characteristic vascular and tissue infiltrations of eosinophil leucocytes in the central nervous system, especially in the telencephalon, the name “eosinophilic encephalitis of swine” has been temporarily given to the disease by Prof. S. YAMAGIWA<sup>44)</sup>.

Since then until the present, the author has been greatly interested in the disease of the central nervous system of unknown origin and he has collected materials of valuable naturally occurring cases with might and main. In the meanwhile, some interim reports on neuro-pathological features of the disease<sup>39,40,44,47)</sup> and, in conjunction with them, changes of the brain tissue of Japanese swine encephalitis<sup>39)</sup> have been published from our department; the existence of evident difference in the changes between the two diseases has been described. Furthermore, the reversion of causal agent or entity of the disease seemed to be apt to be hastily determined on the basis of surmise from only the circumstances of outbreak and clinical particulars of the disease and from only the isolation of a certain virus<sup>47)</sup> and, further, on the basis of the results of pathological examinations of only a few cases or a mere few limited regions of the body. Accordingly, Prof. S. YAMAGIWA and the present author have called Japanese veterinary circles' attention to the disease to avoid adventure of this kind, also at the same time admonishing ourselves.

Fortunately, the author has been able to collect such materials of naturally occurred cases of the disease as are satisfactory for the purpose of investigating

This work was communicated at the 49th General Meeting of the Japanese Pathological Society on May 14, 1960 in Niigata.

on the pathomorphological nature of the disease; using those materials he has made careful histo-pathological examinations on numerous regions of the body from the general point of view. At the time of such examinations, a metamorphosis of the mature adipose tissue which was found in almost all the cases, belonging to the category of lesion of "yellow fat disease", had also been observed with keen interest.

In this report, the author proposes to present minute neuro-histopathological descriptions of the individual cases with the intention of clarifying various pathomorphological processes of the disease and with consideration of the necessity of introducing knowledge of the characters of the disease in Japan, naturally, considering the circumstances that a certain swine disease of similar name with the present disease has been reported by many investigators<sup>1,2,8,9,11,13,15,18,25,27,35</sup> from Europe and America in recent years. The author, moreover, would like to describe histo-pathogenetical investigations of the disease, and further present some considerations with reference to the causal genesis of the disease from the morphological standpoint.

#### MATERIALS AND METHODS

Materials subjected for investigation were collected during the period July, 1948 to December, 1957; they were of thirty-one cases died or slaughtered. They consisted of 18 cases autopsied in our department and 13 sent for verification, and one healed case (No. 31) was included amongst them. All but Case No. 18 which was from Aomori Prefecture occurred in various areas of Hokkaido Prefecture; the breed of all the animals was pure and cross-bred Middle Yorkshire excepting Case No. 25 which was cross-bred Birkshire (Tables 1 & 2).

The brain and spinal cord were taken as soon as possible after the affected animals were dead or slaughtered; all materials were fixed in 10% formalin solution and 95% ethyl alcohol.

For histological examination on all the cases, the tissue materials were prepared by frontal sectioning from many parts of the brain in such a manner as to include the lobus frontalis, parietalis, temporalis, occipitalis, rhinencephalon, pes hippocampi, nuclei cerebri, diencephalon, mesencephalon, pons, cerebellum, medulla oblongata, etc., and from pars cervicalis, thoracica and lumbaris of the medulla spinalis obtained from 12 cases of the whole number in transverse or longitudinal sectioning. All of these materials were paraffin-embedded and on the other hand celloidin-embedding was done on a large majority of the cases.

In the histological investigation on the central nervous system use was made principally of NISSL-staining by employment of toluidin-blue or thionine, hematoxylin-eosin, and when necessary, ZIEHL-NEELSEN'S or VERHOEFF'S carbol-

TABLE 1. *Recapitulation of Cases Investigated*

CASE NO.	PROTOCOL NO.	SEX	AGE	TERMINATION	LENGTH OF COURSE	REMARKS
1	E. 2070	♂	4 m	21/V '56 †	2 h	
2	Pr. 2613	♀	4 m	22/VII '48 †	6 h	
3	Pr. 2614	♀	4 m	22/VII '48 †	6 h	
4	E. 2376	♀	70 d	5/V '57 †	6 h	
5	E. 1626	♂	7 m	27/XII '54 †	12 h	
6	E. 2433	♂	50 d	24/VI '57 †	12 h ?	
7	E. 35	?	50 d	30/IX '48 †	1 d	Inoculation (-)
8	Pr. 3594	♀	4 m	11/XI '54 †	1 d	
9	E. 1653	♀	5 m	16/II '55 †	1 d	
10	E. 2375	♀	70 d	25/V '57 †	1 d	
11	Pr. 2691	♀	4 m	10/XI '48 †	1.5 d	
12	Pr. 2785	♂	3 m	7/VII '49 †	1.5 d	
13	Pr. 3058	♂	4.5 m	18/I '50 †	1.5 d	
14	Pr. 3570	♀	4 m	11/VIII '54 †	1.5 d	
15	Pr. 2738	♀	6 m	15/III '49 †	2 d	
16	Pr. 2895	♀	12 m	8/V '50 †	2 d	
17	Pr. 3418	♂	2 m	4/IX '53 †	2 d ?	
18	Pr. 2744	♀	3 m	28/XII '48 †	2.5 d	
19	457	♂	50 d	31/V '50 †	2.5 d	
20	Pr. 3419	♂	2 m	5/IX '53 †	3 d	
21	Pr. 3572	♂	6 m	26/VIII '54 †	3 d	Inoculation (-)
22	E. 711	♀	1 m	27/XI '52 †	4 d	
23	E. 2200	♂	6 m	4/X '56 †	4 d	
24	Pr. 3687	♀	50 d	4/VII '56 †	5 d	
25	E. 2434	♀	54 d	28/VI '57 †	5 d	
26	Pr. 2900	♀	4 y	13/V '50 †	6 d	
27	460	♂	4 m	11/VI '50 †	6 d	Inoculation (-)
28	E. 2549	♂	3 m	7/XI '57 †	9.5 d	
29	Pr. 2850	♀	2 m	?/XII '49 †	?	
30	E. 594	♀	2 m	30/V '52 †	?	
31	E. 2573	♂	10 m	25/XII '57 †	7 d	Healing case ; 23/VI, onset

N. B. h: hour; d: day; m: month; y: year.

TABLE 2. *Materials Subjected to Investigation*  
(Seasons of Attacks of the Disease)

YEAR	SEASON (Month)				TOTAL
	Spring (4~6)	Summer (7~8)	Autumn (9~11)	Winter (12~3)	
1948	•	2	2	1	5
1949	•	1	•	2	3
1950	4	•	•	1	5
1951	•	•	•	•	—
1952	1	•	1	•	2
1953	•	•	2	•	2
1954	•	2	1	1	4
1955	•	•	•	1	1
1956	1	1	1	•	3
1957	5	•	1	•	6
Total	11	6	8	6	31

fuchsin-hematoxylin, VAN GIESON'S, PERLS' Berlin-blue, Sudan III and SPIELMEYER'S myelin sheath.

The examinations on the other organs and tissues were performed on various samples as many as possible on all the cases with the exception of Case No. 9. Ten percent formalin solution was employed for fixation of specimens from these organs. The section preparations were stained usually with hematoxylin-eosin, and as occasion demanded, ZIEHL-NEELSEN'S or VERHOEFF'S carbolfuchsin-hematoxylin and Sudan III.

In addition, the brain and fat tissue sections treated with paraffin-embedding were also stained with Sudan III as occasion demanded.

Mice, a piglet and mice, and mice and rats were intracerebrally inoculated with the brain suspensions which were made from Case Nos. 7\*, 21 and 27, respectively, but all of the transmission experiments yielded negative results. HVJ (hemoagglutinating virus of Japan)\*\* was isolated from the brain of Case No. 8 which was examined.

\* Through the kindness of the Department of Hygiene and Microbiology (Prof. K. HIRATO), Faculty of Veterinary Medicine, Hokkaido University, Sapporo.

\*\* A hemoagglutinating virus isolated from various mammals in Japan was given this name at the 3rd Meeting of the Society of Japanese Virologists on April 3, 1955 in Kyoto. This experiment was carried out by Dr. J. SASAHARA, National Institute of Animal Health, Tokyo.

RESULTS OF INVESTIGATION  
(Description of Cases)

In this report, histological findings concerning the central nervous system will be described principally, and information in regard to the other organs and tissues will be produced with importance attached to only the principal findings.

No. 1 E. 2070 (Figs. 1 & 2)

**Clinical:** 21/V '56, suddenly developed circular movement and convulsions after a midday meal and died at 2.00 p. m.

**Post-Mortem:** General congestion. Congestive edema of the lungs. Hyperemia of the cerebral meninges.

FIG. 1. No. 1. E. 2070



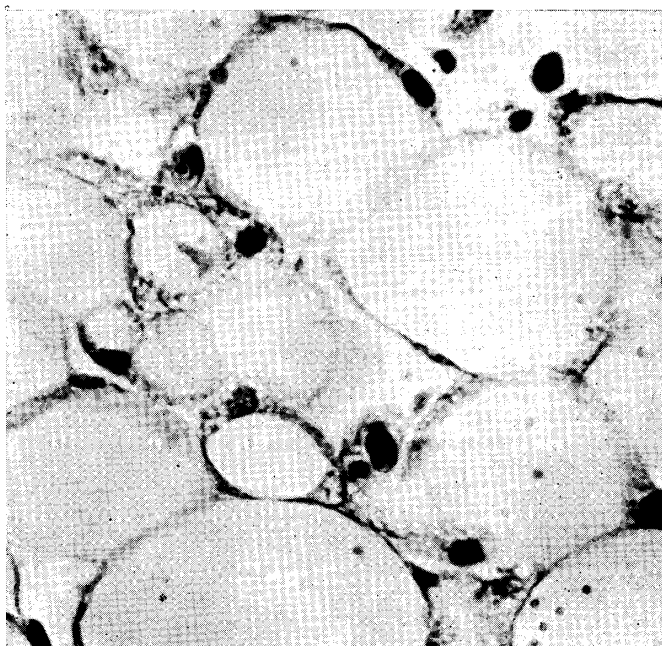
Lobus parietalis.  
Nerve cells, showing mostly acute changes,  
in the cortex. Toluidin-blue.  $\times 120$

**Microscopical:**

*Central nervous system* Acutely changing nerve cells were scatteringly present in all areas of the brain and spinal cord, especially somewhat conspicuous in the convex part, and above all in the parietal and occipital lobes, of the pallium of the cerebrum.

The ground substances of the middle laminae of the cortex of the right parietal and occipital lobes, in the convex of the cerebrum, slightly increased in eosin staining more than

FIG. 2. No. 1. E. 2070



Mature fat tissue near the adrenal glands. Initial metamorphotic features belonging to lesion "yellow fat disease". H.-E.  $\times 480$

in the other areas revealing pseudolaminar U-form features around the cerebral sulci; a small number of ischemic nerve cells laid scattered in such altering areas (focal pallor).

Capillary and venous hyperemia was intensive in all areas of the brain including the cerebral meninges; especially striking in the altering foci and in the meninges which cover the portions of such foci in the cerebrum. Edematous dilatation of the perivascular lymph spaces and perivascular edema of the brain tissue were evident; they were somewhat striking in the foci and rhinencephalon. The meninges of the sulci sometimes had edematous homogeneous substances in the lymph spaces.

Very slight perivascular infiltration, involving the capillaries and veins, and tissue emigration of eosinophil leucocytes were recognized in all areas of the cerebral cortex and in the meninges which are connected with just before noted foci. Sometimes, mild perivascular infiltration of lymphocytes and plasma cells had occurred in the meninges of the telencephalon. Swelling of endothelial cells of the capillaries was hardly noticed even in the foci of the telencephalon.

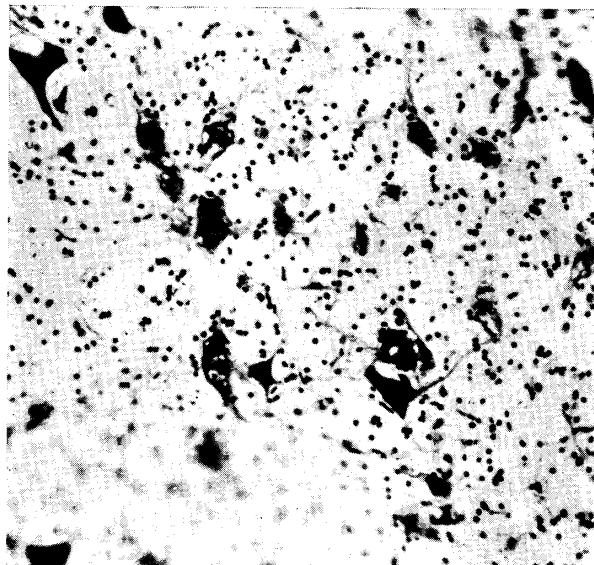
Acid-fast pigment substances could not be recognized in any part of the brain.

*Other organs and tissues* Slight fatty degeneration of liver cells was scatteringly observed. Hyperemia and hemorrhages in the thymus and deep layers of the adrenal cortex. In the various fat tissues, mature fat cells in which minute vacuoles existed in their large fat drops were noticed scatteringly or diffusely; the vacuoles were located adjacent to the inner surface of the cell membrane; no pigment substances were distinct in the vacuoles.

No. 2 Pr. 2613 (Figs. 3 & 4)

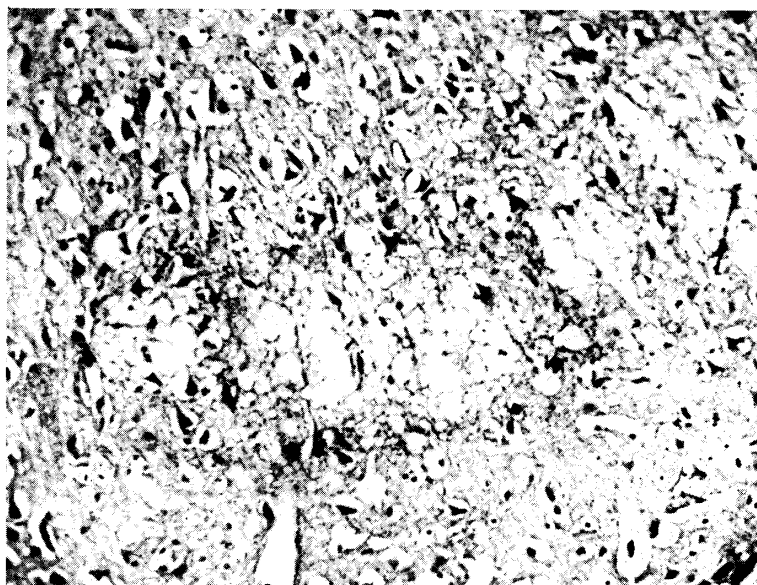
**Clinical:** 21/VII '48, 14 piglets (4 months of age) from one piggery became ill at 6.30 a. m.;

FIG. 3. No. 2. Pr. 2613



Olivary nucleus.  
Various acute changes of nerve cells.  
Thionine.  $\times 120$

FIG. 4. No. 2. Pr. 2613



Lobus parietalis.  
Pseudolaminar pallid lesion with status  
cribrosus in the cortex. H.-E.  $\times 120$

these piglets developed languishment, dysorexia, ptyalism, etc. and some of them walking about, posterior asthenia and dog-sitting posture. Conjunctivitis was observed in some piglets. Nine piglets out of the 14 cases died at 12.00 to 2.00 p. m. and the other 5 piglets were slaughtered.

One additional piglet, this case (Case No. 2), developed similar symptoms to those mentioned just before at 6.30 a. m. on 22/VII, and died at about noon of the same day. Simultaneous occurrence with Case No. 3.

**Post-mortem :** General congestion. Slight cloudy swelling of the liver. Congestive edema of the lungs. Hemorrhages in subendo- and subepicardium. Incomplete coagulation of the blood. Intensive hyperemia of the cerebral meninges. Pseudolaminar foci with discoloration in the cerebral cortex (after fixation).

**Microscopical :**

*Central nervous system* Acute changes of nerve cells were remarkably observed in all areas of the brain and spinal cord; frequency of the incidence of such cells was higher in the convex of the telencephalon than the other parts. Vacuolation of nerve cells in the olivary nuclei was very conspicuous.

In the convex of the telencephalon, the ground substances of the middle to deep laminae of the cortex increased in eosin staining developing into pseudolaminar features in the portions of gyral legs and valleys; ischemic nerve cells were scattered in the foci, and some of them were incrustated (focal pallor).

Capillary and venous hyperemia was extremely intense in all areas of the brain; it was especially conspicuous in the telencephalic cortex and above all in the pseudolaminar foci. Similar condition was also observed in the cerebral meninges, and venous hyperemia of the meninges of the cerebral sulci was intense; such hyperemic veins sometimes contained fibrin thrombi. Such thrombi were also found in the medulla oblongata. Fresh small focal hemorrhages existed in the rhinencephalon and ventral part of the occipital lobe.

Edema of the brain substance and cerebral meninges was remarkable. In the above noted cortical foci the edema was intensive; perivascular edema was conspicuous and in the dorsal part of the parietal and occipital lobes pseudolaminar loosened foci (status cribrosus) were formed.

Eosinophil cell infiltration was observed interspersed in the cerebral cortex and confined to the meninges of cerebral sulci; perivascular lymph spaces of the capillaries and veins were infiltrated by the cells in such a manner as to develop into cuffing consisting of one or two layers of the cells. Slight swelling of endothelial cells of the blood vessels was also recognized in the same areas.

*Other organs and tissues* Fatty degeneration of liver cells was scatteringly observed in the liver. Fatty degeneration of the kidneys. Mature fat cells with minute vacuoles laid scattered in all the fat tissues; the vacuoles existed in large fat drop of the cells, and many more adjacent to the inner surface of the cell membrane in general; some of these cells had distinctly yellowish pigment substances which were contained in the vacuoles; no cell reaction was yet remarkable.

No. 3 Pr. 2614 (Fig. 5)

**Clinical:** Simultaneous occurrence with Case No. 2. The symptoms of this case were

resembled those of Case No. 2; 22/VII '48, onset at about 6.30 a.m.; revealed circular movement, dog-sitting posture and conjunctivitis; slaughtered at about noon.

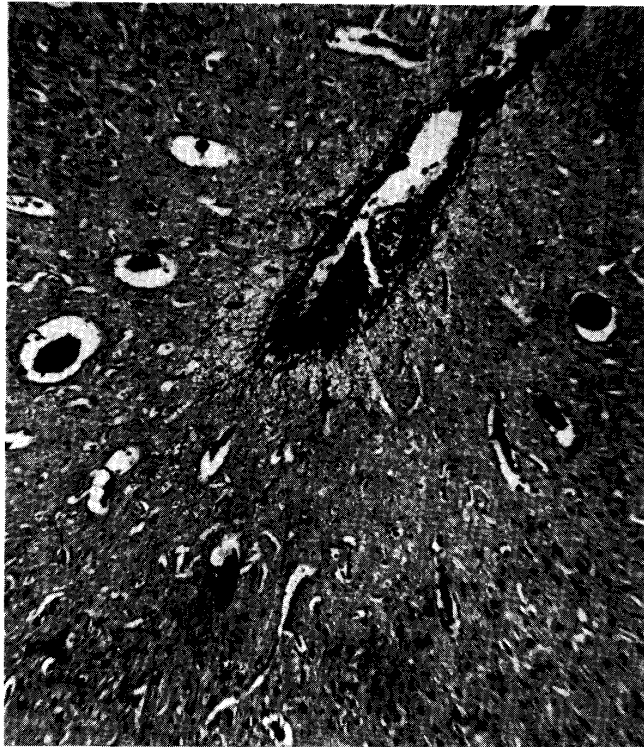**Post-mortem:** Slight cloudiness of the liver. Solitary cyst of the kidney. Pseudolaminar foci with discoloration in the cerebral cortex (after fixation).

**Microscopical:**

*Central nervous system* Acute changes of nerve cells were conspicuous in all areas of the brain, and slight in the spinal cord.

In almost all the gyral legs and valleys of the telencephalon, U-form-pseudolaminar and fleck-form foci were conspicuously observed extending over almost all the laminae of the cerebral cortex; in such foci the ground substances increased in eosin staining to various degrees, and degeneration of nerve cells, showing ischemic cell change, ghost appearance and condition of loss, was strikingly noticed, being especially severe in the foci of status cribrosus described below; no proliferation of microglia cells was yet evident.

FIG. 5. No. 3. Pr. 2614



Lobus parietalis.

Perivascular infiltration of eosinophil leucocytes in the cortex and meningeal eosinophil infiltration in the sulcus. H.-E.  $\times 70$

Capillary and venous hyperemia was particularly intensive in the cerebral cortex, and that of the cerebral meninges was more severe in the portions which cover the telencephalon. Feature of edema was generally conspicuous; considerably severe focal tissue edema which had developed to pseudolaminarly loosened status (status cribrosus) was observed coinciding with the necrobiotic foci in the occipital lobe.

Capillary and venous perivascular infiltration of eosinophil leucocytes was extremely striking in the grey matter of the prosencephalon and especially more intensive in the cortical foci and in the cerebral meninges being concerned with such foci. Tissue emigration of the cells was also striking, resembling the perivascular infiltration in localization; such features that the cells seemed to adhere to degenerating cells were relatively numerous found. Swelling of endothelial cells of the blood vessels was also conspicuous in the grey matter of the prosencephalon.

*Other organs and tissues* Hyperemia in the deep layers of the adrenal cortex. Slight initial metamorphosis of "yellow fat disease" was occasionally recognized in all the mature fat tissues; nuclei of fat cells in the affected areas were pale and swelled, and existence of yellowish pigment substances was not distinct.

No. 4 E. 2376 (Fig. 6)

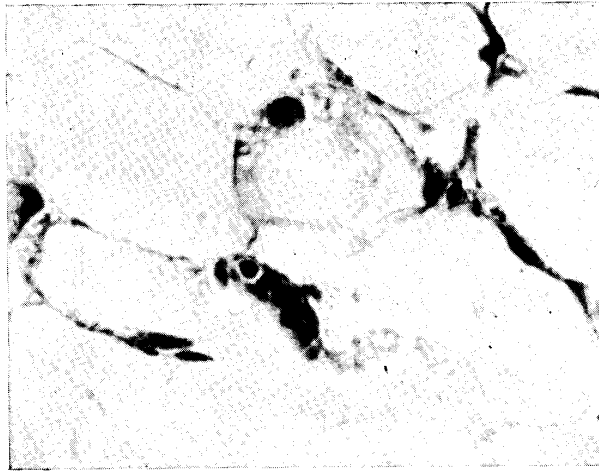
**Clinical:** 5/V '57, onset in the morning; dysorexia, circular movement and defecation of soft feces; died at about noon.

**Post-mortem:** Discolored foci in the cerebral cortex (after fixation).

**Microscopical:**

*Central nervous system* Acute changes of nerve cells were recognized in all areas of the brain, especially comparatively severe in the prosencephalon.

FIG. 6. No. 4. E. 2376



Mature fat tissue (omentum) near the stomach.  
Initial metamorphotic features belonging to lesion  
of "yellow fat disease." H.-E.  $\times 480$

In the cerebral cortex especially in the convex part, extending over almost all the gyri, U-form pseudolaminar foci were conspicuously observed around the sulci extending over middle to deep laminae of the cortex, and in such foci the ground substances increased in eosin staining to various degrees; ischemic and profound cell changes were manifestly recognized scatteringly in some of the foci at least, and these degenerated cells were sometimes incrustated; degeneration of myelin sheaths was not yet remarkable. Metamorphotically changed satellites and microglia cells were observed in the telencephalon and diencephalon; they revealed mitosis

and sometimes pycnosis; but the microglia cells laden with lipoid substances were not remarkable.

Circulatory disturbances consisting of venous and capillary hyperemia, venous fibrin thromboses, diapedetic hemorrhages and edema were extremely intensive, and especially conspicuous in the prosencephalon; such disturbances of the cerebral meninges were the same. Perivascular edema which was somewhat diffusely observed in the cerebral cortex came to be most severe in the necrobiotic foci in which the ischemic cells lay scattered developing partially into initial status cribrosus. In the lumen of the blood vessels there were relatively many neutrophil leucocytes.

Swelling and increase of vascular endothelial cells were clearly observed in the cortical desolated foci described just above. Slight perivascular lymphocytic round cell infiltration was occasionally recognized on the medium-sized veins in such foci.

Eosinophil cell infiltration was found very rarely in the grey matter of the prosencephalon.

No acid-fast pigment substances could be detected anywhere in the brain.

*Other organs and tissues* General congestion. Fatty degeneration and venous thromboses in the liver. Congestive edema of the lungs. Initial features of metamorphosis belonging to changes of "yellow fat disease" were scatteringly recognized in the mature fat tissues in various regions of the body; mesenchymal cells in situ swelled and some of them had certain concentrated dark-yellowish pigment substances in their bodies.

**No. 5 E. 1626** (Figs. 7 & 8)

**Clinical:** 27/XII '54, at about noon suddenly developed convulsive seizures, and next lying posture and pangs; after a little while the animal rose and made anti-clockwise circular movement. Duration of the seizures became gradually prolonged with the evening; pangs bending the neck to the back, continuous epileptiform seizures and inability to rise; died at about 11.00 p. m.

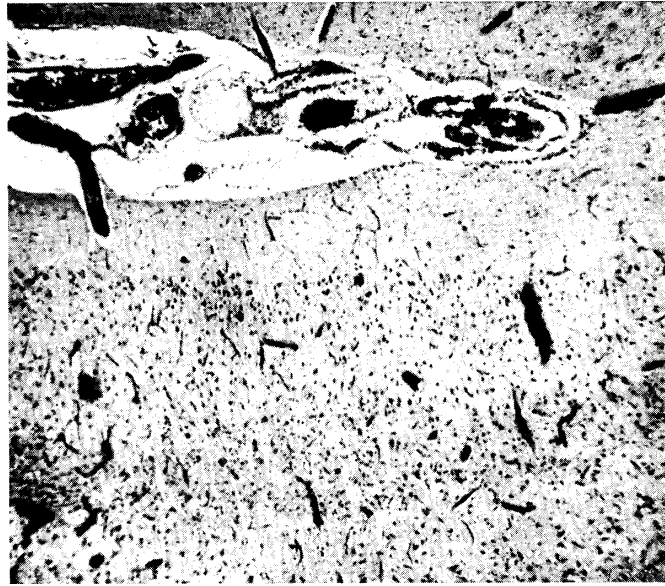**Post-mortem:** General congestion. Cloudiness of the kidneys and heart. Multiple petechiae in the subpericardium. Meningeal hyperemia and edema and parenchymatous hyperemia of the brain. Pseudolaminar foci with discoloration in the cerebral cortex (after fixation).

**Microscopical:**

*Central nervous system* Degeneration of nerve cells was extremely striking extending over almost all areas of the brain; mainly belonging to acute cell changes; slight similar changes were also observed in the spinal cord.

In the prosencephalon, furthermore, especially in the telencephalic cortex, profound and ischemic cell changes were frequently observed; many of the degenerated nerve cells were incrustated and also abnormal dust-like, droplet-form substances appeared around glial element; "wabig" changed nerve cells were also found; these changes, being accompanied with loss of nerve cells, were extremely severe in the legs and valleys of almost all the gyri in the telencephalic cortex. It was noted that pseudolaminar foci in which the ground substances increased in eosin staining developed centering around the middle laminae of the legs and valleys of the gyri of the telencephalic cortex; ischemic cell change was specially notable in such foci (focal pallor). In such desolated foci of the parietal lobe degeneration and fall of myelin sheaths were manifest and sometimes tangential fibers were also involved locally. The desolation was

FIG. 7. No. 5. E. 1626



## Lobus parietalis.

Pseudolaminar pallidness in the cortex; accompanied by slight microglial proliferation; capillary and venous hyperemia is intensive. Tissue infiltration of a few of eosinophil leucocytes in the cortex. Venous fibrin thromboses in the sulcus.  
H.-E.  $\times 40$


accompanied with slight proliferation of microglia cells.

Capillary and venous hyperemia was extremely intense and especially conspicuous in the telencephalic cortex around the sulci. Fibrin thrombi were easily detectable here and there in the veins of medium and smaller diameter. Edema was severe extending over nearly all areas of the cerebral cortex, i. e. edematous dilatation of the perivascular lymph spaces and tissue edema around the veins of medium and smaller diameter, etc.; the edematous changes were severe especially in the portions of the brain around the cerebral sulci, and in portions where U-form loosened areas were pseudolaminarly formed. A few perivascular small hemorrhages were found. Venous hyperemia, venous thromboses and edema in the meninges were also remarkable in the prosencephalon, especially in the sulci.

Capillary and venous infiltration of eosinophil leucocytes was diffusely observed in the grey matter of the prosencephalon in general, although it was rather slight in general; but the frequency of existence of the leucocytes was somewhat higher in the telencephalon especially in the above-noted desolated foci. The infiltration in the meninges was liable to catch eye in the sulci of the telencephalon and it was mostly of venous type; the degree was slight like that in the brain substance. Moreover, slight venous perivascular infiltration of eosinophil leucocytes was occasionally found in the white matter of the telencephalon. Mild tissue infiltration was noted in the telencephalic cortex, also.

Swelling and increase of capillary and venous endothelial cells were intensive in both the desolated cortical foci and meninges of the telencephalic sulci.

FIG. 8. No. 5. E. 1626



Lobus frontalis. Middle lamina of the cortex.  
Ischemic changes of nerve cells, being accompanied by incrustation,  
in a pseudolaminar pallid lesion. Toluidin-blue.  $\times 480$

Acid-fast pigment substances could not be found anywhere in the brain.

*Other organs and tissues* Fatty metamorphosis of the liver. Abundant hyaline urinary casts in the kidneys. Venous fibrin thrombus formation in the splenic hilus, lungs and tonsils. Features of initial metamorphosis of "yellow fat disease" were occasionally found out in the mature fat tissues; such lesions were accompanied with swelling of fat cell nuclei.

No. 6 E. 2433 (Fig. 9)

**Clinical:** 23/VI '57, no abnormality revealed before the evening. 24/VI, in the morning, developed dysorexia, languishment, posterior asthenia, astasia, spumy salivation and trembling of the oral angles, etc.; at 10.00 a. m., T. 41.5°C, P. 180, posterior asthenia and continual epileptiform seizures; died in the afternoon. This case and Case No. 25, raised in the same piggery, were affected, the one following on the heels of the other.

**Post-mortem:** Hyperemia of the brain. Slight hemorrhages in the gastric mucosa. Pseudolaminar foci with discoloration in the cerebral cortex (after fixation).

**Microscopical:**

*Central nervous system* Acute changes of nerve cells were extremely conspicuous extending over all areas of the brain and spinal cord, especially severe in the prosencephalon.

In all the gyri of the telencephalon, there were conspicuous U-form pseudolaminar foci, being around the sulci, in which the ground substances increased in eosin staining extending

FIG. 9. No. 6. E. 2433



Dorsal part of the lobus occipitalis

Pseudolaminar pallidness in the cortex. Venous hyperemia. Meningeal eosinophil cell infiltration, and perivascular eosinophil infiltration being accompanied by tissue emigration of a mere few of the cells around the vein in the cortex. H.-E.  $\times 40$

over the middle to deep cortical laminae; the degree of such tissue desolation was exceedingly severe in the dorsal parts of the parietal and occipital lobes; nerve cells in the foci developed ischemic and profound changes, and some of them were incrustated with abnormal droplet substances (focal pallor). Slight reactive proliferation of microglia cells was observed in the desolated foci of the parietal and occipital lobes: some of the cells revealed mitosis, but the cells laden with lipoid substances were not remarkable.

Slight perivascular infiltration of eosinophil leucocytes on the capillaries and veins was observed in all the grey matter of the prosencephalon; above all it was somewhat conspicuous in the desolated foci and in the meninges which cover those foci. Furthermore, emigrated eosinophil cells in the cerebral cortex were recognized scatteringly, and somewhat numerous in the desolated foci.

Swelling and proliferation of endothelial and adventitial cells of both the capillaries and veins were very intensive and conspicuous, especially within and near the pseudolaminar cortical foci and in the meninges which are concerned with them.

Acid-fast pigment substances could not be observed in any parts of the brain.

*Other organs and tissues* Scattering centrolobular fatty degeneration in the liver. Congestion of the liver. Slight fatty degeneration of the kidneys. Lesions of initial metamorphosis of "yellow fat disease" were recognized scatteringly in the mature fat tissues, accompanied with swelling of fat cell nuclei in situ: the existence of yellowish pigment substances was not evident.

No. 7 E. 35 (Fig. 10)

**Clinical:** 29/IX '48, stood still at one corner of the pen; showed drooping of the head and mental depression: T. 39.2°C and P. 100 in the forenoon at the time of the first medical examination; clockwise circular movement drooping the head at about 3.00 p. m. 30/IX, died at about 4.00 a. m.

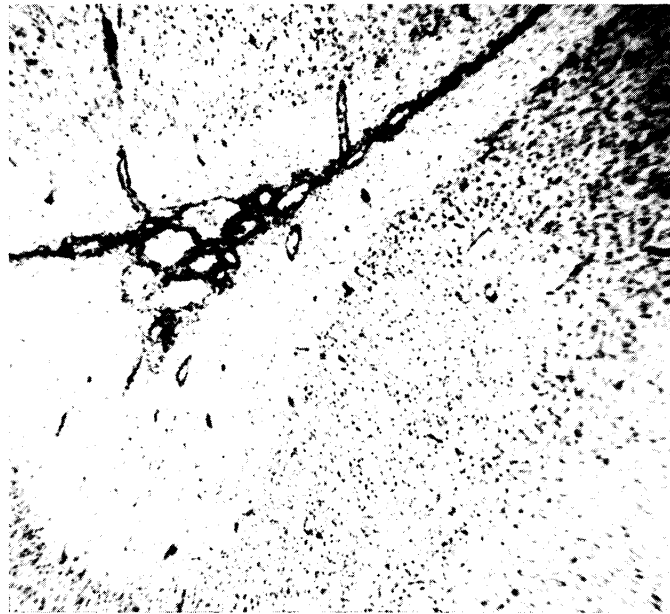**Post-mortem:** Pseudolaminar foci with discoloration in the cerebral cortex (after fixation).

**Microscopical:**

*Central nervous system* Acute changes of nerve cells were recognized remarkable in all areas of the brain, but it was generally slight.

In the telencephalic cortex, desolated foci were found in which the ground substances increased to various degrees in eosin staining, mostly around the sulci, extending over the second to fourth laminae; various features of ischemic and profound changes of nerve cells were manifestly evident in such foci, and also loss of nerve cells was evident; some of the

FIG. 10. No. 7. E. 35



Lobus parietalis.

Focal pallor in the cortex. Thionine. × 40

degenerated nerve cells were incrustated (focal pallor). Similar necrobiotic lesions existed in the caudate nuclei and thalamus. Moreover, some of the desolated foci were accompanied with loss of nerve cells in striated, pseudolaminar and fleck-form areas. Coinciding with the foci showing loss of nerve cells, section preparations to which myelin sheath staining was applied, even if boundaries of the foci were rather indistinct, revealed myelin sheath degeneration such as irregular droplet-form and cloddy substances.

Microglia cells in the prosencephalon especially in the telencephalic cortex showed metamorphosis in general, and almost all the cells exhibited mitosis; some of them were incrustated

with abnormal fine droplet-like substances. Some of the foci which showed loss of nerve cells were accompanied with slight increase of microglia cells.

States of edema in the brain substances were more severe in the necrobiotic lesions, and they were observed as demonstrating pseudolaminar and fleck-form tissue loosening. Edema of the cerebral meninges was somewhat remarkable in the sulci which were concerned with the cortical lesions. Venous hyperemia was also somewhat intense in the desolated lesions and in the meninges which cover them.

The mildest perivascular cell infiltration, mainly consisting of lymphocytes, which was observed generally as a venous one existed diffusely in the prosencephalic grey matter, and it was remarkably less in the desolated lesions; similar infiltration was also observed in the meninges covering the telencephalon. Being somewhat conspicuous in the cerebral meninges which cover the desolated lesions of the telencephalon, a mere few eosinophil cells were mingled in the infiltrating cell element; simultaneously neutrophil leucocytes were mingled in a measure, and some of them infiltrated to the adjacent superficial cortical lamina.

Slight swelling and increase of vascular endothelial cells were observed in and near the desolated lesions mentioned above.

*Other organs and tissues* In the mature fat tissues, swelling of fat cell nuclei was found here and there.

**No. 8 Pr. 3594** (Figs. 11~13)

**Clinical:** 10/XI '54, onset; gave rise to certain nervous symptoms (details were not reported to the writer). 11/XI, died at about noon.

**Post-mortem:** General congestion. Severe cloudiness of the liver and heart. Multiple greyish-white foci in the liver. Congestive edema and hemorrhages in the lungs. Intensive hyperemia of the brain. Pseudolaminar discolored foci in the cerebral cortex.

**Microscopical:**


*Central nervous system* Acute changes of nerve cells were extremely conspicuous in all areas of the brain and spinal cord, especially in the prosencephalon.

In the telencephalic cortex and even in the other portions of the prosencephalon, necrobiotic foci, in which the ground substances increased in eosin staining to various degrees and ischemic and profound changes of nerve cells were very evident, existed extending over the second to fifth laminae in parallel with surface of the telencephalon; these changes were especially remarkable in U-form territories around the sulci; many of the degenerated nerve cells were incrustated (focal pallor). It was pointed out that the desolation of the tissue in some of the necrobiotic foci probably had developed perivascularly. Some of the necrobiotic foci were accompanied with observable loss of nerve cells in pseudolaminar extent.

Extending over almost all areas of the telencephalic cortex, myelin sheath degeneration was clearly observed as alterations to irregular droplet-form, spherical and balloon-form, etc. In the prosencephalon the proliferative process of microglia cells was not very active although slight mitosis of the cells was frequently observed. Some incrustated microglia cells also were seen.

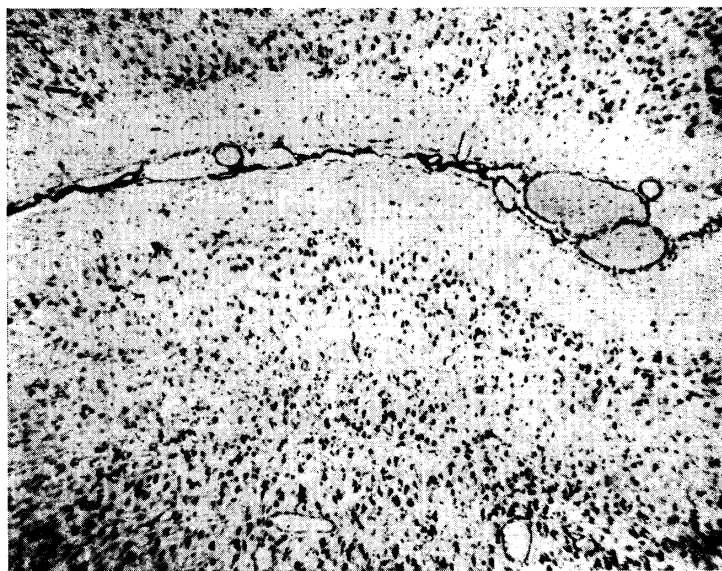
Venous hyperemia was intensive in the prosencephalon, especially more strong in and near the necrobiotic foci, occasionally accompanied with fibrin thromboses. Hyperemia in the cerebral meninges was notable in the portions which cover the telencephalon, and many of

FIG. 11. No. 8. Pr. 3594



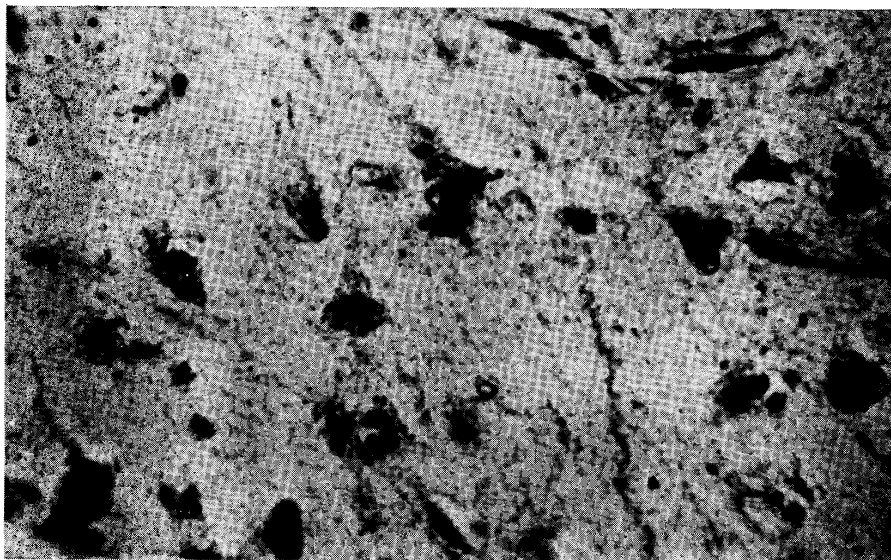
Pars lumbaris of the medulla spinalis.  
Longitudinal section.  
Nerve cells, a majority of which shows evident acute changes, in the ventral horn. Toluidin-blue.  $\times 120$

FIG. 12. No. 8. Pr. 3594



Lobus parietalis.  
Pseudolaminar focal pallor in the cortex.  
Toluidin-blue.  $\times 40$

FIG. 13. No. 8. Pr. 3594



Lobus parietalis. Middle lamina of the cortex.

Ischemic changes of nerve cells, being accompanied by incrustation, in a pseudolaminar pallid lesion. Toluidin-blue.  $\times 480$

the blood vessels contained fibrin thrombi. Extending over all parts of the telencephalic cortex edematous changes were severe, and especially the following changes in and near the necrobiotic foci attracted attention, viz., demarcated, pseudolaminar and fleck-form tissue loosening (status cribrosus).

In general, vascular endothelial cells slightly swelled; a mere few eosinophil cells which were infiltrated to the walls of the blood vessels were found in the telencephalic grey matter.

No acid-fast pigment substances could be found in any parts of the brain.

*Other organs and tissues* Centrolobular necrobiosis and severe fatty degeneration in the liver. Fatty degeneration of the kidneys. Hyperemia of the adrenal glands. Hyperemia, hemorrhages and multiple fibrin thromboses in gastric mucosa of the fundus gland region.

Initial metamorphosis belonging to changes of "yellow fat disease" was observed scatteringly in the mature fat tissues; fat cell nuclei in situ were pale and swelled; yellowish pigment substances were not uncertainly identified.

#### No. 9 E. 1653

**Clinical:** Developed certain nervous symptoms (details were not reported to the writer). 16/II '55, died after one day course of the disease.

**Post-mortem:** Desolated pseudolaminar foci with discoloration in the cerebral cortex (after fixation).

#### **Microscopical:**

*Central nervous system* Acute changes of nerve cells were remarkable in all areas of the brain especially in the prosencephalon.

In the parietal lobe and dorsal part of the occipital lobe of the telencephalon, pseudolaminar

areas in which the ground substances slightly increased in eosin staining were observed around the sulci of a few gyri; variously degenerated nerve cells, showing ischemic change and loss of nerve cells, etc., were many in areas centering around the middle laminae (focal pallor). Glial reaction was hardly recognized.

Hyperemia was not very intense. Slight edematous dilatation of the perivascular lymph spaces was observed. The cerebral meninges were slightly edematous, also.

Eosinophil leucocytes were no more than a very small number of pericapillary ones in the cortex and of perivenous ones in the meninges of the sulci in the telencephalon. Swelling of endothelial cells of the blood vessels was hardly observed.

A toxoplasma-pseudocyst without any reaction was found in the cortex of the occipital lobe, in the medial portion of the right cerebral hemisphere. Furthermore, macrophages which took dust-like organisms (?) were recognized in the lumen of the blood vessels of the cerebral meninges.

No acid-fast pigment substances were detected anywhere in the brain.

#### No. 10 E. 2375

**Clinical:** 24/V '57, onset in the afternoon; dysorexia, clockwise circular movement, defecation of soft feces, T. 41.4°C, P. 80~85. 25/V, astasia, no tail resistance, T. 39.0°C, P. 90, no circling, but straight went ahead; died at about noon.

**Post-mortem:** Pseudolaminar desolated foci with discoloration in the cerebral cortex (after fixation).

#### **Microscopical:**

*Central nervous system* Acute changes in nerve cells were extremely conspicuous in all areas of the brain especially in the prosencephalon.

In every place of the grey matter of the prosencephalon focal pallor was clearly evident; these foci were particularly remarkable in the telencephalic cortex in the convex part, developing mainly centering about the middle laminae around the sulci; the ground substances in these foci increased in eosin staining to various degrees, and such foci embraced many degenerated nerve cells showing ischemic change, profound change, ghost appearance, vacuolization, etc.; some degenerated nerve cells were incrustated by small quantity of abnormal dust-like substances. Proliferation of microglia cells was somewhat intensive in such necrobiotic foci and occasionally presented irregular fleck-form territories of the proliferation which developed around the medium-sized veins; it appeared likely that such a feature represented the initiation of "mobiler Typus des Abbaus" being accompanied with occurrence of below described mild vascular reaction.

Swelling and increase of cells of the walls of the blood vessels were observed in the grey matter of the telencephalon diffusely in general, especially more intense in and just outside of the desolated foci; the latter might manifest an aspect representing a response to the above glial proliferation.

In the grey matter of the prosencephalon and the meninges which cover it, capillary and venous hyperemia was very intense; it brought on diapedetic hemorrhages everywhere and was accompanied with fibrin thromboses. Edematous changes were also observed in the grey matter of the prosencephalon, viz., small foci of tissue loosening around the blood vessels and demarcated tissue loosening on the necrobiotic foci.

A rare eosinophil cell infiltration was recognized in the grey matter and meninges of the sulci of the telencephalon. Occasionally, slight perivasucular lymphocytic round cell infiltration was found on the blood vessels of medium diameter in and just outside of the necrobiotic foci. A few emigrating neutrophil leucocytes were found in the telencephalic cortex.

In section preparations to which carbol-fuchsin-hematoxylin stain was applied, a small quantity of dark-reddish homogeneous acid-fast pigment substances were frequently recognizable at the adventitial portion of the small veins. Sometimes, similar substances were also found in protoplasm of the degenerated nerve cells as delicate droplet-like ones.

*Other organs and tissues* General congestion. Severe fatty degeneration of the liver and kidneys. Initial metamorphic features of lesion of "yellow fat disease" were scatteringly recognized in the mature fat tissues in various regions of the body; fat cell nuclei in situ were pale and swelled.

No. 11 Pr. 2691 (Fig. 14)

**Clinical:** 9/XI '48, in the morning, languishment, dysorexia, ptyalism, dyspnoea, sometimes mental excitement, cyanotic visible mucosae, T. 39.1°C; afterward, progressing under continuation of similar symptoms. 10/XI, died in the night.

**Post-mortem:** Hyperemia of the cerebral meninges. Minute whitish spots in the liver. Pseudolaminar desolated foci with discoloration in the cerebral cortex (after fixation).

**Microscopical:**

*Central nervous system* Acute changes of nerve cells were extremely conspicuous in all areas of the brain especially in the telencephalic cortex.

Multiple necrobiotic foci (focal pallor) existed extending over almost all the telencephalic cortex around the sulci; many of them were located in the second to fifth laminae and some in the deep; those in which the ground substances increased in eosin staining to various degrees manifested U-form pseudolaminar aspects; in those in which were the changes severe, there were degenerative nerve cells which showed ischemic and profound cell changes. In some of the foci incomplete malacia developed taking of fleck-form and U-form, and such lesions were ahead macroscopically evident in the NISSL-stained section preparation as deeply stained ones due to densely accumulated cells, possessing many fat compound granular corpuscles, many mitotic microglia cells and many mesenchymal cells.

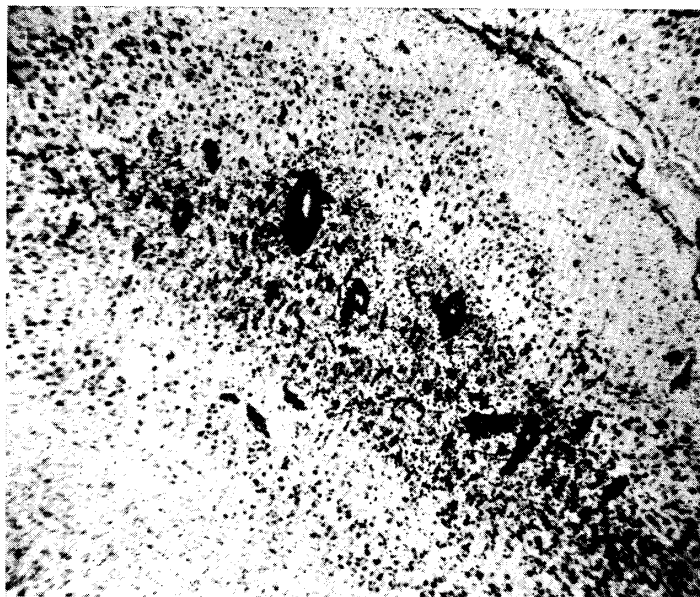
Coinciding with the desolated lesions, degeneration of myelin sheaths was clearly observed, and especially in the malactic foci it was evident as focal fall to loss of myelin sheaths with sharp margin.

Swelling and increase of cells of the walls of the blood vessels were not intensive excepting those in the incompletely malactic foci. In and just outside of the malactic foci, perivasucular, mainly perivenous, thick cuffs consisting of round cell infiltration were often observed.

Capillary and venous hyperemia was intensive and occasionally accompanied with small hemorrhages. In the telencephalon, edema was somewhat severe in the cortex and meninges of the sulci, especially more so in and just outside of the desolated foci.

Mild perivasucular and tissue infiltrations of eosinophil cells were scatteringly observed in all areas of the grey matter of the prosencephalon and slightly remarkable in the incompletely malactic foci; in the latter some perivasucular cuffs were formed by a few layers of the cells. Similar infiltration was also slightly observable in the meninges of the prosencephalon especially

FIG. 14. No. 11. Pr. 2691



Lobus parietalis.

Pseudolaminar "gliös-mesenchymaler Abbau"  
in the cortex. Toluidin.  $\times 40$

in the sulci concerned with the desolated foci.

*Other organs and tissues* General congestion. Fatty degeneration of the liver and kidneys. Initial metamorphic features belonging to lesion of "yellow fat disease" were observed scatteringly in the various mature fat tissues; fat cell nuclei in situ were pale and swelled.

**No. 12 Pr. 2785**

**Clinical:** 6/VII '49, dysorexia, occasional epileptiform seizures and spumous salivation from the oral angles. 7/VII, 40.6°C, P. 170, poor condition of nutrition, slight conjunctival hyperemia, palpitation, peristalsis vanished, tachypnoea, anti-clockwise circular movement, epileptiform seizures; died at 7.20 p. m.

**Post-mortem:** Hyperemia of the cerebral meninges. Fatty metamorphosis of the liver. Metastrongyliasis of the lungs. Desolated pseudolaminar foci with discoloration in the cerebral cortex (after fixation).

**Microscopical:**

*Central nervous system* Acute changes of nerve cells were conspicuous in all areas of the brain and spinal cord, especially severe in the cerebrum.

The grey matter of the prosencephalon developed scattering ischemic necroses of nerve cells, and especially in the convex part of the telencephalon, there were multiple U-form pseudolaminar necrobiotic foci in the middle or second to fifth laminae around the sulci, in which the ground substances increased in eosin staining to various degrees; many nerve cells which showed ischemic and profound cell changes existed in the foci, and some of those cells were incrustated (focal pallor). Glial reaction responding to the desolation was mild yet, but

in the thalamus swelling and increase of microglia cells were occasionally found in fleck-form.

Venous hyperemia was very intense and sometimes followed by small diapedetic hemorrhages; especially remarkable in the desolated foci and the meninges of the sulci concerned with them in the prosencephalon. Edematous process was also obvious in all areas of the brain and spinal cord, particularly notable in the grey matter of the prosencephalon; perivascular and demarcated focal edemata were evident in the telencephalic cortex.

Venous and capillary perivascular infiltrations of eosinophils were intense throughout the grey matter of the prosencephalon; especially in and near the desolated foci there were a great number of the cells, and they formed remarkable cuffing developing into a maximum 4~5 cell layers. Eosinophil tissue infiltration around the blood vessels was clearly to be seen in the same desolated foci; aspects such as the infiltrated eosinophils disposed around degenerative nerve cells were found occasionally. Meningeal eosinophil cell infiltration was conspicuously observed in the prosencephalon, and it was strikingly intense in the sulci concerned with the telencephalic desolated foci in general, being usually perivenous in character.

Swelling and increase of cells of the blood vessel walls were generally diffusely recognized in the grey matter of the prosencephalon being most intensive in and near the desolated foci. Somewhat intensive infiltration of round cells consisting mainly of lymphocytes was found in and near the desolated foci in the prosencephalon on rare occasions; round cell infiltration was also present perivenously in the dorsal horn of the thoracic part of the spinal cord.

*Other organs and tissues* Fatty metamorphosis of the liver. No obvious features of changes of "yellow fat disease" were present in the mature fat tissues.

**No. 13 Pr. 3508** (Figs. 15 & 16)

**Clinical:** 17/I '50, from morning, languishment, dysorexia, staggering in walking and pangs; at night walking about with mental excitement. 18/I, staggering in walking, languishment, cyanosis of the visible mucous membranes, palpitation and peristaltic acceleration, T. 36.4°C, P. 144, R. 6,960,000, W. 24,600, albuminuria (+); slaughtered.

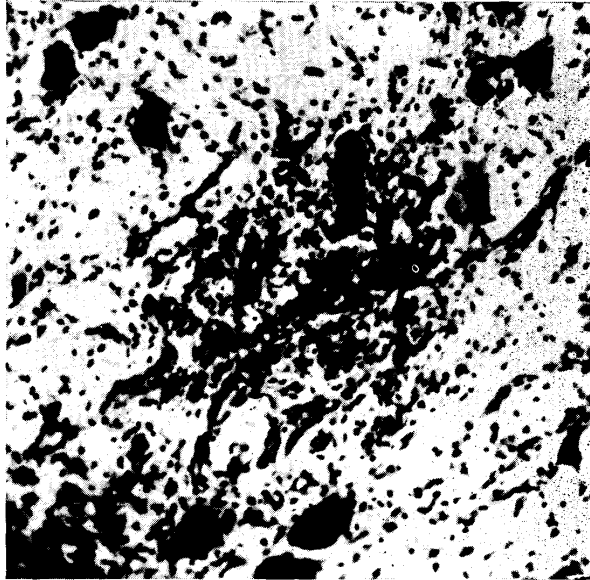
**Post-mortem:** Purulent bronchopneumonia. Hyperemia of the cerebral meninges. Pseudolaminar desolated foci with discoloration in the cerebral cortex (after fixation).

**Microscopical:**

*Central nervous system* Acute changes of nerve cells were conspicuous extending over all areas of the brain and spinal cord especially in the prosencephalon.

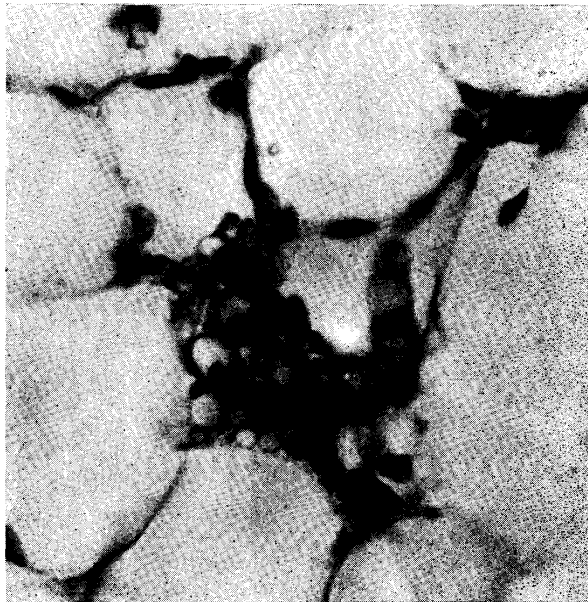
The grey matter of the prosencephalon generally showed pallidness; in the pallid foci the ground substances increased in eosin staining to various degrees; in almost all territories of the cerebral cortex, such lesions were observable as mono-, poly-pseudolaminar and fleck-form ones, mostly being parallel with the surface of the cortex; there were many scattering ischemic nerve cells in the lesions. Coinciding with the necrobiotic areas, especially in the convex part of the parietal and temporal lobes, fleck-form and pseudolaminar focal glio-mesenchymal reaction was very remarkably notable in the gyral legs, tops and valleys of the cortex; occasionally as a result of mutual confluence of these foci U-form features were induced; generally these focal desolations displayed the characters of incomplete malacia, being accompanied with intensive proliferation of microglia cells, vascularization and a number of fat compound granular corpuscles, and embracing remaining ischemic nerve cells and those which showed ghost appearance. Degeneration of myelin sheaths was very remarkable in all

FIG. 15. *No. 13. Pr. 3058*



Mesencephalon.  
Focal "gliös-mesenchymaler Abbau" in  
the grey matter. Thionine.  $\times 120$

FIG. 16. *No. 13. Pr. 3058*



Mature fat tissue at the retropharyngeal region.  
Changes of "yellow fat disease." Mesenchymal  
cell proliferation. Yellowish and dark-yellowish  
pigment substances are evident. H.-E.  $\times 480$

the desolated areas, and in the malactic foci it developed into fall and loss.

Furthermore, malactic desolated foci were observed in the cerebral nuclei, thalamus and red nuclei.

Eosinophil cell infiltration in the brain substance was confined within the grey matter of the prosencephalon and was generally intensive in degree; it seemed to be not especially closely connected with the malactic foci; it was observed as mainly pericapillary and perivenous in type and sometimes emigrated into the tissue around the blood vessels with cuffs. That of the meninges was usually confined within the sulci of the telencephalon.

In addition, as an infiltrating cell element lymphocytic round cells were noticed in parallel with eosinophils; there were a great number of the round cells in the malactic foci, the circumferences of which and the other necrobiotic foci around the sulci of the telencephalon, and the cell infiltration was located in the medium-sized veins predominantly; similar round cell infiltration also existed in the meninges of the sulci of the telencephalon. It is natural that both the round and the eosinophil cell infiltration occurred on the same blood vessels. Venous hyperemia was intensive, especially in the prosencephalon; sometimes being accompanied with a small quantity of fibrin thrombi and small hemorrhages. Edema was not very intense in general although it was somewhat marked in the prosencephalon; however, it was notable being perivenous fleck-form, demarcatedly striated and pseudolaminar tissue loosening in having relation to the desolated foci.

Swelling and increase of cells of the blood vessel walls were somewhat intense in and just outside of the foci of desolation; those features in the malactic foci naturally were specially remarkable.

*Other organs and tissues* Slight fatty degeneration of the liver and kidneys. Metamorphotic features of "yellow fat disease" were clearly recognized scatteringly in the mature fat tissues, consisting of changes of various stages ranging from initial stage to appearance of large vacuoles of which the content consisted of evident yellowish pigment substances; such lesions were accompanied with activation of mesenchymal cells in situ. The yellowish pigments exhibited qualitatively various staining states ranging from yellowish homogeneous to concentrated homogeneous dark-yellowish.

No. 14 Pr. 3570 (Fig. 17)

**Clinical:** 10/VIII '54, onset in the morning; in the same pen two animals developed epileptiform seizures, simultaneously. Present state in the evening: went straight ahead and ran against the wall; further tried to climb the walls and other objects and falled, at the same time the animals violently moved their limbs pouring out spume from the oral angles for 1.0~1.5 minutes; soon rose, and stood still at a corner of the pen and presented mental depression for about 2.0 minutes; after that the same seizures were repeated many times; dysorexia and adipsia; excoriations in the nasal and tail regions. 11/VIII, the seizures ceased at about 2.00 a. m.; mental depression and lying posture. Present state at about 10.00 a. m.; right-lying posture; tremor of the face, breast and abdomen; dysorexia and adipsia; no utterance; irregular skin temperature; probable feverish; no defecation. This case (No. 14) was slaughtered at about 3.00 p. m. Post-mortem examination was made of only this case.

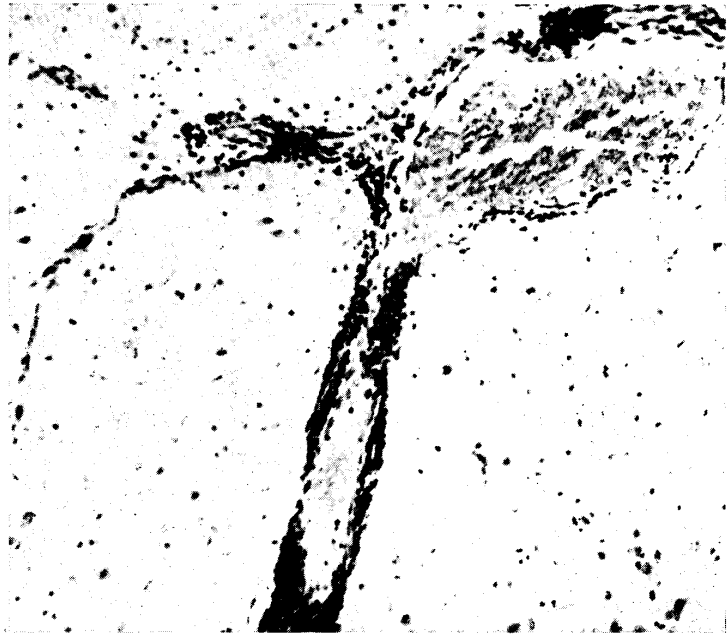
**Post-mortem:** Hyperemia and edema of the brain. Pseudolaminar desolated foci with discoloration in the cerebral cortex (after fixation).

**Microscopical :**

*Central nervous system* Acute changes of nerve cells were conspicuous in all territories of the brain, especially in the prosencephalon.

In the telencephalic cortex, U-form pseudolaminar desolated foci were outstanding, being located in the middle laminae for the most part and also in the second to fifth laminae; the foci showed various transitional necrotic processes, ranging from focal pallor or pallidness (scattering ischemic necroses) to fleck-form or U-form pseudolaminar malacia which came to exhibit striking fat compound granular corpuscle formation developing mainly in the convex part; various degenerative nerve cells, evidencing ischemic change, ghost appearance and loss, were notable in and just outside of the foci; gliomesenchymal reaction was somewhat intensive in general in the malactic foci; in the desolated areas other than the malactic foci glial reaction was hardly of any account yet.

FIG. 17. No. 14. Pr. 3570



Lobus parietalis.

Perivascular eosinophil leucocyte infiltration into the vein in the cortex; there is also meningeal infiltration of eosinophils in the sulcus. H.-E.  $\times 120$

Capillary and venous perivascular eosinophil cell infiltration was exceedingly intense, and conspicuous in all parts of the grey matter of the prosencephalon especially in the pallid foci of the telencephalon; there were many thick cuffs of which the layers of eosinophil leucocytes developed into 7~8 layers in maximum. Eosinophil infiltration in the cerebral meninges was confined within the prosencephalon. Tissue infiltration of eosinophil cells was observed in the grey matter of the prosencephalon; it was intensive in and near the malactic foci and slight in the other areas.

Venously perivascular lymphocytic round cell infiltration existed in and near the malactic foci, frequently being very intensive; it goes without saying that the infiltration contained eosinophil leucocytes simultaneously.

Venous hyperemia was intense in both the brain substance and meninges. Appearance of edematous features was noted as demarcating tissue loosening in the circumference of the desolated, especially of the malactic, foci and as tissue loosening in surrounding areas of the blood vessels.

Swelling of endothelial cells of the blood vessels could be recognized even in the pallid foci other than the malactic ones.

No acid-fast pigment substances were recognized anywhere in the brain.

*Other organs and tissues* Slight fatty degeneration of the kidneys. Features of changes of "yellow fat disease" were not distinct.

#### No. 15 Pr. 2738

**Clinical:** 13/III '49, astasia; tremor of the limbs. 14/III, indications were the same as on the previous day; T. 37.8°C. 15/III, somewhat aggravated; slaughtered.

**Post-mortem:** Slight hyperemia of the cerebral meninges.

#### **Microscopical:**

*Central nervous system* Acute changes of nerve cells were observed in all areas of the brain and spinal cord, but the severity was not very intense.

Scattered slight perivascular eosinophil infiltration into the capillaries and veins was observed in the grey matter of the prosencephalon; in the diencephalon there were relatively thick cuffs of eosinophil leucocytes in which mingled lymphocytes, also; in the telencephalon the infiltration was observed mainly in the dorsal part and rarely in the subcortical white matter. Furthermore, in the molecular layer of the cerebellum a few small-sized veins were found, which slightly suffered from eosinophil cell infiltration. Slight eosinophil cell infiltration into the meninges was observed in the sulci of the convex part of the telencephalon. Moreover, extremely slight lymphocytic infiltration existed in the telencephalic and cerebellar meninges.

In both the brain substance and meninges, venous hyperemia was somewhat intensive, being sometimes accompanied with small perivascular hemorrhages. Slight edematous dilatation of the perivascular lymph spaces was observed in the grey matter of the prosencephalon.

Merely slight swelling of endothelial cells of the blood vessels was observed only in grey matter of the telencephalon. Meninges of the sulci of the cerebellum exhibited slight cell proliferation, having a few macrophages.

*Other organs and tissues* Fatty degeneration of the liver and kidneys. Hyperemia and hemorrhages in the adrenal medulla. Scattered features of initial metamorphosis of "yellow fat disease" were observed in the mature fat tissues.

#### No. 16 Pr. 2895

**Clinical:** 4/V '50, Preventive vaccination against hog cholera. 6/V, abnormal general condition was recognized. 7/V, mental depression, tachypnoea, dysorexia, convulsions, ptyalism, emesia, astasia, T. 40.0°C. 8/V, got better; T. 40.8°C, P. 126, A. 98; slaughtered.

**Post-mortem:** Slight hyperemia of the cerebral meninges. Pseudolaminar desolated foci with discoloration in the cerebral cortex (after fixation).

**Microscopical :**

*Central nervous system* Acute changes of nerve cells were intensive extending over all areas of the brain and spinal cord, especially conspicuous in the prosencephalon.

In the dorsal part of the frontal and occipital lobes large localized desolation foci were present, developing around the middle laminae of the cortex as centers and localizing in the gyral legs and valleys; the foci presented loosened edematous changes, severe loss of nerve cells and ischemic change, profound change and ghost appearance of remaining nerve cells; manifest demyelination was observed coinciding with these foci; proliferation of microglia cells was not very intensive, only the cells laden with lipid substances were recognized; the foci accompanied with slight vascularization.

In the grey matter and meninges of the prosencephalon perivenous infiltration of eosinophil cells was very intensive, frequently developing into formation of thick cuff, especially more intensive in the cortex around the sulci; tissue emigration of the cells around the blood vessels was also more intensive in the areas around the sulci of the telencephalon being especially conspicuous in the desolated foci; the infiltration in the meninges was more intensive in the sulci than in the other meningeal portions. Moreover, a small number of lymphocytic round cells mingled with the perivascularly infiltrated cells in and just outside of the desolated foci and in the sulci concerned with them, in the telencephalon.

Swelling of endothelial cells of the blood vessels was diffusely intensive, indisputable in the desolated foci in the telencephalon, in the grey matter of the prosencephalon in general. Venous hyperemia was remarkable in the brain substance and meninges of the prosencephalon. In addition to the edematous process in the above noted desolated foci, small fleck-form loosened tissue edemata were seen here and there around the small-sized blood vessels in the cortex of the olfactory gyri.

*Other organs and tissues* Features of initial metamorphosis of "yellow fat disease" were occasionally found in the mature fat tissues; nuclei of fat cells in situ were pale and swelled; yellowish pigment substances were not evident.

No. 17 Pr. 3418 (Fig. 18)

**Clinical:** 4/IX '53, from about two days before, 8 piglets became ill sporadically from one piggery; 4 out of them died, one was dying (Case No. 20), and the others were getting better. This case (Case No. 17) died on 4/IX; representing nervous symptoms consisting of staggering, convulsions, etc., in lifetime.

**Post-mortem:** Hyperemia of the brain. Focal pseudolaminar cortical desolation in the cerebrum. Necrotic gastritis.

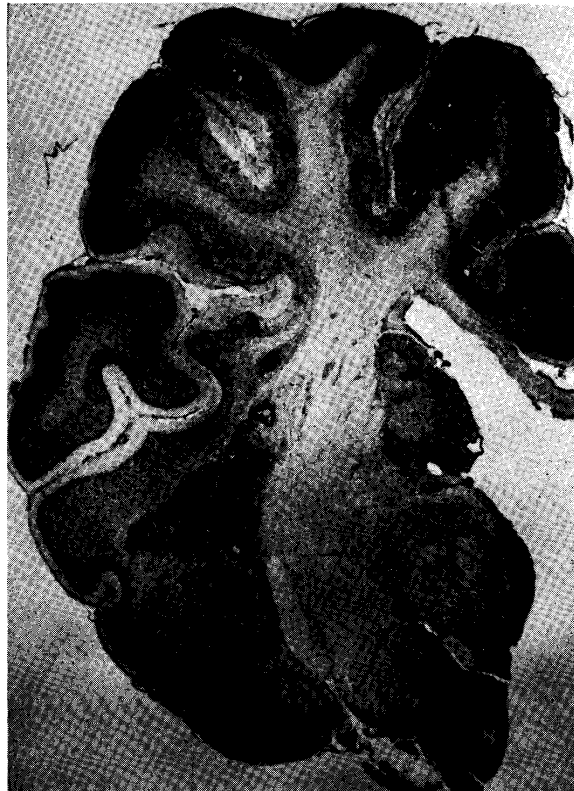**Microscopical :**

*Central nervous system* Acute changes in nerve cells were extremely conspicuous extending over all areas of the brain and spinal cord.

Focal desolation which exhibited various necrotic processes, developing into fat compound granular corpuscle cell malacia in most severe occasion, was very outstanding in almost all the grey matter of the prosencephalon; macroscopically such lesions were ahead clearly observed as pallid to deeply stained areas on NISSL-stained section preparations; i. e., ranging from scattering ischemic necroses (focal pallor; the ground substances increased in eosin

staining) to loss of nerve cells and, furthermore, to complete fat compound granular corpuscle cell malacia, which was observed to take the form of fleck-form, striated and pseudolaminar foci or pseudolaminar-U-form around the sulci in the second to fifth laminae. In the foci which showed loss of nerve cells, the brain tissues around the dilated veins were stained basic and were delicately pulverized being transformed into dust-like; remaining nerve cells in such areas exhibited such features as to suggest calcification; microglial proliferation which was accompanied with rod cell formation was yet generally mild, although vascularization was relatively conspicuous, but the fleck-form foci of "gliös-mesenchymaler mobiler Abbau" which

FIG. 18. No. 17. Pr. 3418



Malactic desolation of various stages in the grey mater of the prosencephalon. Thionine  $\times 3.2$

developed centering around the dilated veins were often observed. In the completely malactic foci, "gliös-mesenchymaler mobiler Abbau" was extremely severe, being especially remarkably evident in the regions of the lenticular nuclei and thalamus.

Capillary and venous hyperemia was very intensive regardless of the brain substance and the encephalic meninges, and such vessels frequently contained fibrin thrombi additionally; these circulatory disturbances were especially intensive in and just outside of the above-noted various necrotic foci. Fleck-form, pseudolaminar and demarcating loosened edematous foci (status cribrosus) being closely connected undoubtedly with the blood vessels were clearly recognized in and near the necrotic foci. The cerebral meninges of the telencephalic sulci

also exhibited edematous features.

In addition to the vascular process in the malactic lesions, swelling of cells of the walls of the capillaries and veins was somewhat intense in all areas of the grey matter and meninges of prosencephalon.

In the grey matter of the prosencephalon there was slight perivascular and tissue infiltration of eosinophil leucocytes; similar infiltration was also observed in the meninges of the telencephalic sulci.

In the section preparations to which was applied carbofuchsin-hematoxylin staining, fine reddish or dark reddish pigment substances which were of homogeneous or droplet-like character were occasionally found at the adventitial portion of the capillaries, in protoplasm of degenerated nerve cells and in microglia cell bodies, coinciding with the desolated areas of the telencephalon in general.

*Other organs and tissues* Scattering fatty degeneration of the liver. Fatty degeneration of the kidneys. Superficial necrosis of the gastric mucosa, being accompanied with erosion and demarcating hyperemia and hemorrhages; there were many hyalin and fibrin thrombi in the mucosa. Multiple focal initial lesions of "yellow fat disease" were very conspicuous, but appearance of yellowish pigment substances was not clearly observed, being accompanied with proliferation of mesenchymal cells in situ.

#### No. 18 Pr. 2744

**Clinical:** 26/XII '48, languishment; dysorexia; desiccation of the rostral planum; fond of taking lying posture at one corner of the pen; frequent convulsive seizures; T. 40.0°C. 27/XII, indications were as on the previous day; T. 38.2°C. 28/XII, indications were same as on the previous day; additionally astasia; died in the evening.

**Post-mortem:** Intense hyperemia of the brain. Pseudolaminar desolated foci with discoloration in the cerebral cortex (after fixation).

#### **Microscopical:**

*Central nervous system* Acute changes of nerve cells were conspicuous in all areas of the brain, especially in the prosencephalon.

In the grey matter of the prosencephalon, especially of most lobes of the telencephalon, pseudolaminar and U-form foci, in which the ground substances increased in eosin staining to various degrees, were very remarkable; some of them were connected with each other at the gyral tops (focal pallor). In the dorsal part of the telencephalon, generally U-form focal incomplete malacia occurred coinciding with those necrobiotic areas: the malactic areas were macroscopically evident on NISSL-stained preparations as definite deeply stained areas; in such areas severe "gliös-mesenchymaler mobiler Abbau" was obvious. These malactic-necrotic foci showed observable fall and loss of myelin sheaths, and there were a few remaining degenerated nerve cells, showing ischemic cell change, severe cell change and ghost appearance, etc., in and near the foci. Such similar necrotic lesions were also found in the claustrum region of the cerebral nuclei.

Glial reaction was hardly observed in any areas other than in and just outside of the malactic foci.

In the grey matter of the prosencephalon, especially of the cerebral pallium, perivascular

eosinophil cell infiltration into the capillaries and veins was very intense, developing conspicuously into thick cuffing; in and just outside of the above necrotic foci, being most intensive and frequently accompanied with intensive tissue infiltration of the cells. Eosinophil cell infiltration in the meninges was intensive in those which covered the telencephalon, especially localizing in those of the sulci. Furthermore, round cell perivascular infiltration consisting mainly of lymphocytes was somewhat intensely seen in and near the necrotic foci and in the meninges of the sulci which cover the foci.

Venous hyperemia was intensive in the prosencephalon, although it was observed on the whole brain, and it was most severe in and near the necrotic foci; that of the meninges was intense in the telencephalic sulci, particularly in the portions which cover the necrotic foci. In and near the necrotic foci tissue edema was observed as demarcating tissue loosening etc. while it did not draw attention in the other areas. Meninges of the prosencephalon were also edematous especially in the sulci.

Even in the grey matter of the prosencephalon other than the necrotic foci, swelling of endothelial cells of the capillaries and veins was somewhat conspicuous.

*Other organs and tissues* General congestion. Scattering degeneration of liver cells. Severe fatty degeneration of the kidneys. Initial metamorphosis of "yellow fat disease" was scatteringly observable in the mature fat tissues; nuclei of mesenchymal cells in situ were pale and swelled; in large fat drops of fat cells sometimes minute vacuoles containing faintly yellowish droplet-like pigment substances were found.

#### No. 19 457

**Clinical:** 29/V '50, good condition of nutrition; dysorexia and adipisia; walked with drooping head; T. about 39.5°C, P. about 170. Convulsive seizures occurred at intervals of 30 to 40 minutes: the animal had dog-sitting posture with the fore limbs outstretched, and the convulsions became gradually heavy, concurrently with spumy salivation from the opened mouth and the visible mucosae showed cyanosis, and finally respiratory movement came to almost a standstill and at the same time the convulsions ceased, and the respiratory movement soon recommenced; duration of this seizures was about one minute. 30/V, maximum temperature was 41.1°C; maximum celerity of pulse was 185. Intervals of the convulsive seizures were shortened to 1.2 to 1.5 minutes and the severity increased. 31/V, asthenia was severe; the seizures occurred almost unceasingly; astasia; T. 37.5°C., P. 200 and weak pulse; slaughtered on the verge of death.

**Post-mortem:** Intensive hyperemia of the brain and spinal cord. Dilatation of the right ventricle of the heart. General congestion. Cloudiness of the liver and kidneys. Pseudolaminar foci with discoloration in the cerebral cortex (after fixation).

#### **Microscopical:**

*Central nervous system* In all areas of the brain and spinal cord acute swelling of nerve cells was conspicuous, especially remarkable in the prosencephalon.

In the grey matter of the prosencephalon necrobiotic foci of various shapes were observed; in the telencephalic cortex there existed fleck-form, pseudolaminar and pseudolaminar-U-form foci in which the ground substances increased in eosin staining to various degrees and in which scattered ischemic nerve cells were evident; the hindmost foci were located around the sulci

(focal pallor). Particularly, in the U-form foci of the dorsal part of the telencephalon there were also many ischemic and many profoundly changing nerve cells; in such foci it was found that slight proliferation of the glial element was induced in parallel with that of vascular system; similar lesions existed in the thalamus region. Moreover, in the several necrobiotic foci the ground substances were stained basic being transformed into fine pulverization.

Venous hyperemia was intense, which was frequently accompanied with fibrin thromboses, particularly in the brain substance and meninges of the sulci of the prosencephalon, and above all it was conspicuous coinciding with the necrobiotic foci which exhibited relatively severe lesions. Almost all areas of the prosencephalon were edematous; in the telencephalic cortex especially in and near the above various lesions, perivascular, fleck-form and demarcated pseudolaminar edematous changes were exceedingly severe, resulting in local tissue loosening. Edema in the cerebral meninges was somewhat remarkable in the sulci of the telencephalon.

Existence of peri-capillary and -venous eosinophil cell infiltration was observed being confined within the grey matter of the prosencephalon, but its intensity was not very striking in general; such infiltration was above all conspicuous in the telencephalon, especially in the cortical areas around the sulci. Very slight tissue infiltration of eosinophil cells was recognized also being confined within the grey matter of the prosencephalon. Moreover, eosinophil cell infiltration in the cerebral meninges was also observed in the sulci of the telencephalon but it was not very intensive just as in the brain substance.

Even in the prosencephalon with the exception of the above lesions which showed glial and vascular proliferation, swelling of endothelial cells of the capillaries and veins was somewhat intensive. Moreover, in the cortex of the temporal lobe yellowish homogeneous pigment substances were occasionally found in the perivascular lymph spaces.

*Other organs and tissues* Fatty degeneration of the liver and kidneys. Features of initial metamorphosis of changes of "yellow fat disease" were scatteringly recognized in the mature fat tissues; nuclei of fat cells in situ were pale and swelled; no obvious yellowish pigment substances were detected.

No. 20 Pr. 3419

**Clinical:** See the particulars which were described in Case No. 17. A case which occurred simultaneously with Case No. 17. Main symptoms were of staggering and convulsions. 5/IX '53, slaughtered on the verge of death.

**Post-mortem:** Hyperemia of the meninges of the brain. Pseudolaminar desolated foci in the cerebral cortex. Fatty metamorphosis of the liver.

**Microscopical:**

*Central nervous system* Acute changes of nerve cells were very conspicuous in all areas of the brain.

In almost all areas of the grey matter of the prosencephalon, focal pallor or pallidness was clearly observed; in the telencephalic cortex, extending over each lobe, it was recognized in the form of pseudolaminar foci of various shapes localizing in the middle or throughout all the laminae, and in such foci ischemic and profound changes of nerve cells were, in some of the foci diffusely, clearly confirmed in various degrees in quality and quantity; the ground substances of the foci generally increased in eosin staining to various degrees. Coinciding

with these foci incompletely malactic processes developed frequently at several places, which generally took U-form around the sulci in the telencephalon; the ground substances were finely pulverized and loss of nerve cells was very severe; microglial reaction varied ranging from very mild to somewhat intensive being correlative with vascularization, and appearance of fat compound granular corpuscles was not yet very remarkable except that in areas around the blood vessels. The process of glio-mesenchymal reaction was observed in the regions of the formatio reticularis of the mesencephalon and olivary nuclei of the medulla oblongata, being located nearly symmetrically, also.

Capillary and venous hyperemia was very intense in every place including the meninges of the brain; it was especially conspicuous in the cerebrum, above all in and near the malactic foci; being frequently accompanied with fibrin thromboses. In and just outside of the necrobiotic and malactic foci of the cerebrum, there was prominent fleck-form, centering around the blood vessels, and demarcated pseudolaminar edematous tissue loosening (*status cribrosus*). Edematous feature also was observed as dilatations of the perivascular lymph spaces in the other parts of the brain. Cerebral meninges of the sulci of the telencephalon were also edematous, and in those portions a small number of mesenchymal gitter cells were found perivenously on the blood vessels being concerned with the processes of the brain substance.

Swelling and increase of cells of the blood vessel walls were remarkable in the prosencephalon in general.

Slight eosinophil cell infiltration was occasionally found as perivascular in type and as tissue emigration in the meninges of the sulci of the telencephalon and in the grey matter of the prosencephalon. Moreover, a mere few perivenously infiltrated lymphocytes were found in the white matter near the olivary nucleus, being accompanied with intermingling of a mere few eosinophil leucocytes.

In section preparations to which carbolfuchsin-hematoxylin stain was applied, generally coinciding with the desolated areas of the telencephalon, fine homogeneous, mostly droplet-like, reddish or darkly reddish pigment substances were found in low frequency in protoplasm of nerve cells which maintained relatively original shape and at adventitial situation of the small-sized veins.

*Other organs and tissues* Fatty degeneration of the liver and kidneys. Features of initial metamorphosis of "yellow fat disease" were occasionally found in the mature fat tissues; nuclei of fat cells in situ were pale and swelled.

**No. 21 Pr. 3572** (Fig. 19~26)

**Clinical:** 23/VIII '54, anorexia. 24/VIII, repeated epileptiform seizures from morning. 25/VIII, the seizures aggravated more and more, occurring at intervals of 5 minutes; astasia from about 7.00 p. m.; at about 10.00 p. m. rose again and frequently revealed seizures of convulsions. 26/VIII, lying posture; occasionally tremor of the face and legs; anesthesia; desiccation of the rostral planum; P. 120; slaughtered at 2.00 p. m.

**Post-mortem:** Intensive hyperemia of the cerebral meninges. Pseudolaminar desolated foci with discoloration in the cerebral cortex. Dilatation of both the ventricles of the heart.

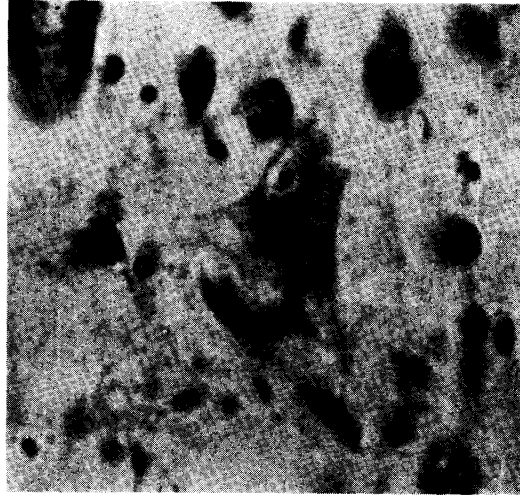
**Microscopical:**

*Central nervous system* Conspicuous acute changes of nerve cells were observed

extending over all areas of the brain.

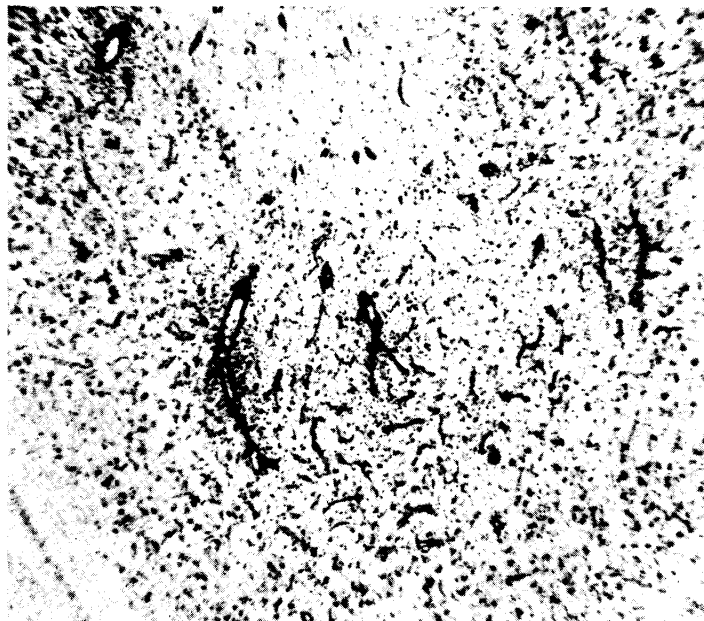
Almost all the grey matter of the prosencephalon presented necroses of scattering ischemic change of nerve cells (pallid process), being furnished with lesions in various stages which develop into malactic process. These processes were especially conspicuous in the telencephalic cortex, the majority of them being located in the middle laminae while some of them were extending over all laminae; these localized lesions consisted of the following: of which the ground substances increased in eosin staining being accompanied with nerve cells which had fallen into ischemic and profound cell changes, those showing U-form pseudolaminar loss of nerve cells in middle laminae around the sulci, and pseudolaminar or U-form ones exhibiting "gliös-mesenchymaler mobiler Abbau" as a further advanced change in the gyral legs, tops and valleys, etc. The claustrum of the cerebral nuclei was also involved by a malactic process which was not a very severe reaction. Although microglial

FIG. 19. No. 21. Pr. 3572



Lobus parietalis.  
Vacuolization of a nerve cell in  
the deep lamina of the cortex.  
Toluidin-blue  $\times 480$

FIG. 20. No. 21. Pr. 3572



Ventral part of the lobus occipitalis.  
"Gliös-mesenchymaler Abbau" in the cortex. Toluidin-blue  $\times 40$

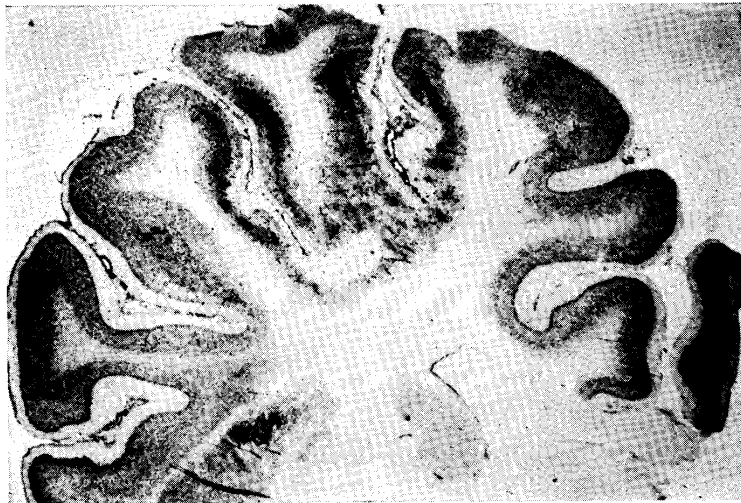
FIG. 21. No. 21. Pr. 3572



Lobus parietalis.

"Glös-mesenchymaler Abbau" in the cortex.  
Toluidin-blue  $\times 40$

FIG. 22. No. 21. Pr. 3572



Malactic desolated foci in the parietal lobe  
and putamen. Toluidin-blue  $\times 3.2$

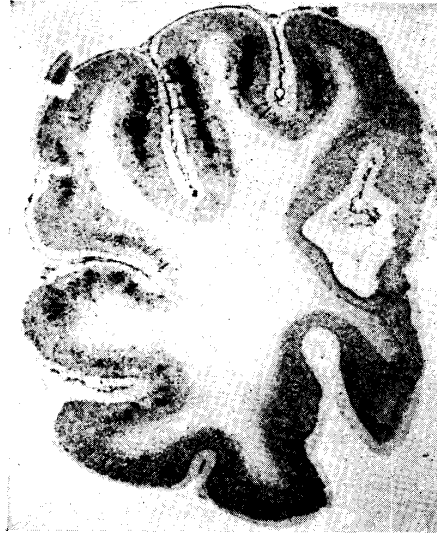proliferation was practically of no account in areas other than the malactic lesions, still, in several necrobiotic lesions slight proliferation of microglia cells was observed.

Eosinophil cell infiltration was somewhat prominent, being confined within the grey matter and meninges of the prosencephalon, sometimes being accompanied with perivascular cuffing which consisted of three to four cell layers; that in the grey matter of the telencephalon was most prominent, occurring on the veins of medium and smaller diameter in general, but rarely on the arteries of smaller diameter; tissue infiltration of eosinophils was extremely slight; rarely perivascular infiltration of eosinophils also was found in the white matter near the grey matter; such a infiltration in the meninges of the prosencephalon was diffuse, and the intensity somewhat increased in the sulci in general.

Even in the grey matter of the prosencephalon except the malactic areas, swelling and increase of cells of the walls of the capillary and venous blood vessels were for the most part somewhat intensive.

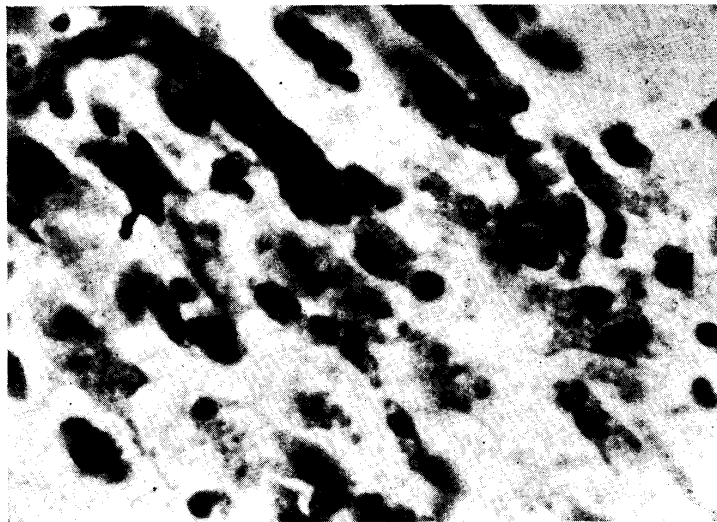
Everywhere in the brain, capillary and venous hyperemia was intense, especially in the prosencephalon including the meninges. Fibrin thrombi were infrequently recognized, and small

FIG. 23. No. 21. Pr. 3572



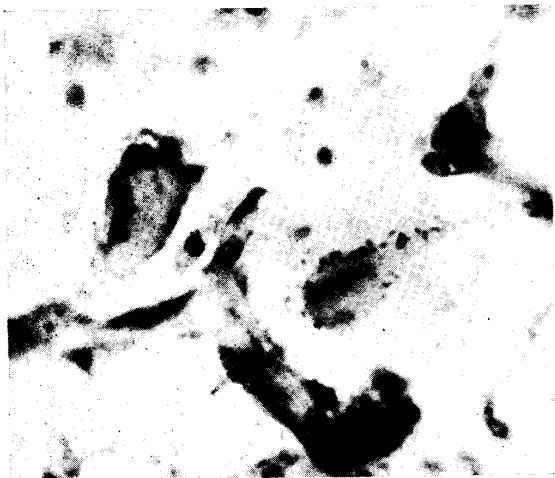
Lobus occipitalis.  
Pseudolaminar malactic-desolated  
lesions in the cortex.  
Toluidin-blue  $\times 3.2$

FIG. 24. No. 21. Pr. 3572



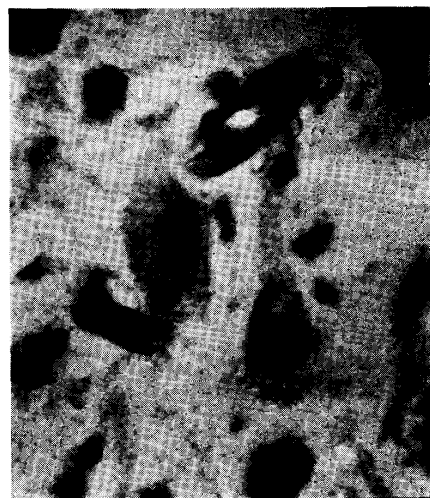
Lobus frontalis.  
Gitter cells in a malactic lesion of the cortex.  
Toluidin-blue  $\times 480$

FIG. 25. No. 21. Pr. 3572



Lenticular nucleus.  
Two nerve cells, showing ischemic changes and incrustation, from an incompletely malactic lesion.  
Toluidin-blue  $\times 480$

FIG. 26. No. 21. Pr. 3572



Lobus parietalis.  
Middle lamina of the cortex.  
Two nerve cells, showing profound changes, from an incompletely malactic area. Toluidin-blue  $\times 480$

diapedetic hemorrhages were sometimes observed. Within and about the above-noted various necrobiotic and necrotic lesions fleck-form and demarcated pseudolaminar tissue loosening was observed in high frequency.

In section preparations to which carbolfuchsin-hematoxylin stain was applied, microglia cells and degenerative nerve cells which had fine homogeneous, droplet-like, acid-fast pigment substances in their protoplasm were sometimes found in the above-noted various desolated areas. Lipoid substances, which could be stained with NISSL-stain, were negative to this stain.

*Other organs and tissues* Slight fatty degeneration of the liver and kidneys. Initial metamorphic features belonging to lesion of "yellow fat disease" were scatteringly recognized in the various mature fat tissues; indistinct yellowish pigment substances were detected; nuclei of fat cells in situ were pale and swelled.

No. 22 E. 711 (Fig. 27)

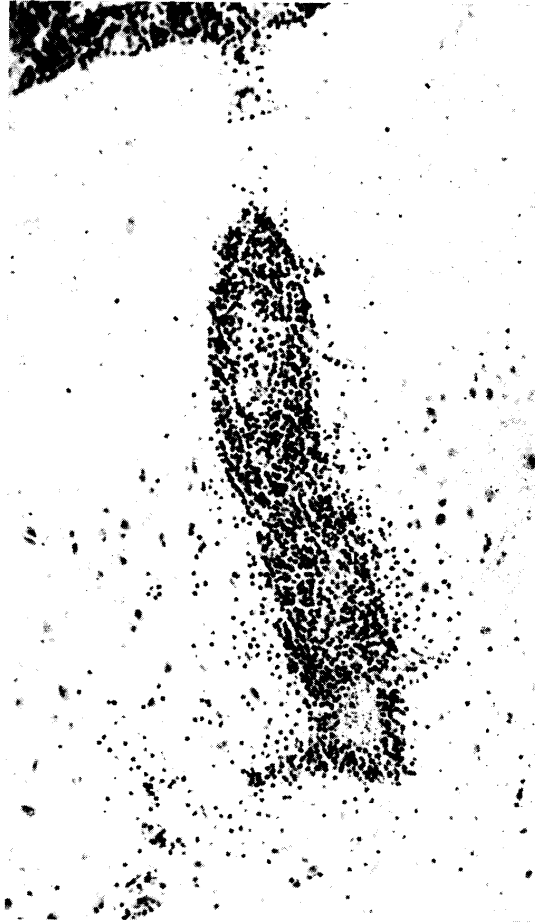**Clinical:** 22/XI '52, preventive vaccination against hog cholera. 23/XI, three animals out of nine litters were affected; dysorexia, languishment, occasional circular walking, convulsive seizures being accompanied with spumous salivation, etc. 24-26/XI, indications were about same as on the previous days. The animals languished gradually. This case out of the three animals, died on the morning of 27/XI (No. 22). One of the remaining animals died on 28/XI; the other got better from 27/XI and regained good condition on 29/XI.

**Post-mortem:** Pseudolaminar desolation with discoloration in the cerebral cortex (after fixation).

**Microscopical:**

*Central nervous system* Acute changes of nerve cells were remarkable in all areas of the brain.

FIG. 27. No. 22. E. 711



Lobus parietalis.

Intensive perivenous eosinophil leucocyte infiltration, being accompanied by tissue infiltration around the vein, in the cortex. Meningeal eosinophil infiltration at the sulcus is also intense. H.-E.  $\times 120$

In most of the convex part of the pallium desolated foci were found in the cerebral cortex, being located in the middle or extending over all the laminae; these foci represented various phases of changes ranging from existence of scattering ischemic nerve cells in the ground substances which increased in eosin staining (focal pallor) to fat compound granular corpuscle malacia, the latter taking the form of pseudolaminar foci located in the gyral legs, valleys and sometimes tops, and the malactic foci developed into U-form extending around the sulci in many cases; "mobiler gliös-mesenchymaler Abbau" was very remarkable in general, being especially severe in the parietal and occipital lobes; sometimes the cerebral meninges also participated in the process of clearance and removal. Several severe lesions also brought on loosening to the neighbouring white matter. Similar desolated lesions were also detected in the claustrum of the cerebral nuclei. Obvious proliferation of microglia cells was not often found in the areas other than the malactic foci.

Perivascular and tissue infiltrations of eosinophil cells were confined within the telencephalon where they were very prominent; pericapillary and perivenous infiltrations were overwhelmingly most numerous; on the veins of medium diameter thick cuffs, of more than ten layers of eosinophils, were present in high frequency; infiltrations in the cerebral meninges were also like those in the brain substance. Quantitative distribution of the infiltration of eosinophil leucocytes had no particular relation to the malactic process and was rather remarkable in the other portions around the sulci; the meningeal infiltration of cells of this kind generally was diffusely present and especially remarkable in the sulci. In the white matter, also, slight eosinophil perivascular cuffing was occasionally detected in the telencephalon.

Capillary and venous hyperemia was intense, and edematous changes were slight; they were observed only within and near the malactic areas.

Even in the grey matter excepting the malactic lesions, in the prosencephalon, swelling of endothelial cells of the blood vessels was rather intensive.

*Other organs and tissues* General congestion. Severe fatty degeneration of the liver and kidneys. No obvious metamorphosis of "yellow fat disease" was detected.

No. 23 E. 2200 (Fig. 28)

**Clinical:** From 30/IX '56, languishment, dysorexia, circular movement, lying posture, decrementum of vision, convulsive seizures, tachypnoea and spumy salivation, etc. Maximum temperature was 40.5°C. 4/X, died at 11.00 p. m.

**Post-mortem:** Cloudy swelling of the liver. Hyperemia of the brain. Pseudolaminar desolated foci with discoloration in the cerebral cortex.

**Microscopical:**

*Central nervous system* Acute changes of nerve cells were extremely prominent in all areas of the brain.

Extending over all areas of the telencephalic cortex there was a definite observation of pseudolaminar malactic and demyelinated lesions, showing very severe damage, located in the deep laminae in general; developed very marked process of "gliös-mesenchymaler mobiler Abbau" and dense accumulation of fat compound granular corpuscles, but there were a few remaining degenerated nerve cells, some of which were calcified, of ischemic and profound types. These severe processes of ruin of tissue involved the subcortical white matter in various degrees; degeneration and destruction of myelin sheaths (droplet-like, small lumpy and balloon-like, etc.) and various appearances of degeneration of axis-cylinders were easily notable; microglia cell reaction also intense and many compound granular corpuscles were present. In the cerebral nuclei multiple incompletely malactic foci existed, also. The grey matter of the prosencephalon except the malactic areas exhibited necrotic processes of scattering ischemic type being accompanied with the ground substances which increased in eosin staining to various degrees (pallidness).

Confined within the grey matter of the prosencephalon, perivascular eosinophil cell infiltration was notable; it was more remarkable in the telencephalon. The infiltrated cells were in the main located in the perivascular lymph spaces on the medium- and smaller-sized veins, but rarely on the small-sized arteries. In the cerebral meninges they were recognized in the sulci. Tissue infiltration of eosinophil cells was not very remarkable.

FIG. 28. No. 23. E. 2200



Dorsal part of the lobus occipitalis.  
Degeneration of nerve fibers in the subcortical  
white matter. SPIELMYER  $\times 480$

Intensive venous and capillary hyperemia was observed, and some of the hyperemic blood vessels contained a few fibrin thrombi; the hyperemia sometimes accompanied with small diapedetic hemorrhages. Intensive edematous changes were observed in the grey matter of the prosencephalon and in and near the malactic lesions, developing fleck-form and demarcated-pseudolaminar loosening of tissue (status cribrosus).

Without connection with the circumstance in the malactic lesions, intensive swelling and increase of endothelial cells of the blood vessels were observed in the prosencephalon. Moreover, accompanied with eosinophil cell infiltration, intensive lymphocytic round cell infiltration, which was sometimes very intensive, was observed perivascularly on the medium-sized veins in and near the malactic lesions, and in the meninges of the sulci which covered such lesions.

Section preparations to which carbol-fuchsin-hematoxylin stain was applied, from the telencephalon especially in the temporal part, demonstrated occasionally acid-fast, homogeneous, dark-reddish, fine pigment substances in protoplasm of degenerated nerve cells, at the adventitial region of the capillaries and in protoplasm of microglia cells near the blood vessels. Lipoid substances taken in cell body of compound granular corpuscles, which could be stained by other methods, showed negative appearance in this staining.

*Other organs and tissues* Severe fatty degeneration of the liver and kidneys. In the mature fat tissues lesions of initial metamorphosis of "yellow fat disease", although they were

scattering, were somewhat prominent; many of them had lost normal structure; mesenchymal cells in situ were hyperplastic; yellowish pigment substances were indistinct in general and acid-fast staining also showed negative.

No. 24 Pr. 3687 (Figs. 29~33)

**Clinical:** 29/VI '56, slow clockwise circular movement in the morning; lying posture, disappearance of lid reflex and cyanosis of visible mucosae, etc. in the evening. 1/VII, the symptoms got rather better from afternoon; walking became possible; slow clockwise circular walking; intensive cyanosis; taking of milk became possible with assistance. 4/VII, inability to rise when put in lying posture and again slow clockwise circular walking when helped to stand up; occasionally stood still pressing the nasal planum against the ground or one corner of the pen; intensive cyanosis; excessive exhaustion; no lid reflex; T. 36.4°C; slaughtered at 3.00 p. m.

**Post-mortem:** Intensive hyperemia of the brain and spinal cord. Pseudolaminar desolated foci with discoloration in the cerebral cortex.

**Microscopical:**


*Central nervous system* Acute changes of nerve cells were very conspicuous in all areas of the brain and spinal cord.

Almost all the grey matter of the prosencephalon developed various tissue desolations ranging from necrobiosis to necroses: in some areas the ground substances increased in eosin staining, being sometimes pulverized dust-like; in such areas there were ischemic and profound nerve cells and loss of nerve cells (focal pallor). Such lesions were mostly accompanied with glio-mesenchymal reaction of clearance and removal of various degrees; such circumstances were exceedingly severe in the dorsal part of the parietal and occipital lobes in particular; a large number of compound granular corpuscles were mobilized in those areas for the most part. In the cerebral cortex, these desolated lesions developed in the main centering around the middle laminae; many of them exhibited U-form pseudolaminar around the sulci; but there also were such lesions as extend over all the laminae of the cortex, those which were located at the top of the gyri and those which were formed by confluence of the lesions of both the top and leg of the gyri. In a majority of the desolated lesions fatty degeneration of nerve cells was remarkably recognized and nerve cells with slight incrustation were also found. Moreover, the malactic processes in the cerebral nuclei and thalamus, being more severe in the sinister hemispherium, indicated similar character to those of the cerebral cortex. Coinciding with the lesions, degeneration, destruction and loss of myelin sheaths were evident. Furthermore, in the cortical superficial lamina which covers the malactic areas, proliferation of macroglia cells, although it was slight, was clearly demonstrated.

Although there existed eosinophil cell infiltration in almost all areas of the grey matter of the prosencephalon, it was slight in degree in both perivascular, on the capillaries and veins, and tissue infiltrations. Meningeal infiltration of eosinophil cells was restricted within the meninges covering the prosencephalon, and it was observed as only slight in the sulci.

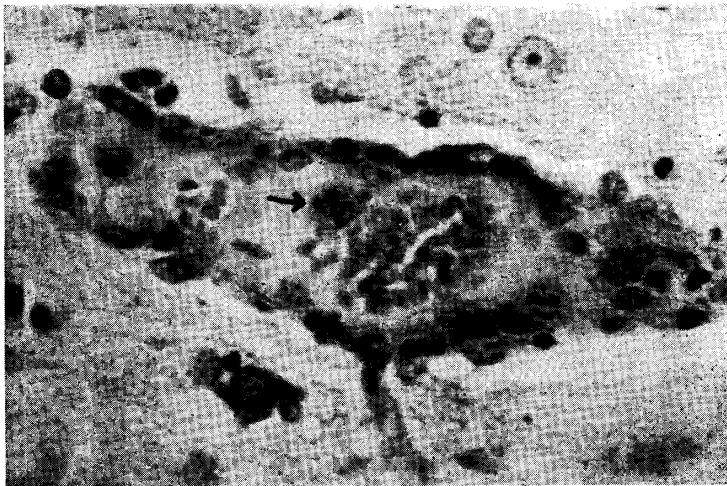
Swelling and increase of cells of the walls of the capillaries and veins were somewhat intensive even in all areas of the prosencephalon except the malactic areas. Proliferation of cells of the meninges was somewhat remarkable in the sulci which are concerned with the

FIG. 29. No. 24. Pr. 3687



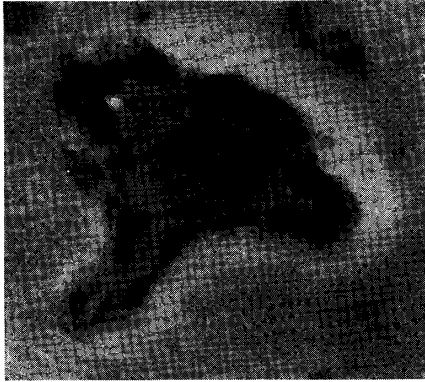
Lobus occipitalis. Middle lamina of the cortex.  
Nerve cells, showing profound changes,  
from a pseudolaminar desolated area.  
Toluidin-blue  $\times 480$

FIG. 30. No. 24. Pr. 3687



Lobus temporalis. Middle lamina of the cortex.  
A macrophage (arrow) laden with acid-fast pigment substances in  
the lumen of the vein of small diameter near a pseudolaminar,  
incompletely malactic lesion. Carbol-fuchsin-hematoxylin  $\times 480$

FIG. 31. No. 24. Pr. 3687



Lobus temporalis. Middle lamina of the cortex.

A small-sized vein of which the intima is, particularly evidently in the portion of arrow, lined with acid-fast pigment substances.

Carbolfuchsin-hematoxylin  
× 480

stances had no close connection with the severity of the lesions; it was difficult in general to look for such substances in nerve cells and in glial element and at the adventitia; floating of macrophages laden with such substances was seldom detected in the lumen of the veins; a feature such as the vascular intima was uniformly lined with substances was also found. In the sulci of the cerebellum similar substances were present in the intima of the veins, also. Moreover, lipid substances which could be stained with NISSL-stain and Sudan III-positive substances in nerve cells which showed fatty degeneration were not stained with this staining.

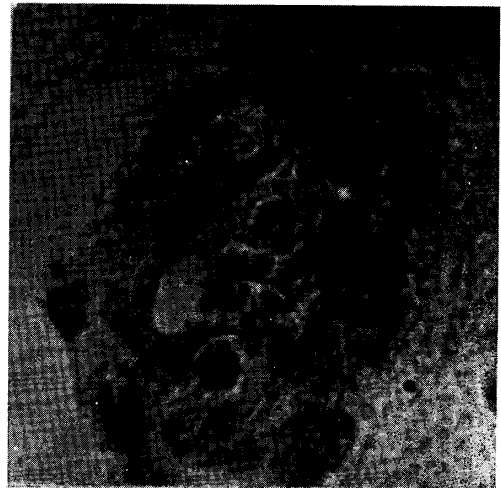*Other organs and tissues* Slight fatty degeneration of the kidneys. Outstanding metamorphosis of "yellow fat disease" was diffusely present in all the mature fat tissues; proper structure of the tissues fell severely into disorder, and everywhere many vacuoles consisting of large- and small-sized ones existed isolated and accumulated just like the yolk in the fowl ovary. A majority of the vacuoles contained homogeneous, yellowish, acid-fast pigment substances, but on the other hand

severely desolated areas; the proliferation was accompanied with slight lymphocytic round cell infiltration, a few eosinophil cells and many macrophages, etc.

Capillary and venous hyperemia was exceedingly intense in the grey and white matter of the prosencephalon, prosencephalic meninges and cerebellar meninges; it was frequently accompanied with fibrin thromboses and sometimes small hemorrhages. Edema in the brain substance and meninges was not very intensive, and perivascular edema was found only in the prosencephalon.

By means of carbolfuchsin-hematoxylin stain, definite, reddish or dark-reddish, homogeneous pigment substances could be relatively frequently detected in the intima of the capillaries, veins of medium and smaller diameter and small-sized arteries in all areas of the prosencephalic grey matter, and in the meningeal cells and intima of the veins of the prosencephalic meninges especially in the sulci; it seemed that the frequency of detection of such sub-

FIG. 32. No. 24. Pr. 3687

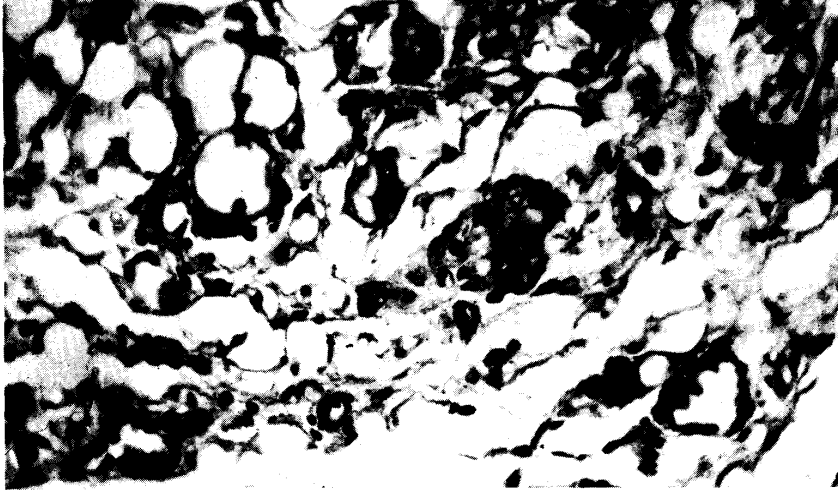


Lenticular nucleus.

A small-sized artery, of which the intima (arrow) has acid-fast pigment substances, from an area which showed a slight glio-mesenchymal clearance process.

Carbolfuchsin-hematoxylin × 480

FIG. 33. No. 24. Pr. 3687



Intermuscular mature fat tissue in a certain skeletal muscle.  
Changes of "yellow fat disease". Mesenchymal cell proliferation.  
Yellowish pigment substances are phanerous. H.-E.  $\times 240$

indistinct existence of the substances was found in some vacuoles. Some of the substances existed in coincidence with fat cells, but the majority were included in mesenchymal cells; proliferation of mesenchymal cells being accompanied with appearance of macrophages and of giant cells developed into many island-like cell accumulations here and there; some of the pigment substances were condensed, so that they exhibited dark-yellowish tone. Initial metamorphic features, which were characterized by lining the membrane of large fat drop of fat cells with minute vacuoles, were not seldom detected; moreover, rings of acid-fast pigment substances which lined membrane of large fat drop of fat cells were found.

No. 25 E. 2434 (Figs. 34~38)

**Clinical:** 23/VI '57, languishment and dysorexia in the morning. 24/VI, languishment; cyanosis of visible mucosae; disappearance of eye-lid reflex; weak pulse; palpitation; disappearance of peristalsis; continuous vertical motion of the head; spumy ptyalismus; defecation of blackish-yellowish dejecta; P. 180, T. 39.5°C, R. 5,880,000, W. 23,500. 25~27/VI, indications were the same as on the previous days on the whole. 28/VI, slaughtered. This case and Case No. 6 were attacked, the one following on the heels of the other, in the same piggery.

**Post-mortem:** Intensive hyperemia of the meninges and parenchyma of the brain, and pseudolaminar desolated foci with discoloration in the cerebral cortex. Fatty degeneration of the liver.

**Microscopical:**

*Central nervous system* Acute changes of nerve cells were extremely conspicuous in all areas of the brain and spinal cord, especially in the prosencephalon.

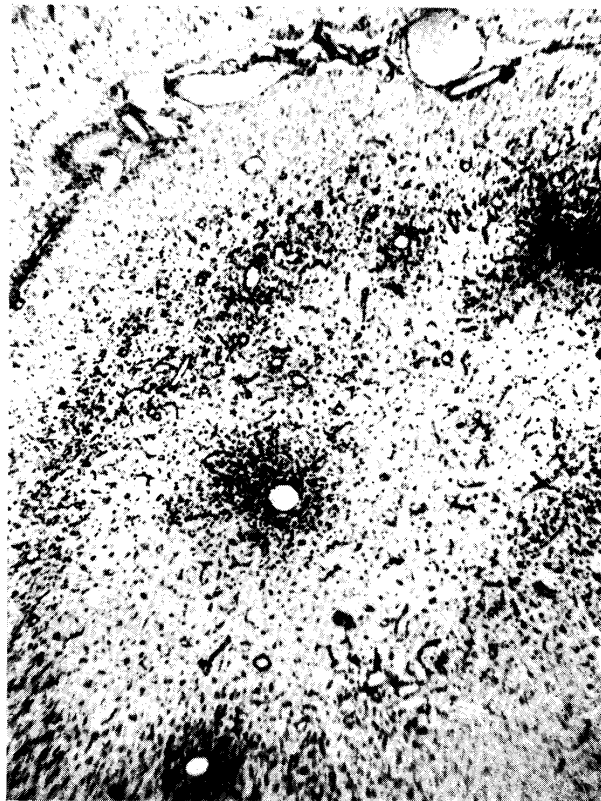
In almost all the pallium of the cerebrum, pseudolaminar or U-form-pseudolaminar, around the sulci, desolated lesions were located in the second to fourth laminae or extending over

whole laminae; these lesions occasionally connected mutually at the gyral tops; fleck-form desolation of tissue which developed centering around the blood vessels was also observed.

These lesions were roughly divided into the following four types from the qualitative standpoint. 1) Such lesions that the ground substances increased in eosin staining, and in them degenerative nerve cells of ischemic or profound types were included in various degrees quantitatively (focal pallor). 2) A great number of degenerative nerve cells showing ischemic change and ghost appearance, etc. were present; intermingled also those which show degeneration resembling calcification. In addition, the ground substances were stained basic; they were pulverized and dusty. In circumferences of and within the lesions, slight glio-mesenchymal reaction developed centering around the blood vessels. 3) Lesions exhibited complete loss of nerve cells; accompanied with somewhat marked process of glio-mesenchymal reaction centering around the blood vessels; feeble proliferation of rod cells was recognizable in all the lesions of this kind. 4) Those developing into fat compound granular corpuscle malacia; accompanied with process of conspicuous glio-mesenchymal clearance and removal.

It goes without saying that there were various transitional features among these types of lesions.


FIG. 34. No. 25. E. 2434



Lobus frontalis.

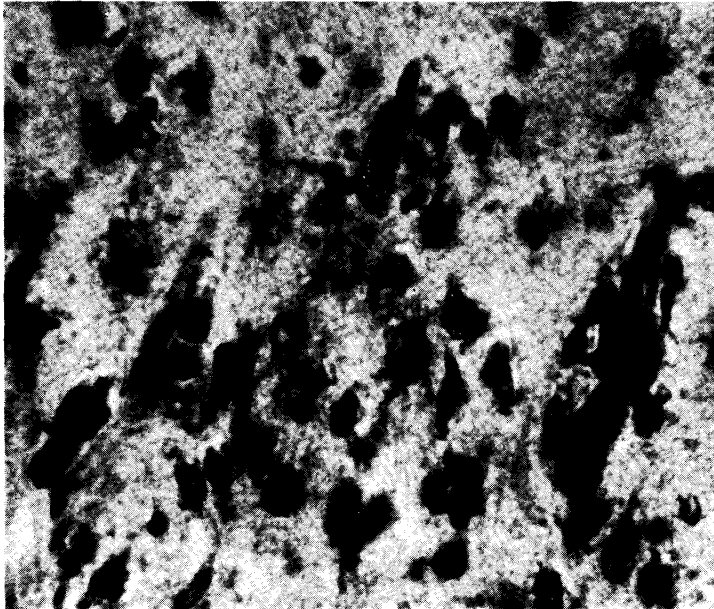
“Gliös-mesenchymaler Abbau” in the cortex; accompanied by macroglial proliferation. Toluidin-blue  $\times 70$

FIG. 35. No. 25. E. 2434



Lobus parietalis.  
"Glös-mesenchymaler Abbau" in the cortex,  
being accompanied by macroglial proliferation  
in the superficial lamina of the cortex.  
Toluidin-blue  $\times 40$

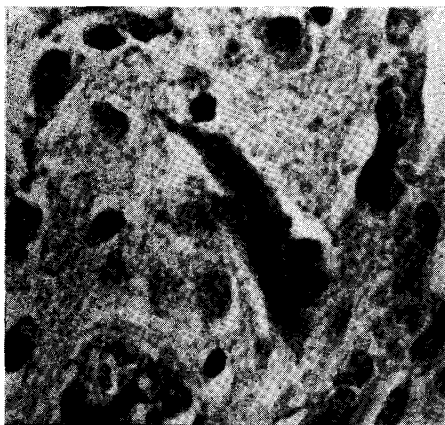
FIG. 36. No. 25. E. 2434



Lobus temporalis.  
Macroglial proliferation in the superficial lamina  
of the cortex. Toluidin-blue  $\times 480$

In addition, macroglial proliferation, which was accompanied with mitosis, was distinctly visible in the circumferences of the malactic lesions, although it was slight in general; the

FIG. 37. No. 25. E. 2434



Lobus parietalis. Middle lamina of the cortex.

A degenerative nerve cell, showing deposition of acid-fast pigment substances, just outside of a malactic lesion.

Carbolfuchsin-hematoxylin  $\times 480$

intense, being accompanied with fibrin thromboses in most areas of the brain and occasionally small diapedetic hemorrhages. These circulatory disturbances in the meninges were more

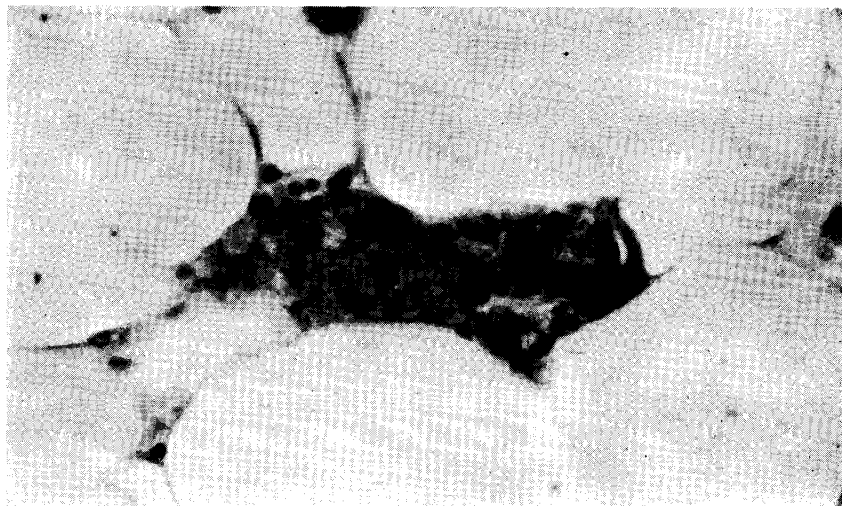
intensity was generally in correspondence with the severity of the malactic changes. The proliferation was more intensive in the superficial lamina of the cerebral cortex in general, and in that occasion simultaneously with it there was microglial activation with formation of rod cells for the most part; yet the proliferation was also observed on the medullary side and even within the lesions, although it was slight.

In the cerebral cortex various degenerative features and loss of myelin sheaths were diffusely remarkable; e.g., droplet-like, small lumpy, irregularly spherular, beaded and balloon-form degeneration, etc. The white matter beneath the severer cortical lesions also loosened, and was accompanied with degeneration of myelin sheaths and microglial proliferation.

Desolation similar to the above-noted lesions also occurred in the cerebral nuclei and diencephalon.

Capillary and venous hyperemia was very

FIG. 38. No. 25. E. 2434



Gastro-hepatic omentum.

Changes of "yellow fat disease" in the mature fat tissue. Deposition of acid-fast pigment substances of various chemical states is evident.

Carbolfuchsin-hematoxylin  $\times 480$

intense in the cerebrum than elsewhere. Edematous changes were observed in all areas of the brain, especially being remarkably observed within and near the severe lesions in the prosencephalon, as fleck-form and demarcated tissue loosening; in the sulci of the telencephalon edema was intense, also.

Swelling and increase of cells of the walls of the capillaries and veins were diffusely observed being limited only in the grey matter of the prosencephalon; it goes without saying that the processes in and near the above-noted desolated lesions are naturally another question on this occasion. In conjunction with the above-noted glio-mesenchymal reactive proliferation, meningeal cell proliferation in the sulci of the telencephalon was very intensive and held many macrophages, being frequently accompanied with perivascular round cell infiltration.

On the veins of medium and smaller diameter in the telencephalic cortex and in the sulci of the cerebral meninges, slight eosinophil cell infiltration was sometimes recognized; tissue emigration of eosinophils was occasionally found in only the telencephalic cortex.

Section preparations to which carbolfuchsin-hematoxylin stain was applied revealed acid-fast, reddish to dark-reddish, homogeneous, droplet-like pigment substances in protoplasm of variously degenerative nerve cells. Similar pigments also were often found at the adventitia of the capillaries and veins, and microglia cells laden with the pigments were occasionally found around the blood vessels.

*Other organs and tissues* Centro-lobular fatty degeneration of the liver. Slight fatty degeneration of the kidneys. Tissue metamorphosis of "yellow fat disease" was remarkable in all the mature fat tissues; a majority of the yellowish pigment substances were taken by mesenchymal cells, but there were many contrary cases; the pigment substances showed various yellowish appearances ranging from light to deep tones; coinciding with such appearances the grade of acid-fastness was varied and some of the light-yellowish pigments exhibited hardly any acid-fastness.

No. 26 Pr. 2900 (Fig. 39)

**Clinical:** 4/V '50, preventive vaccination against hog cholera. 7/V, staggering in walking from noon; outstanding clonic spasms; dysorexia; tachypnoea; T. 38.5°C. 8~9/V, the symptoms got worse again. 12/V, conspicuous clonic spasms; standing still with drooping head. 13/V, indications were the same as on the previous day in the forenoon; lying posture and inability to rise in the afternoon; slaughtered at about 3.00 p.m. Simultaneous occurrence with Case No. 16.

The store farm in which this case occurred accomodated 90 store pigs. Amongst them the mature pigs only were preventively vaccinated against hog cholera on 4/V. In three to four days following 6/V 14 pigs which were vaccinated only showed mutually similar nervous symptoms; 3 pigs died and 8 were slaughtered within a half-day to 6 days after onset. The other 3 pigs showed recovery.

**Post-mortem:** Pseudolaminar desolated foci with discoloration in the cerebral cortex (after fixation). Slight dilatation of the right ventricle of the heart.

**Microscopical:**

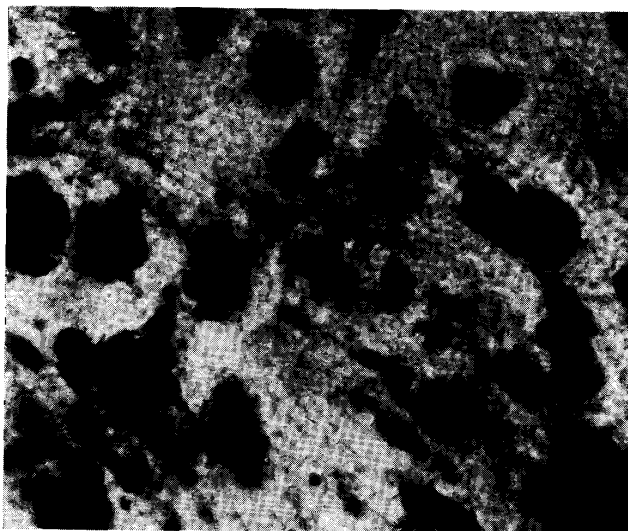
*Central nervous system* Acute changes of nerve cells were extremely striking in all areas of the brain and spinal cord.

In many of the gyri of the cerebral pallium slight macroglial proliferation extending over

almost all the laminae of the cortex was observed, which showed U-form extensions around the sulci; the proliferation formed relatively active small "Gliarosen" being concurrently accompanied with slight microglial proliferation consisting of diffuse formation of rod cells and formation of loose glial nodules. In some of the gyri, pseudolaminar loss of nerve cells in narrow extent had occurred in the middle laminae, being accompanied with slight microglial proliferation. Furthermore, in the other gyri, there were U-form lesions around the sulci in which the ground substances of the middle laminae increased in eosin staining, being accompanied with slight process of glio-mesenchymal clearance and removal; appearance of fat compound granular corpuscles was yet poor, but formation of rod cells with wide nuclei and microglia cells which carried a little lipid substances were relatively remarkable; a small number of nerve cells of ischemic and ghost appearance remained; myelin sheaths exhibited degeneration.

A part of the cerebellar cortex presented slight atrophy of the granular layer.

FIG. 39. No. 26. Pr. 2900



Lobus occipitalis.

"Gliarosen" in the middle lamina  
of the cortex. Thionine  $\times 480$

The above desolated lesions suffered intensive eosinophil cell infiltration; the infiltration was mainly perivascular on the medium-sized veins; in the surrounding areas of the blood vessels emigration of eosinophils into tissue was observed, also. The infiltration also was marked in the sulci which are concerned with the lesions in the cerebral cortex.

With the exception of the events in the lesions of glio-mesenchymal reaction, swelling of endothelial cells of the blood vessels was practically of no account. In the sulci which are concerned the severe cortical lesions, slight meningeal infiltration of round cells resembling lymphocytes was observed in the main perivenously.

Hyperemia was slight in general. Edema also was generally slight, but it was recognized as not serious.

*Other organs and tissues* Fatty degeneration of the kidneys. No obvious metamorphosis of "yellow fat disease" was found in the mature fat tissues.

No. 27 460

**Clinical:** 5 /VI '50, inappetence; occasional convulsive seizures being accompanied with dyspnoea; clockwise or anticlockwise walking about. 6/VI, T. 38.6°C, P. 120; good condition of nutrition; hyperemia of the visible mucosae; staggering of the hinder part of the body; going ahead and bumping against one corner of the pen; walking about the same as on the previous day; dysorexia and adipisia; decrementum of visual acuity; convulsive seizures at intervals of one hour, which were accompanied with respiratory standstill and spumy salivation; the seizures continued for about 1.5 minutes and then the animal rose and walked. 7/VI, indications were the same as on the previous day. 8/VI, intervals of the seizures became 30 minutes; posterior paralysis; lying posture; astasia; blindness; cyanosis of the ears; T. about 38.0°C, P. 170. 9/VI, indications were the same as on the previous day. 10/VI, continuation of the convulsive seizures; excessive general exhaustion. 11/VI, slaughtered.

**Post-mortem:** General congestion. Hyperemia of the brain and spinal cord. Pseudolaminar desolated foci with discoloration in the cerebral cortex (after fixation). Cloudiness of the liver and heart. Gastric erosions in the fundus region.

**Microscopical:**

*Central nervous system* Acute changes of nerve cells were conspicuous in all areas of the brain and spinal cord.

Pseudolaminar desolated foci extending over almost all laminae existed in almost all the cortex of the telencephalon; in the gyral tops the ground substances of the middle laminae increased in eosin staining to various degrees, and in them nerve cells suffering from ischemic and profound changes were scatteringly present (focal pallor); in the gyral legs and valleys many U-form foci developed malactic processes in various phases, and the frequency of encountering with such features was higher in the posterior part of the pallium; moreover, in the majority of the incompletely malactic lesions which were accompanied with feeble reaction the ground substances were stained basic and were pulverized, and there were a few nerve cells of ischemic and profound types and relatively many nerve cells showing a degeneration resembling calcification. Furthermore, incompletely malactic lesions in which feeble reaction was recognized were also present in the diencephalon.

Capillary and venous hyperemia was intense, occasionally being accompanied with small hemorrhages and fibrin thrombosis. In the prosencephalon, especially in the cortex and meninges of the telencephalon intensive edemata were observed; they were conspicuous in and near the desolated lesions in particular (perivascular, fleck-form and demarcated-pseudolaminar edemata).

Eosinophil cell infiltration was scarcely found. Swelling of cells of the blood vessel walls was generally slight with the exception of that in and near the malactic lesions. In the meninges of sulci concerned with the malactic desolated lesions of the telencephalon, there was sometimes intensive cell proliferation, which contained many macrophages.

*Other organs and tissues* Fatty degeneration of the liver. Fresh erosions of the gastric mucosa in the fundus region. No obvious metamorphosis of "yellow fat disease" was detected in the mature fat tissues.

No. 28 E. 2549 (Figs. 40~42)

**Clinical:** 28/X '57, four pigs were preventively vaccinated against hog cholera out of five which were three months of age. This case was one of the vaccinated pigs, and developed anorexia at about 5.00 p. m. of the same day. 29/X~1/XI, indication was the same as on the previous days. 2/XI, anorexia; adipsia; intermittent pangs; T. 38.9°C. 3~6/XI, the symptoms grew worse. 7/XI, died at 5.00 a. m.

**Post-mortem:** General congestion. Cloudy swelling of the liver and kidneys. Intensive dilatation of the ventricles of the heart. Intensive hyperemia of the brain and outstanding pseudolaminar foci with hyperemia in the cerebral cortex. Submeningeal petechiae. Circumscribed necrotic gastritis.

**Microscopical:**

*Central nervous system* Acute changes of nerve cells were very remarkable in all areas of the brain and spinal cord; vacuolization was relatively conspicuous.

In almost all the gyri of the telencephalon there were prominent pseudolaminar pallid lesions of which the majority manifested U-form pictures around the sulci, which developed centering around the middle laminae for the most part (focal pallor); the ground substances increased in eosin staining and there existed many degenerative nerve cells of ischemic and profound types. Many of the lesions at the gyral tops connected mutually with those in the gyral legs. Degeneration and loss of myelin sheaths were remarkable coinciding with the desolated lesions, mainly taking droplet-like shapes, changing into small lumps and swelling like small balloons, etc. All the lesions were accompanied with slight progressive metamorphosis of microglia cells; lipoid substance-laden microglia cells were frequently recognized in the areas where swelling and increase of cells of the blood vessel walls were somewhat observable.

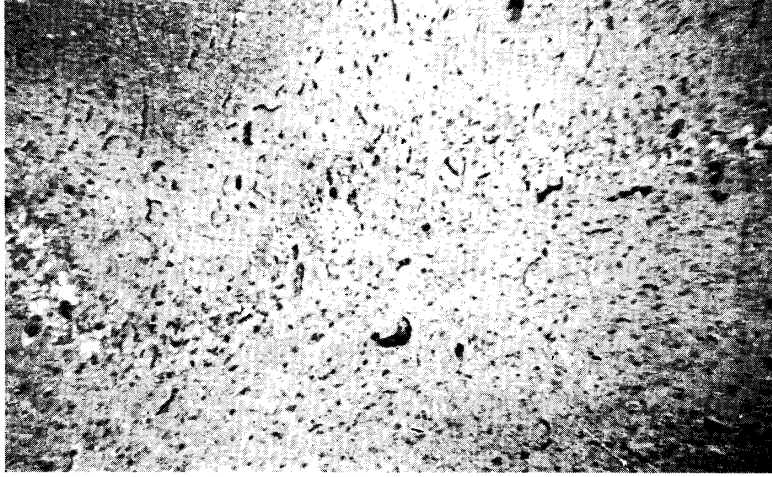Swelling of endothelial cells of the capillaries and veins was relatively intense in almost all the areas of the grey matter of the telencephalon. On rare occasions homogeneous yellowish pigment substances were found at the adventitia of the capillaries. In the meninges of the sulci which cover the cortical desolated lesions such as developed feeble "gliöser Abbau", slight swelling and increase of cells of the blood vessel walls were observable on rare occasions.

Capillary and venous hyperemia was exceedingly intense including meningeal one, especially remarkable in the desolated lesions of the prosencephalon; being frequently accompanied with fibrin thromboses and marked petechiae. Furthermore, edema was intense; it was evidently observed as small fleck-form or demarcated-pseudolaminar tissue loosening (status cribrosus) in and near the desolated lesions in the cerebral cortex in addition to edematous dilatation of the perivascular lymph spaces; the cribriform lesions were especially outstanding in the rhinencephalic gyri.

Eosinophil cell infiltration could not be recognized at all.

In section preparations to which carbolfuchsin-hematoxylin stain was applied, various degenerated nerve cells containing minute, homogeneous, sometimes droplet-like, pigment substances which were stained reddish to dark-reddish were detected frequently in the telencephalic cortex coinciding generally with the desolated areas; the blood capillaries of which the adventitia had a very small quantity of the pigments were also found on rare occasions in the same areas.


FIG. 40. No. 28. E. 2549



Rhinencephalic cortex.

Pseudolaminar cribriform lesion; there are many ischemic changed nerve cells in and near the lesion. Capillary hyperemia. H.-E.  $\times 40$

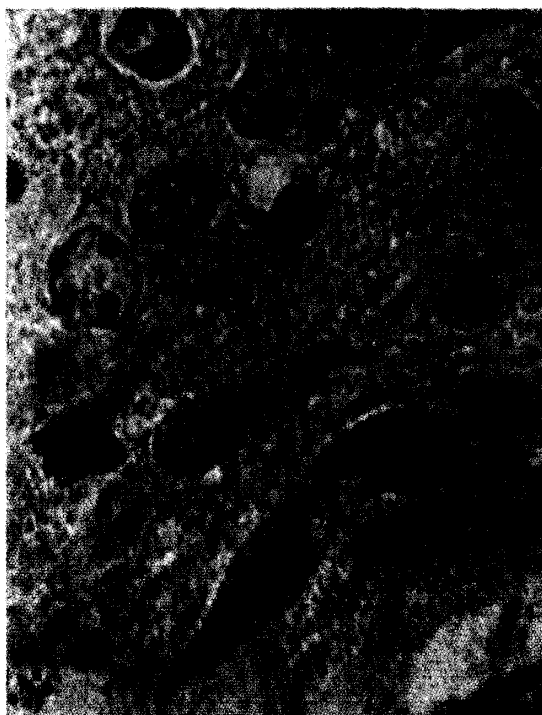
FIG. 41. No. 28. E. 2549



Lobus parietalis.

Pseudolaminar desolation of nerve fibres in the gyral top of the cortex. SPIELMYER  $\times 40$

FIG. 42. No. 28. E. 2549



Rhinencephalic cortex.

Ischemic change and acute swelling  
of nerve cells. H.-E.  $\times 850$ .

*Other organs and tissues* Slight centro-lobular necrobioses, being accompanied with generally diffuse slight degeneration, in the liver. The gastric mucosa circumscriptly got into necroses to deep layer; a majority of the lesions suffered infiltration of neutrophil leucocytes; there were many thrombi of large and small size in the submucosa, and some of them were attended with organizing processes. Initial metamorphic pictures of "yellow fat disease" were scatteringly recognized in the mature fat tissues; nuclei of fat cells in situ swelled; distinct yellowish pigment substances were found on rare occasions.

No. 29 E. 2580

**Clinical:** The animal showed nervous symptoms, but the details were not reported to the writer. Died case.

**Post-mortem:** Metastrongyliasis of the lungs. Pseudolaminar desolated foci with discoloration in the cerebral cortex (after fixation).

**Microscopical:**

*Central nervous system* Acute changes of nerve cells were marked in all areas of the brain.

U-form pseudolaminar desolated lesions, which were located around the sulci and mainly in the middle laminae, were present in the telencephalic cortex in the convex part; they manifested various necrotic processes ranging from slight loss of nerve cells as well as slight

microglial reaction to severe loss of nerve cells as well as malactic process which was accompanied with relatively abundant fat compound granular corpuscles. There were also slightly desolated pseudolaminar lesions located at the gyral tops.

Perivascular eosinophil cell infiltration was not very intense in general, and it was observed on the veins of medium and smaller diameter in the telencephalic cortex of the cerebral convex; however, in the areas around the sulci thick cuffs consisting of 5~6 layers of eosinophil leucocytes were found occasionally; tissue infiltration of the cells was also very slight. Limited to the telencephalic sulci for the most part, slight meningeal infiltration of eosinophils was observed, also.

Hyperemia was not very intense. On rare occasions small parenchymatous hemorrhages were found in the prosencephalon.

Swelling and increase of cells of the blood vessel walls were slight in general; even in the malactic lesions mesenchymal reaction was rather feeble-looking in general.

*Other organs and tissues* Fatty degeneration of the liver. Initial metamorphotic features were scatteringly observed; existence of yellowish pigment substances was not evident.

No. 30 E. 594

**Clinical:** Details were not certain. Died case.

**Post-mortem:** Increase of pericardiac liquor. Congestive edema of the lungs. Intensive hyperemia of the encephalic meninges. Pseudolaminar desolated foci with discoloration in the cerebral cortex (after fixation).

**Microscopical:**

*Central nervous system* Acute changes of nerve cells were conspicuous in all areas of the brain.

Extending over almost all areas of the cerebral cortex, pseudolaminar desolated lesions involving almost all the laminae were remarkably observable, and those around the sulci, exhibiting U-form aspect, were the most severe. They showed various changes ranging from such an one as that the ground substances, in which nerve cells of profound and ischemic types were scattered, increased in eosin staining (focal pallor) to malactic change which developed centering around the middle laminae. In the malactic lesions, in addition, even in those which were accompanied with the appearance of many fat compound granular corpuscles, mesenchymal reactive proliferation as yet appeared to be feeble in general.

Capillary and venous hyperemia was intensive; many of the veins contained fibrin thrombi; sometimes accompanied with small diapedetic hemorrhages. In the telencephalic cortex especially in and near the malactic areas, there was edematous dilatation of the perivascular lymph spaces. The meninges of the sulci which are concerned with the severe lesions in the telencephalic cortex also were edematous.

Swelling of endothelial cells of the capillaries and small veins was generally slight, but in and near the malactic lesions relatively manifest swelling and increase of cells of the blood vessel walls were observed. The meninges of the sulci, concerned with the malactic lesions of the telencephalic cortex, manifested slight cell proliferation.

Perivascular eosinophil cell infiltration was, on very rare occasions, found confined within the telencephalon, i. e., the cortical areas around the sulci and meninges of such sulci, and

very slight; tissue infiltration of eosinophil cells was also detected in the same areas of the telencephalon on very rare occasions.

*Other organs and tissues* Centro-lobular necrobioses and diffuse fatty degeneration in the liver. Slight fatty degeneration of the kidneys. No obvious initial metamorphic pictures of "yellow fat disease" were found in the mature fat tissues.

No. 31 E. 2573 (Fig. 43)

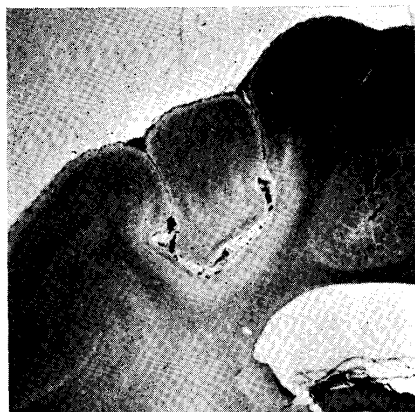**Clinical:** Certain nervous symptoms upon which a diagnosis of so-called "eosinophilic encephalitis" was given to this case occurred on 23/VI '57. The symptoms, however, got gradually better and the animal recovered one week later. 25/XII, slaughtered.

**Post-mortem:** Evident U-form pseudolaminar foci in the cortex of the parietal lobe of the cerebral hemispheres, slightly displayed a small degree of transparency, accompanied with scattering of pale-yellowish, minute, crystalline substances. The foci in the right hemisphere were smaller than those in the left.

**Microscopical:**

*Central nervous system* In the cerebral cortex in the convex part, striated and pseudolaminar-U-form lesions, being located in the middle laminae for the most part, were clearly visible around almost all the sulci.

FIG. 43. No. 31. E. 2573



Lobus parietalis.

Focal gliomenchymal scarring  
in the cortex. H.-E.  $\times 3.2$

The lesions which were visible to the naked eye, extending over almost all the laminae and showing a few nerve cells left in the deep laminae, manifested loose glial scarring through relatively active proliferation of fibrous macroglia cells; concurrently, relatively feeble mesenchymal proliferation which developed centering around the blood vessels was recognized; relatively many compound granular corpuscles, carrying lipid substances which were insoluble in alcohol and acid-fast granular pigment substances, and much basic tissue debris were embraced in the meshes of the reticular structures around the blood vessels which were formed by perivascularly proliferated fine collagenous fibres. On rare occasions there were a few compound granular corpuscles in the perivascular lymph spaces in the white matter

beneath the cortical lesions. The meninges of the sulci which cover the cortical lesions exhibited hyperemia and were edematous.

Small lesions developing mildly, being invisible to the naked eye, manifested substitution of fibrous macroglia cells for loss of neurons; a mere few lipid substance-laden cells were found; vascular proliferation was very slight or hardly recognizable.

Coinciding with each of the lesions, myelin sheaths were slightly injured or there was occasionally incomplete loss of myelin sheaths. A majority of tangential fibers being over the lesions were maintained without showing loss.

On very rare occasions, in the severe lesions eosinophil leucocytes were detected as

perivascular and tissue infiltrations. In certain areas of the cerebral cortex having no connection with the lesions, eosinophils were also found on very rare occasions.

*Other organs and tissues* Initial metamorphic features of "yellow fat disease" were recognized scatteringly in the mature fat tissues; existence of yellowish pigment substances was faintly evident in minute vacuoles; occasionally there existed condensed, homogeneous, dark-yellowish pigment substances, which demonstrated acid-fastness in section preparations to which carbolfuchsin-hematoxylin stain was applied.

## DISCUSSION

### A. Lesions of the Central Nervous System

#### 1. Macroscopical findings

Hyperemia of the encephalic meninges and brain substance could be very definitely observed through almost all the cases examined in this investigation, although there were variations of the degree among the respective cases. In many of them edematous features also were distinctly recognized. Small meningeal hemorrhages also were observed on rare occasions (Case No. 28).

What must be enumerated as the most characteristic macroscopical change in this disease is the appearance of focal pseudolaminar desolation being in the main located in the cerebral cortex. The desolated lesions showed U-form around the sulci in general, appreciable yellowish tone in many of them, additional reddish tone where hyperemia was intensive and edematous features were existent. Such lesions were more clearly recognizable on the sections of the brain which was fixed, which were circumscribed from the surrounding brain tissue and, in addition, discolored. Description on macroscopical states of this kind in description of cases has been purposively simplified.

From a localization point of view, the lesions of which the severity and extension of desolation were most intense, therefore, those which caught one's eye quickly, existed in the cerebral cortex around each of the "Bogenfurchen", principally the dorsal branches of the suprasylvian fissures and marginal fissures. It appeared that occurrence of such macroscopically observable lesions was more frequent in the cases with a course of above 1.5 days.

All of the desolated lesions which were macroscopically visible were seen to be accompanied with the features of "gliös-mesenchymaler Abbau" of various degrees under the microscope, but even in certain cases which had hardly such microscopical process, where pallid process was very severe, by close observation, circumscribed pseudolaminar lesions might be macroscopically detected in the cerebral cortex (Case Nos. 8 & 28).

In the recovered case (Case No. 31), pale-yellowish, crystalline substances were observed in the desolated lesions of the cerebral cortex.

Moreover, it was usually difficult to find out macroscopically observable foci in parts of the brain other than the telencephalon.

## 2. Microscopical changes

With regard to characteristic features of the microscopical changes, one must enumerate focal necroses which were located principally in the cerebral cortex and perivascular and tissue infiltrations of eosinophil leucocytes which were mainly confined within the telencephalon. At the same time the degenerative features of nerve cells (acute cell change in the main), which were prominent in all areas of the brain and spinal cord, must be considered a finding of importance.

### a) Focal necrosis

The various necrotic processes were, in the majority of cases, recognized in only the grey matter of the prosencephalon; they showed most severe change in the convex part of the telencephalon; on that occasion, they developed centering around the middle laminae of the cortex in general and usually appeared in pseudolaminar manner.

The necrotic process could be divided into two types, viz., those which showed focal pallor or pallidness ("Erbleichung" SPIELMYER's) and those which had already come to show glio-mesenchymal reaction. It is natural that the former occurred concurrently in such cases as gave rise to the latter.

1) Focal pallor As regards such cases as showed only pallidness, all of those of which the course was less than one day (Case Nos. 1~10) were in that condition and Case No. 15 which had not yet developed recognizable change might be also included in this category. Furthermore, it is conceivable that Case No. 28 also should be included in this item and discussed.

The pallid foci most frequently occurred in the cerebral cortex in the convex part; they developed centering around the middle laminae in the portions of the gyral legs and valleys, and appeared fleck-form, pseudolaminar and pseudolaminar-U-form. From point of view of localization, those which were concerned with the respective "Bogenfurchen" were likely to manifest most severe change. These foci, of which the ground substances increased in eosin staining to various degrees, were easily recognized, as they were distinctly separated from the circumferential tissue for the most part. The states of ischemic necrosis of nerve cells which were distinctly evident in these foci did not necessarily show any invariable aspect, that is to say, there were qualitatively and quantitatively differences in the changes dependent upon the individual cases and upon the localizations even in the same case. That is, there were various features of transitional process among changes ranging from very slight ischemic destruction of nerve cells which occurred scatteringly to loss of nerve cells. Furthermore, some of the cases

mingled many profoundly degenerated nerve cells in some of their foci, and some other cases possessed nerve cells which showed marked incrustation.

Coinciding with the foci degeneration and ruin of myelin sheaths were distinctly recognized and sometimes tangential fibres were also involved, although they were not uniform according to qualitative and quantitative differences of the necrotic processes.

Microglial reaction in the pallid foci was very feeble in appearance for the most part. However, the foci in a few cases were accompanied with slight but obvious progressive metamorphoses of microglia cells in parallel with swelling and increase of cells of the walls of the blood vessels, but fat compound granular corpuscles which came to plump were hardly found; such an event could be regarded as an initial feature of glio-mesenchymal reactive process belonging to the following item.

Moreover, the lesions of scattered ischemic necroses were detected in the cerebral nuclei and diencephalon of several amongst the cases which were included in this item.

2) Glio-mesenchymal reactive process What the author has most frequently encountered at the time of autopsy of naturally occurring cases suffered from the disease have usually been cases which came to show glio-mesenchymal reactive process. Of the present cases, eighteen (Case Nos. 11~30 except Case Nos. 15 & 28) probably belonged to this category.

It was indubitable that the development of the glio-mesenchymal reactive processes had occurred in the areas coinciding with the necrobiotic lesions of the foregoing item and succeeded to the necrobiotic changes. Such a circumstance has been distinct from the fact that almost all the 18 cases concurrently had necrobiotic foci, and that in those individual cases there were transitional features of various stages between the necrobiotic changes and the development of glio-mesenchymal clearance and removal. And, as for the features developing into the completely malactic processes, there existed many transitions among the changes ranging from slight proliferation of rod cells which acted in unison with the scattering ischemic necrosis, through small fleck-form clearance reaction which developed centering around the blood vessels, to severe glio-mesenchymal reaction extending over all the laminae of the cerebral cortex, which already evidenced macroscopically cell-dense deeply stained foci on NISSL-stained preparations; such a state was naturally applicable to respective one case. The lesions which showed the character of incomplete malacia were rather many in the cases with relatively short course, while many of the lesions and cases which showed complete compound granular corpuscle malacia were observed in those of rather longer course in general.

The more the desolating process was conspicuously severe, the more extensive was the incidence of the focal pallor or pallidness. And, almost all the cases in this item possessed such necrotic changes in almost all the grey matter of the prosencephalon with appreciable differences dependent upon the individual cases. The appearances of the necrobiotic and malactic lesions naturally were most prominent coinciding generally with those mentioned under the foregoing item, but generally speaking from the point of view of localization, almost all areas of the telencephalic cortex and further cerebral grey matter might make an offer localities for the lesions. That is, there were encountered not only the U-form lesions around the sulci which developed centering around the middle laminae of the cortex, but also lesions in the gyral tops and pseudolaminar lesions which extensively occurred in parallel with the cortical surfaces; moreover they existed in the red nuclei of the mesencephalon (Case No. 13) and the formatio reticularis (Case No. 20) in addition to the cerebral nuclei and thalamus (Case Nos. 13, 17, 18, 21, 22, 23, 24, & 25), in addition, in the olivary nuclei of the rhombencephalon (Case No. 20). The malactic lesions other than those in the cerebral cortex were usually small and in a habit of exhibiting somewhat indistinct demarcations and obscure shapes.

Coinciding with the necrotic areas, obvious degeneration, ruin and loss of myelin sheaths, developing pseudolaminarly in the cerebral cortex for the most part, were observed, although there were variations in the degree of the processes dependent upon the different cases. Where the desolation was grossly severe, the subcortical white matter also was often involved revealing tissue loosening and observable degeneration of myelin sheaths.

In addition, in Case Nos. 24, 25 & 26 slight proliferation of macroglia cells which could be regarded as that which has to do with the necrotic lesions was evident in the cerebral cortex. It is a reasonable surmise that the delay of progress of disease induced such a proliferation. In Case No. 26, the development of malacia was yet very feeble and the majority of the lesions developed only slight reactive proliferation of the glial element; as to the macroglial proliferation which was observed in the same case, the author would like to regard it as a reparative-reactive process which followed after focal pallor or pallid changes. Accordingly, this case may arouse an appreciable interest in having relation to the clinical particulars.

3) Healing process The case which showed restoration of the clinical symptoms was only one, Case No. 31, in this study. Judging from the localization of the lesions and eosinophil cell infiltration in the cerebrum, etc., it might be reasonably concluded that the changes belonged to healing processes of lesions of so-called "eosinophilic encephalitis." All of the large and small striated and

pseudolaminar lesions exhibiting loss of nerve cells, which were located in the cerebral cortex in the convex part, were replaced by fibrous macroglia cells in different degrees, and additionally networks of fine collagenous fibers were formed around the proliferated blood vessels. The author is of opinion that, taking into consideration existence of the eosinophil cell infiltration, it is unquestionable that all of the lesions indicate terminal scarring features which followed after certain desolations such as those mentioned above.

4) Short summary Without need of additional detailed explanations here, it is considerable that it is clear at a glance that the necrobiotic and necrotic lesions mentioned above may be caused by local functional disturbances of the blood circulation in addition to being conditioned by the blood vessels from the histological point of view.

Comparatively speaking in regard to the character and substance between this disease and encephalomalacia in cases of other species of domestic animals, the lesions in the present disease compare in general with those of encephalomalacia in horses and sheep<sup>48)</sup>, and foxes<sup>46)</sup>. In addition, changes of encephalomalacia in chicks<sup>21,38,42)</sup> and cattle and sheep<sup>14)</sup> are fully similar to those in the present disease in quality. Moreover, in this connection, spontaneous avitaminosis of sheep<sup>20)</sup> should be called to mind.

Furthermore, the author would like to call attention to the circumstances which have been discussed, for many years in human medicine, in connection with cerebral diseases developing from infectious disease, intoxication and experimental spastic disease as well as genuine epilepsy, symptomatic epilepsy, eclampsia, etc., and those are lacking on organic change upon which an adequate explanation can be given to the genesis of focal necrosis; also to local pseudolaminar desolation being due to circulatory disturbances in the cerebral cortex<sup>30,41)</sup>. The reason is that there are many resemblances between the changes in these diseases and those in the nervous system of the cases of the present disease. The granular atrophy of the cerebellum in Case No. 26 also may be regarded as lesion which was caused by circulatory disturbances in like manner.

As to focal necrosis and encephalomalacia of this kind, in Europe and America at the present time, it seems that they have been also observed in the brain of a certain swine disease being called under a name similar to that of the present disease. Judging from localization of lesions, etc., both the foreign and present lesions may be essentially resemble, if not identical, to one another; in particular, the author would like to call attention to the reports published by DONE et al.<sup>8,9)</sup>, HJÄRRE and OBEL, RAC et al. and SMITH.

b) Microglial reaction

It goes without saying that microglia cell reaction giving rise to discussion

under this item is that other than the secondary reaction of microglia cells in the lesions of the various desolations already mentioned in the above item a.

That which is to be given attention in the whole histological picture is that microglia cell reaction was generally very feeble through all the present cases. In other words, only loose nodular foci or diffuse proliferation of rod cells were barely detected in a mere few case although many preparations were subjected to microscopical observation; however, even as for such features, the author has considered that indistinct difference may exist between those and very mild reactive features belonging to a reparative process.

c) Eosinophil cell infiltration

The perivascular and tissue infiltration of eosinophil leucocytes could be observed in the grey matter of the prosencephalon of all cases except Case Nos. 27 and 28. The blood vessels which showed the infiltration were of medium and smaller diameter for the most part, being mostly limited to the venous and capillary ones. However, the infiltration was seldom detected on the small arteries. The intensity of the infiltration varied dependent upon the individual cases and showed many variations dependent upon the localities even in the same case; in at least about half the cases it could be grossly marked; there were different qualitative relations of the infiltration ranging from that which formed thick cellular cuffs to that in which a mere few infiltrated cells were recognized in the perivascular lymph spaces. However, generally speaking, there was no denying the fact that the cases with short course of less than one day had a tendency to show feeble intensity in quantity and extent of the eosinophil cell infiltration. The infiltration into perivascular tissue revealed varieties in degree depending upon the cases or the localizations.

Most frequently the cerebral cortex presented the place for infiltration, but in most cases the cerebral nuclei concurrently suffered, although it was slightly, from the perivascular and tissue infiltration. In addition to this, in eleven cases of which a majority showed remarkably intensive infiltration of eosinophils into the telencephalon the similar slight infiltration was also detected in the grey matter of the diencephalon; a mere few of the infiltrated eosinophils were also found in the molecular layer of the cerebellum. Furthermore, on rare occasions, a few of the small blood vessels to which a mere few eosinophils infiltrated perivascularly were detected in the subcortical white matter (Case Nos. 5, 15, 21 & 22) and the white matter near the olivary nuclei (Case No. 20).

As to the difference in degree depending upon the localization of eosinophil cell infiltration, a majority of the cases exhibited rather more intensive infiltration in the areas coinciding generally with the various desolated lesions than with other places, but it was sure that there were also some cases in which the

telencephalic grey matter was diffusely infiltrated by such cells.

The eosinophil cell infiltration in the encephalic meninges, which was in the main observed as a perivenous one, ordinarily was nearly restricted within the meninges covering the telencephalon especially in the sulci being concerned with the cortical desolated processes of various degrees, and the intensity of infiltration was parallel with that in the brain substance in general.

In the first place, it is a well-known fact that cellular infiltration, as mesenchymal reaction which has observed in the already known encephalitides of domestic animals, plays a part of importance in the histological features of encephalitic lesions. And on such an occasion, eosinophil leucocytes are nearly out of the problem as an infiltrated cell element. However, in the swine brains of the present cases, eosinophil leucocytes were generally playing a significant role of importance in the histological pictures, as distinctly indicated also in the figures.

Under these circumstances, such eosinophil cell infiltration as may be regarded as a kind of mesenchymal reaction gives rise to discussion as to what significance it has. On this problem the author, after reflection, would like to advocate the following opinion. That is, the infiltration should be regarded as a simple reactive phase of the body toward a certain sort of abnormal or toxic metabolic substances, judging from the facts that extending over all areas of the brain and spinal cord, conspicuous degeneration of nerve cells which was regarded as acute cell changes was confirmed, that changes in the various organs and tissues other than the central nervous system, especially metamorphosis in the mature fat tissues belonging to changes of "yellow fat disease", was noticeable, that deposition of acid-fast pigment substances was detected in the brain and that eosinophil leucocytes were limited to the veins and capillaries for the most part, etc. As for these particulars, much more discussion might be presented under each item, especially under histo-pathogenesis, mentioned below.

Furthermore, as to the two cases in which eosinophil cell infiltration could not be recognized (Nos. 27 & 28) and variety in number depending upon the individual cases, the author would like to account for them as something that originated in the mutual relation between quality and quantity of the metabolic substances and reactive capacity of the body.

In the certain swine disease being called under a name similar to that of the present disease from Europe and America, eosinophil cell infiltration into the brain has been enumerated as characteristic picture<sup>1,2,8,9,11,13,15,18,25,27,35</sup>. However, putting aside whether or not the two swine diseases are identical, it appears that explanation of the infiltrated eosinophil leucocytes by the foreign investigators has been vague or general.

## d) Degeneration of nerve cells

The degeneration of nerve cells of the kind which will be discussed in this item consists mainly of that which was regarded as belonging to acute cell changes. Ordinarily, it was diffusely observed in the brain and spinal cord, but it is of course true that there were appreciable differences in degree dependent upon the individual cases; generally speaking, the intensity was conspicuous in the prosencephalon. Generally, such cases as had progressed over 1.5 days presented a high degree of both intensity and extent of the degeneration. There were a considerable number of cases where the degeneration was simultaneously accompanied by vacuolization of protoplasm and ghost appearance of nerve cells. It was a very ordinary incidence that both the incompletely malactic and pallid lesions also had the same degenerated nerve cells showing acute changes in their interiors in like manner to that in the other areas of the brain and spinal cord.

Considering such circumstances, the author believe it a reasonable probability that the pathological processes occurring in the central nervous system of the present disease may have their origin in this kind of degeneration of nerve cells.

At any rate, the author would like to regard the diffusely extended degenerative process of nerve cells of this kind as "encephalopathia toxica."

## e) Mesenchymal reactive process with the exception of that in malactic lesion

Mainly swelling of endothelial cells of the capillaries and vessels was noticed in the grey matter of the prosencephalon, particularly in the telencephalon, throughout all but a mere few cases, although variety in the degree existed depending upon the individual cases. In the cases which showed only pallidness the changes of this kind in endothelial cells were somewhat more feeble than those of the other sorts.

The author is of opinion that the changes of this kind should be, with careful allowance for the process of eosinophil cell infiltration and further deposition of acid-fast pigment substances, regarded as a reactive process for the various tissue disturbances or certain kind of abnormal metabolic substances. Furthermore, various mesenchymal reactions which occurred mainly in portions of the sulci of the telencephalon, excepting reactions which directly took part in the malactic process, may be included in the same category.

In the fifteen cases perivascular infiltration, mainly on the veins and capillaries, of round cells resembling lymphocytes or plasma cells was observed in the telencephalon; it occurred generally in the desolated foci, in their circumferences and in the meninges of the sulci which cover the desolated foci in the cerebral cortex. Such infiltration frequently conspicuously notable in the cases which showed the glio-mesenchymal reactive process; on the contrary the cases

which had only pallidness (five cases) presented feeble infiltration in general.

The author is of opinion that such round cell infiltration which acted in unison with the glio-mesenchymal reactive process should be manifestly regarded as a reactive-symptomatic inflammatory process judging from the aspect. As regards the occurrences of feeble round cell infiltration, which were observed in the cases having only pallidness, all of them could be considered to be probably connected with the lesions judging from considerations of localization; accordingly, the author would like to regard the infiltration as a reactive process just as stated above.

f) Circulatory disturbances

Throughout all of the cases, capillary and venous hyperemia generally was conspicuously observed in all areas of the brain and spinal cord including the encephalic meninges; in a majority of the cases, it was particularly intensive in the telencephalon because there was probably relation to localization of the lesions.

Frequently the blood vessels which showed hyperemia, especially in the parenchyma and meninges of the telencephalon, contained venous fibrin thrombi and exhibited also small diapedetic hemorrhages.

The edematous features which occurred frequently in the prosencephalon especially telencephalic cortex had to do with the lesions for the most part; viz., above all, in the interiors and circumferences of the lesions such features were to be evidently observed as fleck-form, centering around the blood vessels, or demarcated-pseudolaminar ones; further observable ones which were decidedly regarded as status cribrosus were encountered frequently. Upon this, an opinion that such edematous changes may be followed by all of the processes of desolation of the brain tissue is not applicable to the present cases, to say the least; considering the fact that remarkable pseudolaminar pallid lesions also actually existed frequently without being accompanied with any significant edematous features, it is probable that such edematous changes were nothing but a secondary phenomenon ascribable to the thromboses as well as the congestion. However, it is naturally impossible for the author to deny that the extensive tissue edemata in the brain may bring on secondary tissue disturbances in some ways and may have an effect upon manifestation of clinical symptoms to some degrees.

g) Deposition of acid-fast pigment substances (Table 3)

In the central nervous system of the present cases, deposition of acid-fast pigment substances, which was confirmed in nine out of cases examined, may be enumerated as one of the histological pictures which drew attention. Mostly such substances occurred coinciding with the desolated lesions of the cerebral cortex, but in some cases their appearance was not necessarily connected with

the lesions and also they were detected in the cerebellum (Case No. 24). At any rate, frequency of the appearance of the pigment substances which was observed in the individual cases was generally exceedingly low.

The pigment substances, the existence of which was uncertain in section preparations stained with hematoxylin-eosin staining, were insoluble in alcohol. Therefore, section preparations to which alcohol-treatment has been previously applied, when stained with ZIEHL-NEESEN'S or VERHOEFF'S carbolfuchsin-hematoxylin, revealed reddish or dark-reddish substances; Sudan III staining was feebly positive. In addition the substances were homogeneous and were in the habit of taking droplet-like shape; they were on no account recognized as certain granule substances which exhibit a hard impression nor as lipofuscin; as they were usually very minute and occurred in low frequency as stated above, it was generally not easy to detect them under microscope.

TABLE 3. *Appearance of Acid-Fast Pigment Substances in the Central Nervous System*

CASE NO.	DEPOSITION OF PIGMENT SUBSTANCES	
1	—	•
4	—	•
5	—	•
6	—	•
8	—	•
9	—	•
10	•	+
14	—	•
17	•	+
20	•	+
21	•	+
23	•	+
24	•	+
25	•	+
28	•	+
31	•	+
Total	7	9

N. B. —: negative, +: positive

The localities which showed occurrence of the pigment substances mainly were in protoplasm of various degenerative nerve cells, and on such occasions the substances existed densely for the most part. On rare occasions, minute

quantity of the substances was contained in the cell body of active microglia cells. There were the capillaries and medium- and smaller-sized veins of which the adventitia had the pigment substances in almost all the positive cases. On certain occasions, the substances were also found at the intima of the capillaries and small-sized veins, and in one certain case the intima which was lined with the substances was evident; on very rare occasions a minute quantity of the substances was located at the intima of the small-sized arteries. Seldom, there were macrophages laden with the pigments in the lumen of the veins.

The state of phanerosis of the pigment substances apparently exhibited a high positive rate in the cases progressed over two days in general.

Such a fact can offer an interest problem in having to do with the state of occurrence of microscopically phanerous yellowish pigment substances on the occasion of metamorphoses belonging to change of "yellow fat disease" which were detected in the mature fat tissues of the body (mentioned below). For the acid-fast yellowish pigment substances, which took small spherical or droplet-like shape, were grossly quite analogous to those in the central nervous system.

The author thinks nobody may hold objection to the idea that the pigment substances may be a metabolic substance or a product of decomposition of neurons or the nerve tissues; in addition it is possible that the pigments are to be regarded as a product due to abnormal metabolism of fat substances of some certain kind. Furthermore, it may be within the bounds of possibility that the substances are likely carried to the blood stream by some certain intermedator, e. g. microglia cells etc. and that the probably occurs upon any disturbances of the blood vessels themselves (v. histo-pathogenesis).

Moreover, as to acid-fast pigment substances which have been reported up to this time in the central nervous system, the author would like to direct attention to the myoclonus-body<sup>19,36)</sup> and ceroid (acid-fast pigment)<sup>23,43)</sup> from the viewpoint of quality; the latter has been considered in having relation to E-avitaminosis. As regards whether or not such pigment substances resemble or are identical to those discussed in this report, the decision should naturally dependent upon further close histochemical investigation.

## B. Changes in the Other Organs and Tissues

### 1. Metamorphosis belonging to changes of "yellow fat disease" in the mature fat tissues

Such metamorphoses of the fat tissues were confirmed in all the present cases except six in which no obvious changes were detected and one upon which examination was not carried out. These processes were naturally observed only under microscope; they generally showed slight severity throughout a majority

of the cases; so they were regarded as initial metamorphoses.

As for the microscopical changes, as the outline was described above in description of cases (particularly see Nos. 1, 2, 4, 13, 18, 23, 24, 25, 28 & 31), the author would like to omit them here. Nos. 13, 23, 24 & 25 in which yellowish pigment substances were evidently phanorous exhibited changes which were just identical with those of "yellow fat disease" in various species of animals; such animals are of cats<sup>5,6</sup>), including one cat case once experienced by the author himself, minks<sup>10,16,24</sup>), including which have been frequently experienced by the author himself, foxes and ferrets<sup>10</sup>) and horses<sup>7</sup>), in addition to swine<sup>12,26</sup>), including swine cases which have been occasionally experienced by the author himself. Several other cases, which included five cases (Nos. 2, 4, 18, 28 & 31) presenting faintly phanorous yellowish pigment substances, indicated initial metamorphosis belonging to changes of "yellow fat disease."

The yellowish pigment substances exhibited homogeneous, droplet-like or small spherical aspect and on no account showed any angular or hard condition. Occasionally condensed, the substances had a dark tone. As the pigments were insoluble in alcohol, alcohol-treated section preparations to which carbolfuchsin-hematoxylin staining was applied indicated acid-fastness and reddish or dark-reddish tone; in Sudan III staining the pigments took on yellowish red tone. However, it goes without saying that there were various transitional features in staining of the pigments; in this connection mention will be made below. The mention has already been made above, with respect to the fact that the pigment substances were grossly quite analogous with those detected in the central nervous system.

It is believed that no one will have objection to regarding the present metamorphoses of the fat tissues belonging to "yellow fat disease" including the other investigator's cases as, from morphological standpoints, those which were caused by metabolic disturbance of fat substances of some certain kind. The yellowish pigment substances indicated various degrees in acid-fastness in stained section preparations subjected to concerning tests; this fact may be dependent upon chemical states they have. In addition, some of the pigment substances showed faintly but decidedly yellowish in the section preparations stained with hematoxylin-eosin, while they exhibited no significant reaction under carbolfuchsin-hematoxylin staining; such a circumstance has occurred frequently even in cases of the cat, mink and swine, which have been experienced by the author in addition to the present cases. In other words, it seems necessarily that the pigment substances, due to abnormal metabolism of fat substances of some certain kind, come to turn into reddish or dark-reddish tone in acid-fast staining because of chemically metamorphic states characterizing them. If, from such a point of

view, an attention is given to the minute vacuoles lining the membrane of large fat drop of fat cells, regarded as a feature of initial metamorphosis of "yellow fat disease," it is easily surmised that those vacuoles probably contained only, morphologically speaking, no phanerous pigment substances because of their chemical states. Furthermore, the author would like to apply such a consideration to the state of the appearance of the acid-fast pigment substances in the central nervous system.

In this connection, as regards causal genesis of "yellow fat disease," at the present time it appears that many investigators have been coming to an agreement on the point that occurrence of this condition may be extraordinarily due to excessive taking of unsaturated fatty acids as well as vitamin E deficiency.

## 2. Other changes

In the majority of the cases there existed general congestion, congestive edema of the lungs and cardiac weakness, and also cloudiness, fatty degeneration, necrobiosis, etc. in the parenchymatous organs consisting of the liver, kidneys, etc., although the changes were generally not very severe.

In a few cases (Nos. 17, 27 & 28) focal necroses and loss of the gastric mucosa were observed; many fibrin and hyaline thrombi were found in the mucosa and submucosa (Nos. 17 & 28). The author interested from the histopathogenetical viewpoint in such processes in point of resemblance between them and the findings of gastric erosion in horses affected with Japanese encephalitis<sup>45)</sup> as reported by the author and co-workers. In that sense, the fact that in the stomach of Case No. 8 multiple fibrin thromboses were observed without being accompanied with any significant damage give rise to discussion as to what significance they may have.

## C. Clinical particulars

In the first place, reviewing through the incidence of this disease depending upon ages, one notices in the present cases that those under five months of age were overwhelmingly many in number and that about half the number consisted of those in a short time after weaning. There was one rare case of four years of age (No. 26). Occasionally, simultaneous occurrence in one and the same piggery was noted.

The occurrence of this disease does not seem to be influenced by the seasons. However, there seem to be appreciably more in spring.

The principal clinical symptoms in this disease were languishment, adipsia, anorexia, dysorexia, tachypnoea, palpitation, standing still, drooping of the head, staggering, posterior asthenia, dog-sitting posture, inability in standing, lying

posture, spumy salivation, disappearance of reflex function, decrementum of vision, blindness, etc. in addition to outstanding cerebral symptoms, viz. convulsions, epileptiform seizures, circular movement, walking about, vertical motion of the head, etc. Furthermore, some of the cases indicated mental depression and some others mental excitement and bumping against objects after going ahead.

Seven out of sixteen cases for which the temperature was taken had over 40°C, 3 cases of which showed slight to moderate (?) fever up to 41.5°C.

Blood examination was conducted in only two cases (Nos. 13 & 25), both of which showed leucocytosis.

Four cases (Nos. 16, 22, 26 & 28) were apprehended in having relation to preventive vaccination against hog cholera. As to this problem, the author is able merely to surmise that such treatment might appreciably have some parts in the occurrence of this disease in the provocative sense.

The clinical symptoms mentioned above seem to be fully similar, if not identical, to those of a certain swine disease reported from Europe and America under a similar name to that of the present disease.

#### D. Histo-pathogenesis

The author has, above, made the mention of patho-morphological processes starting from the description of cases, giving several considerations to them; various transitional features of the lesions could generally be observed through the description of cases carried out under such an order as from short to long course of the disease. Consequently, the author thinks that the patho-morphological outline of this disease has been accounted for in general.

As to the next step, the author would like to present some considerations on the lesions of this disease from the histo-pathogenetical point of view.

The most basic lesion in the central nervous system of this disease might be degeneration of nerve cells, recognized diffusely extending over all areas of the brain and spinal cord; it was regarded as belonging to acute cell changes (encephalopathia toxica). As to sources of degeneration of this kind, many active growths of infectious or toxic factors may give rise to discussion. As to this problem, the author is of opinion that consideration should be given to the significant matter of the deposition of acid-fast pigment substances detected in the central nervous system. In addition to this, the author would like to direct attention to the microscopically not yet phanerous substances of this kind, chemical states of which may be regarded as interim ones before becoming morphologically phanerous (acid-fast); existence of chemical states of various stages can be surmised from the fact that various responses to staining have been demonstrated on lesions of "yellow fat disease" which were confirmed in the present cases and others in

the author's experience as mentioned above.

Inasmuch as it is considered that "yellow fat disease" takes its rise in metabolic disturbances of fat substances of some certain kind, and since the acid-fast pigment substances found in the mature fat tissues were qualitatively grossly quite analogous to those in nerve cells, etc. of the central nervous system, it seems reasonable to postulate that such metabolic processes must take place also in the central nervous system.

From the viewpoints above mentioned, the author is of the opinion that, respecting the degenerative processes in the parenchymatous organs such as the liver, kidneys, etc., such the degenerative process as the above discussed in the central nervous system should, from general viewpoints, be regarded as a kind of toxic phenomena.

Because of the disturbances of fat metabolism, morphologically phanorous or not phanorous (acid-fast in the former) certain abnormal product of metabolism may be excreted from nerve cells and transported with participation of microglia cells, etc. Specifically acid-fast pigment substances were detected at the adventitia and intima of the capillaries and veins; further in the lumen of the blood vessel there were found macrophages which laden with the pigment substances. On rare occasions, the pigment substances were found at the intima of the small-sized arteries. Moreover, the pigment substances were found at the intima of the veins in the meninges of the cerebrum and cerebellum. As regards the fact that the pigment substances were, in respect to localization, detected in having relation to the various necrotic-desolated lesions for the most part, the author would like to be able to discuss how chemical metamorphic state of abnormal substances of this kind may be developed, under such pathological stages or processes, into microscopically phanorous one. It goes without saying that from only the localization point of view such a discussion can not be offered as definitive.

At any rate, there is no wholly denying the surmise that, were the abnormal metabolic substances of this kind are deposited in the walls of the blood vessels, the blood vessels may give rise to some functional disturbances. The author considered that it admits of no doubt that the various lesions ranging from pallidness or focal pallor to "gliös-mesenchymaler mobiler Abbau" probably have, from the qualitative evidences, localization, etc., to do with angio-architectonic condition, and are due to local functional disturbances of the blood circulation in addition to being conditioned by the blood vessels (SPIELMYER). Hereupon, as one of causes bringing on such disturbances of the blood circulation, the author would like to mention the above abnormal microscopically phanorous or not phanorous metabolic substances which may be deposited in the walls of the blood vessels including the small arteies.

The demarcated, pseudolaminar, fleck-form and the other edematous features (status cribrosus) which were observed in a majority of the cases were obviously connected mainly with venous hyperemia frequently accompanied by venous thromboses. And that, the abnormality in the character of the blood may have resulted from heightend local abnormal metabolism of tissues; the stasis of the blood may have been caused by the abnormal functioning of the blood vessels. Furthermore, such a fact that the edematous changes bring on widespread necrobioses or necroses of tissues was not only hard to be affirmed in the present cases, to say the least of it, but also in some cases quite impossible in view of evidence displayed.

With the exception of the generally slight reparative symptomatic inflammation, the perivascular and tissue infiltration of eosinophil leucocytes which was recognized in the central nervous system of almost all the cases may be regarded as a pathognomonic histological picture. It is a fact which has been confirmed at present that eosinophil leucocytes have phagocytosis and chemotaxis (MENSNIL, 1895); in addition, the fact that eosinophil leucocytes play part in management and neutralization of toxic substances (WEINBERG and SEGUIN, 1914) has met with universal acceptance. In addition to such matters, the author is interested in such function of eosinophil leucocytes as SHIMIZU and HATTA<sup>28,29</sup> have elucidated. Accordingly, the author would like to rather comprehend, according to the theory of SHIMIZU and HATTA, the eosinophil cell infiltration in the present disease as probably a manifestation of a function of the cells which acceleratedly act counteractively.

#### E. Causal genesis

In the end of the discussion, the author would like to refer to the problem of causal genesis of the present disease from the morphological point of view.

It is quite within the bounds of possibility that, in the present disease, the disorder in the central nervous system causal-genetically has relation to the metamorphosis belonging to changes of "yellow fat disease" in the fat tissues. Therefore, where this disease is considered from the causal genesis point of view, naturally "yellow fat disease" enters into the discussion.

It has met with universal acceptance that "yellow fat disease" in various creatures may be resulted from such main factors as excessive taking of unsaturated fatty acid and vitamin E deficiency. The decision that disturbances of fat metabolism due to causal agents of this kind were likely concerned in the present cases was confirmed from the fact that the changes belonging to "yellow fat disease" were actually discovered in the fat tissues. Regardless of that, the present pigs showed degeneration of nerve cells (encephalopathia toxica) or

tissue desolation such as necrobiosis or necrosis, accompanied with eosinophil cell infiltration, in the central nervous system; as to this circumstances, certain conditions of importance including disposition of age may give rise to discussion. The author, thinking of it, would like to call attention to the very interesting statement by McNUTT, viz.: "HJÄRRE (1952) observed an encephalopathy associated with focal eosinophilic perivascular infiltration in swine raised in Sweden..... He stated that veterinarians and owners of animals often suspect poisoning with herring brine or common salt but..... Some animals survived, but more often they died after a short illness. Other than the changes in the central nervous system, autopsy examinations were negative. Since the pigs of GORHAM et al. (1951) had convulsions, a possible relationship between vitamin E deficiency and the Scandinavian swine disease is suggested."

As to the next step, in connection with the etiology on "yellow fat disease," the author would like to call attention to encephalomalacia of chicks, because it appears that the disease has some significance. As the main factors of the occurrence of encephalomalacia in chicks such main nutritional ones as excessive taking of unsaturated fatty acid and vitamin E deficiency has been enumerated (PAPPENHEIMER and GOETTSCH<sup>21,22</sup>), WOLF and PAPPENHEIMER<sup>42</sup>), JUNGHERR and co-workers<sup>3,4,31-34</sup>), etc.).

Furthermore, the author would like to direct attention to the fact that ceroid (acid-fast pigment) in the central nervous system has been considered in having relation to vitamin E deficiency (WOLF and PAPPENHEIMER<sup>43</sup>) and PAPPENHEIMER and VICTOR).

The brain inocula from three out of all the present cases were inoculated intra-cerebrally into a piglet and other experimental animals, but the results were all negative; histological pictures of all the cases including the three did not indicate any infectious ones except Case No. 9. In this connection, as to HVJ isolated from the brain of Case No. 8 which was examined, the author is of the opinion that the virus was probably a saprophytic one and played no significant part.

The author would like to mention that he has borne in mind that there is a certain swine disease, to which references have been made in the foregoing pages, of name similar to the present disease in Europe and America; as regards the etiology of that disease one has attached importance to salt poisoning.

#### SUMMARY

Detailed neuro-histopathological investigations were performed, being grounded on the general point of view, on thirty-one naturally occurring cases gathered during the years 1948 to 1957, of a swine disease in Japan, so-called "encephalitis

eosinophilica suis." The cardinal symptoms of it consist of circular movement, convulsions, epileptiform seizures, etc.

Histopathological lesions of the disease in the central nervous system are characterized by various processes consisting of nerve cells diffusely extending over all areas of the brain and spinal cord, mainly pseudolaminar focal necroses (pallidness or focal pallor to malacia) principally being located in the grey matter of the prosencephalon especially in the cerebral cortex and perivascular and tissue infiltration of eosinophil leucocytes principally observed in the cortex and meninges of the telencephalon. The focal necroses, furthermore, are occasionally located in the grey matter such as in the cerebral nuclei, diencephalon, mesencephalon and medulla oblongata.

Histo-pathogenetically, a great importance is attached to the fact that most basic pathological processes in the central nervous system of the disease may possibly have much connection with a certain toxic condition originating from systemic metabolic disturbances of fat substances of certain kinds. Such disturbances were proved by the degenerative condition of nerve cells (acute cell change), metamorphosis of fat tissues belonging to the category of changes of "yellow fat disease," degeneration in the parenchymatous organs and deposition of acid-fast pigment substances detected in the central nervous system, etc. It was confirmed that the necrotic-desolated processes of the central nervous system offer much evidence that they had origin in local functional disturbances of the blood circulation (SPIELMYER); such changes were regarded as secondary ones. There is no wholly denying the surmise that the acid-fast pigment substances which were regarded as an abnormal product of metabolism of fat substances of a certain kind may take part in the functional disturbances.

It is conceivable, in conformity with histological findings, that these acid-fast substances may have various chemical states ranging morphologically from non-phanerous to phanerous, the latter showing acid-fastness for the most part.

With the exception of reparative symptomatic inflammatory infiltration into the necrotic-desolated processes, as to eosinophil cell infiltration which was recognized in almost all the cases, the author would like to comprehend it as likely manifestation of the function of the cells which acceleratedly act to counteract to the abnormal pigment substances; in other words, such infiltration is a phenomenon which belongs to a simple reactive process of the body.

With the exception of glio-mesenchymal reactive process to the necrotic-desolated lesions, mesenchymal changes consisting of swelling, increase, etc. of cells of the walls of the blood vessels, being observed particularly in the grey matter and meninges of the prosencephalon, were regarded as changes reactive to the disorder of the tissue and the abnormal metabolic substances.

Edematous focal tissue loosening of various degrees observed frequently in the cerebral cortex are considered to be a secondary process having to do with hyperemia and fibrin thromboses of the blood vessels principally of the veins.

As to the causal genesis of the present disease, "yellow fat disease" of various creatures and encephalomalacia of chicks are referred to as interesting objects from the morphological standpoint.

A certain swine disease in Europe and America, having a name similar to that of the present disease, is clinically and morphologically similar, if not identical, to the present disease.

#### CONCLUSION

In connection with so-called "encephalitis eosinophila suis" naturally occurred in Japan, detailed neuro-histopathological description of cases is presented. Discussion is offered on the histo-pathogenesis of lesions in the central nervous system from the general point of view. From the morphological standpoint comment is made on the causal genesis of the disease.

The lesions in the central nervous system of the disease are characterized by secondary necrotic-desolated processes (pallidness or focal pallor to malacia) which were regarded as having been caused by local functional disturbances of the blood circulation and eosinophil cell infiltration which was regarded as a simple reactive process of the body, both occurred principally in the telencephalon, as well as a certain kind of toxic condition which was regarded as the most basic lesion (encephalopathia toxica).

In conclusion, the author wishes to express his heart-felt thanks to his honoured teacher, Prof. S. YAMAGIWA, chief of the Department of Veterinary Pathology, Faculty of Veterinary Medicine, Hokkaido University, for his friendly guidance.

#### REFERENCES

- 1) BOHOSIEWICZ, M. (1953): *Méd. vét., Varsovie*, **11**, 498 [DONE, J. T. et al. (1957): *Vet. Rec.*, **69**, 67].
- 2) BOHSTEDT, G. & R. H. GRÜMMER (1954): *J. Anim. Sci.*, **13**, 933 [DONE, J. T. (1957): *Vet. Rec.*, **69**, 67].
- 3) BUNNELL, R. H., L. D. MATTERSON, E. P. SINGSEN & H. D. EATON (1955; -56): *Poult. Sci.*, **34**, 1184; **35**, 436.
- 4) BUNNELL, R. H., L. D. MATTERSON, E. P. SINGSEN & L. M. POTTER, A. KOZEFF & E. L. JUNGHERR (1955): *Ibid.*, **34**, 1068.
- 5) COFFIN, D. L. & J. H. HOLZWORTH (1954): *Cornell Vet.*, **44**, 63.
- 6) CORDY, D. R. (1954): *Ibid.*, **44**, 310.
- 7) DODD, D. C., A. A. BLAKELY, R. S. THORNBURY & H. F. DEWES (1960): *N. Z. vet. J.*, **8**, 45.

- 8) DONE, J. T., J. D. T. HARDING & M. K. LLOYD (1959): *Vet. Rec.*, **71**, 92.
- 9) DONE, J. T., N. H. BROOKSBANK & D. BUNTAIN (1957): *Ibid.*, **69**, 67.
- 10) ENDER, F. & A. HELGEBOSTAD (1953): *15th Proc. int. vet. Cong., Stockholm*, **1**, 636.
- 11) GOLDGLÜCK, G. (1952): *Mh. Tierheilk.*, **4**, 348 [DONE, J. T. et al. (1957): *Vet. Rec.*, **69**, 67].
- 12) GORHAM, J. R., N. BOE & G. A. BAKER (1951): *Cornell Vet.*, **41**, 332.
- 13) HJÄRRE, A. & A.-L. OBEL (1956): *Mh. VetMed.*, **11**, Suppl. 2, 690.
- 14) JENSEN, R., L. A. GLINER & O. R. ADAMS (1956): *J. Amer. vet. med. Ass.*, **129**, 311.
- 15) LARSEN, N. B., T. MØLLER & AA. THORDAL-CHRISTENSEN (1955): *Nord. VetMed.*, **7**, 653.
- 16) MASON, K. E. & G. R. HARTSOUGH (1951): *J. Amer. vet. med. Ass.*, **119**, 72.
- 17) MCNUTT, S. H. (1953): *Advances in Veterinary Science*, **1**, 283, Academic Press Inc., N. Y.
- 18) MICHALKA, J. (1941): *Wien. tierärztl. Mschr.*, **28**, 295.
- 19) NOETZEL, H. (1957): LUBARSCH-HENKE-RÖSSLE's Handb. spez. path. Anat. Histol., **13**, 1/A, 589, Springer-verlag, Berlin-Göttingen-Heidelberg.
- 20) PALLASKE, G. (1936): *Arch. wiss. prakt. Tierheilk.*, **70**, 278.
- 21) PAPPENHEIMER, A. M. & M. GOETTRICH (1931): *J. exp. Med.*, **53**, 11.
- 22) PAPPENHEIMER, A. M. & M. GOETTSCH (1933): *Ibid.*, **57**, 365.
- 23) PAPPENHEIMER, A. M. & J. VICTOR (1946): *Amer. J. Path.*, **22**, 395.
- 24) QUORTRUP, E. R., J. R. GORHAM & C. L. DAVIS (1948): *Vet. Med.*, **43**, 228.
- 25) RAC, R., J. H. BRAY & J. LYNCH (1959): *Vet. Rec.*, **71**, 688.
- 26) ROBINSON, K. L. & W. E. COEY (1951): *Nature*, **168**, 997.
- 27) SAUTTER, J. H., D. K. SORENSON & J. J. CLARK (1957): *J. Amer. vet. med. Ass.*, **130**, 12.
- 28) SHIMIZU, M. & Y. HATTA (1954): *Symposium on Hematology*, **7**, 203 (in Japanese).
- 29) SHIMIZU, M. & Y. HATTA (1955): *Jap. J. med. Prog.*, **42**, 309 (in Japanese).
- 30) SCHOLZ, W. (1957): LUBARSCH-HENKE-RÖSSLE's Handb. spez. path. Anat. Histol., **13**, 1/B, 1326, Springer-verlag, Berlin-Göttingen-Heidelberg.
- 31) SINGSEN, E. P., R. H. BUNNELL, L. D. MATTERSON, A. KOZEFF & E. L. JUNGHER (1955): *Poult. Sci.*, **34**, 262.
- 32) SINGSEN, E. P., L. D. MATTERSON, A. KOZEFF, R. H. BUNNELL & E. L. JUNGHER (1954): *Ibid.*, **33**, 192 [*Vet. Bull., Weybridge*, **24**, 669 (1954)].
- 33) SINGSEN, E. P., L. M. POTTER, R. H. BUNNELL, L. D. MATTERSON, L. STINSON, V. AMATO & E. L. JUNGHER (1955): *Ibid.*, **34**, 1234.
- 34) SINGSEN, E. P., L. M. POTTER, L. D. MATTERSON, R. H. BUNNELL, A. KOZEFF & E. L. JUNGHER (1955): *Ibid.*, **34**, 1075.
- 35) SMITH, D. L. T. (1957): *Amer. J. vet. Res.*, **18**, 825.
- 36) SPIELMYER, W. (1922): *Histopath. Nervensystem*, Springer-verlag, Berlin.
- 37) TAJIMA, M. (1953): *Jap. J. vet. Res.*, **1**, Extra 1 (in Japanese with English summary).
- 38) TAJIMA, M. (1954): *J. Jap. vet. med. Ass.*, **7**, 6 (in Japanese).
- 39) TAJIMA, M. & S. TSUBAKI (1950): *Jui-chikusan-shinpo*, No. 48, 625 (in Japanese).
- 40) TAJIMA, M. & S. YAMAGIWA (1950): *Jap. J. vet. Sci.*, **12**, 111 (in Japanese with English summary).

- 41) WAKE, I. (1942): *Trans. soc. path. jap.*, **32**, 577.
- 42) WOLF, A. & A. M. PAPPENHEIMER (1931): *J. exp. Med.*, **54**, 399.
- 43) WOLF, A. & A. M. PAPPENHEIMER (1945): *J. Neuropath.*, **4**, 402 [PAPPENHEIMER, A. M. et al. (1945): *Amer. J. Path.*, **22**, 395].
- 44) YAMAGIWA, S. (1955): *Jap. J. vet. Res.*, **3**, 41 & 153.
- 45) YAMAGIWA, S., Y. FUJIMOTO, K. OHSHIMA, H. SATOH, S. SUGANO & J. USHIJIMA (1959): *Ibid.*, **7**, 1.
- 46) YAMAGIWA, S., M. OHBAYASHI & H. SATOH (1954): *Jap. J. vet. Sci.*, **16**, Suppl., 59 (in Japanese).
- 47) YAMAGIWA, S. & H. SATOH (1956): *Jui-chikusan-shinpo*, No. 188, 846 (in Japanese).
- 48) YAMAGIWA, S. & M. TAJIMA (1952): *Mem. Fac. Agr. Hokkaido Univ.*, **1**, 145 (in Japanese with German summary).