



# HOKKAIDO UNIVERSITY

Title	FINE ANGIOARCHITECTURES IN THE PENIS OF THE DOG
Author(s)	TAKAHATA, Kurahiko; KUDO, Norio; FURUHATA, Kitao et al.
Citation	Japanese Journal of Veterinary Research, 10(4), 203-214
Issue Date	1962-12
DOI	<a href="https://doi.org/10.14943/jjvr.10.4.203">https://doi.org/10.14943/jjvr.10.4.203</a>
Doc URL	<a href="https://hdl.handle.net/2115/1771">https://hdl.handle.net/2115/1771</a>
Type	departmental bulletin paper
File Information	KJ00002373360.pdf



# FINE ANGIOARCHITECTURES IN THE PENIS OF THE DOG

Kurahiko TAKAHATA, Norio KUDO, Kitao FURUHATA,  
Makoto SUGIMURA and Tatsudo TAMURA

*Department of Veterinary Anatomy  
Faculty of Veterinary Medicine  
Hokkaido University, Sapporo, Japan*

(Received for publication, Oct. 8, 1962)

## INTRODUCTION

Problems of the mechanism of erection and vascular patterns, especially those of erectile bodies (cavernous systems), of the penis have attracted many investigators' strong interest. The delayed erection is a specific phenomenon, found only in the dog, mink and bat (CHRISTENSEN, '54; SHIOTA, '59; WIMSATT and KALLEN, '52). It was reported that such phenomenon is intimately related with parts of the specific cavernous structure, such as the bulbus glandis and pars longa glandis in the dog (CHRISTENSEN) and the accessory cavernous body in the bat (WIMSATT and KALLEN). On the other hand, SHIOTA stated that the phenomenon of delayed copulation in the mink was related with the distal hook-shaped process of the os penis in the male mink and the vaginal diverticulum, which fitted with the hook-shaped process of the os penis, in the female one. He also stated that the mink penis has no structure corresponding to the bulbus glandis of the dog penis.

The above mentioned findings seem to indicate different vascular patterns of the penis between different animal species, even if a similar phenomenon appears during copulation. Moreover, the fine vascular correlations among the arteries, veins and cavernous sinuses have never been reported in detail.

Therefore, further observations are needed in regard to the fine angio-architectures of the penis in the various animals. The present paper attempts some microstereographical clarification of the vascular patterns in the penis of the dog.

## MATERIAL AND METHOD

The penes of twelve male dogs, as presented in table 1, were used as materials.

Each dog was bled out under chloral hydrate anesthesia. After death, double solution of Neoprene latex 601-A was injected from the abdominal aorta into the penis. When the latex was returned to *V. pudenda interna* and *externa*, and when the penis showed erectile condition, the injection was stopped. Then the aorta was ligated. After macroscopic observation of the courses of the blood vessels, the penis was cut off with accompanying neighbouring tissues and macerated with industrial HCl. The macerated Neoprene cast preparations were observed

TABLE 1. Cases from Which Materials were Obtained (Male dogs)

EXP. NO	AGE	WEIGHT	EXP. NO	AGE	WEIGHT
1	5 Days	400 g	7	1 Year	16,000 g
2	"	410	8	3-4 Years	20,000
3	"	420	9	"	25,000
4	1 Year	11,000	10	?	25,000
5	"	15,000	11	18 Years	35,000
6	"	15,000	12	?	?

macroscopically and microstereographically after having been washed thoroughly with tap water.

In this paper, the nomenclatures of the blood vessels and erectile bodies in the penis of the dog correspond with those in CHRISTENSEN's descriptions.

## OBSERVATIONS

### A. Cavernous Systems

The erectile bodies in the penis of the dog consist of three separated cavernous systems, the corpus cavernosum penis, corpus cavernosum urethrae and glans penis. The glans penis is distinctly separated into two parts, the bulbus glandis and pars longa glandis (Plate I).

#### 1. Corpus cavernosum penis

The corpus cavernosum penis is a paired structure. Each corpus cavernosum penis arises from the ischial tuberosities and runs distally in the dorso-lateral side of the root and body of the penis as far as the proximal end of the os penis. This cavernous body has the narrowest sinuses in the cavernous systems of the penis. The cavernous sinuses are arranged in transverse direction, but somewhat irregularly. There are no vascular connections between the right and left corpus cavernosum penis (Fig. 5).

#### 2. Corpus cavernosum urethrae

The corpus cavernosum urethrae continues from the cavernous body surrounding the urethra in the pelvic cavity and extends as far as the distal end of the penis (Figs. 1, 2, 3 and 4). This erectile body surrounds the penile urethra throughout its course; it is situated at the ventral side of the corpus cavernosum penis in the root and body of the penis, and is covered by the os penis, bulbus glandis and pars longa glandis in the glans penis. The sinuses of this body are wide and longitudinal in direction. In the cross section, it is seen to be narrow at the dorsal side of the urethra, wide at the lateral sides and to open by a narrow longitudinal slit at the ventral side (Fig. 3). Poor connections of the sinus-branches are found across the slit. In the root of the penis, the bulb of the urethra is found as a bilobed ventral expansion of this erectile body (Fig. 5). One or three arterial anastomoses are found between the corpus cavernosum urethrae and corpus cavernosum penis. Actually, these anastomoses form connections between *A. profunda penis* and *A. bulbi urethrae* running

in each cavernous body. The corpus cavernosum urethrae gives off numerous venous branches from its ventro-medial part to supply blood to the bulbus glandis and pars longa glandis at the glans penis (Fig. 3).

### 3. Bulbus glandis

The bulbus glandis is a dense sinus plexus of walnut-shape covering the proximal one-third of the os penis. It receives numerous veins arising from the each side of the ventro-medial part of the corpus cavernosum urethrae, but neither any connection with the pars longa glandis nor with an artery is found, even if the injected latex fills the sinuses of the pars longa glandis and the subepithelial tissues of the glans (Figs. 1, 2 and 3).

### 4. Pars longa glandis

The pars longa glandis is a thin sinus plexus of cone-shape with a wedge-shaped slit at the ventral side; it covers the distal part of bulbus glandis and the distal two-thirds of the os penis. These cavernous sinuses receive numerous veins from the corpus cavernosum urethrae at the tapered end of the penis, but there is no connection with any artery (Figs. 1 and 2).

## B. Arterial System (Fig. 4)

A pair of *A. pudenda interna* and *externa* nourishes the penis of the dog. Each *A. pudenda interna* runs caudad giving off visceral branches to the bladder and prostate in the pelvic cavity, and at the root of the penis gives off *A. perinealis*, which nourishes the penile muscles, and is continued by *A. penis* running craniad. Some branches of *A. perinealis* enter into the corpus cavernosum urethrae to nourish the cavernous body. Short distance after, *A. bulbi urethrae* branches off from *A. penis*; the former sends blood into the bulbus urethrae, and next *A. profunda penis* branches off, which nourishes the corpus cavernosum penis. *A. bulbi urethrae* and *A. profunda penis* arise at portions only a short distance from *A. penis* and sometimes they occur as a common trunk. In some cases, these two arteries were seen to anastomose with *A. perinealis*. *A. bulbi urethrae* invades into the bulbus urethrae from its dorsal part and runs craniad in the lateral thick part of the corpus cavernosum urethrae to empty into this cavernous body. *A. profunda penis* divides into two or three branches before entering into the corpus cavernosum penis and then enters into this cavernous body. After the giving off of *A. profunda penis*, the main trunk of *A. penis* is continued by *A. dorsalis penis*. This artery runs craniad along the dorsal part of the corpus cavernosum penis and on the course, gives off three or more branches, which anastomose with the same artery of the opposite side and moreover with *A. profunda penis* and *A. bulbi urethrae*, running in respective cavernous bodies. At the proximal end of the glans penis, *A. dorsalis penis* gives off three branches, preputial, superficial and deep. The preputial and superficial branches repeat division into many branches, anastomosing with each other and form the capillary plexus in the subepithelial tissues of the glans penis and prepuce. The deep branch runs craniad along the dorsal side of os penis deep to the bulbus glandis and pars longa glandis and forms the capillary network at the end of the penis (Fig. 2). These three branches show conspicuous snaking or tortuous features in their course. Between the three branches, many arterial anastomoses are found.

*A. pudenda externa* supplies mainly the prepuce, but a few branches extend through the

fornix to the glans penis together with the three branches of *A. dorsalis penis*.

### C. Venous System (Figs. 4 and 5)

Main veins, which drain the penis of the dogs, are *V. pudenda interna* and *externa*. *V. pudenda interna*, the more effective one, collects blood of *V. dorsalis penis*, *V. profunda penis*, *V. bulbi urethrae* and *V. perinealis*. A pair of *V. dorsalis penis*, which begins from each proximo-lateral side of the bulbus glandis and runs caudad along the corresponding artery, is of wide diameter and has over ten conspicuous semilunar valves on their course. Each vein is confluent to a single trunk near the ischial arch. In this portion, sometimes, one or two venous networks were found. The single trunk redivides to follow to the right and left *Vv. pudendae internae*. *V. profunda penis* receives blood of the corpus cavernosum penis. The vein begins from the dorsal root of the corpus cavernosum penis and runs along the corresponding artery. *V. bulbi urethrae* drains blood from the bulbus urethrae. The course of this vein is also nearly corresponding with the artery of the same name. *V. profunda penis* and *V. bulbi urethrae* are not confluent to a single common trunk, but form a venous plexus conjugating with *V. dorsalis penis* and *V. perinealis* at the dorsal side of the penile root. *V. perinealis* receives blood of the penile muscles at the root of the penis and enters into the above-noted venous plexus.

*V. pudenda externa* drains blood from the pars longa glandis and the subepithelial tissues of the glans penis. The vein leaves the penis through the fornix of the prepuce and also drains blood from the prepuce.

There are two sorts of veins, which make connection between the cavernous bodies, as mentioned in the above paragraphs. The one sort comprises the several veins of plexus form, which run from the corpus cavernosum urethrae to the bulbus glandis. The other one extends from the corpus cavernosum urethrae to the pars longa glandis and shows similar features to the former.

In this paper, use is made provisionally of the names *Vv. intercavernosae caudales* for the former and *Vv. intercavernosae craniales* for the latter.

All of the above-described veins have semilunar valves at short intervals in their course, as found in *V. dorsalis penis*. On the other hand, all cavernous sinuses have no valves.

The deep veins of the glans, which connect between the bulbus glandis and pars longa glandis (CHRISTENSEN), could not be found in this observation.

### D. Fine Vascular Arrangement

#### 1. In the corpus cavernosum penis (Plate III)

*A. profunda penis* runs distad in the corpus cavernosum penis and gives off many branches in this cavernous body, at right angles to the course of this arterial trunk. These branches send off capillaries, to nourish the supporting tissue among the sinuses, and the so-called helicine arteries, which enter directly into the sinuses. The latter redivide into clumps of three or several vessels shortly after leaving their trunk. In the latex cast preparation, the lumen of each vessel shows irregular swelling, constriction and snaking in its course and enters directly into the sinuses of the corpus cavernosum penis. Blood of the cavernous sinuses is drained by *V. profunda penis*. The connecting parts between the vein and cavernous sinuses are usually narrow in the latex cast.

## 2. In the bulbus urethrae and corpus cavernosum urethrae (Plate IV)

After entering into the bulbus urethrae, *A. bulbi urethrae* gives off numerous branches at nearly right angles to the longitudinal arterial trunk. The arterial trunk runs distad in the lateral part of the corpus cavernosum urethrae to supply blood to the urethral cavernous sinuses of the penile body. Near and in the glans penis, the corpus cavernosum urethrae is supplied by arterial rami of the trunk and deep branches of *A. dorsalis penis*. The connecting feature between the cavernous sinuses and arteries is similar to that in the corpus cavernosum penis; each arterial branch gives off three or more rami, which show helicine arterial features, and also enter directly into the cavernous sinuses. But, in detail, it seems that each arterial ramus is less tortuous than that of the corpus cavernosum penis.

Blood of the bulbus urethrae and proximal half of the corpus cavernosum urethrae is drained by *V. bulbi urethrae*. In its course, no specific features are found in the latex cast. Blood of the distal half of the corpus cavernosum urethrae flows into the bulbus glandis and pars longa glandis through *Vv. intercavernosae caudales* and *craniales* as described already.

## 3. In the bulbus glandis (Plate I)

The connective tissues existing between the sinuses of the bulbus glandis are nourished by the capillaries arising from the three branches of *A. dorsalis penis* and *A. pudenda externa*. On the other hand, these arterial branches and capillaries never enter directly into the sinuses. The bulbus glandis is supplied by *Vv. intercavernosae caudales* arising from the corpus cavernosum urethrae. *Vv. intercavernosae caudales* show two different flows; the one begins as a plexus of several veins from each ventro-medial part of the corpus cavernosum urethrae at the proximal part of the glans penis and flows into the ventro-caudal portion of the bulbus glandis (CHRISTENSEN's ventral shunt). The other one begins from the short distal part of the former veins to enter into the dorso-distal part of the bulbus glandis (corresponding to CHRISTENSEN's dorsal shunt).

Blood of the sinuses is drained by *V. dorsalis penis*.

## 4. In the pars longa glandis (Plate V)

The pars longa glandis is covered by a rich vascular plexus of the subepithelial tissue of the glans. But, there were never found any arteries which enter directly into the sinuses.

Venous blood arising from the ventro-distal end of the corpus cavernosum urethrae flows through *Vv. intercavernosae craniales* into the sinuses of the pars longa glandis. More largely, the subepithelial capillaries are collected into small veins, which form a venous plexus around the penis tip at the distal end of the glans penis to continue into the sinuses of the pars longa glandis. Usually, the beginning of the venous plexus shows conspicuous tortuous and arterial features in the cast preparation.

Blood of the pars longa glandis is collected into a vein, which is continued by *V. pudenda externa* through the fornix of the prepuce at the dorsal part of the glans penis.

## 5. In subepithelial tissues of the glans penis (Plate VI)

In the subepithelial tissues of the glans penis, a conspicuous vascular plexus is formed with participation of the preputial and superficial branches of *A. dorsalis penis* and *A. pudenda externa*.

In the subepithelial vascular plexus, typical arterio-venous anastomoses were frequently found. The communicating vessels usually have irregular lumen as shown in the latex cast. Each of them makes one conspicuous loop respectively just after leaving the artery and enters into the venous plexus with somewhat long course (Figs. 16, 17 and 18).

Blood of the vascular plexus flows mainly into the pars longa glandis and partially into *V. pudenda externa* together with that of the prepuce.

#### DISCUSSION

Morphological and angiological observations of the mammal penis have been reported by MÄDER ('07), KISS ('21), VAERST ('38), DEYSACH ('39), ASHDOWN ('58) and DAIGO ('60). Recently, with special interest for the phenomenon of the delayed erection, the vascular organization of the penis was observed by WIMSATT and KALLEN ('52), CHRISTENSEN ('54) and SHIOTA ('59) with use of bats, dogs and minks respectively.

In his recent report regarding the vascularization of the penis of the dog, DAIGO's interest was concentrated upon anastomoses between *A. pudenda externa* and *interna* in the dog penis on the basis of a roentgenographical method, but he paid no attention to the cavernous systems and veins.

The present writers could not find arterial anastomoses between *A. profunda penis* and *A. pudenda externa* (DAIGO's *A. dorsalis penis cranialis*), which were described by DAIGO.

CHRISTENSEN's report is the most detailed one in the literature on the subject; in the present observation, the arterial supply of the dog penis is seen to be in accord with his description. But, with regard to the venous pattern, there were several items of disagreement.

CHRISTENSEN maintained that the deep veins of the glans, which drain blood from the pars longa glandis into the bulbus glandis, flow into the dorsal shunts of the latter and help the action of the bulbus glandis under the phenomenon of delayed erection. Nevertheless, he is not successful in getting injection into the pars longa glandis.

In the perfectly injected cast, the present writers found that the sinuses of the pars longa glandis receive blood from *Vv. intercavernosae craniales*, beginning from the distal tip of the corpus cavernosum urethrae, and from a venous plexus, originating from the subepithelial capillaries of glans, but there are no veins corresponding to CHRISTENSEN's "deep veins of the glans". Moreover, it could be demonstrated that the dorso-distal end of the bulbus glandis, which was suggested as the entrance of the deep veins of the glans of CHRISTENSEN, was distinctly connected with branches of *Vv. intercavernosae caudales*. That is, the pars longa glandis and bulbus glandis are cavernous bodies independent of each other. The presence of the "deep veins of the glans" was proved to be doubtful by this

observation.

One of the other disagreements is the appearance of venous connection at the root of the penis. CHRISTENSEN stated that *V. perinealis*, *V. bulbi urethrae* and *V. profunda penis* form a common venous trunk and then the common trunk enters into *V. pudenda interna* at each side; however, the present writers' observations showed that the above-mentioned three veins form a somewhat complex venous plexus at each side of the penile root. Blood of the venous plexus is collected into two veins of different courses; the one runs caudad to enter into *V. pudenda interna*, which was described as a usual course by CHRISTENSEN. The other one runs cranial to enter into the common trunk of *V. dorsalis penis*. The venous plexus may correspond with SANTOLINI's plexus in the penis of men, monkeys and pigs (DEYSACH) or with the cord-like venous plexus in the penis of minks (SHIOTA).

In this observation, the present writers' interest has been focused on fine vascular connections among the cavernous bodies, arteries and veins.

With regard to a peculiar artery, the helicine arteries, in the corpus cavernosum penis, attention was paid by VAERST, KISS and others. They reported that the helicine arteries retain their spiral shape due to contracted myo-epithelium in nonerection and convey blood directly into the sinuses of the corpus cavernosum penis. But, these investigators paid no special attention to the vascular connection in the other cavernous bodies.

In the corpus cavernosum penis, the present writers proved that the helicine arteries connect directly with the sinuses and has tortuous, irregular lumen, but does not show spiral figures in specimens artificially erected by means of injection with Neoprene latex. The similar arterial feature and connection were also found in the corpus cavernosum urethrae and bulbus urethrae.

DEYSACH stated that *V. profunda penis* has specific sluice valves, which dam up blood in the cavernous sinuses of the corpus cavernosum penis, in the animals having no long os penis.

The present writers could not detect any special feature regarding connection between veins and cavernous sinuses in the dog penis.

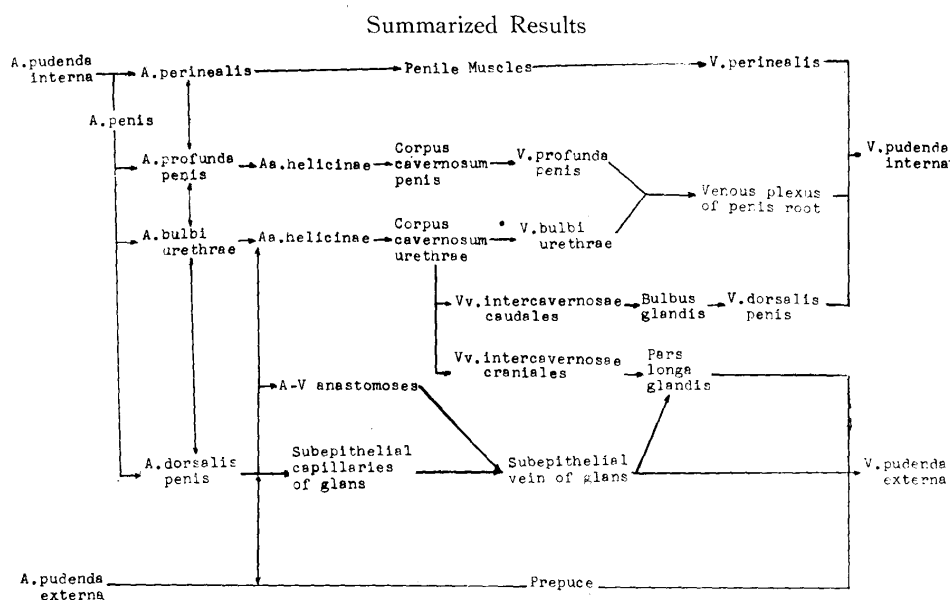
Concerning the vascular correlations among the arteries, veins and cavernous sinuses in the glans, especially in the pars longa glandis, there are only a few descriptions, suggesting that venous blood flows into the sinuses of the glans (MÄDER and CHRISTENSEN).

The present writers proved that the sinuses of the bulbus glandis and pars longa glandis receive blood from *Vv. intercavernosae*, which originate from the corpus cavernosum urethrae, and the pars longa glandis principally receives venous blood which was collected from the subepithelial veins of the glans at the penis

tip. However, the connective tissue between the sinuses was nourished by capillaries of the subepithelial vascular plexus of the glans.

The typical arterio-venous anastomoses, as shown in the tongue by PRICHARD and DANIEL, were found numerous only in the subepithelial vascular plexus of the glans. The communicating vessels showed loop or tortuous features just near the arteries from which they originated, often with irregular lumen on some portion of their courses. Actually, the anastomoses may act as an important passage, when the pars longa glandis is in need of a large quantity of venous blood in erection.

From the above-mentioned observations of the present writers, the relation of the vascular supply of the penis of the dog may be summarized, as shown in the next table.



As suggested by this table, the corpus cavernosum penis and urethrae are cavernous bodies with capillary or arterial nature. On the other hand, the bulbus glandis and pars longa glandis are cavernous bodies with venous nature.

With regard to the mechanism of the erection and delayed erection, CHRISTENSEN described in detail from his physiological and angiological findings.

The present writers have no physiological data, so they have no intention to discuss the mechanism of the erection or delayed erection. But, at least, it should be necessary to reinvestigate with regard to existence and functional significance of deep veins of the glans.

#### SUMMARY

The fine angioarchitecture of the penis of the dog was observed with use of

Neoprene latex cast preparations. The results obtained are summarized as follows.

1. The cavernous systems of the dog penis consist of a pair of the corpus cavernosum penis, the corpus cavernosum urethrae, which has a bilobed bulbus urethrae at the ventral penile root, and the glans. In the glans, there are two independent cavernous bodies, the bulbus glandis and pars longa glandis.

2. Main arteries, supplying the penis of the dog, consist of a pair of *A. pudenda externa* and *interna*. Each *A. pudenda interna* gives off *A. perinealis* to be continued by *A. penis* at the ischial arch. After a short distance, *A. penis* branches off *A. bulbi urethrae* and *A. profunda penis* to be continued by *A. dorsalis penis*. *A. dorsalis penis* gives off several circumflex branches in its course, and near the glans divides into three branches; preputial, superficial and deep ones. *A. pudenda externa* nourishes mainly the prepuce, but some branches, anastomosing with three branches of *A. dorsalis penis*, supply blood to the glans through the fornix of the prepuce.

3. In the corpus cavernosum penis, *A. profunda penis* divides into clumps of three or several vessels. Each vessel shows irregular, swelling and constricted lumen in its course and enters directly into the sinuses. These vessels correspond to the so-called helicine arteries.

4. The proximal half of the corpus cavernosum urethrae and bulbus urethrae are supplied by *A. bulbi urethrae*, and the distal half of the former is nourished by branches of *A. dorsalis penis*. In the corpus cavernosum urethrae, the appearance of the vascular connection is similar to that in the corpus cavernosum penis; the cavernous sinuses receive directly the arterial blood from the helicine-like arteries.

5. The cavernous sinus of the bulbus glandis receives the venous blood through *Vv. intercavernosae caudales*, which begin from the corpus cavernosum urethrae, but no direct communication with an artery is found.

6. The cavernous sinus of the pars longa glandis receives also the venous blood through *Vv. intercavernosae craniales*, which begin also from the corpus cavernosum urethrae. In addition, the venous blood, which is drained from the subepithelial vascular plexus of the glans, flows into this cavernous sinus, but the sinus does not receive any arterial blood.

7. In the subepithelial vascular plexus of the glans, numerous typical arterio-venous anastomoses are found.

8. The main veins, which drain blood of the penis of the dog, are *V. pudenda interna* and *externa*. *V. pudenda interna* collects blood of *V. dorsalis penis*, *V. profunda penis*, *V. bulbi urethrae* and *V. perinealis*. Each of them drain blood from the sinuses of the bulbus glandis, of the corpus cavernosum penis, of the corpus cavernosum urethrae and the penis muscles respectively.

9. *V. profunda penis*, *V. bulbi urethrae* and *V. perinealis* are not confluent

to a common trunk, but form a venous plexus at the root of the penis.

*V. pudenda externa* drains blood from the pars longa glandis and prepuce. The so-called "deep veins of the glans" of CHRISTENSEN were not found in this observation.

#### REFERENCES

- 1) ASHDOWN, R. R. (1958): *Anat. Anz.*, **105**, 222
- 2) BRADLEY, O. C. & T. GRAHAM (1959): *Topographical anatomy of the dog*, 6th Edit., Oliver and Boyd, Edinburgh and London
- 3) CHRISTENSEN, G. C. (1954): *Amer. J. Anat.*, **95**, 227
- 4) DAIGO, M. (1960): *The Bulletin of the Nippon Veterinary and Zootechnical College*, No. 9, 38 (in Japanese with English summary)
- 5) DEYSACH, L. J. (1939): *Amer. J. Anat.*, **64**, 111
- 6) KISS, F. (1921): *Z. ges. Anat.*, **61**, 455
- 7) MÄDER, E. (1907): *Arch. wiss. prakt. Tierheilk.*, **33**, 137 u. 281
- 8) MILLER, M. E. (1952): *Guide to the dissection of the dog*, 3rd. Edit., Ithaca. New York
- 9) PRICHARD, M. M. L. & P. M. DANIEL (1954): *Amer. J. Anat.*, **95**, 203
- 10) SHIOTA, G. (1959): *Inaug-Diss.*, Nippon University, Tokyo (in Japanese)
- 11) VAERST, L. (1938): *Gegenbauers Jb.*, **81**, 307
- 12) WIMSATT, W. A. & F. C. KALLEN (1952): *J. Morph.*, **90**, 415

ABBREVIATIONS OF FIGURES

- CCP: Corpus cavernosum penis  
 CCU: Corpus cavernosum urethrae  
 BU: Bulbus urethrae  
 BG: Bulbus glandis  
 PLG: Pars longa glandis  
 A: Artery  
 Ape: *A. pudenda externa*  
 Api: *A. pudenda interna*  
 Ap: *A. penis*  
 Aper: *A. perinealis*  
 Adp: *A. dorsalis penis*  
 Abu: *A. bulbi urethrae*  
 App: *A. profunda penis*  
 V: Vein  
 Vpe: *V. pudenda externa*  
 Vpi: *V. pudenda interna*  
 Vper: *V. perinealis*  
 Vdp: *V. dorsalis penis*  
 Vbu: *V. bulbi urethrae*  
 Vpp: *V. profunda penis*  
 Vicr: *Vv. intercavernosae craniales*  
 Vicd: *Vv. intercavernosae caudales*

EXPLANATION OF PLATE

All figures are photographs of Neoprene latex cast preparations.

PLATE I. Cavernous bodies

- Fig. 1. Lateral view of entire cast of the penis, in which subepithelial vascular plexus of the glans is removed.  
 Fig. 2. Lateral view of the glans, in which subepithelial plexus and pars longa glandis are removed. The bulbus glandis connects with the corpus cavernosum urethrae at the ventral and dorso-distal parts respectively. Deep branch of *A. dorsalis penis* shows conspicuous spiral and snaking features.  
 Fig. 3. Ventral view of the glans. The bulbus glandis and the pars longa glandis connect with the corpus cavernosum urethrae through the *Vv. intercavernosae*, which have semilunar valves in their course.

PLATE II. Arterial and venous supplies

- Fig. 4. Lateral view of the penis, bladder and prostate. Arteries and veins supplying the penis are clearly shown.  
 Fig. 5. Dorsal view of the penis root. In this preparation, arteries are removed. The venous course from *V. dorsalis penis* to *V. pudenda interna* is clear and

moreover a venous plexus, which is formed by the conflux of *V. profunda penis*, and *V. bulbi urethrae*, is also shown.

PLATE III. In the corpus cavernosum penis

- Figs. 6, 7 and 8. The cavernous sinuses connect directly with arterial branches, which correspond to helicine arteries. × 50
- Fig. 9. The cavernous sinuses are drained by *V. profunda penis*. In its course, no peculiar features are found, though the connecting part between the vein and sinuses is somewhat thin. × 23

PLATE IV. In the corpus cavernosum urethrae

- Fig. 10. In the bulbus urethrae, the arterial branches enter directly into the cavernous sinuses. The lumens have irregular strictures. × 50
- Fig. 11. In the corpus cavernosum urethrae, the same feature is found. × 50
- Fig. 12. Showing the connection between *V. bulbi urethrae* and cavernous sinuses. × 50

PLATE V. In the pars longa glandis

- Fig. 13. The pars longa glandis (upper) receives venous branches which collect the capillaries of the subepithelial vascular plexus (left). The venous branches show arterial, spiral and snaking features in cast specimens (right lower). × 23
- Fig. 14. The same finding. In a vein, a semilunar valve is seen. × 50

PLATE VI. In the subepithelial vascular plexus of the glans

- Fig. 15. Showing the subepithelial vascular plexus of the glans. × 50
- Figs. 16, 17 and 18. Typical arterio-venous anastomoses. In their course, the communicating vessels have a loop or tortuous feature each, just after leaving the artery (upper). × 50

