



HOKKAIDO UNIVERSITY

Title	PATHOLOGICAL STUDIES OF AVIAN LEUKOSIS : I. ON PATHOGENESIS OF AVIAN VISCERAL LYMPHOMATOSIS
Author(s)	YAMAGIWA, Saburo; ONO, Takeshi; UEDA, Akira et al.
Citation	Japanese Journal of Veterinary Research, 11(4), 99-122
Issue Date	1963-12
DOI	https://doi.org/10.14943/jjvr.11.4.99
Doc URL	https://hdl.handle.net/2115/1782
Type	departmental bulletin paper
File Information	KJ00002373394.pdf



PATHOLOGICAL STUDIES OF AVIAN LEUKOSIS

I. ON PATHOGENESIS OF AVIAN VISCERAL LYMPHOMATOSIS

Saburo YAMAGIWA*

*Department of Comparative Pathology, Faculty of Veterinary
Medicine, Hokkaido University, Sapporo, Japan*

Takeshi ONO, Akira UEDA

Obihiro Zootechnical College, Obihiro, Japan

and Mutsumi INOUE

Faculty of Agriculture, Gifu University, Gifu, Japan

(Received for publication, July 26, 1963)

INTRODUCTION

Study of avian leukosis is one of the important research problems which have long been assigned to veterinary investigators. In recent years, etiological studies have gradually progressed, but it appears that pathological investigations have not always been scrupulously and carefully performed. The authors hope to supplement this defect by arranging their pathological experience gained and necropsy materials accumulated during about ten years at the Gifu University which is located in such an territory of Japan as poultry raising advance.

The papers which have given the most attention to the pathogenesis of avian visceral lymphomatosis are probably those of LUCAS and his co-workers^{14-18,22}. They have conducted comparative studies with qualitative and quantitative accounts, using pigeons, ducks, pheasants, doves, and chick lines which are resistant and susceptible to lymphomatosis, on the ectopic lymphoid tissue in the pancreases of the birds examined. On the basis of these studies, they have discussed the relation between the ectopic lymphoid tissue and naturally occurring lymphomatosis. In conclusion, they have attached great importance to the role which may be played by the ectopic lymphoid tissue in lymphomatosis, and they have formed an opinion that it is appropriate to consider dividing lymphomatosis into two phases, systemic and neoplastic.

On the other hand, some studies of problems concerning virus isolation, transmissibility and metastasis, etc. of neoplastic tissue masses in lymphomatosis have also been reported, before or after those by LUCAS and his co-workers. More recently, even features of tissue culture (FONTES et al.; SHARPLESS et al.) and electron microscopy (DMOCHOWSKI) of certain viral agents which have been mentioned as

* Present address: Obihiro Zootechnical College, Obihiro Japan.

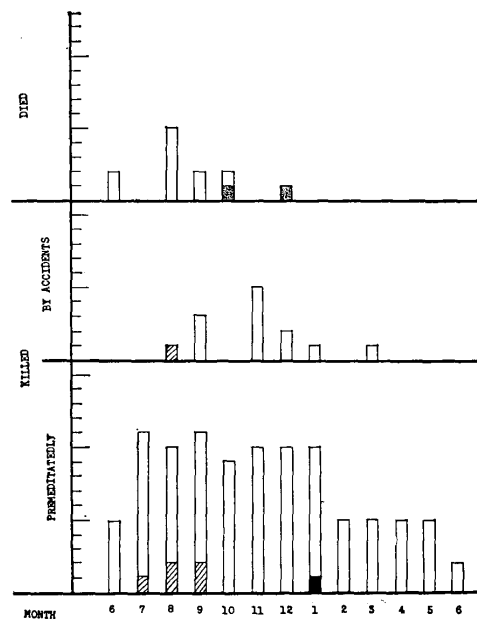
causal agents of lymphomatosis have appeared in the limelight in the literature.

However, to our disappointment, generally little attention has been paid to the pathogenesis of lymphomatosis since the studies made by LUCAS and his co-workers. The authors became interested in the pathogenesis of lymphomatosis in the course of their studies on avian leukosis and endeavoured to make materials for investigation under their particular conception. In this paper, centering around findings from these materials, the authors should like to advance their discussion.

MATERIALS AND METHODS

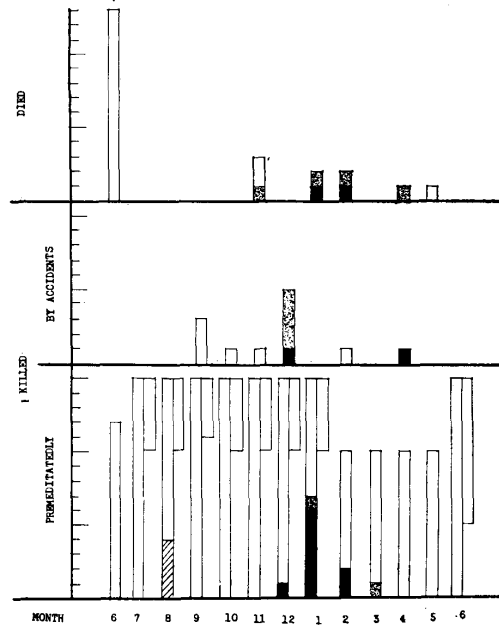
Materials submitted for the investigation are of 703 cases which were obtained by means which will be described. All of the cases were, after autopsy, provided histopathological observation by already establishing methods. All of the cases were divided into three groups: group 1, 2 and 3 are of 123 cocks of White Leghorn, 250 and 330 hens of White Leghorn × Plymouth Rock, hatching at the same time, respectively. From the day of hatching, a total of 703 fowls were kept under identical conditions without any treatment, being given ideal breeding and management using cages. Usually, in each of the groups, the birds were

CHART 1. *Group 1 of Experiment*



- ▨ "Abnormal hyperplasia" of lymphatic tissue
- ▤ "Immaturation" of abnormally hyperplastic lymphatic tissue
- "Maturation" of abnormally hyperplastic lymphatic tissue
- Lymphatic tissue outside the question

CHART 2. Group 2 of Experiment



- ▨ "Abnormal hyperplasia" of lymphatic tissue
- ▩ "Immaturation" of abnormally hyperplastic lymphatic tissue
- "Maturation" of abnormally hyperplastic lymphatic tissue
- Lymphatic tissue outside the question

submitted for investigation in such a manner as that about ten of them were killed at intervals of one month, and consequently the period in which the materials were obtained was extended to about a year in each group. During this period some birds died and some birds were killed by accidents outside the program; all of them were also used as the materials to be examined (Charts 1, 2 and 3).

All of the chickens submitted for experiment originated from the breeding groups belonging to the G HATCHERY, INC. in Gifu City, and they could be regarded as so-called "brothers and sisters" of "closed flock" and as nearly pure chick lines.

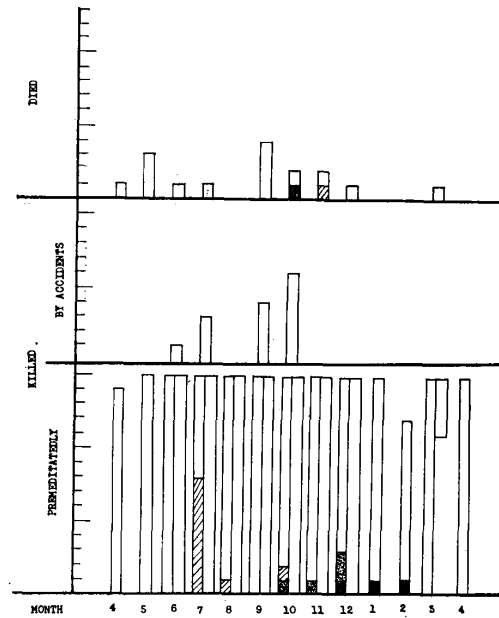
DESCRIPTION BY CASES

Among the 703 cases examined, description by cases on the 16 (Nos. 1~16) selected ones adequate for figure preparation will be made. One should note in advance that there were no significant changes, except in special cases, in the main organs on which no microscopical findings are described.

No. 1

No. 1245 (Autopsy No.) Group 3, White Leghorn×Plymouth Rock, ♀, 93 days of age (Body weight, 500 g.), Killed

Liver : 13.5g. Macroscopically, there were a large number of gray-whitish fine foci in

CHART 3. *Group 3 of Experiment*

- ▨ "Abnormal hyperplasia" of lymphatic tissue
- ▤ "Immaturation" of abnormally hyperplastic lymphatic tissue
- "Maturation" of abnormally hyperplastic lymphatic tissue
- Lymphatic tissue outside the question

the parenchyma. Under low magnification, ten odd numbers of roundish cellular foci were observed. Many of them were tightly attached to the veins, and had very distinct circumferences (Fig. 1). Each of the foci was composed of cells having large pale nucleus and somewhat abundant protoplasm, and included some cells with outstandingly larger nucleus, and intermingled with lymphocytes on rare occasions (Fig. 2).

Spleen: 2 g. Macroscopically, the follicles were swollen. Periarterially, there were many irregular-shaped loose foci of cell proliferation. The cellular elements of the foci were principally pale-nuclear cells with fleshy protoplasm, intermingled with many pyknotic naked nuclei (Cf. Figs. 8 and 9). Some of the foci had a small accumulation of plasma cells on their peripheries.

Kidneys: 2.5 g. There were ten odd numbers of cellular foci with rather indistinct circumferences. All of these foci were composed of cells with large pale nucleus. Some of the foci closely touched the veins. (Cf. Figs. 51~53).

Heart: 3.5 g. A few small cellular accumulation foci were seen in the intermuscular tissues, endocardium and subintimal tissue of the veins respectively. Foci with loose cellular composition had many large-pale-nuclear cells and irregular circumferences, while foci with dense cellular composition had distinct circumferences and were principally composed of lymphocytes.

Lungs: A few cellular accumulation foci were observed. In the large ones there were

many large-pale-nuclear cells and pyknotic naked nucleus.

Proventriculus: In the submucosa, one fairly large cellular focus was observed. Cells which composed the focus generally had large pale nucleus.

Discussion Foci resembling normal lymphatic apparatus in arrangement, size, etc. were observed in all of the organs examined. However, the foci were predominantly composed of cells differed from mature lymphatic cells in character.

No. 2

No. 1548 Group 1, White Leghorn, ♂, 31 days (350 g.), Killed

Liver: 11.6 g. Macroscopically slightly swollen. Round cell accumulation foci were observed, contacting or surrounding the veins. The foci were dissimilar in size, and could be seen hardly with low magnification. Although some foci of which the cellular element consisted mainly of lymphocytes were present, many were composed of cells having pale nucleus as the principal component (Figs. 3 and 4).

Spleen: 1.4 g. Macroscopically, small circumscribed areas were scattered in the pulp. Periarterially, there were foci of cells of which the nucleus was large and pale and of which the cytoplasm was abundant were observed; many of the foci showed network structures. The features were similar to those described in *No. 1*, but in this case the foci included few naked nuclei and had a tendency to denseness. There were many plasma cells in the red pulp.

Kidneys: 1.6 g. A small focus was observed. The focus was composed of cells with large pale nucleus, intermingled with lymphocytes.

Lungs: There were scattered ten odd large and small foci. These foci were composed of cells with large pale nucleus and were intermingled with fair numbers of lymphocytes.

Proventriculus: In the submucosa there were loose or dense network foci of somewhat fleshy cells with pale nucleus.

Cecum: In the submucosa there were many lymphatic cells with pale nucleus, and scattered lymph follicle-like foci among the cells. These foci were crowded with large-pale-nuclear cells.

Discussion In the kidneys, lungs, proventriculus and cecum as well as in the spleen and liver, foci of tissue proliferation were observed. They were principally composed of large-pale-nuclear cells and considered to be closely related to the lymphatic apparatus in arrangement and character. The bursa of Fabricius was almost normal (Figs. 5~7). Granulomata with multinuclear giant cells were observed in the coronary adipose tissues of the heart and in the pectoral muscles.

No. 3

No. 1612 Group 1, White Leghorn, ♂, 93 days (1300 g.), Killed

Liver: 36.5 g. There were many cellular foci. These foci were in contact with or surrounding the veins, or in the subintimal tissue protruding into the vascular lumen. Although the cellular element of the foci was not always uniform, the majority of the foci were principally composed of cells with large pale nucleus (Cf. Figs. 12 and 13).

Spleen: 9 g. Moderately swollen. Prominent features of periarterial hyperplasia (Figs. 8 and 9); the cellular element was principally composed of cells with large pale nucleus, accompanied with intermingling of pyknotic nuclei. There were a few lymph follicles.

Kidneys: 5.5 g. Somewhat irregular-shaped cellular foci were scattered throughout. The

cellular element of the foci was principally cells with large pale nucleus.

Heart: 5.5 g. In the intermuscular and subpericardial tissues of the heart, there existed the lymphatic apparatus somewhat conspicuously. A few of the apparatus were composed principally of cells with large pale nucleus.

Discussion In the liver and spleen the arrangement of large-pale-nuclear cell foci was the same as Nos. 1 and 2, but the scale of the foci was larger. In the lungs, oesophagus, proventriculus, jejunum, cecum, thyroid glands and bone marrow of the femur, the development of the lymphatic apparatus was also remarkable.

No. 4

No. 1243 Group 3, White Leghorn×Plymouth Rock, ♀, 93 days (1050 g.), Killed

Liver: 25.5 g. The development of the lymphatic apparatus was fairly conspicuous; the apparatus were in contact with the veins and bile ducts, or in the subintimal tissue protruding into the lumen of the veins. In some of the apparatus, there were many large-pale-nuclear cells.

Spleen: 3.5 g. Slightly swollen. Periarterially, the lymphatic tissues developed hyperplasia. In some of the tissues, there were many large-pale-nuclear cells.

Kidneys: 4.5 g. Two cellular foci of somewhat large size and irregular shape were observed among the scattered lymphatic apparatus. These foci were crowded with large-pale-nuclear cells, intermingled with mitotic ones.

Heart: 5 g. In the intermuscular tissues one small focus was observed composed of large-pale-nuclear cells.

Ileum: The lymphatic apparatus in the submucosa were well developed. In some of them, the component cells possessed large pale nucleus (Figs. 10 and 11).

Bursa of Fabricius: Enlarged. In each lobule the tissue structures were disordered. In the outermost tissues, almost all of the lymphocytes had disappeared, and in the innermost, large-pale-nuclear cells proliferated.

Discussion In addition to the organs described above, in the lungs, crop, thyroid glands and bone marrow of the femur, the development of the lymphatic tissues was fairly prominent; in some of the tissues it was clearly indicated that large-pale-nuclear cells came to the front.

No. 5

No. 1332 Group 3, White Leghorn×Plymouth Rock, ♀, 184 days (1150 g.), Killed

Liver: 59.5 g. Moderately swollen. Many minute foci were present; thin layers of large-pale-nuclear cells had developed surrounding almost all the veins. Consequently, the arborescent structures corresponding to the vascular running were picturesque. Development of similar cell layers was also observed around the bile ducts. Among the proliferated cells, pyknotic cells were observed in fairly large numbers (Figs. 12 and 13).

Spleen: 6 g. Moderately swollen. Large-pale-nuclear cells proliferated perivascularly; there were not a few pyknotic cells (Cf. Figs. 8 and 9).

Kidneys: 8.5 g. Focally, particularly around the veins forming a stratified structure, the proliferation of large-pale-nuclear cells was fairly conspicuous; a large number of mitotic cells were observed; almost no features of cellular degeneration could be found (Figs. 14 and 15).

Heart: 8 g. In the myocardium, a few cord-like foci of large-pale-nuclear cells were

clearly observed in the intermuscular tissues. Their character was similar to those in the kidneys (Figs. 16 and 17).

Lungs: Almost completely occupied by large-pale-nuclear cells. The bronchial system was somewhat dilated and had no cells.

Crop: Proliferation of large-pale-nuclear cells was remarkable, particularly in the submucosa. The epithelium was well maintained as a whole, but there were a few eroded foci. In the submucosa, muscularis, etc., a perivascular, slight, mantle-like proliferation of large-pale-nuclear cells was observed.

Proventriculus: The submucosa was stuffed with large-pale-nuclear cells. The proper tissue structures were completely maintained. In the muscularis and the other loose interstitial tissues, proliferation of large-pale-nuclear cells was also observed.

Jejunum: Lymph follicles in the mucosa were occupied by large-pale-nuclear cells.

Adrenals: In the capsule, thin-stratiform proliferation foci of large-pale-nuclear cells were observed. These foci also invaded the parenchyma. In the peripheral adipose tissues, there were also accumulations of large-pale-nuclear cells.

Ovaries: In the loose connective tissues, proliferation of large-pale-nuclear cells was observed. The proper tissue structures of the ovaries were not disappeared (Cf. Figs. 22 and 23).

Thyroid glands: In the peripheral adipose tissues two foci of large-pale-nuclear cells were observed.

Discussion Proliferation of large-pale-nuclear cells was prominent in the lungs and proventriculus. But in both, the proper tissue structures were maintained. In the other organs, proliferation of large-pale-nuclear cells was not so remarkable.

No. 6

No. 1375 Group 3, White Leghorn × Plymouth Rock, ♀, 213 days (2150 g.), Killed

Liver: 98 g. Macroscopically swollen with many minute foci. There were many cellular foci with somewhat long shape and with large or small knobby shapes, grew around the blood vessels like a mantle. Their cellular element was composed of large-pale-nuclear cells that, in many cases, clearly showed a pavement-like arrangement. In the remaining liver tissues, the same kind of cells were also present within the sinusoids either singly or in small groups (Figs. 18 and 19).

Spleen: 3.5 g. Swollen to the size of a sparrow's egg. There were a large number of cellular foci of various shapes, proliferated perivascularly. The cellular element was identical with that described in the liver (Figs. 20 and 21).

Kidneys: 7 g. Minute cellular foci were scattered in the interstitial tissues. The cells were the same as that in the liver and spleen.

Proventriculus: A mass of large-pale-nuclear cells was present in the submucosa. In a portion of the mass, lymphocyte accumulation was observed.

Cecum: Lymphatic tissues in the mucosa were hyperplastic, and the cellular element was composed of cells with large pale nucleus.

Rectum: There were cellular foci of large-pale-nuclear cells in the muscularis.

Adrenals: Beneath the capsule, there was one cellular focus of large-pale-nuclear cells.

Ovaries: In the interstitial tissues, there were many small foci of large-pale-nuclear cells. Both the nuclei and cytoplasm of the component cells increased in staining (Figs. 22 and 23).

Bone marrow of the femur: Macroscopically there were many grayish-yellow foci. Microscopically they were seen to be foci of large-pale-nuclear cells.

Discussion In the liver, spleen and bone marrow of the femur, proliferation of large-pale-nuclear cells was worthy of note. The proliferation of the same kind of cells, of which the feature resembled the lymph follicle, was observed in the proventriculus, cecum, rectum, adrenals, kidneys, etc. The character of cells in the ovaries had a somewhat different appearance. In the heart, lungs and oesophagus, the lymphatic tissues were conspicuous.

No. 7

No. 1454 Group 3, White Leghorn×Plymouth Rock, ♀, 306 days (1500 g.), Killed

Liver: 250 g. Markedly swollen. Foci of cellular proliferation, many of which were clearly of perivascular proliferation, so filled the liver that little liver tissue remained. The proliferated cells were of large-pale-nuclear cells, many of which showed mitosis (Figs. 24 and 25).

Spleen: 7 g. Moderately swollen. Periarterially and surrounding the veins, large-pale-nuclear cells prominently proliferated side by side. Around the sheathed arteries, a proliferation of the same kind of cells was also noted. The character of each focus was always dissimilar; some showed superior staining, and some had a regular margin and were thinly bordered with fibrous cells.

Kidneys: 15.5 g. Remarkably swollen. There were many large or small foci of large-pale-nuclear cells. Although the relation to the blood vessels was not always distinct, it was certain that there were features which made it possible to judge that the large foci were formed by a conglomeration of the foci which proliferated in the interstitium.

Lungs: In the submucosa of the parabronchia there were two lymphatic apparatus of which the component cells were all large-pale-nuclear ones.

Proventriculus: One of the lymphatic apparatus in the submucosa had a tendency to be large-pale-nuclear cells in the cellular composition.

Bursa of Fabricius: The proper tissue structures were indistinct. Foci of large-pale-nuclear cells, which were bordered by fibrous cords, were noticeable.

Adrenals: In one lymphatic apparatus in the peritoneum, all of the component cells had a tendency to be large-pale-nuclear cells.

Ovaries: A few small foci composed of cells with large pale nucleus were present in the interstitial tissues. In some of the foci the cells were intensively stained (Cf. Figs. 22 and 23).

Bone marrow of the femur: Many large and small foci of large-pale-nuclear cells.

Discussion In the liver, spleen, kidneys, bursa of Fabricius and bone marrow of the femur, there was intensive proliferation of large-pale-nuclear cells. Some foci in the spleen were bounded on the surrounding tissues by thin fibrous tissues. In the lungs, proventriculus, peritoneum, etc. the cells which composed the lymphatic apparatus had a tendency to be large-pale-nuclear ones.

No. 8

No. 1362 Group 3, White Leghorn×Plymouth Rock, ♀, 188 days (1800 g.), Killed

Liver: 31 g. There were scattered with a large number of small foci principally composed of large-pale-nuclear cells. Some of the foci showed fairly sharp circumferences. In the subcapsule, one extra-ordinarily large focus was observed, which differed from the small foci only in size. Despite the size of the foci, some of them had localized accumulations of lymphocytes (Figs. 26~28; Cf. Figs. 1~4).

Spleen: 3g. There were scattered with generally small foci of large-pale-nuclear cells with distinct circumferences like the lymph follicles. In the subcapsule, there was one focus, 0.3 cm in long diameter.

Bursa of Fabricius: The proper tissue structures had disappeared and were replaced with masses of large-pale-nuclear cells.

Bone marrow of the femur: Fairly large foci of large-pale-nuclear cells were observed.

Skin: Two large foci of large-pale-nuclear cells, 0.3 cm in diameter, bounded by fibrous cords, were observed in the subcutaneous adipose tissues. The foci illustrated (Figs. 29 and 30) were small solitary ones which were near the large foci. In the Fig. 29, 1/3 of the upper focus was an accumulation of lymphocytes.

Discussion The proliferation of large-pale-nuclear cells in the liver and spleen was rather weak in general. However, it should be noted that, in the liver, spleen, bone marrow of the femur and subcutis, fairly large foci were present, and that the whole bursa of Fabricius was replaced by masses of large-pale-nuclear cells.

No. 9

No. 1679 Group 1, White Leghorn, ♂, 137 days (1150 g.), 30 hours post mortem

Liver: 172 g. Intensively swollen. There were a large number of cellular foci of various sizes, the largest 0.5 cm in long diameter. Each focus existed independently, unaccompanied with any distinct fibrous tissue around itself. The cells which composed the foci were rounded; the nuclei showed pyknosis or rhexis; around the nuclei the Hof was recognizable; the cytoplasm was faintly and homogeneously stained.

Spleen: 17 g. Swelling was conspicuous. Histological findings were similar to those of the liver. However, the circumferences of the cellular foci were more regular than those of the liver (Figs. 31 and 32).

Kidneys: 9 g. Irregular-shaped, minute cellular foci were scattered. The cellular element of the foci resembled large-pale-nuclear cells; the cytoplasm was somewhat intensive in staining; mingled with cells with degenerative nucleus.

Proventriculus: Cellular elements in the lymphatic apparatus of the submucosa were principally composed of large-pale-nuclear cells.

Jejunum: Cellular elements in the lymphatic apparatus were principally composed of large-pale-nuclear cells. Many of the cells showed degeneration.

Cecum: The lymphatic apparatus were swollen; the cellular element was identical with that described for the jejunum (Figs. 33 and 34).

Colon: As just above.

Bursa of Fabricius: The proper tissue structures were lost and were replaced by large masses of rounded large-pale-nuclear cells.

Thymus: Replaced by masses of rounded large-pale-nuclear cells.

Oil gland: The lymphatic apparatus situated in the capsule was replaced by masses of

large-pale-nuclear cells.

Bone marrow of the femur: There were foci of large-pale-nuclear cells; the circumferences of the foci were indistinct.

Discussion The proliferation of large-pale-nuclear cells was conspicuous in the liver, spleen, bursa of Fabricius, and cells which composed the lymphatic apparatus of the proventriculus, colon and oil gland were also the same kind of cells. The rounding of the cells seemed to be post mortem changes.

No. 10

No. 1850 Group 2, White Leghorn×Plymouth Rock, ♀, 324 days (1350 g.), Killed

Liver: 167 g. Swelling was conspicuous. There were a large number of foci composed of large-pale-nuclear cells extended over whole section preparations. The individual foci were about 0.1 cm in diameter. The foci were arranged in moniliform around the veins and in the subcapsule. The circumference of each focus was regular as a whole, unaccompanied with a significant increase in argyrophile fibers.

Spleen: 3 g. Slightly swollen. Microscopical findings were similar to those described for the liver; there were similar foci in the capsule and in the peritoneum (Figs. 35 and 36).

Kidneys: 16 g. Remarkably swollen. Microscopical findings were nearly similar to those described for the liver. It was pointed out that the foci conglomerated reciprocally.

Oesophagus: Some of the lymphatic apparatus in the lamina propria were replaced by masses of large-pale-nuclear cells.

Proventriculus: Microscopical findings were nearly similar to those of the oesophagus, but stronger in degree.

Small intestine: The lymphatic apparatus in the submucosa and muscularis were turned into foci of large-pale-nuclear cells.

Large intestine: As just above. The same lymphatic apparatus were also observed in the peritoneum in large numbers.

Bursa of Fabricius: The proper tissue structures were lost and foci of large-pale-nuclear cells were present side by side.

Adrenals: In and beneath the capsule and in the peripheral peritoneum, there were many foci of large-pale-nuclear cells.

Oviducts: Some foci such as described just above were present in the submucosa and peripheral peritoneum.

Ovaries: In the interstitial tissues, there were widespread or focal proliferations of large-pale-nuclear cells.

Thyroid glands: A few of large-pale-nuclear cells were observed.

Bone marrow of the femur: There were large-pale-nuclear cell foci with fairly distinct circumferences. Staining of the cells was fairly intensive.

Discussion In the liver, spleen, kidneys and bursa of Fabricius, there were vigorous proliferations of large-pale-nuclear cells, which had a multicentral character and no tendency to large focus formation. In the other organs and in the peritoneum, the same kind of cellular proliferation was observed.

No. 11

No. 1757 Group 2, White Leghorn×Plymouth Rock, ♀, 200 days (1800 g.), Killed

Liver: 103 g. Remarkably swollen. Conspicuous proliferations of large-pale-nuclear cells surrounded the veins like a mantle. In addition, there were small, scattered foci, and two large foci of about 0.5 cm in diameter. The circumferences of the foci were indistinct (Cf. Figs. 26~28).

Spleen: 6 g. Slightly swollen. Cellular foci arrayed in moniliform were observed periarterially and perivenously. Cellular foci were also present in the intima of the veins in very small numbers. The cellular elements of the foci belonged to large-pale-nuclear cells, but the staining of the cells and the density of the foci were not always uniform.

Kidneys: 23 g. Remarkably swollen. Large or small foci of large-pale-nuclear cells occupied nearly the whole kidneys. The proper tissue element was buried in the large foci.

Heart: 8.5 g. In a portion of the subpericardium, two adjacent lymphatic apparatus were present, and one of these was occupied by large-pale-nuclear cells.

Lungs: In the submucosa of the respiratory tract and the neighbouring interstitium, large-pale-nuclear cells proliferated and formed a mass of about 0.2 cm in diameter. The cells were intensively stained.

Oesophagus: Some of the lymphatic apparatus in the lamina propria were composed of large-pale-nuclear cells.

Proventriculus: As just above.

Duodenum: In the muscularis and in the peripheral peritoneum, there were many foci of large-pale-nuclear cells. Staining of the cells was fairly intensive.

Large intestine: As just above.

Bursa of Fabricius: The proper tissue structures disappeared and were replaced by masses of large-pale-nuclear cells.

Peritoneum: In the peritoneum of the organs and in the parietal peritoneum, there were many foci of large-pale-nuclear cells.

Adrenals: Foci of large-pale-nuclear cells were observed in the capsule.

Thymus: Throughout the whole section preparations, proliferation of large-pale-nuclear cells was very conspicuous.

Thyroid glands: In the interstitium, large-pale-nuclear cells proliferated forming network structures.

Oviducts: Fleck-form foci of large-pale-nuclear cells were observed in the submucosa. The proper tissue structures were undisturbed.

Ovaries: Macroscopically, showed a grayish-yellow, somewhat hard mass, the size of a hen's egg. Proliferation of large-pale-nuclear cells was very intensive. In some parts of the ovaries, the proper tissue structures were distinct (Figs. 37~39).

Bone marrow of the femur: There were foci of large-pale-nuclear cells. Staining of the cells was intensive.

Skin: In the subcutis, a cellular mass of about 0.6 cm in diameter was observed. It was an agglomeration of knobby foci of large-pale-nuclear cells.

Discussion Proliferation of large-pale-nuclear cells was remarkable in the kidneys, bursa of Fabricius and thymus. Especially, in this case, the development of foci of large-pale-nuclear cells in the peritoneum and the formation of a large massive focus in the ovaries were outstanding.

No. 12

No. 1717 Group 2, White Leghorn×Plymouth Rock, ♀, 176 days, 24 hours post mortem

Liver: 211 g. Swelling was conspicuous. Nearly all of the tissues were filled with roundish cellular foci multacentrally. Many of the foci had fairly clear circumferences, and the cellular element belonged to large-pale-nuclear cells. But all the cells were rounded, and had a hof around the nucleus and degenerative nuclei (post mortem changes).

Spleen: 5.5 g. Swollen. Principally periarterial, multiple cellular foci, identical with those of the liver. There was no significant development of argyrophile fibers around the foci.

Kidneys: 10 g. Sporadically in the interstitium, large-pale-nuclear cells were slightly proliferated, forming a fine network.

Heart: In the auricular myocardium, a small number of large-pale-nuclear cells were scattered, intermingled with lymphocytes.

Lungs: The lymphatic apparatus in the submucosa of the respiratory tract and the interstitium were slightly hyperplastic. The cellular element was composed of rounded large-pale-nuclear cells.

Oesophagus: Some of the lymphatic apparatus in the lamina propria were replaced by large-pale-nuclear cells.

Gizzard: A small number of large-pale-nuclear cells were scattered in the intermuscular tissues of the muscularis.

Cecum: The lymphatic apparatus in the submucosa were hyperplastic and rich in large-pale-nuclear cells.

Bursa of Fabricius: The proper tissue structures were generally distinct, but in the cortex and medulla of each lobule, the cellular element was replaced by large-pale-nuclear cells (Figs. 40~42).

Oviducts: Partially, there were some foci of large-pale-nuclear cells in the submucosa.

Ovaries: The proper tissue structures were generally obvious, but in the interstitium large-pale-nuclear cells proliferated.

Thymus: The proper tissue structures were generally clear, but cells of the parenchyma were replaced by large-pale-nuclear cells.

Bone marrow of the femur: There were multiple, roundish cellular foci identical with those of the liver, spleen and others.

Discussion In the bursa of Fabricius, thymus and others, large-pale-nuclear cells conspicuously proliferated, generally corresponding to the lymphatic tissues. The same kind of cells were slightly scattered in the interstitium of the kidneys and heart.

No. 13

No. 1802 Group 2, White Leghorn×Plymouth Rock, ♀, 247 days (1440 g.), Killed

Liver: 198.5 g. Swelling was conspicuous. There were many cellular foci with roundish shape, various sizes and very distinct circumferences. The element of the foci was composed of large-pale-nuclear cells. In general, the cells had poor cytoplasm and the nuclei showed intensive staining. The circumference of each focus was surrounded by a thin layer of fibrous cells (Figs. 43 and 44).

Spleen: 4.5 g. Slightly swollen. Roundish foci were scattered periarterially. The

character of the foci resembled that of the liver, but the staining of the nuclei and the condition of circumferences of the foci were superior to those of the liver (Figs. 45 and 46).

Kidneys: 10 g. Slightly swollen. A large number of roundish cellular foci were observed. The circumferences of the foci were not always sharp, and staining of the component cells was weaker than that of the liver (Cf. Figs. 51~53).

Heart: In the adipose tissues of the coronary areas, there was one focus of large-pale-nuclear cells. Staining of the cells was feeble.

Lungs: The lymphatic apparatus in the submucosa of the respiratory tract were hyperplastic and abounded in large-pale-nuclear cells. Staining of the cells was intensive.

Oesophagus: The lymphatic apparatus situated in the lamina propria were occupied totally or partially with large-pale-nuclear cells.

Proventriculus: The lymphatic apparatus in the submucosa were hyperplastic and filled with large-pale-nuclear cells. Staining of the cells was intensive.

Large intestine: The lymphatic apparatus in the submucosa were composed of large-pale-nuclear cells. Staining of the cells was feeble.

Bursa of Fabricius: The proper tissue structures were preserved. The element was replaced with large-pale-nuclear cells. Staining of the cells was feeble.

Pancreas: One lymphatic apparatus composed of large-pale-nuclear cells was observed in the peritoneal tissues. Staining of the cells was feeble.

Adrenals: In the subcapsule and in the surrounding peritoneal tissues, foci of large-pale-nuclear cells were observed in large numbers.

Oviducts: In the submucosa a small number of foci composed of large-pale-nuclear cells were observed. Staining of the cells was feeble.

Ovaries: The proper tissue structures were distinct, but there were many foci of large-pale-nuclear cells in the interstitium. Staining of the cells was intensive.

Thymus: There were many foci composed of large-pale-nuclear cells which were feebly stained.

Bone marrow of the femur: There were roundish cellular foci. The character of the foci was quite similar to that in the spleen (Figs. 47 and 48).

Discussion In the liver, spleen, bone marrow of the femur, kidneys and others, there were many roundish foci composed of large-pale-nuclear cells. In the other organs, the elements of the lymphatic apparatus were composed of the same cells. It should be noted here that the degree of encapsulation of the cellular foci and the staining of the component cells differed decidedly in each organ.

No. 14

No. 1436 Group 3, White Leghorn×Plymouth Rock, ♀, 251 days (1650 g.), Killed

Liver: 159.5 g. Swelling was conspicuous. There were many, multicentral cellular foci, frequently surrounding the veins. They were always of irregular shape, and their circumferences were not sharp. The cellular element of the foci was composed of large-pale-nuclear cells with feeble staining.

Spleen: 6.5 g. Swollen. There were a large number of roundish cellular foci, periarterially, around the veins and in the capsule. All of the foci had distinct circumferences and thin layers of fibrous tissues. The cellular element of the foci was large-pale-nuclear cells

with intensive staining (Figs. 49 and 50).

Kidneys: 29.5 g. Remarkably swollen. There were many somewhat irregular-shaped, large or small cellular foci. The character of the foci was similar to the liver. In the capsule, there were also similar cellular foci (Figs. 51~53).

Oesophagus: Some lymphatic apparatus in the lamina propria were composed of large-pale-nuclear cells.

Proventriculus: In the submucosa, the lymphatic apparatus were hyperplastic and rich in large-pale-nuclear cells.

Duodenum: Some lymphatic apparatus of the submucosa were filled with large-pale-nuclear cells.

Jejunum: The lymphatic apparatus in the submucosa were very hyperplastic. The cellular element was composed of large-pale-nuclear cells, and the staining of the cells varied locally. The same cellular foci were also abundant in the peritoneum.

Cecum: As just above.

Colon: The lymphatic apparatus of the mesentery were composed of large-pale-nuclear cells.

Pancreas: There was one cellular mass, 0.3 cm in diameter. It was formed by an aggregation of small foci composed of large-pale-nuclear cells. A little pancreatic tissues were included in the mass. In the mesentery there were many foci of large-pale-nuclear cells.

Adrenals: In the subcapsule, there was a cellular focus of large-pale-nuclear cells. There were many cellular foci in the mesentery; the character of these foci was the same as the subcapsular one.

Oviducts: In the submucosa and submucosa and muscularis, there were a small number of foci of large-pale-nuclear cells. In the uterine region, one walnut-sized cellular focus with the same character was observed.

Ovaries: Walnut-sized. The proper tissue structures could be observed, but the interstitium was nearly occupied with foci of large-pale-nuclear cells. In each focus there were areas which were intensely stained and areas which were feebly stained.

Thymus: The proper tissue structures remained. There was one roundish cellular focus, 1 cm in diameter. The cellular element of the focus was large-pale-nuclear cells; staining of the cells varied locally.

Thyroid glands: There were two cellular foci, one in the interior and the other in the capsule, composed of large-pale-nuclear cells. Staining of the cells was feeble.

Bone marrow of the femur: Scattered with large or small cellular foci. The cellular element of the foci was large-pale-nuclear cells and the staining of the cells was feeble.

Skin: In different areas of the skin, various-sized knobby masses were observed in the subcutis: the size of a cherry in the part covering the left clavicle, of a sparrow's egg in the right femur, of a thumb-tip in the lateral of left tibia, of a soybean seed in the thoracic vertebral column, of a small sparrow's egg and a thumb-tip in the lumbar vertebral column and of a walnut in the ventral of tail plan. All the masses were foci of large-pale-nuclear cells and were run through in all directions by fibrous tissue cords. Staining of the cells was feeble.

Discussion Macroscopically visible foci were observed on the pancreas, oviducts, thymus

and various skin areas. In the other parenchymatous organs and the peritoneum, large-pale-nuclear cell foci were also present multilocally. In the character, the foci in the spleen possessed a distinct circumference and a thin fibrous layer. Staining of cells of the foci was intensive. In other foci, the circumferences were not always distinct and the staining of the cells varied locally.

No. 15

No. 1767 Group 1, White Leghorn, ♂, 221 days (1800 g.), Killed

Liver: 81 g. Swollen. As an accessory finding, the interstitium was intensively inflammatory and fibrous. Fairly large foci of large-pale-nuclear cells were embedded in the chronically inflammatory tissue. Staining of the cells was feeble.

Spleen: 6 g. Swollen. Fairly large foci of large-pale-nuclear cells were scattered periarterially. Each focus had a very distinct circumference and a thin layer of fibrous tissue. Staining of the cells was fairly intensive (Figs. 54 and 55).

Kidneys: 9.5 g. There were a mere few small cellular foci of fairly regular shape. Cells of the foci were composed of feebly stained large-pale-nuclear cells.

Lungs: In the submucosa of the respiratory tract, there were foci of hyperplasia of the lymphatic apparatus, approximately 0.1 cm in diameter. The cellular element of the foci was large-pale-nuclear cells; staining of the foci was large-pale-nuclear cells; staining of the cells varied locally (Figs. 56 and 57).

Proventriculus: As an accessory finding, fibrous, inflammatory foci were observed in the submucosa. The foci included a small number of large-pale-nuclear cells.

Duodenum: In the submucosa there was hyperplasia of the lymphatic apparatus. The cellular elements of the apparatus were mostly of large-pale-nuclear cells. Staining of these cells was intensive.

Jejunum: Some of the lymphatic apparatus of the submucosa were filled with large-pale-nuclear cells.

Ileum: In the submucosa intensive hyperplasia of the lymphatic apparatus was observed. The cellular elements of the apparatus were replaced by large-pale-nuclear cells. Staining of these cells was feeble.

Cecum: As just above.

Colon: Some of the lymphatic apparatus of the submucosa were filled with large-pale-nuclear cells.

Adrenals: In the capsule there was one focus composed of large-pale-nuclear cells.

Bone marrow of the femur: As an accessory finding, there were foci of chronic fibrous inflammation. Independently of these, there were a few of large-pale-nuclear cells; the foci had a thin fibrous layer; staining of the cells was intensive.

Discussion The foci of large-pale-nuclear cells in the spleen and bone marrow of the femur had a thin layer of fibrous tissue. The staining of the cells of the foci was generally intensive. In addition, in the alimentary tract and in the others, there was conspicuous hyperplasia of the lymphatic apparatus and the component cells were markedly replaced by large-pale-nuclear cells.

No. 16

No. 1785 Group 2, White Leghorn×Plymouth Rock, ♀, 223 days (1670 g.), Killed

Liver: 142 g. Remarkably swollen. There were a large number of various-sized foci, including fairly large ones, of large-pale-nuclear cells. Generally, the circumferences of the foci were distinct, but they had no layer of fibrous tissue around them. However, in the areas in which a slight chronic interstitial inflammation was observed as an accessory finding, it appeared that the foci had been encapsulated by fibrous tissue.

Spleen: 4.5 g. Swollen. Scattered with large or small cellular foci with sharp circumferences. The foci were composed of large-pale-nuclear cells and had a thin layer of fibrous tissue around them. Staining of the cells was fairly intensive (Figs. 58 and 59).

Kidneys: 8.5 g. There were large or small cellular foci. All of the foci had clear circumferences but no fibrous layer around them. The cellular element of the foci was composed of large-pale-nuclear cells intensively stained.

Lungs: In the interstitial areas, there was one lymphatic apparatus, which was replaced by large-pale-nuclear cells.

Oesophagus: One of the lymphatic apparatus in the lamina propria was completely and another partially replaced by large-pale-nuclear cells. In the peripheral adipose tissues there were three lymphatic apparatus of the same character.

Proventriculus: In the submucosa the lymphatic apparatus was hyperplastic. In the apparatus, foci of large-pale-nuclear cells were embedded in lymph follicle-like structure.

Intestine: In the serosa and submucosa, there were lymphatic apparatus replaced by large-pale-nuclear cells.

Cecum: In the serosa there were somewhat many lymphatic apparatus of which the cellular element was replaced by large-pale-nuclear cells.

Cloaca: In the surrounding connective tissues, there were many cellular foci. All the foci were composed of large-pale-nuclear cells.

Pancreas: In the surrounding mesentery, there were lymphatic apparatus of which the cellular element was replaced by large-pale-nuclear cells.

Adrenals: In the capsule there were many small cellular foci composed of large-pale-nuclear cells.

Oviducts: In the submucosa and muscularis, there were cellular foci composed of large-pale-nuclear cells.

Ovaries: Partially, showed the normal tissue structures, but the majority were changed to compact tissue masses by proliferation of large-pale-nuclear cells.

Thymus: No proper tissue structures were observed. Foci of large-pale-nuclear cells intermingled with accumulation areas of lymphocytes.

Thyroid glands: In the subcapsule there were two foci of large-pale-nuclear cells.

Discussion The spleen was scattered with large-pale-nuclear cell foci with slight encapsulation. Although proliferation of large-pale-nuclear cells was vigorous in the liver, kidneys and thymus, it was difficult to observe encapsulation. In the alimentary tract and the others, it was obvious that the composition of the lymphatic apparatus had been replaced by large-pale-nuclear cells.

SUMMARY OF THE FINDINGS

There is no doubt that all of the cases just described, from the findings, are suffered from avian visceral lymphomatosis.

The microscopical findings which were observed in all the present cases may be summarized as follows:

Hyperplasia of the lymphatic tissue

- a. "Abnormal hyperplasia" of the lymphatic tissue
- b. "Immaturation"
- c. "Maturation"
- [d. Lymphatic tissue outside the question]

In the first place, the authors will explain the terms used.

"Abnormal hyperplasia" of the lymphatic tissue This is hyperplasia of the lymphatic tissues in which the principal cellular element was composed of large-pale-nuclear cells repeatedly called in the preceding descriptions. The cells was not identical with lymphoblasts, and the authors consider that the cells may be appropriately called germ cells in the lymphatic tissues. The cells of this kind have frequently been called lymphoid cells in the literature (v. discussion).

"Immaturation" and "Maturation" Both terms indicate such histological features as the abnormally hyperplastic lymphatic tissues were composed of large-pale-nuclear cells and had a neoplastic character. In "maturation", it is characteristic that the hyperplastic tissues show histological features suggestive of the lymph follicles (v. discussion).

Next, the authors illustrate the findings in the three groups. In group 1 (Chart 1) which includes 123 cases, 6 were cases of "abnormal hyperplasia" of the lymphatic tissues, which were only in the chicken stage. Two cases of "immaturation" and one of "maturation" were detected only in the adult stage. In the final experimental phase, no abnormal cases were detected. In general, the same tendency could be also observed in groups 2 and 3 (Charts 2 and 3). From all of the cases illustrated, also, one case of neural lymphomatosis from the December cases of group 1, one case of erythroblastosis from the June cases in the terminal phase of the experiment in group 2, and two cases of neural lymphomatosis from the October cases of group 3 were also detected. Other than these, there were no remarkable infectious diseases in cases which died or were killed by reason of accidents.

DISCUSSION AND CONCLUSION

Lymphatic tissue in aves—its location, size and cellular element

Although one has no need to refer to information by DANCHAKOFF and MJASSOJEDOFF, in aves, microscopical lymphatic tissues are present all over the body

in the connective tissues, particularly in having relation to the blood vessels. In the present investigation also, the authors could observe this condition in a large number of fowls differing in breed, age and sex. In various aves other than fowls, scrupulous investigations of the lymphatic tissues of the pancreas have been done by LUCAS and his co-workers^{15,16,17}). Discussing the works concerning avian visceral lymphomatosis, not a few investigators have considered that the existence of the lymphatic tissues in aves is abnormal from the outset and have lightly named them "lymphoid tissues" or "lymphoid foci" (in such occasions as tissues took neoplastic character, the cellular element has been well investigated). As an exception, in the case of the ectopic lymphoid tissues reported by LUCAS, scrupulous investigation seems to have made on cellular element in parallel with location and size of the localized areas. In other words, localized areas are suitably called "lymphoid", granting that the areas are slightly-built, in so far as principal part of the cellular element composing the areas is the "large mononuclear monocytes" named by MATHEWS et al. or the "large-pale-nuclear cells" by the authors of this paper.

Relation between "abnormal hyperplasia" of the lymphatic tissues and avian visceral lymphomatosis

The "abnormal hyperplasia" of the lymphatic tissue giving rise to discussion now differs from the reactive condition of reticulo-endothelial tissue in the lymphatic tissues as a response to pathogen invasion in cases of infectious disease in mammalia. FURTH has stated that "It is often impossible to determine whether the neoplasms caused by the virus of Strain 2 are of endothelial or mesenchymal origin," Judging from the character of cells, it is reasonable to consider that the origin of cells which were observed in the "abnormal hyperplasia" in the present disease may be the mesenchyma; it is with such a meaning that the authors have stated that the cells may be called germ cells. Differentiated reticulo-endothelial tissue should be outside the scope of this discussion. This was confirmed by examining stamp and smear preparations to which particular stainings were applied in each case of "immaturation" and "maturation".

Judging from the location, growth conditions, and in consideration of the time factor, the authors would like to infer that the foci of "abnormal hyperplasia" of the lymphatic tissues are able to develop up to those of "immaturation" and "maturation". Nearly the same thought has been also stated by LUCAS. In the literature, among the workers who observed naturally occurring cases, PAYNE and BRENEMAN have used the term "potential neoplasms" in their studies of the lymphoid areas in the endocrine glands of fowl, SUGANO et al. have stated that "in so-called lymphomatosis, foci of cellular accumulation are founded on formation in locus.", and HORIUCHI has also mentioned that "tumor which developed in the Glisson's capsule" . These must not be overlooked. Among the workers who studied

experimentally, FURTH has stated that "..... cells may be stimulated by the same virus.", and DENINGTON et al. have reported that "Even 24 days after inoculation—of lymphoid tumor filtrate—the number of so-called normal lymphoid areas was double that found in the control birds. At 100 days it was five times as great." BIGGS has expressed in such a manner as "..... that it is reasonable to look on the so-called ectopic lymphoid areas as a normal expression of lymphoid tissue which may become hyperplastic or even neoplastic at different stage of lymphoid disease".

On the other hand, surveyed the studies of transmissibility, passage and tissue culture of the viral agents and electron microscopy of the viral agents (OLSON, BURMESTER et al.^{2,3,4}), DAVIS and DOYLE, EL DARDIRY et al., EYSTONE, FONTES et al., SHARPLESS et al., and DMOCHOWSKI), it was disclosed that the fact that no attention has been given to the problem of the pathogenesis, except that EYSTONE has stated "There was no indications that the general lymphoid tissues of the body became neoplastic". It may safely be said that the "abnormal hyperplasia" of the lymphatic tissues in the present cases is, from the histological finding at this stage, indivisible from avian visceral lymphomatosis, and that the hyperplasia has developed on the basis of the normal lymphatic tissues. The hyperplasia is, according to LUCAS¹⁵), the feature which belongs to the systemic phase.

Problem of metastasis

In the facts which were first clarified through the present experiment, it is included that the majority of the abnormally hyperplastic lymphatic tissues were observed in the chicken stage. On this occasion, as has been ascertained by LUCAS and his co-workers, it should be brought up for consideration that the manifestations may be different in different individuals even if a same agent affects the individuals at the same stage. In other words, it matters little even if field materials, etc. of which the histological findings contradict the present result are experienced. The authors would like to refer that LUCAS and BREITMAYER¹⁷) have put forward an very interesting idea, the host-pathogen relationship. Judging from the fact that for the most part foci of "abnormal hyperplasia" of the lymphatic tissues have been lack in the adult stage, it is inferred that the majority of the individuals which developed "abnormal hyperplasia" of the lymphatic tissues in the chicken stage become to show features of "immaturation" or "maturation".

Among the investigators who performed experimental studies, EL DARDIRY et al. and EYSTONE have clearly used the term metastasis, and have shown the results that both resistant and susceptible chicken or chick lines developed metastasis. Strictly speaking, grappling with a vast number of experimental cases, to examine each focus histologically is a great deal of laborious work, but they have not described the examination data. And in truth, it is to be attended with a marked difficulty to decide whether each focus which grew neoplastically is metastatic

one or not, as has also been stated by LUCAS and BREITMAYER¹⁷⁾. LUCAS and BREITMAYER¹⁷⁾ even have expressed that "Experiments are need to determine whether the agent of lymphomatosis can produce lymphocytomata in birds which are devoid of ectopic lymphoid foci". In this occasion, it is conceived an idea that germfree chicken should be submitted for experiment. However, after all, it is impossible to consider separated lymphatic tissues from experimental chickens, although, according to THORBECKE et al, "The lymphoid tissue of intestinal wall showed the most pronounced differences between germfree and conventional". In the result of the present investigation, it should be remembered that the foci which showed "immaturation" or "maturation" were closely related to the lymphatic tissues extending over the whole body of chickens, i. e. in the spleen, liver, ovaries, kidneys and also in the submucosa or the subserosa, etc.; the authors consider that it may be permitted to regard such features as what developed into neoplastic features started from "abnormal hyperplasia" in situ. It is natural that there was such a feature as, in the liver etc., hyperplastic cells were regarded as ones which proliferated intracanalicularly. The authors do not deny at all the fact of the existence of metastasis in transmission experiments, but the authors can only know a very mere few as to its detailed findings. In addition, the authors are uneasy about the point that many investigators who did experimental studies appear not to paid much attention to the "abnormal hyperplasia" of the lymphatic tissues such as was observed in the present investigation. The authors, however, have no intention of excluding metastatic focus from neoplastic tissues, and also have no complete persuasion on such an opinion. For the time being, it is prudent to deal with the features of "immaturation" and "maturation" in the lymphatic tissues in the present materials as processes belonging to the neoplastic phase against the systemic phase, as mentioned by LUCAS¹⁵⁾. Thinking of it, the fact that ectopic lymphoid tissues can display very vigorous proliferation in avian visceral lymphomatosis was an actuality; at the same time, the authors could not help being aware of the state under which the fowl's body well withstood such a condition.

"Developing into organoid" of neoplastic tissue

In the literature, many morphological classifications of neoplastic tissues have been described, which are principally restricted to the liver and spleen. Among the classifications there is the form which expressed as nodular or alveolar. It seems that the form included a feature which corresponds to our "maturation", namely "developing into organoid" of the abnormally hyperplastic lymphatic tissues. The authors would like to attach great importance to the fact that in the present investigation "maturation" was only observed on materials autopsied after a prolonged examination period. Judging from the very vigorous hyperplasia of the lymphatic tissues, the authors for the present adopted the idea of a neoplastic

phase, and would like to consider that the phase may be terminated by "developing into organoid". Thus, the opinion of the pathogenesis of avian visceral lymphomatosis becomes more unequivocal.

In neoplastic tissues secondary nodules were occasionally embedded; the authors regard the nodules as pre-existing tissues.

Furthermore, the authors would like to call attention to the fact that there were many birds which showed no abnormal findings in the lymphatic tissues after the period at which cases of "maturation" occurred. It has hitherto been said among poultry raisers that a way to make a chicken group resistant to avian visceral lymphomatosis is to obtain breeding birds from fertile eggs after molting season. The present results should seem to support such an opinion. In a further study, the authors should like to obtain trustworthy data by further prolonging the experimental period.

On methodology of pathogenetical investigation

Several kinds of viral agents have been introduced to the academic circles as pathogens of avian visceral lymphomatosis. According to EL DARDIRY et al., BURMESTER et al. and DMOCHOWSKI, those agents are not always pure from the viewpoint of virology. Also those pathogenecities are not stable, judging from the results of various experiments using those agents. There were also experiments stressing the susceptibility of the chicken used (EL DARDIRY et al. and EYESTONE). As the authors have already discussed, however, when avian visceral lymphomatosis is investigated, unless the lymphatic tissues in the host are taken into consideration, it is probably impossible to expect complete results, even if resistant or susceptible chickens are used, or viral agents are used properly. It seems that the objective of the experiment of EL DARDIRY et al. consist in that to investigate resistance or susceptibility by transplantation experiment is economical of time. However, the authors cannot express their approval of dealing with the disease by only observing life and death or gross visible tumors. In the future investigation of this field, it is necessary to adopt such a method as the authors employed here. Through such an attempt, in other words through reaching the truth of the general viewpoint on naturally occurring avian visceral lymphomatosis, it is believed that the investigation of susceptibility of chicken becomes possible.

Conclusion

1) Avian visceral lymphomatosis is a disease which starts from "abnormal hyperplasia" of the lymphatic tissue, subsequently develops the feature of "immaturation" and is terminated by the feature of "maturation". 2) Based upon the idea of the host-pathogen relationship, the comparison of susceptibilities of hereditarily close chick lines can be nearly perfectly studied using the method given in the present investigation.

REFERENCES

- 1) BIGGS, P. M. (1956): *Vet. Rec.*, **68**, 525
- 2) BURMESTER, B. R. & G. E. COTTRAL (1947): *Cancer Res.*, **7**, 669
- 3) BURMESTER, B. R. & E. M. DENINGTON (1947): *Ibid.*, **7**, 779
- 4) BURMESTER, B. R., W. G. WALTER, M. A. GROSS & A. K. FONTES (1959): *J. nat. Cancer Inst.*, **23**, 277
- 5) DANTCHAKOFF, V., (1916): *Anat. Rec.*, **10**, 483
- 6) DAVIS, O. S. & L. P. DOYLE (1947): *Amer. J. vet. Res.*, **8**, 103
- 7) DENINGTON, E. M., A. M. LUCAS, B. R. BURMESTER & G. E. COTTRAL (1952): *Poult. Sci.*, **31**, 913
- 8) DMOCHOWSKI, L. (1959): BIESTER-SCHWART's *Disease of Poultry*, 4th Ed., 429, Iowa State
- 9) EL DARDIRY, A. H., N. F. WATERS & G. E. COTTRAL (1952): *Poult. Sci.*, **31**, 523
- 10) EYESTONE, W. H. (1953): *Amer. J. vet. Res.*, **14**, 594
- 11) FONTES, A. K., B. R. BURMESTER & P. E. ISELER (1957): *Poult. Sci.*, **36**, 1117
- 12) FURTH, J. (1934): *J. exp. Med.*, **59**, 501
- 13) HORIUCHI, T. (1961): *Jap. J. vet. Sci.*, **23**, 227
- 14) LUCAS, A. M. (1949): *Amer. J. Path.*, **25**, 1197
- 15) LUCAS, A. M. (1951): *Poult. Sci.*, **30**, 116
- 16) LUCAS, A. M. & J. B. BREITMAYER (1949): *Ibid.*, **28**, 436
- 17) LUCAS, A. M. & J. B. BREITMAYER (1950): *Ibid.*, **29**, 450
- 18) LUCAS, A. M. & E. F. OAKBERG (1950): *Amer. J. Path.*, **26**, 75
- 19) MATHEWS, F.P. & F. L. WALKEY (1929): *J. Cancer Res.*, **13**, 383
- 20) MJASSOJEDOFF, S. W. (1926): *Folia haemat.*, **32**, 263
- 21) OAKBERG, E. F. (1950): *Poult. Sci.*, **29**, 420
- 22) OAKBERG, E. F. & A. M. LUCAS (1949): *Ibid.*, **28**, 675
- 23) OLSON, C. (1941): *Cancer Res.*, **1**, 384
- 24) PAYNE, F. & W. R. BRENNEMAN (1952): *Poult. Sci.*, **31**, 155
- 25) SHARPLESS, G. R., V. DEFENDI & H. R. COX (1957): *Ibid.*, **36**, 1156
- 26) SUGANO, S., M. INOUE, M. MAKITA & S. KATO (1954): *Jap. J. vet. Sci.*, **16**, Suppl., 151
- 27) THORBECKE, G. J., H. A. GORDON, B. WOSTMAN, M. WAGNER & J. A. REYNIERS (1957): *J. infect. Dis.*, **101**, 237

EXPLANATION OF PLATES

All figures were obtained from section preparations stained with hematoxylin-eosin. See text.

PLATE I

Fig. 1	No. 1	Liver	× 75
Fig. 2	No. 1	Liver	× 370
Fig. 3	No. 2	Liver	× 75

Fig. 4	<i>No. 2</i>	Liver	× 370
Fig. 5	<i>No. 2</i>	Bursa of Fabricius	× 6
Fig. 6	<i>No. 2</i>	Bursa of Fabricius	× 75
Fig. 7	<i>No. 2</i>	Bursa of Fabricius	× 370

PLATE II

Fig. 8	<i>No. 3</i>	Spleen	× 75
Fig. 9	<i>No. 3</i>	Spleen	× 370
Fig. 10	<i>No. 4</i>	Ileum	× 75
Fig. 11	<i>No. 4</i>	Ileum	× 370
Fig. 12	<i>No. 5</i>	Liver	× 75
Fig. 13	<i>No. 5</i>	Liver	× 370

PLATE III

Fig. 14	<i>No. 5</i>	Kidney	× 75
Fig. 15	<i>No. 5</i>	Kidney	× 370
Fig. 16	<i>No. 5</i>	Heart	× 75
Fig. 17	<i>No. 5</i>	Heart	× 370
Fig. 18	<i>No. 6</i>	Liver	× 75
Fig. 19	<i>No. 6</i>	Liver	× 370

PLATE IV

Fig. 20	<i>No. 6</i>	Spleen	× 75
Fig. 21	<i>No. 6</i>	Spleen	× 370
Fig. 22	<i>No. 6</i>	Ovary	× 75
Fig. 23	<i>No. 6</i>	Ovary	× 370
Fig. 24	<i>No. 7</i>	Liver	× 75
Fig. 25	<i>No. 7</i>	Liver	× 370

PLATE V

Fig. 26	<i>No. 8</i>	Liver	× 6
Fig. 27	<i>No. 8</i>	Liver	× 75
Fig. 28	<i>No. 8</i>	Liver	× 370
Fig. 29	<i>No. 8</i>	Skin	× 75
Fig. 30	<i>No. 8</i>	Skin	× 370
Fig. 31	<i>No. 9</i>	Spleen	× 75
Fig. 32	<i>No. 9</i>	Spleen	× 370

PLATE VI

Fig. 33	<i>No. 9</i>	Cecum	× 75
Fig. 34	<i>No. 9</i>	Cecum	× 370
Fig. 35	<i>No. 10</i>	Spleen	× 75
Fig. 36	<i>No. 10</i>	Spleen	× 370
Fig. 37	<i>No. 11</i>	Ovary	× 6
Fig. 38	<i>No. 11</i>	Ovary	× 75

Fig. 39 *No. 11* Ovary × 370

PLATE VII

Fig. 40 *No. 12* Bursa of Fabricius × 6

Fig. 41 *No. 12* Bursa of Fabricius × 75

Fig. 42 *No. 12* Bursa of Fabricius × 370

Fig. 43 *No. 13* Liver × 75

Fig. 44 *No. 13* Liver × 370

Fig. 45 *No. 13* Spleen × 75

Fig. 46 *No. 13* Spleen × 370

PLATE VIII

Fig. 47 *No. 13* Bone marrow of the femur × 75

Fig. 48 *No. 13* Bone marrow of the femur × 370

Fig. 49 *No. 14* Spleen × 75

Fig. 50 *No. 14* Spleen × 370

Fig. 51 *No. 14* Kidney × 6

Fig. 52 *No. 14* Kidney × 75

Fig. 53 *No. 14* Kidney × 370

PLATE IX

Fig. 54 *No. 15* Spleen × 75

Fig. 55 *No. 15* Spleen × 370

Fig. 56 *No. 15* Lung × 75

Fig. 57 *No. 15* Lung × 370

Fig. 58 *No. 16* Spleen × 75

Fig. 59 *No. 16* Spleen × 370

