



HOKKAIDO UNIVERSITY

Title	MORPHOLOGICAL STUDIES OF THE TRIFURCATE PORTIONS OF THE COMMON CAROTID ARTERIES AND THE SO-CALLED INTERCAROTID BONE IN THE HORSE
Author(s)	FURUHATA, Kitao
Citation	Japanese Journal of Veterinary Research, 12(3), 47-60
Issue Date	1964-09
DOI	https://doi.org/10.14943/jjvr.12.3.47
Doc URL	https://hdl.handle.net/2115/1796
Type	departmental bulletin paper
File Information	KJ00002369103.pdf



MORPHOLOGICAL STUDIES OF THE TRIFURCATE PORTIONS OF THE COMMON CAROTID ARTERIES AND THE SO-CALLED INTERCAROTID BONE IN THE HORSE

Kitao FURUHATA

*Department of Veterinary Anatomy,
Faculty of Veterinary Medicine,
Hokkaido University, Sapporo, Japan*

(Received for publication, June 10, 1964)

INTRODUCTION

In 1879 BINSWANGER first demonstrated that some swelling in the initial portion of the internal carotid artery is a normal phenomenon in humans. The same phenomenon was observed in mammals by TANDLER^{17,18)} and named the "sinus caroticus" or "bulbus caroticus". In Japan, the present author ('54) reported a detailed description of this phenomenon in dogs, especially emphasizing the presence of longitudinal smooth muscles in the subendothelial tissue of the sinus wall and also the presence of swelling at the root of the occipital artery. A detailed description of the carotid sinus in the horse was first reported by ARGAUD and DE BOISSEZON³⁾ in 1936 and subsequent observations were reported by DE BOISSEZON, OCHOTERENA, MEIJLING, and others, but these reports refer primarily to histological findings and to the nerve supply of the carotid body and the sinus, and the gross anatomical findings are given slight attention. In these reports, only ARGAUD and DE BOISSEZON²⁾ reported the presence of a small bone which they called "*Os intercarotidien*" in the horse. They described this bone as follows. The anlage of this bone develops in the embryonic period and ossification begins several months after birth, and the bone is always present in adult horses. However, the formative mechanism and the changes which occur in this bone with aging are still not completely understood.

Many Japanese investigators have studied the human carotid body and sinus, but there have been no reports of any investigation of these structures in other domestic animals with the exception of the present author's study of the dog ('54). The author hopes to fill this gap in the literature about the histology and macroscopical anatomy of this structure. He believes that he has obtained some significant results.

MATERIAL AND METHODS

The common carotid arteries were obtained from 43 horses (left and right arteries from

34 horses, right only from 4, and left only from 5) and 77 specimens of the trifurcate portion were prepared. Details are given in table 1.

TABLE 1. *Cases from which Specimens Were Obtained*

EXP. NO.	SEX	AGE	SIDE	EXP. NO.	SEX	AGE	SIDE
1	♂	3 Months	LR	23	♀	7 Years	LR
2	♀	"	R	24	♂	8 Years	LR
3	"	"	LR	25	♀	"	LR
4	♂	4 Months	LR	26	"	"	LR
5	"	2 Years	L	27	"	9 Years	LR*
6	"	"	L*R	28	"	"	LR
7	"	"	LR	29	"	11 Years	LR
8	♀	"	L	30	♂	12 Years	LR
9	"	"	LR	31	♀	"	R
10	"	"	LR	32	"	13 Years	LR
11	"	3 Years	L*R*	33	"	"	R
12	"	"	LR	34	♂	15 Years	L
13	♂	4 Years	LR	35	♀	"	R
14	♀	"	LR	36	"	"	LR
15	"	5 Years	LR	37	"	"	LR
16	"	"	LR	38	"	16 Years	LR
17	"	"	LR	39	"	17 Years	LR
18	"	6 Years	LR	40	"	"	LR
19	"	"	L	41	"	18 Years	LR
20	♂	7 Years	LR	42	"	"	LR
21	♀	"	LR	43	"	19 Years	LR
22	"	"	L	Total			77

* Abnormal specimens

L Specimen obtained from left side

R Specimen obtained from right side

After the fresh materials were fixed in 10% formalin solution, those fat tissues, nerves and connective tissues which were superfluous to the purpose of the investigation were carefully removed. Special consideration was given to avoid injury to the adventitia of the arteries and to the carotid body.

In addition to macroscopic observation of the external portions of the specimens, the lumen diameter of 10 different parts of the specimen was estimated in approximately 13 horses. Eight of those sections are shown in figure 1. The other two parts were the initial portions of the internal carotid and occipital arteries.

X-rays were taken with an ultrasoft X-ray apparatus (E type SOFTEX, KOIZUMI X-ray Co.)

with 80 V, 5 mA, for 3~5 sec. All specimens were X-rayed from the lateral side and were projected on FUJI X-ray film. The prints were enlarged twice. These prints were used to determine the presence of and to measure the dimensions of the bones. Five specimens were used for macroscopic observation of bones. The other five bones used for microscopic examination were decalcified in 10% nitric acid, embedded in celloidin and sectioned in series, or in some cases singly, in 30 μ sections which were then stained with hematoxylin-eosin. Eighteen specimens were prepared from 12 horses to determine the existence of cartilage corresponding to the bones.

RESULTS

A. Macroscopical Findings

In the 77 specimens examined, abnormal forms were observed in 4 specimens from 3 horses. The remaining 73 specimens had forms which were similar to the following general description. The abnormal forms are also described.

1) General Description of the 73 Normal Specimens

On the lateral wall of the guttural pouch, at the level of the ventral side of the atlas, the common carotid artery of the horse branches into three arteries, the external carotid, the internal carotid and the occipital. The external carotid artery is the largest of these branches. Usually, the common carotid artery continues straight from the external carotid artery while internal carotid and occipital arteries branch off from the common carotid artery at a definite angle.

From the lateral view of the branching portion, one may observe distinct swelling in the upper end of the common carotid artery and in the initial portion of the occipital artery. The present author could not find any references to this swelling in the occipital artery in any of the literature with the exception of his own report in the dog.

From the medial view one may observe a distinct swelling in the initial portion of the internal carotid artery. The carotid body is seen as a small ball in the dorso-medial portion of the initial portion of the occipital artery (Fig. 1).

2) Measurement of the Arterial Lumens

The author used 26 randomly chosen specimens from 13 adult horses to measure the diameters of the arterial lumens. The data obtained are given in table 2.

It is obvious that the dimension of the arterial lumen differs in different portions of the artery.

a) The common and external carotid arteries

The lower end of the stem of the common carotid artery is round and thick-walled and the lumen is relatively narrow, but the upper end swells suddenly in a funnel shape accompanied by districted regional dilation of the lumen. The diameter of this upper portion is twice that of the stem. The arterial wall is especially thin in the dorso-medial portion. The stem of the external carotid artery is somewhat narrower than that of the common carotid artery, but its root is larger.

b) The internal carotid artery

TABLE 2. *Lumen Diameters of the Arteries of the Trifurcate Portions (mm)*

LOCATIONS OF ARTERIES		LONG DIAMETER SHORT DIAMETER	
		$\bar{x} \pm s$ (min. ~ max.)	$\bar{x} \pm s$ (min. ~ max.)
Common carotid	Stem	4.3 ± 0.9 (3.0 ~ 7.0)	4.0 ± 0.7 (2.8 ~ 5.6)
	Branch into internal carotid artery	9.9 ± 1.2 (7.5 ~ 13.0)	7.5 ± 0.9 (6.0 ~ 9.2)
External carotid	Branch into occipital artery	5.1 ± 1.3 (3.5 ~ 9.3)	4.5 ± 0.8 (3.4 ~ 7.2)
	Stem	3.6 ± 0.9 (2.3 ~ 5.0)	3.3 ± 0.9 (2.1 ~ 6.3)
Internal carotid	Initial portion	6.0 ± 0.9 (4.2 ~ 7.8)	4.7 ± 0.8 (3.0 ~ 6.0)
	Mid-section of sinus	5.8 ± 1.0 (4.3 ~ 7.8)	4.3 ± 0.7 (2.5 ~ 5.4)
	Stem	1.2 ± 0.2 (0.8 ~ 1.7)	1.0 ± 0.2 (0.7 ~ 1.7)
Occipital	Initial portion	4.6 ± 0.8 (3.3 ~ 6.0)	3.6 ± 0.8 (2.0 ~ 4.9)
	Mid-section of sinus	4.4 ± 0.8 (3.0 ~ 6.5)	3.9 ± 0.5 (2.8 ~ 4.8)
	Stem	1.5 ± 0.5 (0.8 ~ 2.4)	1.1 ± 0.3 (0.8 ~ 1.6)

Generally, this artery comes from the dorso-medial side of the upper end of the common carotid artery with a sinus in its initial portion. In adult horses, this sinus is about 1 cm in length, narrowing at its end. The diameter of the orifice of the sinus is equal to, or somewhat wider than the lumen of the sinus. The cranial margin of this orifice is partially combined with the compact mass of fibrous tissues in the branching part. The edge of the compact tissues between the common carotid artery and the carotid sinus is seen as a semicircular projection on the inner surface of the lumen, and the caudal half of the lumen is smooth. The cranial wall of the sinus is often combined to the wall of the external carotid and occipital arteries presenting a somewhat flat, plate-like appearance, but the caudal wall of the sinus is rounded. So, in the frontal section, the mid portion of the sinus is half-moon shaped, and the upper end is round. The wall of the sinus is thin and stretched, and feels elastic. The upper end of sinus diminishes, presenting a funnel shape with a diameter one-fifth of the that of the sinus. The sinus continues to the stem of the internal carotid artery which is small in diameter with a relatively thick wall.

c) The occipital artery

This artery comes from the dorsal or dorso-lateral side of the common carotid artery where it joins the internal carotid artery. Macroscopically, author observed a slight swelling near the beginning of this artery. This swelling appears fusiform to the naked eye, but there is no marked difference between the diameters of the initial and dilated portions. In the initial portion the medial wall is thick and is closely attached to part of the carotid body.

The dilated portion is similar to the carotid sinus and its wall is thin. In transverse section, the lumen is round and its inner surface is smooth. It tapers gradually where it joins the stem of the occipital artery. The diameter of the lumen of the stem diminishes to one-third that of the dilated part. The stem of the occipital artery resembles the internal carotid artery.

3) Description of Abnormal Branching

The author found abnormal branching in 3 horses, one case on the left side only, one case on the right side only and one bilateral case.

In these cases, the internal carotid and the occipital arteries have a common stem from the common carotid artery. That is, in these cases, the common carotid artery is simply bifurcated instead of the normal trifurcated form. This common occipito-internal carotid stem occurred in only 4 specimens of the 77 investigated (Figs. 2, 3, 4 and 6).

The diameter of the lumen in these abnormal cases are given in table 3.

TABLE 3. *Diameters of Artery in Abnormal Specimens*

EXP. NO.	SIDE	COMMON CAROTID		EXTERNAL CAROTID		OCCIPITO-INTERNAL CAROTID STEM	
		Stem (Diameter : mm)	Upper end (Diameter : mm)	Root (Diameter : mm)	Stem (Diameter : mm)	Diameter (mm)	Length (mm)
6	L	2.5	6.6	5.4	3.4	4.8	7.0
11	L	2.6	4.4	3.5	2.8	5.5	6.0
	R	3.1	7.5	3.4	3.3	5.8	6.5
27	R	3.3	4.7	4.2	3.2	5.6	6.5

As is shown in the table, the upper end of the common carotid artery dilates as is normal. The initial portion of the external carotid artery is slightly dilated, but the dilation is smaller than that found in the common occipito-internal carotid stem with the exception of Exp. No. 6. The common stem is relatively short.

4) The Carotid Body and Its Fibrous Attachment

In adult horses, the carotid body is seen as a small elevated mass on the cranio-medial surface of initial portion of the occipital artery, but in foals it is often situated between the roots of the occipital, internal and external carotid arteries. The body is about 4~5 mm in size and is enclosed in a rough-surfaced fibrous capsule.

The base of the body is tightly attached to the wall of the occipital, internal and external carotid arteries by thick compact connective tissue, which corresponds to the so-called "ligament of MAYER" in humans. The author observed one or two small arteries coming from the root of the occipital artery or from between the roots of the internal and occipital arteries, but it was impossible to trace their distribution macroscopically after they entered the branching portion of the thick capsule. He also found a small bone included in the fibrous tissue which attaches the carotid body to the arterial wall.

B. X-Ray Observation of the Intercarotid Bones

It is possible to determine the presence of this bone macroscopically and by palpation, if

it is large enough, but when it is very small, X-ray observation is more convenient.

1) Relation between the Presence of the Intercarotid Bone and Age

The results obtained by X-rays are tabulated in table 4.

TABLE 4. *X-Ray Observations*

EXP. NO.	AGE	BONE		EXP. NO.	AGE	BONE	
		Left side	Right side			Left side	Right side
1	3 Months	—	—	23	7 Years	+	—
2	"	.	—	24	8 Years	+	+
3	"	—	—	25	"	+	+
4	4 Months	—	—	26	"	—	—
5	2 Years	—	.	27	9 Years	+	+
6	"	—	—	28	"	—	—
7	"	—	—	29	11 Years	+	+
8	"	—	.	30	12 Years	—	—
9	"	—	—	31	"	.	—
10	"	—	—	32	13 Years	—	—
11	3 Years	+	+	33	"	.	+
12	"	+	+	34	15 Years	+	.
13	4 Years	—	+	35	"	.	+
14	"	+	+	36	"	+	+
15	5 Years	+	+	37	"	+	+
16	"	—	—	38	16 Years	+	+
17	"	—	—	39	17 Years	—	—
18	6 Years	+	+	40	"	—	—
19	"	—	.	41	18 Years	+	+
20	7 Years	—	—	42	"	+	+
21	"	—	—	43	19 Years	+	+
22	"	+	.				

— : No bone

+ : Bone

In table 5 these results are summarized by age.

The specimens from foals in which no bones were found are shown in figures 2, 7, 8, 9 and 10, and the specimens from adult horses in figures 19, 23, 24, 30 and 31.

Those results suggest that formation of the bone occurs at about 3 years, but the bone tissue was not always found in the adults.

2) The Appearance of the Intercarotid Bone Found in Different Sides

For this purpose, the author summarized the data from 27 horses in which specimens

TABLE 5. *Relation between Presence of Bone and Age*

BONE	SIDE	GRADE OF AGES				TOTAL
		3 Months to 2 Years	3 to 4 Years	5 to 9 Years	11 to 19 Years	
Not Present	Left	9	1	7	4	41 (53.2%)
	Right	8	0	7	5	
Present	Left	0	3	7	8	36 (46.8%)
	Right	0	4	5	9	
Total		17	8	26	26	77

TABLE 6. *X-Ray Observation of Presence of Bone*

BONE	CASES
Present in both sides	15
Not present in either side	10
Present in left side only	1
Present in right side only	1
Total	27

were taken bilaterally. The data are given in table 6.

As is shown in the table, intercarotid bones were found bilaterally in 15 cases (Figs. 3~6, 11, 12, 14~17, 20, 21, 27, 28, 32~27) and unilaterally in 2 cases (Figs. 18 and 19), and were absent entirely in 10 cases (Figs. 23, 24, 30 and 31).

3) Location, Size, and Form of the Intercarotid Bone

The trifurcate portion of the common carotid artery was X-rayed.

a) Location: The bone is embedded between the roots of the external carotid and occipital arteries in the so-called "ligament of MAYER", just below the carotid body. But, in some large well-developed bones, the upper end extends to the carotid body and the lower end to the initial portion of the internal carotid artery (Fig. 34). The location and size of the bone are somewhat variable as may be seen in the figures. One was found in the carotid body (Fig. 4) and another one appeared to bridge the roots of the occipital and internal carotid arteries (Fig. 18).

b) Size of the bone: The length of the bones from 15 adult horses were measured from the X-ray photographs and the results are shown in table 7.

As may be seen in the table, the length ranges from 1.0~14.0 mm. The bones from different side of the same horse were usually of approximately the same length but there were many exceptions.

c) Form of the intercarotid bone: The intercarotid bones varied in shape being oval, ellipsoid, U-shaped or rod-like.

TABLE 7. *Length of Bones in X-Ray Figures (mm)*

EXP. NO.	LEFT SIDE	RIGHT SIDE
11	4.5	1.5
12	3.0	2.5
14	5.5	5.5
15	5.5	4.0
18	3.5	9.0
24	8.5	9.5
25	5.5	4.5
27	4.5	5.0
29	3.0	1.0
36	7.0	8.0
37	6.0	8.5
38	3.0	4.0
41	6.0	6.0
42	14.0	7.0
43	3.5	6.0

TABLE 8. *Histological Specimens and Their X-Ray Results*

EXP. NO.	LEFT SIDE	RIGHT SIDE	TOTAL
1	—	—	} 18 Specimens
2	•	—	
3	—	—	
4	—	—	
5	—	•	
6	•	—	
7	—	—	
8	—	•	
9	—	—	
10	—	—	
16	—	•	} 5 Specimens
20	—	•	
12	+	•	
13	•	+	
14	+	•	
18	+	•	
24	•	+	
Total	12	11	23 Specimens

— : No Bone + : Bone

The author removed five of these bones. They were generally flat with sharp, finely serrated margins. The surface of the larger bones appeared to be finely perforated (Fig. 38).

C. Histological Findings

Specimens with and without bones were examined and are listed in table 8.

Histological investigation disclosed that in those cases where the bone was not present, there was always cartilage (Figs. 39~41). This cartilage was found not only in foals, but also in adults, which implies that the cartilage or the bone tissue is an essential structure. In the 5 sections from horses with intercarotid bones as determined from the X-ray films, the author observed distinct bone tissue with trabeculae and bone marrow (Figs. 42~44).

To determine the location and relation of the carotid body to other tissues, the author made serial section of the trifurcate parts of the common carotid arteries. From these sections, it was determined that the lower part of the carotid body is attached to the arterial wall by thick fibrous tissue in which is embedded a small mass of cartilage or bone tissue and some small blood vessels, which appear to be distributed in the carotid body.

DISCUSSION

SUNDER-PLASSMANN and MEIJLING stated that the equine carotid sinus is a bulbous dilation in the initial portion of the internal carotid artery. DOBBERSTEIN and KOCH also described a slight dilation. DE BOISSEZON said that the equine carotid sinus is a large swelling in the initial portion of the internal carotid artery and in the post-medial portion of the upper extremity of the common carotid artery.

The present author found a distriected swelling in the upper end of the common carotid artery corresponding to its trifurcate portion in all 13 adult horses observed. This swelling at the upper end of the common carotid artery is not a part of the sinus reported by DE BOISSEZON.

The present observation applies to untreated specimens, but the author has also observed the same swelling in specimens which had been injected with formalin which would seem to suggest that the state exists *in vivo* and which agrees with the opinion of SUNDER-PLASSMANN and MEIJLING etc.

In the specimens used in the present observation, the sinus is bulbous from the external view, but from the internal view and from the mean value of the diameter it is apparent that it is an ampulla-shaped swelling even in untreated materials.

BOYD classified the adult human sinuses into 5 types. From 118 cases which he investigated, the swelling of the internal carotid artery only was found in the largest number of cases. A sinus-like swelling of the common carotid and internal carotid arteries was only demonstrated in 32 cases.

The present author observed swelling of the latter type in all of the specimens from horses. This difference is presumed to be due to the difference in species.

That is, in the human, the common carotid artery is usually bifurcate, and in the horse, trifurcate.

ASK-UPMARK clearly demonstrated by macroscopic observation that with the exception of the cow, the carotid sinus of mammals is generally restricted at the root of the internal carotid artery.

The occurrence of the sinus in the initial portion of the occipital artery in cows has been reported by ARGAUD and DE BOISSEZON³⁾, and DE CASTRO and SUNDERPLASSMANN, but there have been no reports of the presence of an occipital sinus in horses.

The present author has previously reported the presence of this sinus in dogs. In the present paper he has also demonstrated the presence of an occipital sinus in horses although this sinus is smaller than the carotid sinus.

WOLHYNSKI explained the mechanism of the sinus formation from the viewpoint of hydrodynamics; he said that the blood stream passes through the sinus in an S-shaped course and the effect of the blood pressure expands the lateral wall of the sinus. His hypothesis is insufficient to explain the mechanism of sinuses in all animals.

The present author considers that the mechanism should be explained in terms of both the physiological function and the anatomical structure of the artery. The lateral swelling of the sinus wall is explained by the structural differences in the medial and lateral walls. The medial wall of the sinus is flat because of its compact well-developed connective tissue, but there is no such tissue in the lateral and in addition, the diameter of the stem of the internal carotid artery is extremely narrow compared with the large lumen of the sinus.

As a consequence, it is natural that the blood pressure should cause expansion of the weaker lateral wall. This explanation of the mechanism of sinus formation obviates the necessity for considerations of hydrodynamics and S-shaped courses.

A similar dilation at the root of the occipital artery in the horse may be similarly explained. It is important that the occipital artery forms an anastomosis with the cerebro-spinal artery and the condyloid and posterior meningeal arteries, playing a role in the cerebral circulation which is similar to that of the internal carotid artery, branch off from the occipital artery.

The present author found an abnormal form, in which the internal carotid and occipital arteries arise from a common stem, in 4 specimens from 3 horses. MEIJLING reported that such abnormal forms are often observed in horses. WINOGRADOW also reported one case in which the length of the common stem of the occipital and internal carotid arteries was 7 cm. But in the 4 specimens observed by the present author the stem was very short, 6~7 mm in length. The author feels that this stem does not develop by secondary fusion between two arteries, but has a primary

origin in the early embryonic period; he traces its origin to the third embryonic branchial artery.

A common stem for the occipital and internal carotid arteries has been observed in *Tapirella bairdii* (Perissodactyla) by ASK-UPMARK, in *Erinaceus europaeus* (Insectivora) by ADAMS and also in the pig by DOBBERSTEIN and KOCH, therefore this type of branching is presumed to be normal in other mammals.

The appearance of the bone tissue at the trifurcate portion of the common carotid artery was described by ARGAUD and DE BOISSEZON^{2,5}), and DE BOISSEZON. The origin of this intercarotid bone was described as a group of specific cells of embryonic mesenchyma. Ossification begins several months after birth and the bone is always present in adult horses. These investigators did not believe that the bone resulted from any pathology, such as calcification of the arterial atheroma or cholesterolin deposit.

X-rays taken by the present author showed that the bone was not present in horses 3 months to 2 years old, and that bone formation only began in horses more than 3 years old.

The present author also proved that the intercarotid bone is not always present in horses much older than 3 years, contrary to the report of ARGAUD and DE BOISSEZON²). He also demonstrated that in those horses where no bone was present there was always cartilage. From these facts, he believes that the anlage of this bone comes from the embryonic mesenchymal cells. This opinion is similar to that of ARGAUD and DE BOISSEZON^{2,5}) described above.

In the X-rays this bone is usually located on the median side of the root of the occipital artery just below the carotid body. In some cases, the upper end of the well developed bone protrudes into the carotid body and its lower end reaches the initial portion of the internal carotid artery.

The form and size of the bone vary widely. The bones which were removed in this experiment had different forms and sizes but they were all more or less flattened with sharp edges, and the edge of the largest bone was particularly sharply serrated.

GOMEZ called the connective tissue in humans, which attaches the carotid body to the arterial wall a "fibro-elastic stump". WHITE regarded it as "band of MAYER" a loose connective tissue which in humans, serves as the connection between the carotid body and the branching part of the common carotid artery. OCHOTERENA reported that in horses, the lower end of the "fibro-vascular pedicle" is combined with the upper end of the common carotid artery and that this "fibro-vascular pedicle" corresponds to the "ligament of MAYER" in humans.

The present observations proved that the lower part of the carotid body is firmly attached to the arterial wall in the branching portion of the artery by thick

compact fibrous tissue and not by loose tissue as was described by WHITE. These tissues build up the fibrous stalk of the carotid body and contain small arteries as does the "ligament of MAYER" in humans. These fibrous tissues, the intercarotid bone or cartilage seem to support the carotid body. The bones are located in the fibrous tissue serving as a firm support of axis for the carotid body.

ARGAUD and DE BOISSEZON⁴⁾ found cartilage tubercles in the media of the internal carotid artery of the horse, and the present author found a districted cartilagenous tissue in the media of the initial portion of the occipital artery in dogs. Though such pathological changes have been reported, the intercarotid bone and cartilage in horses are certainly not pathological but physiological conditions.

CONCLUSION AND SUMMARY

For the purpose of filling in some gaps in the literature, the trifurcate portions of the common carotid artery were investigated. The author's primary purpose was X-ray and macroscopic investigations of this part and of the intercarotid bones. Histological investigations were also used.

Results obtained may be summarized as follows.

1. Even in specimens treated with fixative there was a dilated carotid sinus in the initial portion of the internal carotid artery. Some dilation was also observed in the upper end of the common carotid artery.

2. There was a sinus-like dilation at the root of the occipital artery which was thought to be similar to the carotid sinus.

3. The mechanism of the dilation of the carotid and occipital sinuses seem to be similar. The author feels that these dilations are produced by the effect of the blood pressure on the structural differences in the medial and lateral walls of the corresponding arteries.

4. An abnormal branching in which the internal carotid and occipital arteries arise from a common stem was observed in 4 specimens. The genesis of this abnormal type was discussed. It was felt that these abnormal branchings have essentially embryonic origins in the third branchial artery.

5. The so-called intercarotid bones were observed and it was ascertained that while their individual form and sizes differ, they are generally flat with sharp serrated margins.

6. In horses less than 2 years old, cartilage tissue instead of the bone tissue was observed. This cartilage was also observed in some horses more than 3 years old, though bones were observed in the majority of horses older than 3 years.

7. The existence of the intercarotid bone or cartilage is thought to be essential and it is believed to have some physiological significance such as supporting the

carotid body, or as a pressure-resisting structure in that portion of the artery constantly subjected to the pressure of the blood stream.

8. The author feels that the development of this bone or cartilage originates in the embryonic mesenchyma in the early embryonic period, and that it is directly related to the fibrous tissue and the carotid body.

ACKNOWLEDGMENT

The author would like to thank K. TAKAHATA, Prof. Emeritus, for his guidance and advice, and Prof. N. KUDO and Dr. M. SUGIMURA for their aid. The experimental materials were obtained through the cooperation of the Sapporo slaughter house.

REFERENCES

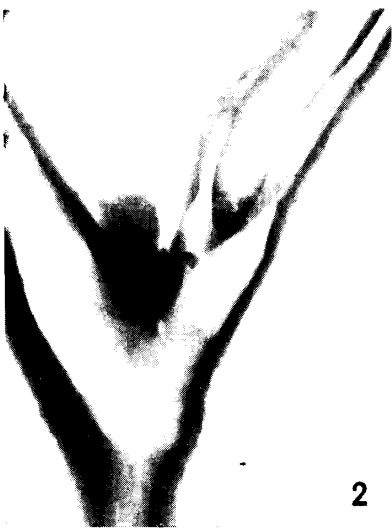
- 1) ADAMS, W. E. (1957): *J. Anat., Lond.*, **91**, 207
- 2) ARGAUD, R. & P. DE BOISSEZON (1935): *Bull. Acad. Méd., Paris*, **114**, 218
- 3) ARGAUD, R. & P. DE BOISSEZON (1936): *Ann. Anat. path. méd.-chir.*, **13**, 1035
- 4) ARGAUD, R. & P. DE BOISSEZON (1938): *Ibid.*, **15**, 641
- 5) ARGAUD, R. & P. DE BOISSEZON (1939): *Bull. Histol. Tech. micr.*, **16**, 65
- 6) ASK-UPMARK, E. (1935): *Acta psychiat., Kbh.*, Suppl. **6**, 1
- 7) BINSWANGER, O. (1879): *Arch. Psychiat. Nervenkr.*, **9**, 351
- 8) DE BOISSEZON, P. (1936): *Ann. Anat. path. méd.-chir.*, **13**, 773
- 9) BOYD, J. D. (1937): *Anat. Anz.*, **84**, 386
- 10) DE CASTRO, F. (1928): *Trad. Lad. Invest. biol. Univ. Madr.*, **25**, 331
- 11) DOBBERSTEIN, J. & T. KOCH (1958): *Lehrbuch der vergleichenden Anatomie der Haustiere*, Bd. **III**, S. Hirzel Verlag, Leipzig
- 12) FURUHATA, K. (1954): *Jap. J. vet. Res.*, **1**, 167
- 13) GOMEZ, L. P. (1908): *Amer. J. med. Sci.*, **136**, 98
- 14) MEIJLING, H. A. (1938): *Acta neerl. morph.*, **1**, 193
- 15) OCHOTERENA, I. (1936): *An. Inst. Biol. Univ. Méx.*, **7**, 397
- 16) SUNDER-PLOSSMANN, P. (1930): *Z. Anat. EntwGesch.*, **93**, 567
- 17) TANDLER, J. (1898): *Denkschr. Akad. Wiss. Wien*, **67**, 677 (Cited by ASK-UPMARK)
- 18) TANDLER, J. (1901): *Anat. Hefte*, Abt. 1, **18**, 327
- 19) WHITE, E. G. (1935): *Beitr. path. Anat.*, **96**, 177
- 20) WINOGRADOW, P. P. (1928): *Anat. Anz.*, **66**, 273
- 21) WOLHYNSKI, F. A. (1937): *Ibid.*, **83**, 261

EXPLANATION OF PLATES

Figures 2~37 are lateral X-ray plates ($\times 2$).

Plate I

- Fig. 1 Macroscopic specimen of the trifurcate portion of the common carotid artery. Portions in which the diameters were estimated and their cross sections. Dilation at the root of the occipital artery, carotid sinus and carotid body are clearly demonstrated. Natural size.
- Fig. 2 No. 6, left side. Abnormal branching. No bone.
- Figs. 3 and 4 No. 11, left and right sides. Abnormal branching in both sides. Bone.
- Figs. 5 and 6 No. 27, left and right sides. Abnormal branching, right side only. Bone.
- Fig. 7 No. 1, left side. No bone.



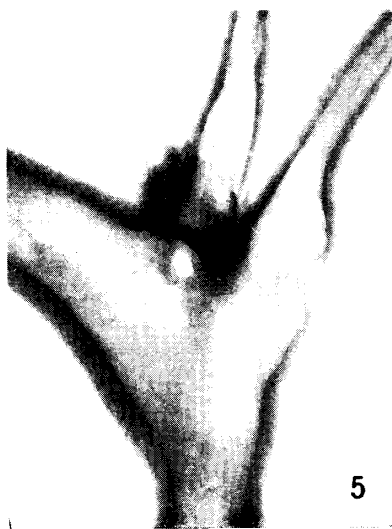2



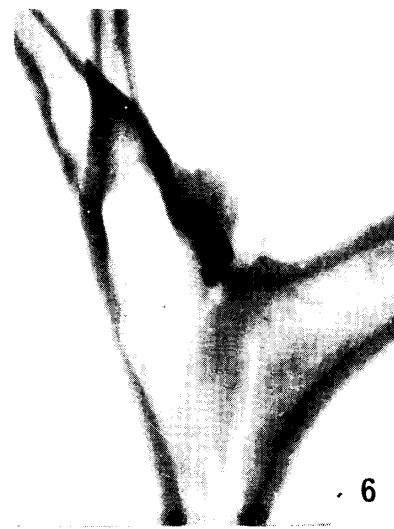3



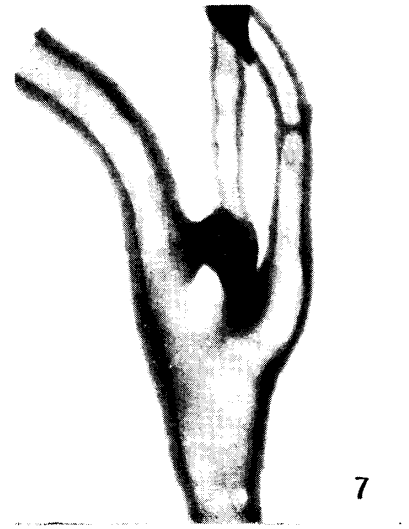
4



5



6



7

Plate II

Fig. 8 No. 3, right side. No bone (ref. Fig. 39).

Fig. 9 No. 4, right side. No bone (ref. Fig. 40).

Fig. 10 No. 10, left side. No bone (ref. Fig. 41).

Figs. 11 and 12 No. 12, left and right sides. Bone (ref. Fig. 42).

Fig. 13 No. 13, right side. Bone.

Figs. 14 and 15 No. 14, left and right sides. Bone (ref. Fig. 38 and 43).

Fig. 16 No. 15, left side. Bone.

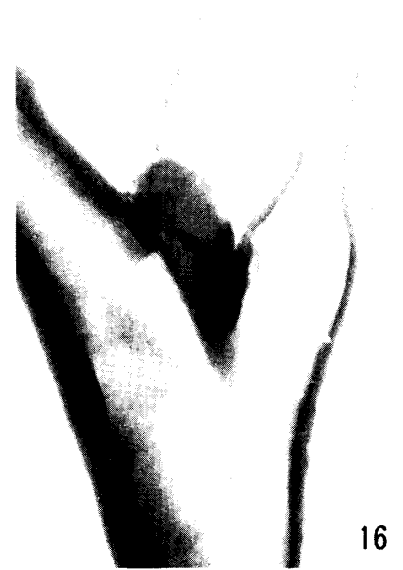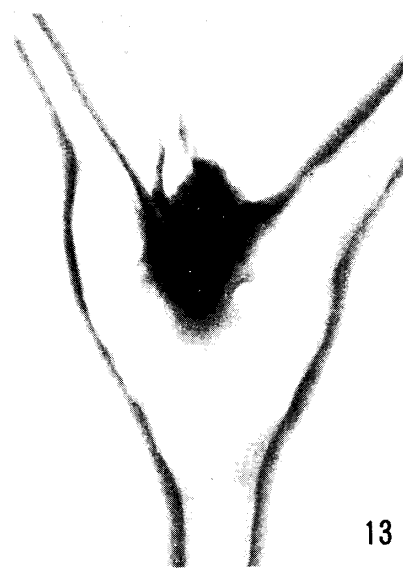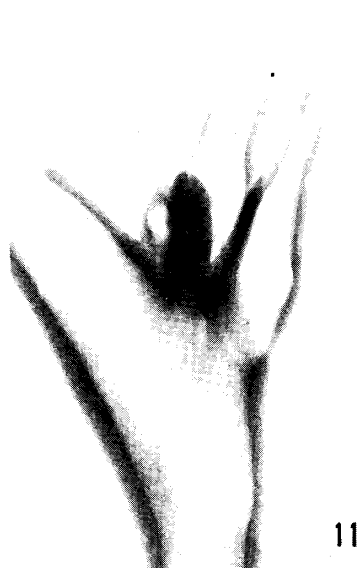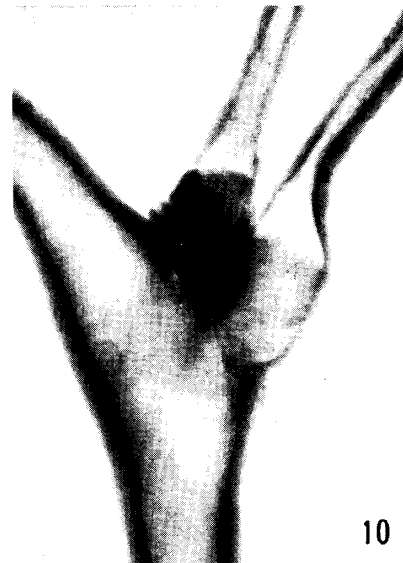


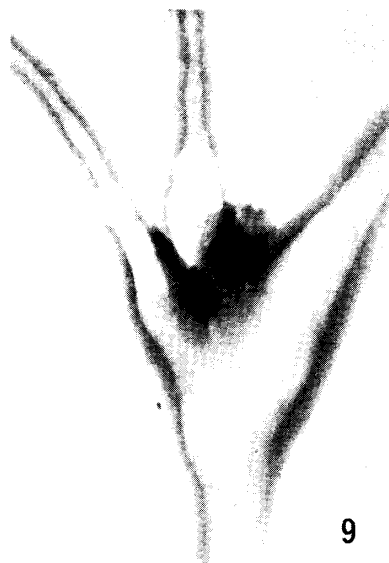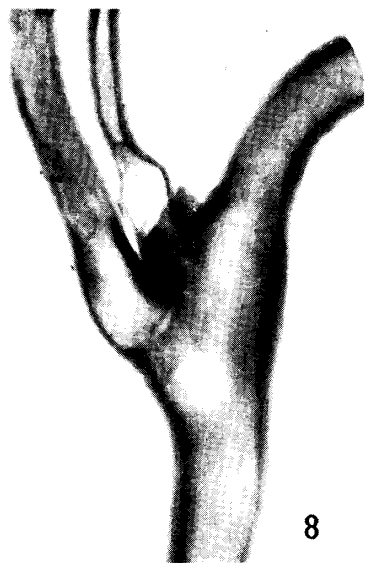Plate III

Fig. 17 No. 15, right side. Bone (ref. Fig. 38).

Figs. 18 and 19 No. 23, left and right sides. Bone in the left side only (ref. Fig. 38).

Figs. 20 and 21 No. 24, left and right sides. Bone (ref. Figs. 38 and 44).

Fig. 22 No. 29, right side. Bone (smallest bone).

Figs. 23 and 24 No. 30, left and right sides. No bone in either side.

Fig. 25 No. 33, right side. Bone (ref. Fig. 38).

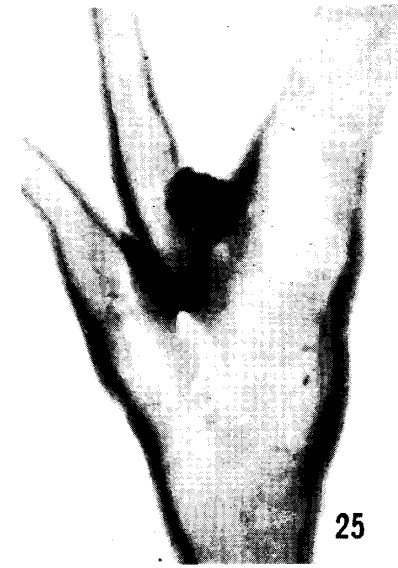
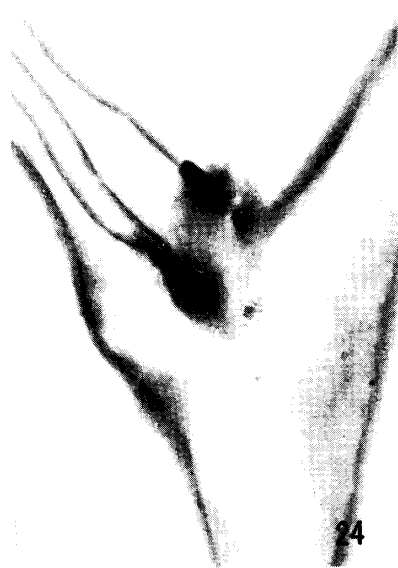
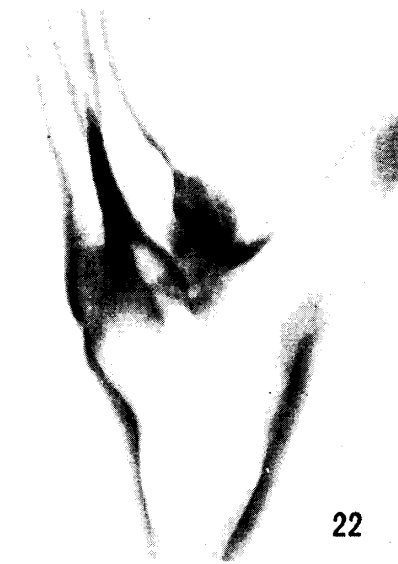
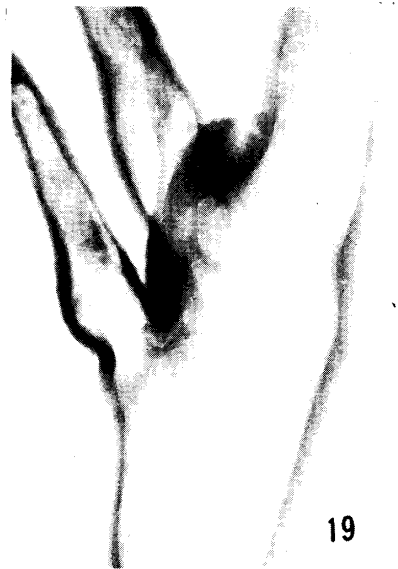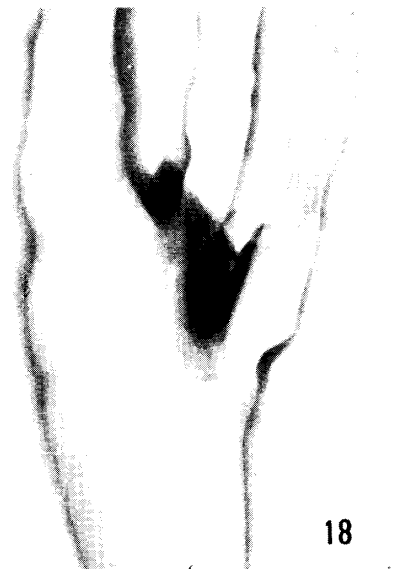Plate IV

Fig. 26 No. 36, right side. Bone.

Figs. 27 and 28 No. 37, left and right sides. Bone.

Fig. 29 No. 38, right side. Bone.

Figs. 30 and 31 No. 40, left and right sides. No bone in either side.

Figs. 32 and 33 No. 41, left and right sides. Bone.

Fig. 34 No. 42, left side. Bone (largest bone).

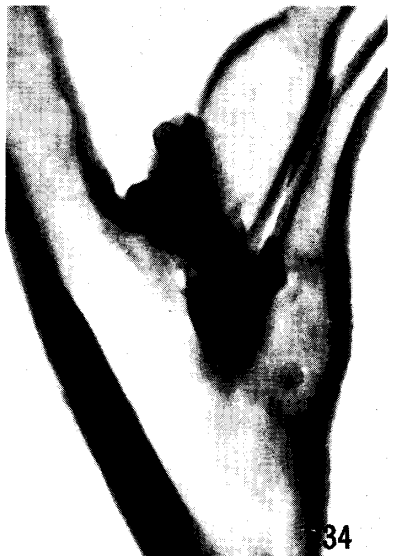
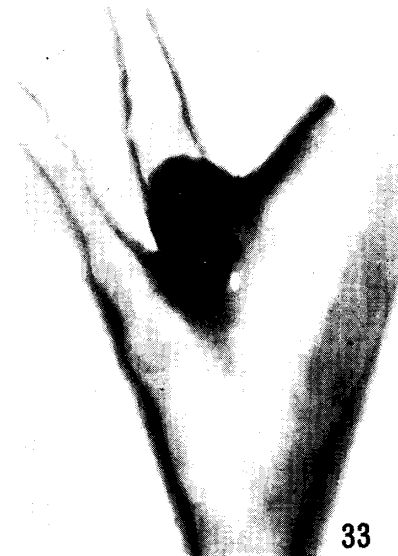
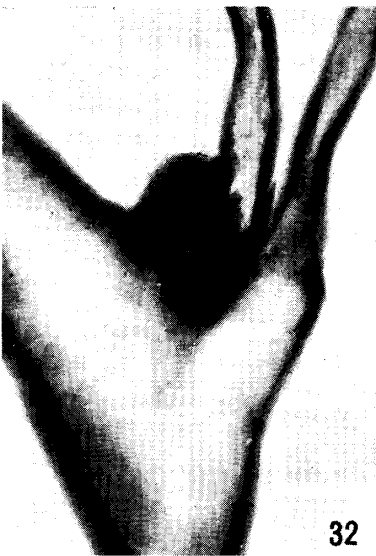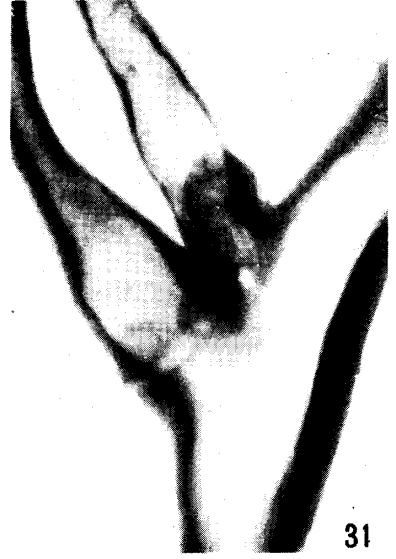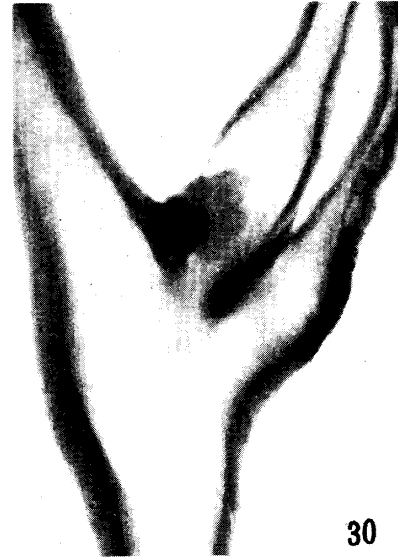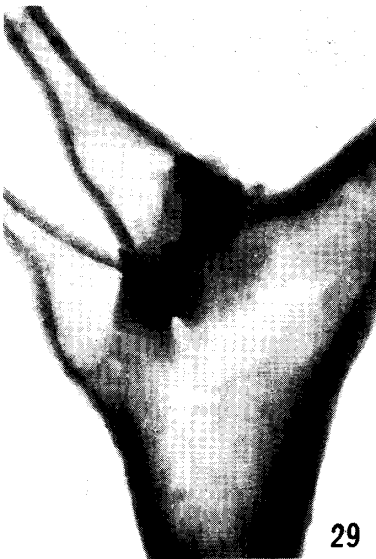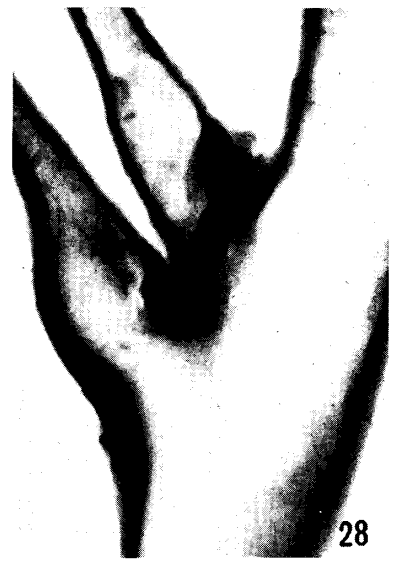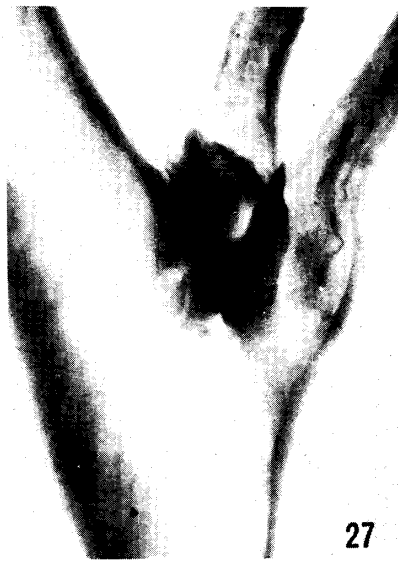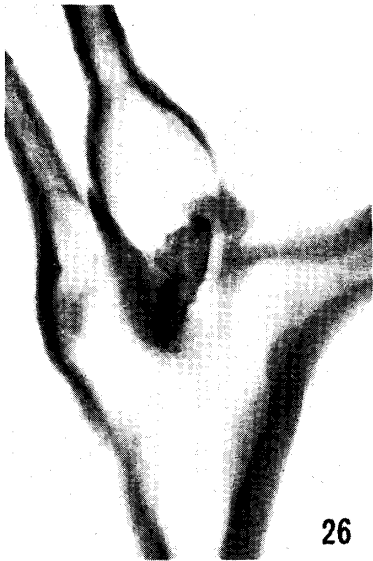Plate V

Fig. 35 No. 42, right side. Bone.

Figs. 36 and 37 No. 43, left and right sides. Bone.

Fig. 38 Five intercarotid bones removed from other tissues (see Figs. 15, 17, 18, 20 and 25).

Fig. 39 No. 3, right side. Longitudinal section of the root of the occipital artery. Cartilage tissue is clearly shown in the fibrous tissue. (H.-E., $\times 16$)

Fig. 40 No. 4, right side. Sagittal section of the trifurcate portion. The cartilage tissue and small artery are found in the fibrous tissue by which the carotid body is attached with the arterial wall. (H.-E., $\times 16$)

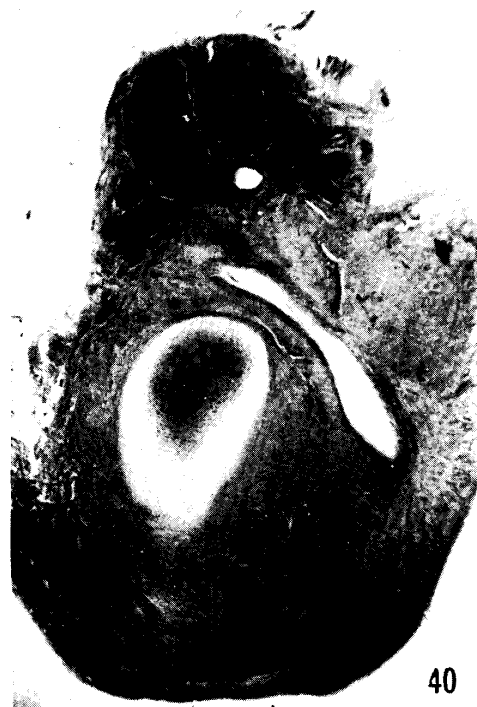
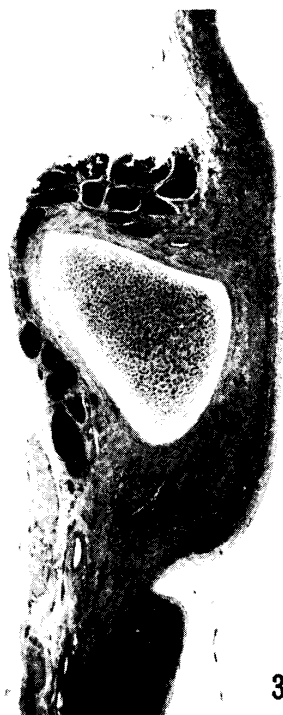
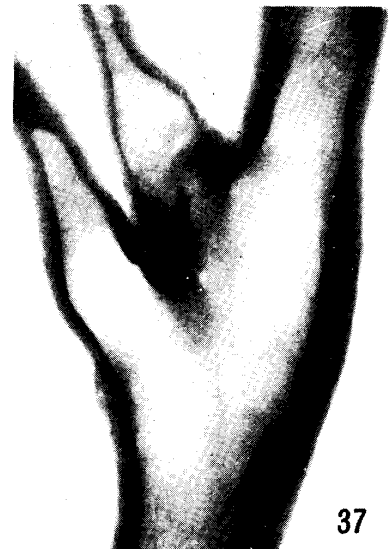
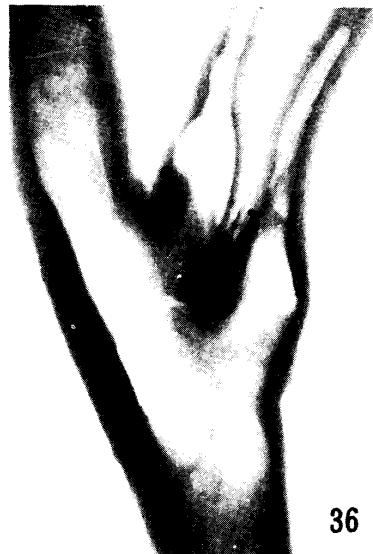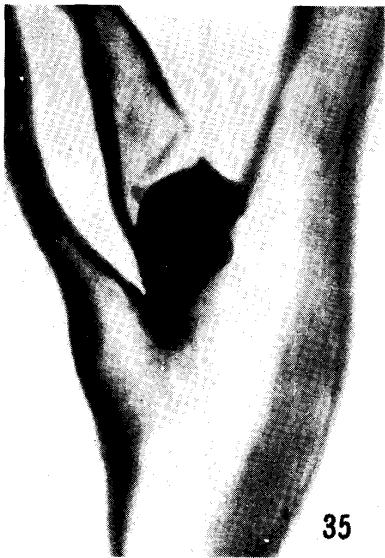Plate VI

- Fig. 41 No. 10, left side. Sagittal section of the trifurcate portion. The cartilage tissue, its center darkly stained, may be seen in the fibrous tissue by which the arterial wall is firmly attached to the carotid body. (H.-E., $\times 16$)
- Fig. 42 No. 12, left side. Cross section of the trifurcate portion. The small flat bone may be seen in the fibrous tissue. On the left side of the figure, the walls of the internal carotid, occipital and external carotid arteries may be seen. (H.-E., $\times 16$)
- Fig. 43 No. 14, left side. Cross section of the trifurcate portion. Bone in the fibrous tissue. See bone marrow. (H.-E., $\times 16$)
- Fig. 44 No. 24, right side. Cross section of the trifurcate portion. Bone contains bone marrow and trabeculae. (H.-E., $\times 16$)

