



Title	THE LYMPH SYSTEM IN MICE
Author(s)	KAWASHIMA, Yoshitsugu; SUGIMURA, Makoto; HWANG, Yann-Ching et al.
Citation	Japanese Journal of Veterinary Research, 12(4), 69-78
Issue Date	1964-12
DOI	<a href="https://doi.org/10.14943/jjvr.12.4.69">https://doi.org/10.14943/jjvr.12.4.69</a>
Doc URL	<a href="https://hdl.handle.net/2115/1797">https://hdl.handle.net/2115/1797</a>
Type	departmental bulletin paper
File Information	KJ00002369111.pdf



# THE LYMPH SYSTEM IN MICE

Yoshitsugu KAWASHIMA\*, Makoto SUGIMURA, Yann-Ching HWANG  
and Norio KUDO

*Department of Veterinary Anatomy,  
Faculty of Veterinary Medicine,  
Hokkaido University, Sapporo, Japan*

(Received for publication, July 25, 1964)

## INTRODUCTION

There are only a few descriptions of the lymph system in mice (DUNN, '54 and HOFFMANN, '56), although lymph nodes from this animal are frequently used in experiments. Especially, there are no detailed reports of the drainage areas of the lymph nodes. In this study, attempts have been made to clarify the location of the lymph nodes and their drainage areas and to compare them with those of the rat described by HIGGINS ('25) and JOB ('15), and to determine the nomenclature of those lymph nodes using the "lymphocenter" conception advocated by BAUM ('26) and GRAU ('43, '61).

## MATERIALS AND METHODS

Sixty white mice (45 dd, 15 NIH), both males and females, 32 to 705 days old were used. The mice were either anaesthetized or killed with chloroform and then India ink was injected directly into the subcutis and various organs with 1/5 mm metal or fine glassy needles. The ink-filled lymph nodes and vessels were examined in a stereomicroscope. In some cases, lymph drainage from the peritoneal cavity was observed in anaesthetized mice following the injection of ink into the cavity.

## RESULTS

### A. Location, Size and Shape of Lymph Nodes

The lymph nodes in mice may be divided into 13 lymphocenters, which include 16 groups of lymph nodes, according to their location and drainage area. Description of these lymphocenters is as follows: (The size of the nodes was measured in adult mice.)

#### 1) Mandibular lymphocenter (*Lymphocentrum mandibulare*; HOFFMANN)

This lymphocenter is composed of two nodal groups (Superficial cervical, DUNN and HIGGINS; Kehlganglymphknoten, HOFFMANN; Submaxillary, JOB).

\* Present address: (Rikagaku Kenkyusho) The Institute of Physical and Chemical Research, Komagome, Bunkyo-Ku, Tokyo, Japan

a) Medial mandibular nodes: The nodes are embedded in the adipose tissue at the caudal border of the mandible, just cranial to the major sublingual and submaxillary glands. They vary from 3.7 to 6.2 mm in length and are usually flatly-ellipsoid.

b) Lateral mandibular nodes: These nodes lie on the caudo-lateral side of the medial mandibular nodes and are always embedded in the parotid gland. They vary from 3.4 to 5.0 mm in length and are usually flatly-ellipsoid.

## 2) Deep cervical lymphocenter

This lymphocenter includes only one group of nodes.

a) Deep cervical nodes (Same, DUNN and HIGGINS; Anterior and posterior cervical, JOB): The nodes lie along the trachea and the common carotid artery just under the *M. omohyoideus* deep in the neck, and are 1.7 to 3.1 mm in length and flatly spherical in shape.

## 3) Axillary lymphocenter

This lymphocenter is composed of two nodal groups.

a) Superficial axillary node (Brachial, DUNN; *Ln. axillaris*, HOFFMANN; Elbow, JOB; Lateral thoracic, HIGGINS): The node is located on the caudal border of the *M. triceps brachii* between the skin and the *M. cutaneus maximus*. The node varies from 3.8 to 5.3 mm in length and is flatly ellipsoid.

b) Deep axillary node (Axillary, DUNN; Axial, JOB; Median thoracic or Axillary, HIGGINS): This node lies at the junction of the lateral thoracic and axillary veins below the *M. pectoralis major*. The node is usually flatly ellipsoid and varies from 3.7 to 6.4 mm in length.

## 4) Mediastinal lymphocenter

This lymphocenter includes only one group of nodes.

a) Mediastinal nodes (Thoracic, mediastinal and tracheobronchial, DUNN; Thoracic group, JOB; Deep thoracic, HIGGINS): The nodes lie along the superior vena cava in the cranial mediastinum, caudal to the hemiazygos vein on the left, and touching the superior intercostal vein on the right. They vary from 1.8 to 3.3 mm in length and are spherical or ellipsoid.

## 5) Bronchial lymphocenter

The lymphocenter also includes only one group of nodes which are not always seen.

a) Bronchial node: This node is on the dorsal side of the tracheal bifurcate portion along the right side of the esophagus. It is 1.0 to 2.0 mm in length and ellipsoid.

## 6) Coeliac lymphocenter

This lymphocenter includes two groups of nodes.

a) Coeliac nodes (Pancreatic or Pyloric, DUNN; Cisternal group, JOB): The nodes lie along the junction of the portal vein and the stem of the gastro-lienal vein and are embedded in the pancreas. They are usually spherical and varies from 2.3 to 4.0 mm in length.

b) Gastric node: This node is usually found on the lesser curvature of the stomach and varies from 1.2 to 1.5 mm in length, and is usually spherical.

## 7) Cranial mesenteric lymphocenter

This lymphocenter includes only one group of nodes.

a) Cranial mesenteric nodes (Mesenteric, DUNN and HIGGINS; Intestinal, JOB): The nodes are along the anterior mesenteric artery in the mesentery. They are club-shaped or spherical and vary from 1.4 to 17.3 mm in length.

8) Caudal mesenteric lymphocenter

This lymphocenter includes only one group of nodes.

a) Caudal mesenteric node (Caudal, DUNN and JOB): The node is located along the posterior mesenteric artery at some distance from the descending colon. If the caudal mesenterium is removed, the node lying caudal to the external iliac artery is likely to be the sacral node. The node is usually spherical and varies from 1.0 to 2.7 mm in length.

9) Iliac lymphocenter

This lymphocenter includes only one group of nodes.

a) Iliac node (Lumbar, DUNN and JOB; Median lumbar, HIGGINS): The node lies on both sides of the abdominal aorta cranial to the external iliac artery. The node is usually a long-ellipsoid and varies from 2.0 to 4.8 mm in length.

10) Lumbar lymphocenter

This lymphocenter also includes only one group of nodes.

a) Lumbar node (Renal, DUNN, JOB and HIGGINS): The node lies on both sides of the abdominal vena cava, cranial to the renal vein on the right and the junction of the renal and suprarenal veins on the left. The size of the nodes varies from 2.7 to 5.7 mm in length and they are usually ellipsoid.

11) Sacral lymphocenter

This lymphocenter includes only one group of nodes.

a) External sacral node (Sciatic, DUNN; Gluteal, HIGGINS): The node is covered by the origin of the *M. biceps femoris* along the sciatic nerve. The node varies from 1.4 to 2.8 mm in length and is spherical.

12) Subiliac lymphocenter (*Lymphocentrum subiliacum*, HOFFMANN)

This lymphocenter includes only one group of nodes.

a) Subiliac node (Inguinal, DUNN, JOB and HIGGINS; Kniefaltenlymphknoten, HOFFMANN): The node is along the superficial epigastric vein on the cranial border of the femur. This node is usually flatly ellipsoid and ranges from 3.5 to 6.6 mm in length.

13) Popliteal lymphocenter

This lymphocenter also includes only one group of nodes.

a) Popliteal node (Same, HIGGINS; Knee, JOB): The node is embedded in adipose tissue of the popliteal fossa and is spherical. This node varies from 1.9 to 3.2 mm in length.

There was no difference in the location of the nodes in the two strains examined.

## B. The Occurrence Ratio and Number of Lymph Nodes

The occurrence ratio and the number of lymph nodes in various locations are listed in table 1.

TABLE 1. Occurrence Ratio and Number of Lymph Nodes

GROUP	DD STRAIN				NIH STRAIN			
	Occurrence	Ratio	Number of Nodes		Occurrence	Ratio	Number of Nodes	
	F/E	%	Min.~Max.	Average	F/E	%	Min.~Max.	Average
Medial mandibular	26/26	100.0	1~2*	1.21 ± 0.44*	15/15	100.0	1~2*	1.23 ± 0.43*
Lateral mandibular	26/26	100.0	1~2*	1.21 ± 0.49*	15/15	100.0	1~2*	1.10 ± 0.31*
Deep cervical	26/26	100.0	1~2*	1.08 ± 0.28*	15/15	100.0	1~2*	1.10 ± 0.31*
Superficial axillary	26/26	100.0	1*	1.00 ± 0*	15/15	100.0	1*	1.00 ± 0*
Deep axillary	26/26	100.0	1*	1.00 ± 0*	15/15	100.0	1*	1.00 ± 0*
Mediastinal	26/26	100.0	1~4*	1.79 ± 0.75*	15/15	100.0	1~4*	2.00 ± 0.69*
Bronchial	9/26	34.6	1	1.00 ± 0	0/15	0		
Coeliac	26/26	100.0	1~2	1.61 ± 0.50	15/15	100.0	1~2	1.87 ± 0.35
Gastric	7/26	26.9	1	1.00 ± 0	15/15	100.0	1	1.00 ± 0
Cranial mesenteric	26/26	100.0	2~4	3.54 ± 0.65	15/15	100.0	2~4	2.67 ± 0.62
Caudal mesenteric	26/26	100.0	1	1.00 ± 0	15/15	100.0	1	1.00 ± 0
Iliac	26/26	100.0	1*	1.00 ± 0*	15/15	100.0	1*	1.00 ± 0*
Lumbar	26/26	100.0	1*	1.00 ± 0*	15/15	100.0	1*	1.00 ± 0*
External sacral	26/26	100.0	1*	1.00 ± 0*	15/15	100.0	1*	1.00 ± 0*
Subiliac	26/26	100.0	1*	1.00 ± 0*	15/15	100.0	1*	1.00 ± 0*
Popliteal	26/26	100.0	1*	1.00 ± 0*	15/15	100.0	1*	1.00 ± 0*
Total			28~36	31.67 ± 3.63			29~34	31.33 ± 1.45

\*: one side

F : Numbers of cases in which lymph nodes were found

E : Numbers of cases examined

As is shown in this table, the majority of the nodes are always observed, but in the dd strain mice the gastric and bronchial nodes were often missing. In NIH strain mice, on the other hand, the gastric nodes are always observed, but the bronchial node is missing.

As is suggested by this table, the number of mouse lymph nodes is fairly constant. Usually there are only one or two nodes in each group of nodes with the exception of the cranial mesenteric and mediastinal nodes, and the total number of nodes is only  $31.67 \pm 3.63$  in mice of the dd strain and  $31.33 \pm 1.45$  in those of the NIH strain.

### C. Afferent and Efferent Lymph Vessels

The drainage areas of the lymph nodes and the courses of the lymph vessels are shown in plates I, II and III.

1) Medial mandibular nodes: Afferent vessels; from the lip, eyelid and tongue, and in some cases from the lateral mandibular nodes. Efferent vessel; into the common jugular vein, in some cases into the deep cervical nodes.

2) Lateral mandibular nodes: Afferent vessels; from the auricle. Efferent vessel; into the common jugular vein and in some cases into the deep cervical node.

3) Deep cervical nodes: Afferent vessels; from deep in the head and neck, and in some cases from the medial and lateral mandibular nodes. Efferent vessel; into the common jugular vein.

4) Superficial axillary node: Afferent vessels; from the foreleg and dorsal thoracic wall. Efferent vessel; into the deep axillary node.

5) Deep axillary node: Afferent vessels; from the foreleg and lateral thoracic wall, and the superficial axillary and subiliac nodes. Efferent vessel; into the common jugular vein.

6) Mediastinal nodes: Afferent vessels; from the lungs, diaphragm, costal pleura and perhaps the heart, and in some mice of the dd strain, from the bronchial node. Efferent vessel; into the common jugular vein.

7) Bronchial node: Afferent vessels; from the lung and diaphragm. Efferent vessel; into the right mediastinal nodes.

8) Coeliac nodes: Afferent vessels; from the liver, stomach and gastric node. Efferent vessel; into the left jugular vein by way of the intestinal trunk to the thoracic duct.

9) Gastric node: Afferent vessels, from the stomach. Efferent vessel; into the coeliac nodes.

10) Cranial mesenteric nodes: Afferent vessels; from the small intestine, caecum and colon. Efferent vessel; into the left common jugular vein by way of the intestinal trunk to the thoracic duct.

11) Caudal mesenteric node: Afferent vessels; from the descending colon and rectum. Efferent vessel; into the iliac node.

12) Iliac node: Afferent vessels; from the hindleg, testis, and external sacral and caudal mesenteric nodes. Efferent vessel; into the lumbar node.

13) Lumbar node: Afferent vessels; from the intercostal walls, diaphragm, testis, ovary and the iliac node. Efferent vessel; into the left common jugular vein by way of the thoracic duct.

14) External sacral node: Afferent vessels; from the tail and popliteal node. Efferent

vessel; into the iliac node.

15) Subiliac node: Afferent vessels; from the subcutis of the abdomen and external pudenda. Efferent vessel; into the deep axillary node.

16) Popliteal node: Afferent vessels; from the hindleg. Efferent vessel; into the external sacral node.

The thoracic duct originates in the cisterna chyli which collects lymph from the intestinal trunk and the efferent vessels of the lumbar nodes, and runs cranial along the right dorsal side of the thoracic aorta, forming a small, delicate network. The duct pours into the left common jugular vein near the confluence of the common jugular and subclavian veins.

The intestinal trunk is formed by the confluence of the efferent vessels of the cranial mesenteric and coeliac nodes. The single trunk enters into the cisterna chyli located between the abdominal vena cava and aorta on the cranial side of the renal veins.

In mice, the lymphatico-venous communication seems to be the common jugular vein near the jugulo-subclavian angles on both sides, but definite evidence is lacking as to whether there is communication at one or more points.

#### DISCUSSION

The conception of "lymphocenters", advocated by BAUM ('26) and subsequently by GRAU ('43, '61), was proved by SPIRA ('62) by extending GRAU's terminology from domestic animals to primates, insectivora, chiroptera, lagomorpha, and rodentia. The term "lymphocenter" was further discussed by SAAR and GETTY ('62) and accepted as a necessity in comparative anatomy in order to have a term for describing the lymph node, nodes, or groups of lymph nodes, which in different species of animals perform the same general function.

In this report, the conception of "lymphocenter" was applied to the mouse lymph nodes and the nomenclature of the nodes were determined and compared with the descriptions of rat (JOB, '15; HIGGINS, '25) and mice (DUNN, '54; HOFFMANN, '56) lymph nodes.

From the 20 lymphocenters noted by GRAU, only 13 were distinguished; the parotid, retropharyngeal, superficial cervical, dorsal and ventral thoracic, superficial inguinal and deep inguinal lymphocenters were not observed in mice.

The divisions used here were generally based upon the locations of the nodes, but the caudal mesenteric lymphocenter was divided on the basis of its drainage area. A corresponding node is described as a caudal node in mice (DUNN) and in rats (JOB). In rats, the caudal node receives the lymph vessels originating from the tail (JOB). In mice, the present authors proved that the node did not receive lymph vessels arising from the tail but from the descending colon and rectum. Accordingly, the caudal mesenteric node is a suitable name for this node in mice.

On the other hand, if this nomenclature is based upon the drainage areas, some are questionable. For example, the lateral mandibular node of the mouse

drains areas corresponding to the areas drained by the parotid lymphocenter in domestic animals, and in addition, the deep cervical and the subiliac lymphocenters of the mouse receive the lymph vessels originating from areas corresponding to the areas drained by the retropharyngeal and superficial inguinal lymphocenters. Therefore, the lymphocenters which are absent in the mouse, seem to be compensated for by other lymphocenters. From this point of view, the names mandibulo-parotid, cervico-retropharyngeal and subilico-inguinal are probably better for the above-mentioned lymphocenters in the mouse.

In their report of the comparative anatomy of the lymph vessels draining the thyroid gland in goats, dogs, cats, mink, rabbits and rats, SUGIMURA et al. ('59) considered that the anterior deep cervical node of the rat corresponds more to the retropharyngeal nodes than to the deep cervical nodes in other animals, based upon the drainage areas of the node. They ascertained that the true deep cervical node does not drain the deep portions of the head, and is sometimes present in dogs, cats and mink, and always present in goats.

The concept of lymphocenters seems to be accepted and useful, but the division and nomenclature should be reinvestigated from the standpoint of phylogeny, especially in the lower mammals in which all of 20 lymphocenters are not developed.

The lymph vessels in mice have some courses which are similar to those in reptiles. One is the course in which the efferent vessel of the subiliac node enters in the deep axillary node, but not the iliac node. This has also been observed in some rats (ENGESET, '59) and newborn rats (HIGGINS, '25), but not in domestic animals. It is noteworthy that a corresponding course is called "*Truncus lymphaticus lateralis*" in the bluetail (HOYER, '31/'32).

Another is the course in which the efferent vessel of the popliteal node enters into the external sacral node, but not directly into the iliac node. The course is observed as collateral in some domestic animals, and as the primary course in alligators (MCCAULEY, '56).

There is another interesting course in mice; the lymph vessels draining the intercostal walls run parallel to the thoracic sympathetic nervous trunk cranially and caudally, and enter into the mediastinal nodes and the lumbar node. The dorsal thoracic lymphocenter and the intercostal nodes are absent in mice. A corresponding course is found in rats, a part of it is seen in dogs and cats, but not in goats and rabbits (TAKAHATA et al., '58). A corresponding course is also observed in alligators (MCCAULEY, '56).

In mice, the courses of the lymph vessels seem to be fairly similar to those in reptiles and compared to domestic and other laboratory animals, the mouse has the smallest number of lymph nodes. The two characteristics may indicate the primitive nature of the mouse lymph system.

## SUMMARY

The present study was undertaken in an effort to clarify the location and number of the lymph nodes, and their draining areas in mice. The results may be summarized as follows:

1. There are 13 lymphocenters (mandibular, deep cervical, axillary, mediastinal, bronchial, coeliac, cranial mesenteric, caudal mesenteric, iliac, lumbar, sacral, subiliac and popliteal) which are comprised of 16 groups of lymph nodes.

2. 14 of these groups are always present, but in mice of the dd strain, the gastric and bronchial nodes are not always present. In mice of the NIH strain the gastric node is always present, but the bronchial node is not observed.

3. The number of lymph nodes is smaller in mice than in domestic and other laboratory animals. Some of the courses of the lymph vessels in mice are fairly similar to those in reptiles. This may indicate that the mouse lymph system is primitive.

4. The concept of "lymphocenters" seems to be accepted and useful, but the division and nomenclature should be reinvestigated from the standpoint of phylogeny, especially in the lower mammals in which all of the 20 lymphocenters do not develop.

Acknowledgments: To Dr. K. TAKAHATA, Prof. Emeritus, the authors owe their deepest appreciation for his advice during this work.

REFERENCES

- 1) BAUM, H. (1926): *Anat. Anz.*, **61**, 39
- 2) DUNN, T. B. (1954): *J. nat. Cancer Inst.*, 14, 1281 (Reticular Tissue in Mice, translated into Japanese by N. IDA, Kanehara Publication Co., Tokyo, 1960)
- 3) ENGESET, A. (1959): *J. Anat.*, **93**, 96
- 4) GRAU, H. (1943): ELLENBERGER-BAUM, Handbuch der vergl. Anatomie der Haustiere, Berlin, 746 (Cited by SPIRA)
- 5) GRAU, H. (1961): Über das Lymphgefäßsystem, Teil II, Die Lymphknoten, Forschungen und Fortschritte, **35**, 44
- 6) HIGGINS, G. H. (1925): *Anat. Rec.*, **30**, 243
- 7) HOFFMANN, G. (1956): Kurzer Abriss der Anatomie und Physiologie der Laboratoriumstiere, Veb Gustav Fischer Verlag, Jena
- 8) HOYER, H. (1931/32): *Anat. Anz.*, **73**, 28
- 9) JOB, T. T. (1915): *Anat. Res.*, **9**, 447
- 10) MCCAULEY, WM. J. (1956): *Amer. J. Anat.*, **99**, 189
- 11) SAAR, L. I. & R. GETTY (1962): *I.S.U. Veterinarian*, **25**, 23
- 12) SPIRA, A. (1962): *Anat. Anz.*, **111**, 294
- 13) SUGIMURA, M., N. KUDO & K. TAKAHATA (1959): *Kaibo Z. (Acta anat. nippon.)*, **34**, 60 (in Japanese)
- 14) TAKAHATA, K., N. KUDO & M. SUGIMURA (1958): *Ibid.* **33**, 169 (in Japanese)

## ABBREVIATIONS IN FIGURES

mm	:	Medial mandibular nodes
lm	:	Lateral mandibular nodes
dc	:	Deep cervical nodes
sa	:	Superficial axillary node
da	:	Deep axillary node
med	:	Mediastinal nodes
br	:	Bronchial node
co	:	Coeliac nodes
ga	:	Gastric node
crm	:	Cranial mesenteric nodes
cdm	:	Caudal mesenteric node
il	:	Iliac node
lu	:	Lumbar node
es	:	External sacral node
si	:	Subiliac node
po	:	Popliteal node
td	:	Thoracic duct
it	:	Intestinal trunk

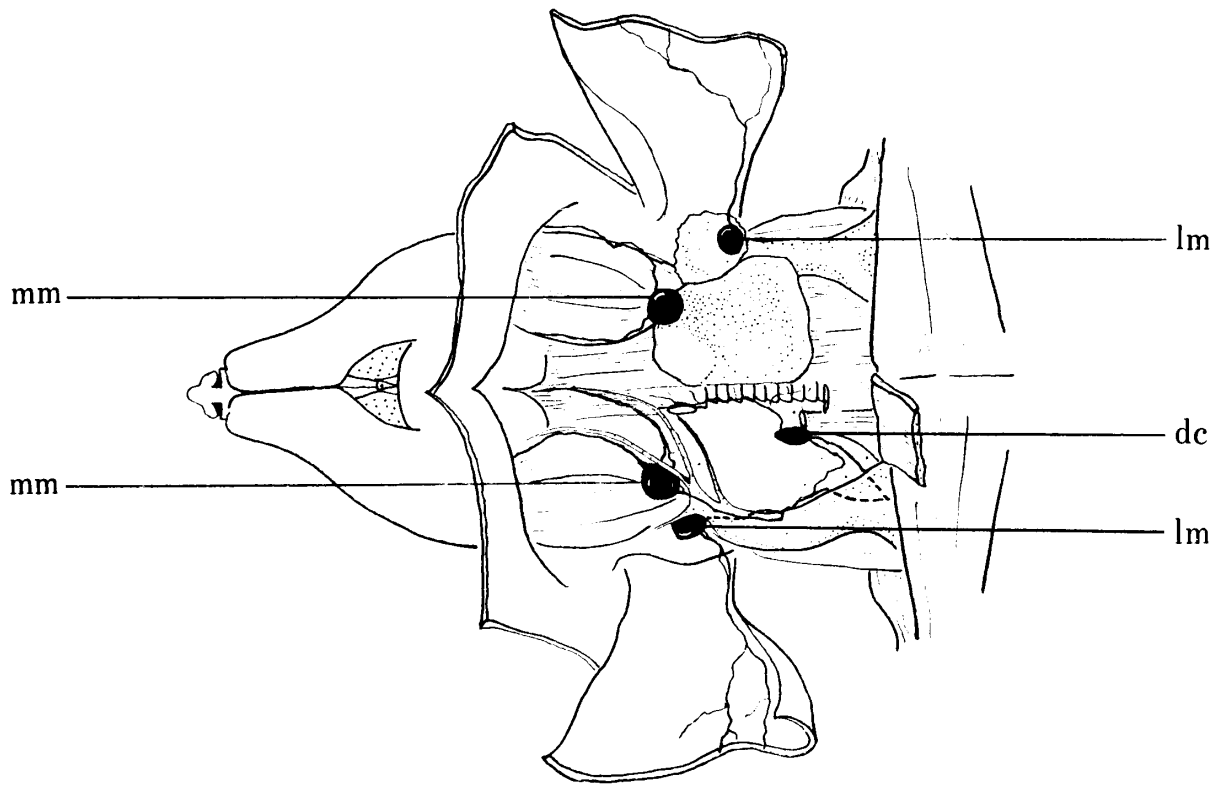


FIG. 1. *Lymph nodes and vessels of head and neck*

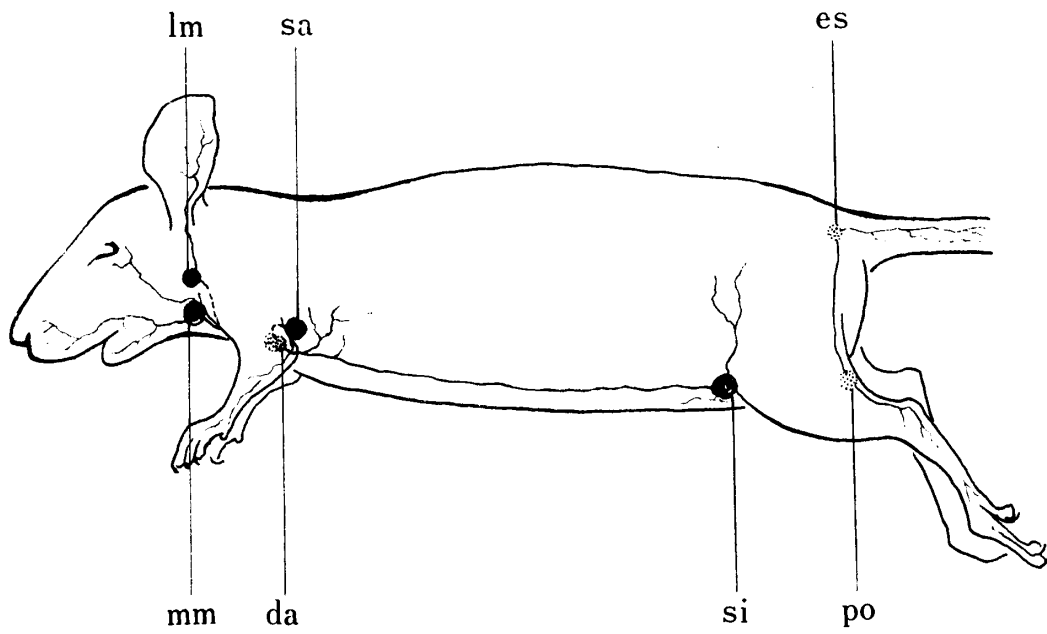


FIG. 2. *Lymph nodes and vessels of body surface*

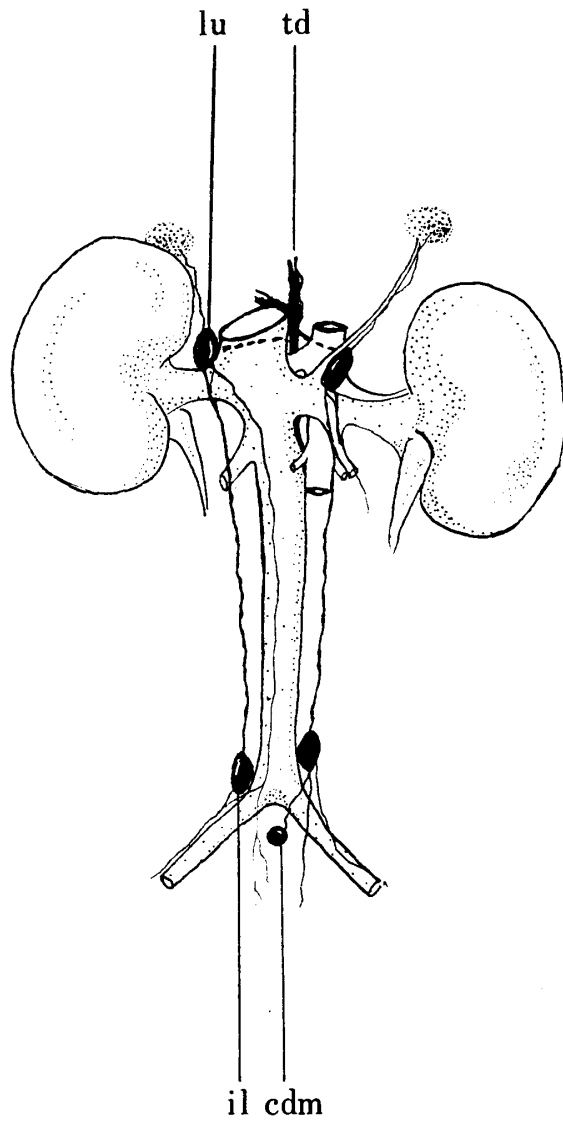


FIG. 3. *Lymph nodes and vessels of wall of abdominal cavity*

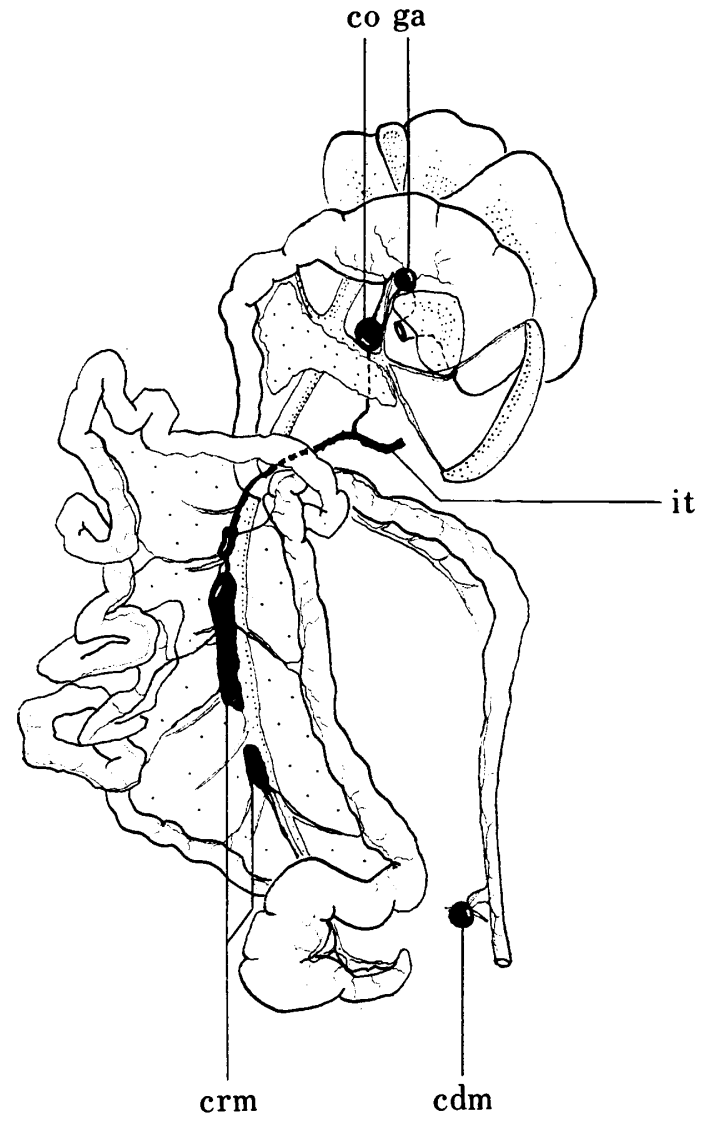


FIG. 4. *Lymph nodes and vessels of abdominal organs*

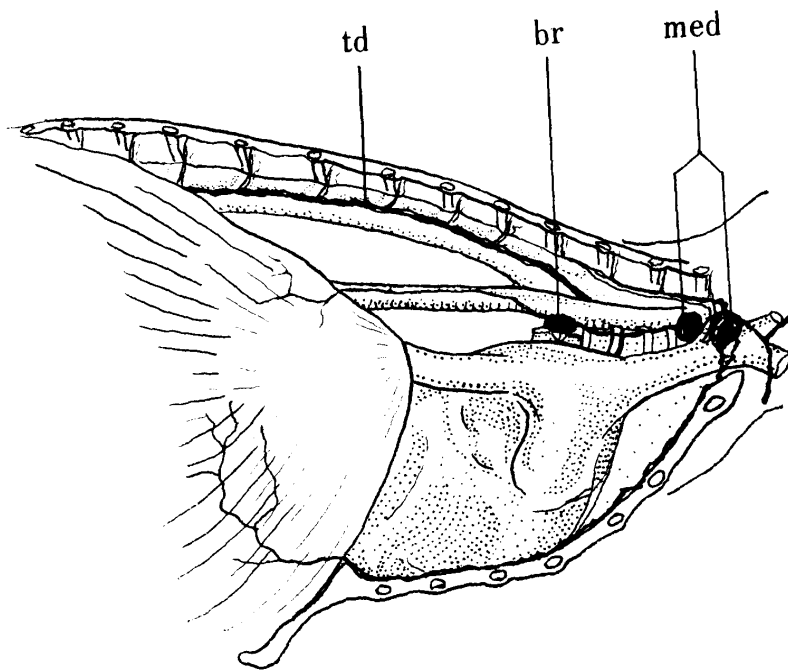


FIG. 5. *Lymph nodes and vessels of thoracic cavity*

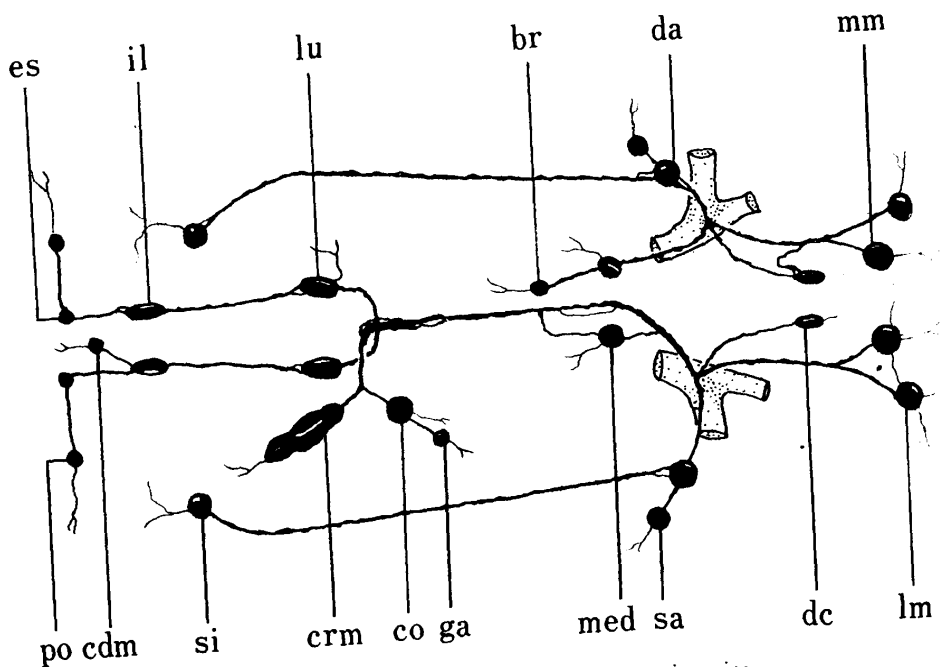


FIG. 6. *Diagram of lymph system in mice*