



Title	SUBCUTANEOUS MULTILOCLAR ECHINOCOCCOSIS IN A VOLE
Author(s)	OH BAYASHI, Masashi; ORI HARA, Miyoji
Citation	Japanese Journal of Veterinary Research, 12(4), 79-82
Issue Date	1964-12
DOI	<a href="https://doi.org/10.14943/jjvr.12.4.79">https://doi.org/10.14943/jjvr.12.4.79</a>
Doc URL	<a href="https://hdl.handle.net/2115/1798">https://hdl.handle.net/2115/1798</a>
Type	departmental bulletin paper
File Information	KJ00002369112.pdf



## SUBCUTANEOUS MULTILOCLAR ECHINOCOCCOSIS IN A VOLE

Masashi OHBAYASHI and Miyoji ORIHARA  
*Department of Parasitology, Faculty of Veterinary  
Medicine, Hokkaido University, Sapporo, Japan*

(Received for publication, August 31, 1964)

Recently the authors observed a case of subcutaneous multiloular echinococcosis in a vole. The animal, a male *Microtus montebelli montebelli* (MILNE-EDWARDS), was obtained from breeding stock from the Institute for Infectious Diseases, at the University of Tokyo. The animal was infected by oral inoculation of about 200 eggs of *Echinococcus multilocularis* LEUCKART, the Alaskan strain, on March 12, 1963 when he was 4 months old. He died on October 26, 1963, 7 months and a half after he was infected.

### FINDINGS

At the time of death the animal was emaciated but the abdomen and the right side from the neck to the thorax were swollen. The total length of the animal was 160 mm and the length of tail 33 mm. Multilocular echinococcal foci were revealed in the liver. The weight of the liver was 18 g, or about ten times normal. The lateral lobes, the caudate lobe and the papillary processes were replaced by echinococcal tissues. This was typical echinococcal tissue; whitish color, medullary appearance and soft elastic consistency. The subcutaneous foci on the right side extended from the posterior portion of the mandible to the axillary region. The foci consisted of six masses with a total weight of 8 g. Of these masses, the largest (25×25×8 mm) was in the neck and the second largest (15×12×8 mm) in the axilla. The others were 6~7 mm in diameter. They were loosely connected to the surrounding tissues and were easily removable. They were enveloped with thin connective tissue and ramous blood vessels and cutaneous muscles. The echinococcal tissue was whitish gray or white, soft and elastic; quite similar to that of the liver echinococci. There were sporadic cystic structures of about 1 mm in size.

Histological sections were stained with hematoxylin-eosin. The echinococcal tissue was composed of cysts of various sizes with very thin cuticles. The cysts contained many brood capsules with scolices and the spaces in the brood capsules were filled with germinative tissue. There were many calcareous corpuscles. The adventitious tissue was fibrous and poorly established. There were frequently observed regressive changes. The scolices and the germinative tissue became shady and there was occasional calcification. The hepatic parenchyma in contact with the echinococci showed pressure atrophy. In lobes without echinococci, there were congestion, interlobular histiocytic accumulation, slight activation of the R. E. S. cells and irregularity in the size of the liver cells. No echinococci were observed

in any organ other than the liver and the subcutis although some congestion was observed. The subcutaneous echinococci were similar to those in the liver, but the cuticle was thicker and there were more regressive changes. There were the blood vessels, muscles, nerves, salivary glands, lymph nodes etc. adjacent to these echinococcal masses. Occasionally islets of lymphoid tissue remained underneath the connective tissue which enveloped the echinococci.

#### DISCUSSION

It is well known that in experimental animals orally infected with echinococci, almost all primary foci of the multilocular echinococci are found in the liver. The data obtained by the present authors are shown below. These experimental animals were investigated during the years 1957 to 1962.

TABLE 1. *Distribution of Multilocular Echinococcal Foci in Experimental Animals (Positive Cases)*

ANIMALS	ORGANS IN WHICH FOCI WERE OBSERVED			TOTAL
	Liver only	Liver and lungs	Liver and Peritoneum*	
<i>Clethrionomys rufocanus bedfordiae</i>	11	2	4	17
<i>Microtus montebelli montebelli</i>	32	—	—	32
<i>Meriones unguiculatus</i>	18	—	—	18
Mice ( <i>Mus musculus</i> )	457	1	8	466
Total	518	3	12	533

\* Metastasis

As is shown in the table, the authors found primary foci in the lungs in only 3 of 533 cases, or 0.56%. In the case reported in the present paper, both the hepatic and subcutaneous echinococcus cysts were considered as primary since they manifested the same degree of scolex formation, regressive changes etc. Lymphoid tissues were found underneath the connective tissue covering the echinococcus. The authors, therefore, conclude that the development of the subcutaneous echinococcus cysts began in the lymph nodes.

There is no report of primary subcutaneous echinococcosis provoked by oral infection of experimental animals. LUBINSKY (1960), however, investigated vegetative propagation of echinococcus in white mice with subcutaneous inoculation and reported that the echinococcal tissue developed well. The present authors (1957) in a study of secondary echinococcosis in mice, also investigated formation of echinococcal foci by subcutaneous inoculation of scolices. It may therefore be

concluded that larval echinococcus, either primary or secondary, can develop in the subcutis of experimental animals. In any case, primary subcutaneous multilocular echinococcosis is very rare phenomenon.

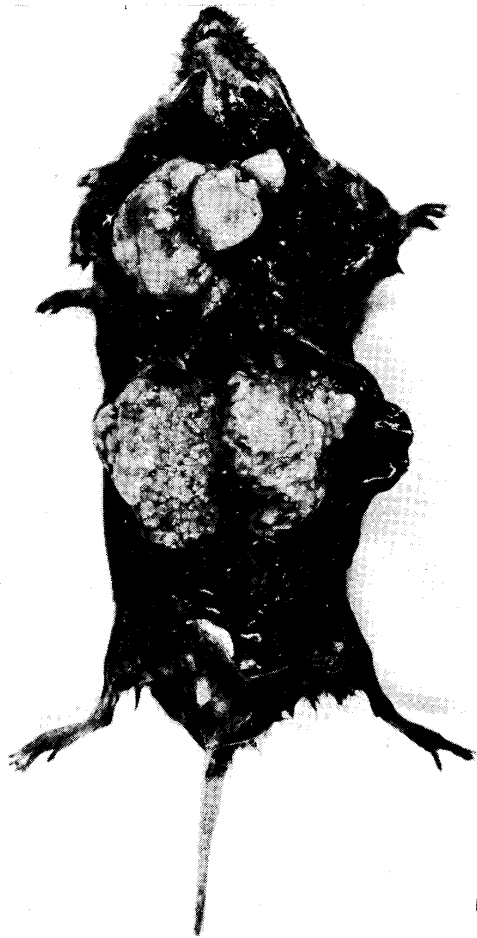
#### SUMMARY

Primary foci of multilocular echinococcosis were found in the subcutis of a male vole as well as in the liver. Initial development of these foci was considered to occur in the lymph nodes.

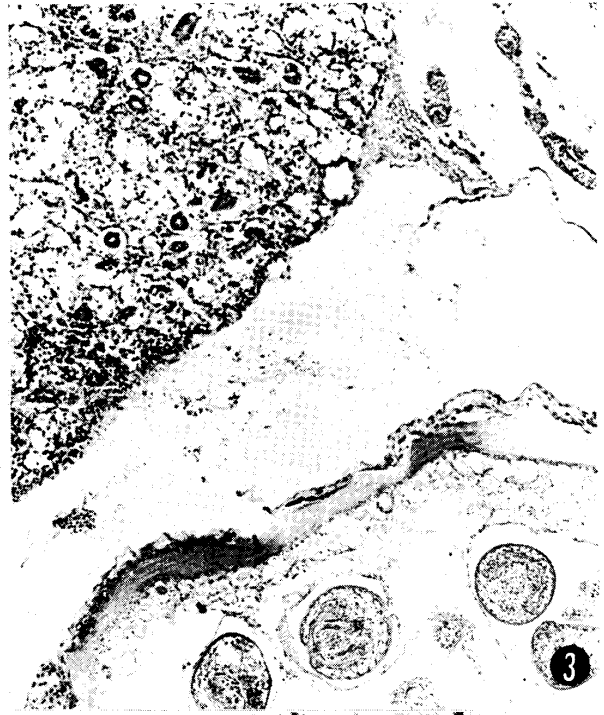#### REFERENCES

- 1) LUBINSKY, G. (1960): *Canad. J. Zool.*, **38**, 1117
- 2) YAMASHITA, J., M. OHBAYASHI & S. KONNO (1957): *Jap. J. vet. Res.*, **5**, 197

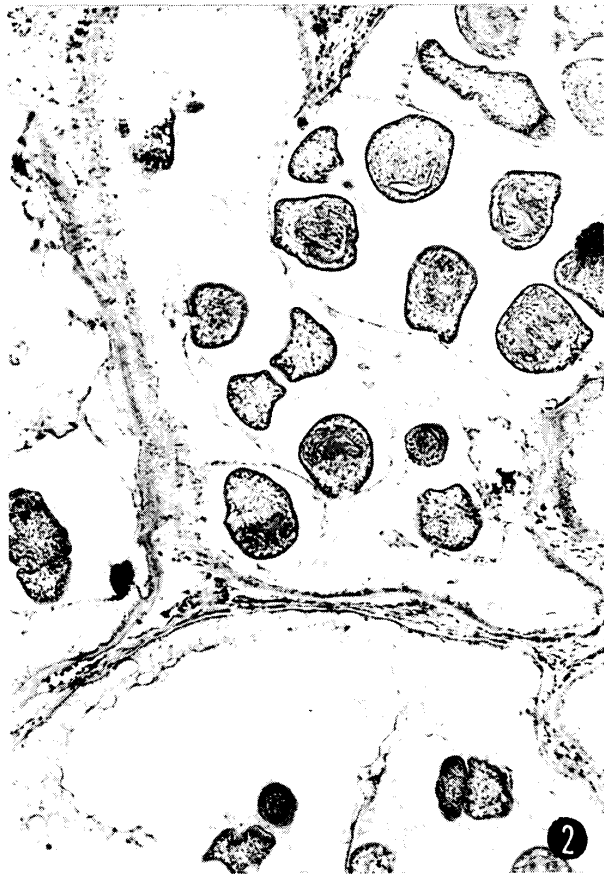



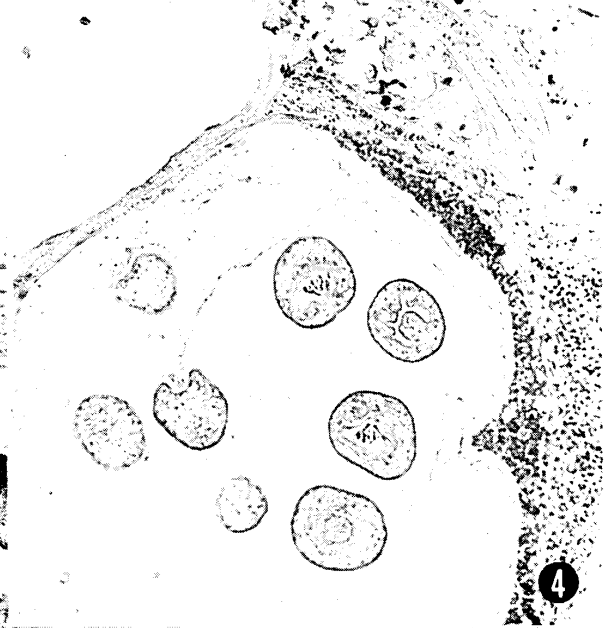1



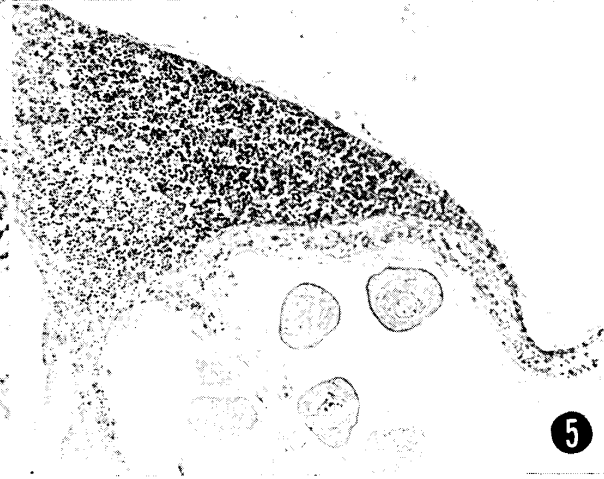
3



2



4



5