



HOKKAIDO UNIVERSITY

Title	FETAL ELECTROCARDIOGRAM IN DAIRY CATTLE : II DIAGNOSIS FOR TWIN PREGNANCY
Author(s)	KANAGAWA, Hiroshi; T00, Kimehiko; KAWATA, Keiichiro et al.
Citation	Japanese Journal of Veterinary Research, 13(4), 111-119
Issue Date	1965-12
DOI	https://doi.org/10.14943/jjvr.13.4.111
Doc URL	https://hdl.handle.net/2115/1828
Type	departmental bulletin paper
File Information	KJ00003418284.pdf



FETAL ELECTROCARDIOGRAM IN DAIRY CATTLE

II DIAGNOSIS FOR TWIN PREGNANCY

Hiroshi KANAGAWA, Kimehiko TOO*¹, Keiichiro KAWATA
and Hitoshi ONO*²

*Department of Veterinary Obstetrics
Faculty of Veterinary Medicine
Hokkaido University, Sapporo, Japan*

(Received for publication, September 16, 1965)

In the previous paper of this series⁹⁾, it was reported that a successful fetal electrocardiogram (F-ECG) of dairy cattle was obtainable after about five months of gestation. This report will deal with a clinical application of the F-ECG technique in diagnosing twin pregnancy in cattle.

HISTORIES OF ANIMALS AND METHODS EMPLOYED

The animals subjected to this study were two pregnant cows in a Holstein herd at the Obihiro Zootechnical College (table). Each cow had received several rectal examinations before and after artificial insemination. At estrum, a mature graffian follicle was palpable in each ovary. At one month after insemination, a corpus luteum developed in each ovary, and at the second month equal bilateral distension of the uterine horns was detected. These findings were deeply suggestive of twin pregnancy. The rectal examination at the fifth month, however, failed to show any signs of twin pregnancy because of the descent of the gravid uterus into the abdominal cavity.

TABLE *Animals examined*

CASE NO.	ANIMAL NUMBER	AGE	EXAMINING STAGES OF PREGNANCY		GESTATION PERIOD	SEXUALITY OF TWINS
			1st	2nd		
		yr. mo.	days	days	days	
1	H-185	5 3	159	211	226 (abortion)	♂, ♀
2	H-218	3 1	219	271	271 (parturition)	♂, ♂

F-ECG was performed twice within a 52-day interval. The technique for recording F-ECG was the same as those described in the previous paper⁹⁾. Case No. 1 aborted heterosexual twins at 226 days of pregnancy, while case No. 2 delivered male twins at 271 days of pregnancy.

*¹ Department of Veterinary Internal Medicine, Faculty of Veterinary Medicine, Hokkaido University, Sapporo, Japan

*² Department of Animal Reproduction, School of Veterinary Medicine, Obihiro Zootechnical College, Obihiro, Japan

For reading the F-ECG in twin pregnancy, the criteria described in the previous paper⁹⁾ are applicable, since there is no essential difference in interpretation of an ECG of either single or multiple patterns. In order to prevent mis-reading, a tracing method was employed; i. e., three spike rhythms corresponding to the mother (M) and two fetuses (f_1 & f_2) were analyzed.

RESULTS

1) F-ECG in twin pregnancy

a) Case No. 1

F-ECG was carried out at 159 and 211 days of pregnancy. At 159 days, complete rhythms with QRS spikes of the twins and the mother were obtained in 3 out of 11 different leads tested. As shown in figures 4-a and b, by leads 1-22 and 1-4, the small amplitude of twin fetuses (f_1 & f_2) could be distinguished from maternal rhythm (M), whereas, by other leads (figs. 4-c, d & e) three different rhythms were not recognizable. Such incomplete recordings may be due to the relation between the fetal position in utero and the lead position. In isolated tracings (figs. 4-f, g & h) copied from an original cardiogram by lead 1-22 (fig. 4-a), the polarity of respective spikes showed QS (negative) type in maternal and f_2 patterns, while R (positive) type in f_1 .

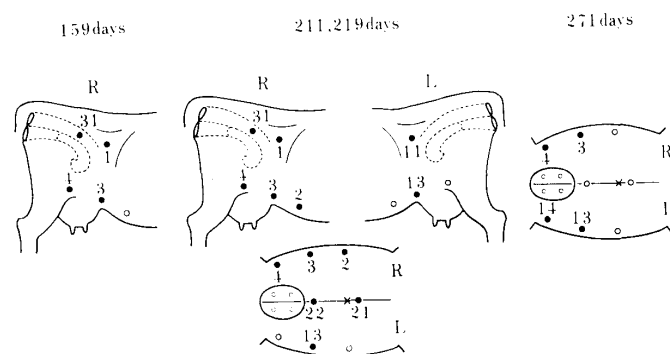
F-ECG at 211 days showed more clearly both maternal and fetal spikes in the majority of leads tested (24 out of 28). Figure 5-a shows maternal and fetal ECG by lead 11-22, and figures 5-b, c and d give isolated tracings of the mother and twin fetuses, respectively.

b) Case No. 2

Recording of the F-ECG was tried at 219 and 271 days of pregnancy. At 219 days, cardiograms with 3 complete rhythms were obtained in almost all of the leads tested (20 out of 21). Figures 7-a, e, f and g show electrocardiograms in different leads. Figures 7-b, c and d indicate isolated tracings copied from figure 7-a (lead 1-3), respectively. In the lead 1-3, the maternal spike appeared as positive-R type pattern, f_1 as QR type and f_2 as RS type, respectively. Polarity and amplitude of these 3 QRS complexes varied with the lead, except for lead 1-3 in which positive deflection varied with amplitude. These differences in polarity or amplitude may be caused by positional relations between the fetal heart and lead points as it does in F-ECG in single pregnancy. The P and T waves of the fetuses could not be recorded.

In experiments made at 271 days, however, 3 complete rhythms for the mother and twins were detected in only 5 out of 24 different bipolar leads. An example of electrocardiograms from a lead between the right flank and the left abdomen is given in figure 6-a. Isolated tracings copied from this clearly indicate maternal and twin ECG (figs. 6-b, c & d). In this lead, QRS patterns of twin fetal hearts were shown by similar configuration to the maternal one but with negative deflection and smaller amplitude. In other leads, however, QRS pattern and amplitude caused by 3 hearts' activation varied with lead positions. Furthermore, a complete recording including maternal and two fetal spikes was limited to several leads among all leads tested. An incomplete recording with two kinds of spikes could not give an exact definition whether the spikes might be produced by the maternal heart or the heart of one of twins.

FIGURE 1 *Suitable lead positions for recording F-ECG of twins*



- Notes R : Right side
 L : Left side
 ● : Suitable lead positions
 ○ : Incomplete or negative lead positions

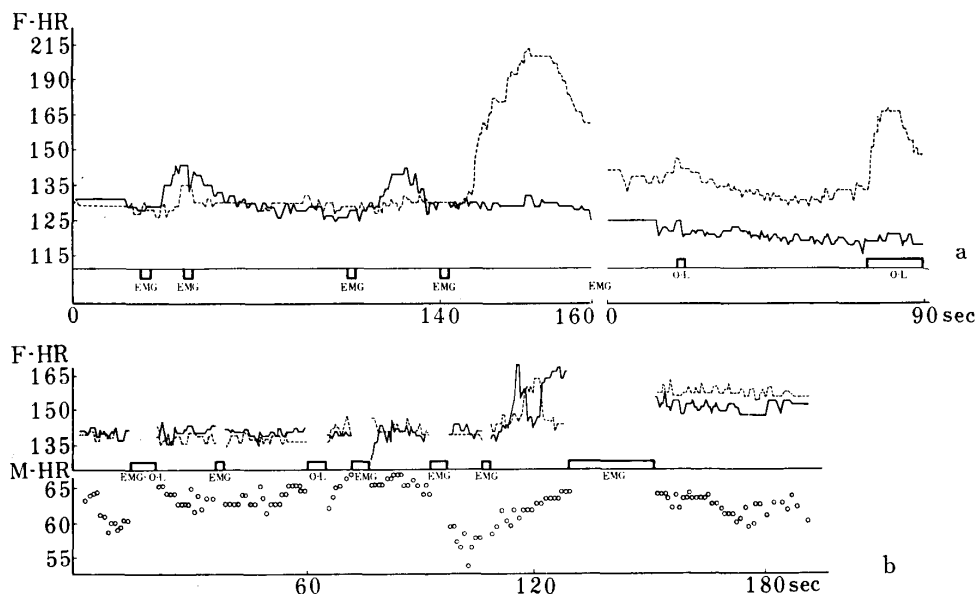
From the results described above, satisfactory recording of F-ECG in twin pregnancy was effected by lead methods and fetal ages. It can be concluded that as suitable lead methods for electrocardiographical diagnosis of twin pregnancy, as shown in figure 1, vertical right side as well as middle-right side leads will be recommended at 159 days of pregnancy, almost all of the leads at 211 and 219 days, and side-side leads at 271 days, respectively.

2) Heart rates of twin fetuses

The fetal heart rates of twins can be pursued only by continuous recording of F-ECG within few minutes by certain leads. In this experiment, a respective heart rate of twins was calculated from the number of R-R intervals per minute.

Two examples of different types in heart rate changes are presented in figure 2. A pattern shown in figure 2-a was obtained from recording of case No. 2 at 219 days of pregnancy. In this figure, the heart rate of one fetus, provisionally named as f_1 (dotted line), indicates about 130 per minute during first 140 seconds, but during subsequent 10 seconds, it increases rapidly up to 215, then decreases to 150. While, the heart rate of the other fetus, f_2 (full line), keeps an almost constant level of about 130 per minute during the same time. After F-ECG recording was stopped for 10 seconds due to disturbances of maternal electro-myogram (EMG), f_1 shows a gradual decrease and returns to an about 130 level during 40 seconds, then it suddenly increases up to about 165. On the contrary, f_2 slightly decreases and maintains an about 120 level. Another example obtained from recording of case No. 1 at 159 days of pregnancy is given in figure 2-b. The recording in this case is frequently compelled to stop due to EMG disturbance or O-line movement. During first 100 seconds, the heart rates of twins show a similar level of about 140 per minute. After about 120 seconds from initial recording, f_2 (full line) increases over 160 and is followed by a similar increased level of f_1 (dotted line). After a long time of EMG disturbances, both heart rates show a continuation with a higher level of about 150~160 per minute.

FIGURE 2 Heart rates of twin fetuses



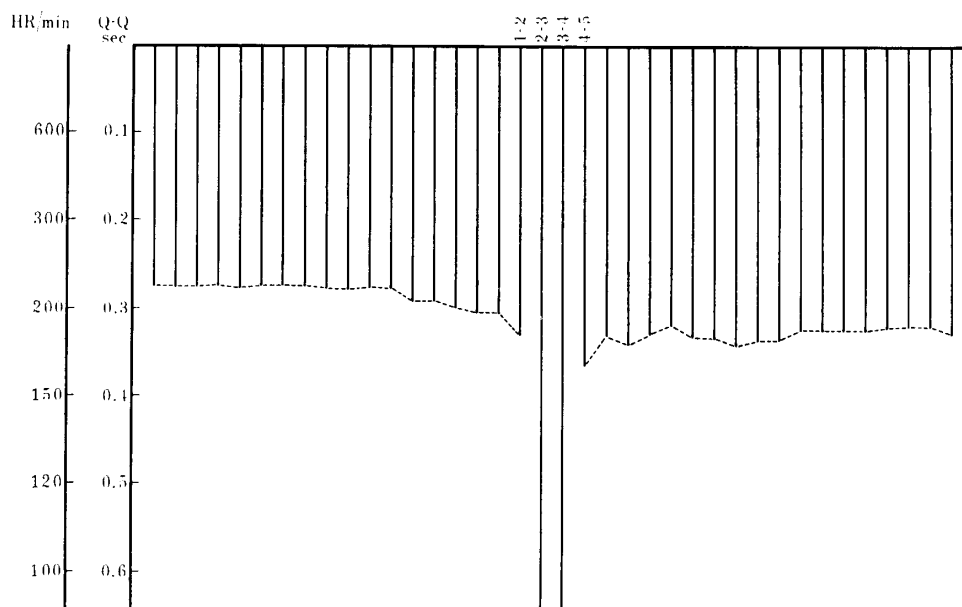
- Notes
- a : Case No. 2, 219 days of pregnancy
 - b : Case No. 1, 159 days of pregnancy
 - F-HR : Fetal heart rate
 - M-HR : Maternal heart rate
 - EMG : Maternal electromyogram
 - O-L : O-line movement
 - : f_1
 - : f_2

3) Fetal arrhythmia

During the course of recording of F-ECG of twins in this study, arrhythmia was observed in a fetus when its fetal heart rhythm showed heavy tachycardia, although a complete analysis of arrhythmia was not carried out, because it was difficult to record clear P and T waves of F-ECG by the present authors' method.

In case No. 2, at 219 days of pregnancy, tachycardia was recorded in one of twins (fig. 8-a). Isolated tracings of each rhythms copied from figure 8-a are shown in figures 8-b (mother), c (f_1) and d (f_2). Each heart rate per minute was counted as 84 in mother, 200 in f_1 and 132 in f_2 , respectively. In the copied strip of f_1 (fig. 8-c), absence of heart beat (ventricular activation: QRS complex) is observed twice between the beat number of 2, 3 and 4 at the central portion of the strip. Every Q-Q intervals of this strip were counted and the values are given in figure 3. A slight prolongation of Q-Q interval observed before and after absence of heart beat means a decrease in heart rate. The Q-Q interval between heart beats 1 and 2 was 0.33 seconds; likewise, between 2 and 3, 0.64; 3 and 4, 0.64; 4 and 5, 0.36, respectively. Intervals between 2 and 3, as well as 3 and 4, corresponded to about 2 times between 1 and 2. This may indicate that beat 3 was activated by the same heart activation

FIGURE 3 Fetal arrhythmia of No. 2 (219 days)



Notes HR: Fetal heart rate 1-2 }
 Q-Q: Q-Q interval 2-3 } Q-Q intervals near arrhythmia
 3-4 } area in fig. 8-a
 4-5 }

mechanism as in beats 1 and 2, which were controlled under the same rhythm production factor. Furthermore, it may be thought that this type of ventricular drop may be due to either sinoauricular block or auriculoventricular block which may arise when transmission of a rhythm occurring at the sinus node to the auricle or ventricle will be disturbed. It is, however, difficult to clarify the exact character of arrhythmia unless P wave recording. In the same material, a similar type of arrhythmia was observed during tachycardia and heavy sinus arrhythmia was also recorded without ventricular drop.

DISCUSSION

Clinical diagnosis of twin pregnancy in cattle has so far mainly been based on several findings on rectal examination, such as equal enlargement of bilateral uterine horns or uterine arteries, the presence of two amniotic vesicles, or the presence of two fetuses (ROBERTS). In majority cases of bovine twin pregnancy, one corpus luteum is present in each ovary and a fetus in each horn, but, sometimes, two corpora lutea are palpable in a single ovary while gestation is bicornual, and sometimes both fetuses are in the same horn. In addition, in identical twins, there should be encountered a single corpus luteum with two developing fetuses. The decisive diagnosis of twin pregnancy is, therefore, somewhat difficult by rectal palpation.

The incidence of twinning in dairy cattle is comparatively high. According to PFAU et al., the literature shows the number of twin births in dairy cattle to range from less than 0.5 to 4.5 per cent, and in certain herds to be as high as 8.8 per cent. In Holstein-Friesian the incidence is highest among dairy breeds. In this connection, a reliable diagnostic method for twin pregnancy in dairy cattle is needed.

In human medicine, F-ECG technique has been introduced into obstetrics and there are some reports concerning fetal-electrocardiographic diagnosis of twin, triple or quadruple pregnancy^{2,4)}. In the veterinary field, however, we can see the only report by AMADA & SENDA, who were successful in recording fetal electrocardiograms in twin pregnancy of seven months in a race horse mare. The present article is, therefore, presumably the first report concerning F-ECG in twin pregnancy in cattle.

LARKS suggested that it is important to select suitable posture of patients at recording for obtaining clear F-ECG in multiple pregnancy in the human. As it is considerably difficult to control various postures in domestic animals, the normal standing position was used throughout the course of this experiment. Selection of suitable lead positions seems more important in the case of twin pregnancy in cattle. In order to obtain a complete recording with 3 rhythms of twins and the mother, it should be recommended to select vertical right side or middle-right side leads at the fifth month of pregnancy, and side-side leads at the ninth month. At the seventh month, however, every bipolar leads between the rectum, flank, mid-line or each side of lower abdomen will be advisable.

When three rhythms with similar intervals, amplitudes and similar spike patterns are recorded in one electrocardiogram, it becomes difficult to identify the maternal and fetal ones by means of using an apparatus with a one channel system. In such instances, it should be recommendable to make isolated traces of each rhythm by copying from the original electrocardiogram, although this method is time consuming. In order to prevent such trouble, application of an electrocardiograph with two or more channel system seems theoretically more desirable, although such an apparatus was not used in this experiment. Furthermore, for the purpose of diagnosing multiple pregnancies, such as triplets or quadruplets, the multiple channel system is undoubtedly convenient. In cattle, however, as the incidence of multiple pregnancies except twins is generally very low, the one channel recorder may be sufficient for clinical use.

In human cases, it is suggested that the direction of fetal spike deflection can give an information for diagnosing fetal position in utero in advanced pregnancy^{5,8)}. This may be valuable for obstetricians. If this concept is allowed to apply to bovine cases,—although, at present, there is no experimental basis to support it—

it can be said that when the direction of fetal QRS is accord with that of maternal one, the fetal position in utero is dorsal, i.e., the apex of the fetal heart faces ventral, and when the direction of fetal QRS is opposite to that of maternal one, the fetal position is ventral, i.e., the apex of the fetal heart faces dorsal. It is interesting to note that in some electrocardiograms in twin pregnancy, there observed two QRS patterns with different directions, one of which being as same as maternal QRS direction and the other opposite. This may suggest that the fetal positions of the twins may be opposite with each other. Before the conclusion is to be confirmed, however, much more work will be required. Particularly, radiographic investigations may be helpful to demonstrate fetal position in utero.

As shown in figure 2, heart rates in twin fetuses are generally in a similar level, but, sometimes, fetal heart rate of one fetus alone suddenly increases while the other keeps the previous rate. Why does such a phenomenon happen? The answer is now obscure, but there is a possibility that some unknown factors may influence to fetal heart rates of twins. If an external factor may give simultaneously some stimulus of the same degree to both of the fetuses, the response in heart rates of twins against the stimulus seems to occur in a same manner at the same time or with a certain difference in time. Therefore, as for the reasons of such discordance in fetal heart rates of twins, as appeared in this figure, it should be considered that some other factors which control fetal heart rate within fetus itself, or which effect upon the response ability of fetuses against various stimuli, may be concerned. In order to clarify these problems, however, further advances on fetal physiology will be needed.

In human cases³⁾, various abnormalities in F-ECG, such as irregularity of ST-T, extrasystol, paroxysmal tachycardia, auricular flutter and fibrillation, sinoauricular block, auriculoventricular block, or bundle branch block, have been reported. These abnormal heart beats appear, in general, under various unhealthy conditions of the mother. Likewise, in this experiment, a type of sinoauricular or auriculoventricular block and a type of sinus arrhythmia were observed. These types of arrhythmia experienced by the authors, however, may be due to a physiological response of the fetal heart control system against severe tachycardia, not due to some kind of disorders or injuries in the fetal heart. The reasons are as follows; firstly such arrhythmia was observed temporarily and not recurrently, and secondly a gradual prolongation in Q-Q intervals appeared before and after arrhythmia.

In conclusion, the electrocardiographic diagnosis of bovine twin pregnancy is successful after five months of gestation, as well as in single pregnancy. In order to prevent mis-diagnosis, selection of suitable lead positions is important, especially

at the fifth month of pregnancy. For diagnosing more multiple pregnancies in cattle, an apparatus with two or three channel system will be desirable.

SUMMARY

The fetal electrocardiographic technique was employed for diagnosing bovine twin pregnancy. Two gravid Holstein cows suspected of twin pregnancy from their previous histories were subjected to this study. Each cow received fetal electrocardiogram examinations twice with a 52-day interval; case No. 1 at 159 and 211 days of pregnancy, while case No. 2 at 219 and 271 days. Both of the cases were decided afterward to be a twin pregnancy at the time of abortion or parturition.

Successful electrocardiograms with different three QRS patterns of two fetuses and the mother were obtainable after five months of pregnancy by means of one channel system recording. It was important, however, to select different suitable lead position with gestational stages, particularly in the earlier pregnant stages. Fetal heart rates of twins calculated from the number of R-R intervals per minute in a continuous recording were generally in a similar level, but, sometimes, one of twins showed tachycardia while the other did not. In addition, during the tachycardiac stage, fetal arrhythmia was observed. The reasons of these phenomena were also discussed in viewpoint of fetal physiology.

The authors wish to express their gratitude to Dr. T. ISHIKAWA, Professor of Department of Veterinary Obstetrics, for his kind guidance, and to Dr. M. MIYAKE, Professor of Obihiro Zootechnical College, for his kind advice and supply of materials.

REFERENCES

- 1) AMADA, A. & SENDA, T. (1964): Proceedings of the 57th Meeting of the Japanese Society of Veterinary Science, *Jap. J. vet. Sci.*, **26**, Suppl., 431 (summary in Japanese)
- 2) BERNSTINE, R. L. & BORKOWSKI, W. J. (1955): *Amer. J. Obstet. & Gynec.*, **70**, 631
- 3) HON, E. H. & LEE, S. T. (1963): *Ibid.*, **87**, 804
- 4) LARKS, S. D. (1959): *Ibid.*, **77**, 1109
- 5) LARKS, S. D. & DASGUPTA, K. (1958): *Amer. Heart J.*, **56**, 701
- 6) PFAU, K. O., BARTLETT, J. W. & SHUART, C. E. (1948): *J. Dairy Sci.*, **31**, 241
- 7) ROBERTS, S. J. (1956): *Veterinary obstetrics and genital diseases*, Ithaca, New York: published by the author
- 8) SOUTHERN, E. M. (1957): *Amer. J. Obstet. & Gynec.*, **73**, 233
- 9) TOO, K., KANAGAWA, H. & KAWATA, K. (1965): *Jap. J. vet. Res.*, **13**, 71

EXPLANATION OF PLATES

PLATE I

Fig. 4 Fetal electrocardiograms in case No. 1 at 159 days of pregnancy

- a: Lead 1-22 } Twins QRS (f_1 & f_2) and maternal one (M) are observed.
- b: Lead 1- 4 }
- c: Lead 22-21 } Two spike rhythms of maternal (M) and one of twins
- d: Lead 22- 3 } (f) are obvious.
- e: Lead 22- 4 QRS of only one fetus is seen, while those in both
mother and another fetus are not detected.
- f: Isolated trace of maternal electrocardiogram copied from original
recording (a)
Maternal spikes (M) showing QS type
- g: Isolated trace of one fetal electrocardiogram copied from (a)
Fetal spikes (f_1) showing R type
- h: Isolated trace of another fetal electrocardiogram copied from (a)
Fetal spikes (f_2) showing Q type

PLATE II

Fig. 5 Fetal electrocardiograms in case No. 1 at 211 days of pregnancy

a: Lead 11-22

Three different spike rhythms of maternal (M) and two fetuses (f_1 & f_2) are identified.

b: Isolated trace of maternal electrocardiogram copied from original recording (a)

c } Isolated traces of two fetal electrocardiograms (c: f_1 & d: f_2) copied
d } from (a)

Fig. 6 Fetal electrocardiograms in case No. 2 at 271 days of pregnancy

a: Lead 1-13

Three different spike rhythms of maternal (M) and two fetuses (f_1 & f_2) are identified.

b: Isolated trace of maternal electrocardiogram copied from original recording (a)

c } Isolated traces of two fetal electrocardiograms (c: f_1 & d: f_2) copied
d } from (a)

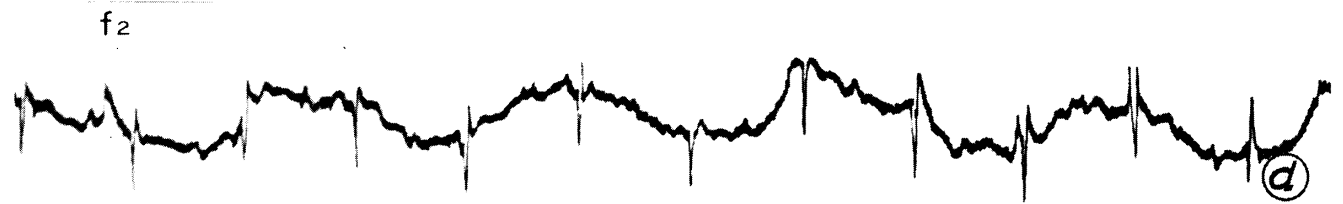

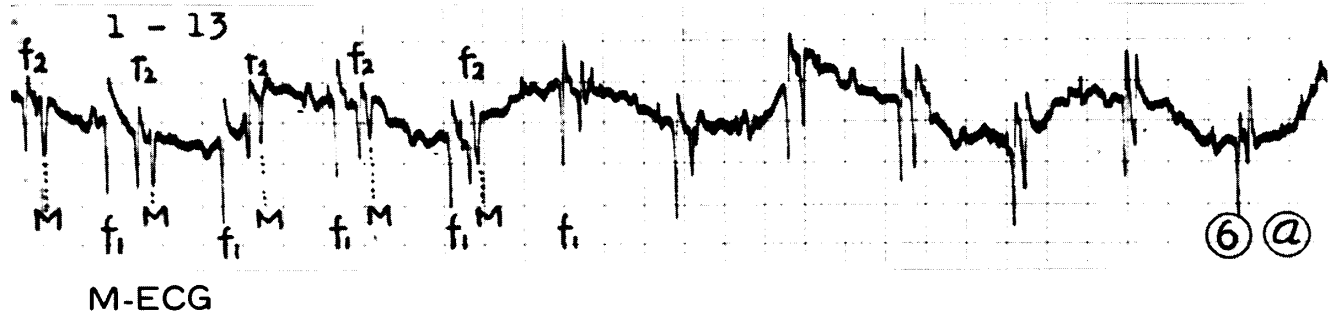



PLATE III

Fig. 7 Fetal electrocardiograms in case No. 2 at 219 days of pregnancy

a: Lead 1-3

Three different spike rhythms of maternal (M) and two fetuses (f_1 & f_2) are identified.

b: Isolated trace of maternal electrocardiogram copied from original recording (a)

c } Isolated traces of two fetal electrocardiograms (c: f_1 & d: f_2) copied
d } from (a)

e: Lead 1-21 }
f: Lead 11-13 } Three different spike rhythms of maternal (M) and two
g: Lead 11-21 } fetuses (f_1 & f_2) are observed.

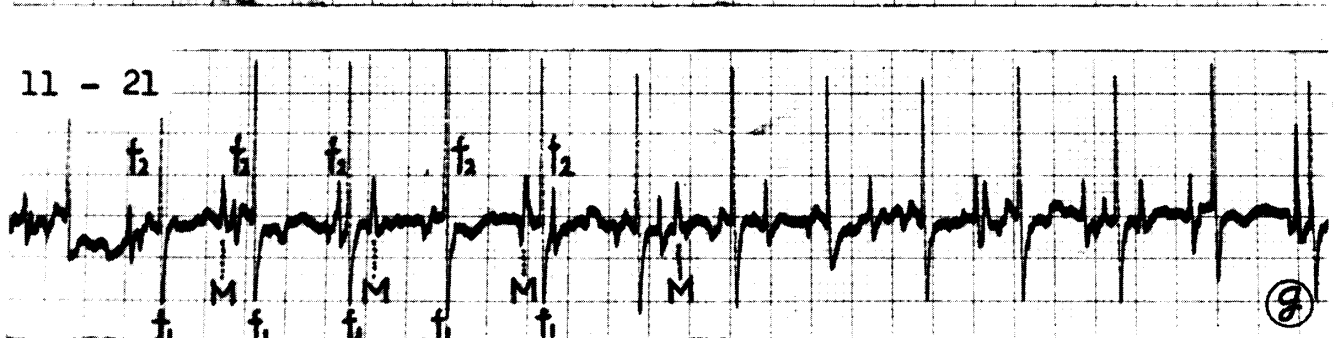
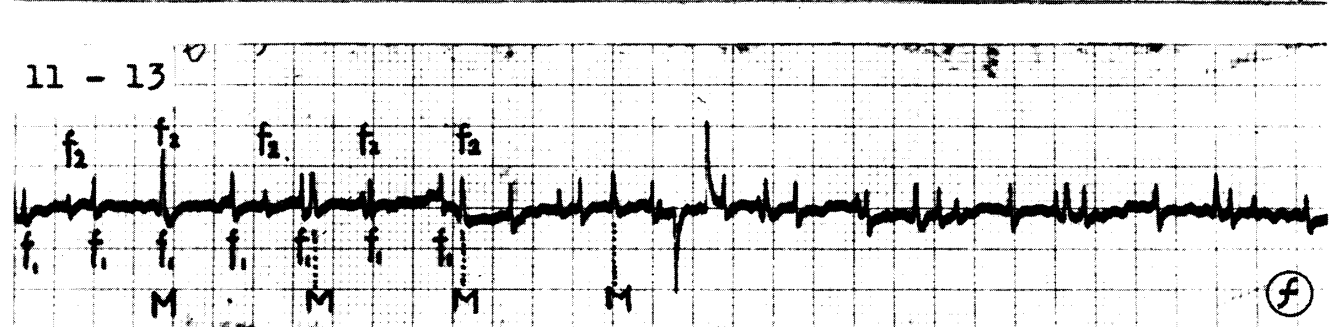
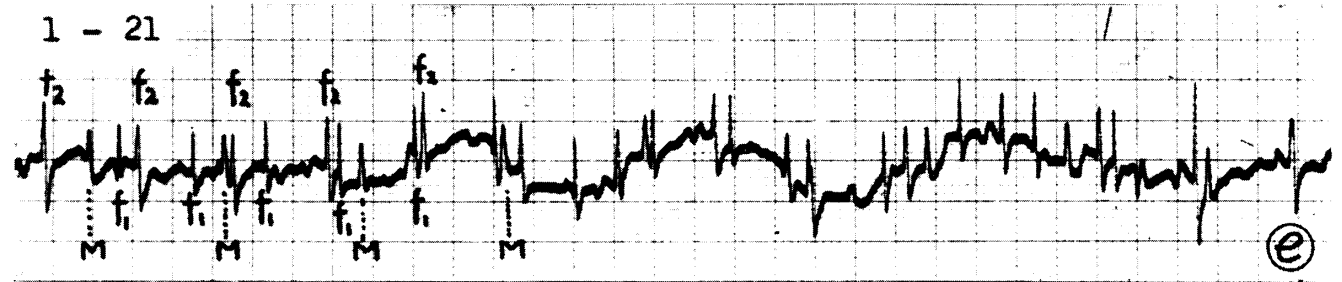


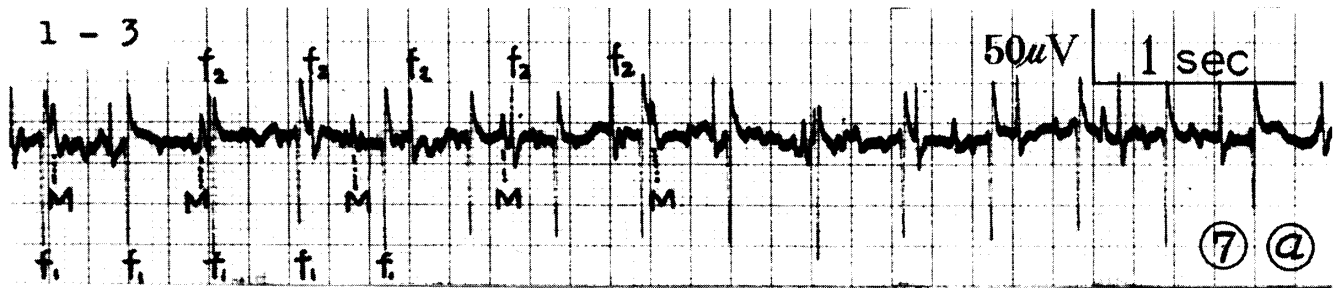


PLATE IV

Fig. 8 Fetal electrocardiograms in case No. 2 at 219 days of pregnancy

a: Lead 22-1

Original recording paper

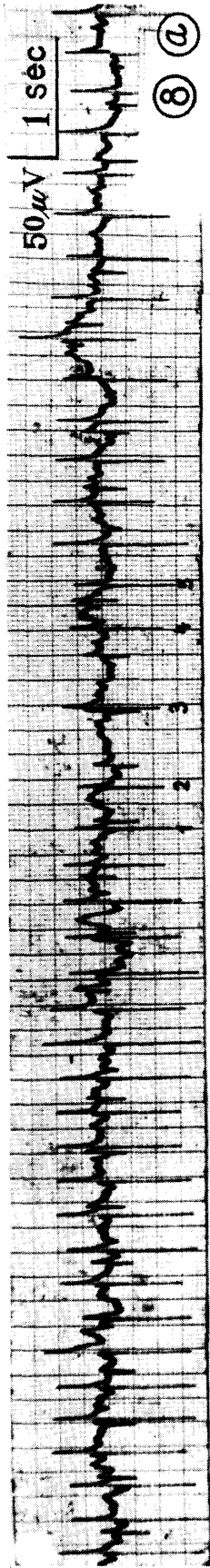
Q-Q intervals between 2~3 and 3~4 showed fetal arrhythmia (one of twins: f_1)

b: Isolated trace of maternal electrocardiogram (black spots) copied from original recording (a)

c: Isolated trace of one fetal electrocardiogram copied from (a)

Fetal spikes (f_1) showing arrhythmia between 2~3 and 3~4 of Q-Q intervals

d: Isolated trace of another fetal spikes (f_2) copied from (a)



M-ECG

