



# HOKKAIDO UNIVERSITY

Title	SEX-CHROMOSOME CHIMERISM (XX/XY) IN HETEROSEXUAL BOVINE TRIPLETS
Author(s)	KANAGAWA, Hiroshi; KAWATA, Keiichiro; ISHIKAWA, Tsune et al.
Citation	Japanese Journal of Veterinary Research, 13(4), 121-126
Issue Date	1965-12
DOI	<a href="https://doi.org/10.14943/jjvr.13.4.121">https://doi.org/10.14943/jjvr.13.4.121</a>
Doc URL	<a href="https://hdl.handle.net/2115/1829">https://hdl.handle.net/2115/1829</a>
Type	departmental bulletin paper
File Information	KJ00003418285.pdf



# SEX-CHROMOSOME CHIMERISM (XX/XY) IN HETEROSEXUAL BOVINE TRIPLETS\*<sup>1</sup>

Hiroshi KANAGAWA, Keiichiro KAWATA, Tsune ISHIKAWA,  
Jun-ichi MURAMOTO\*<sup>2</sup> and Hitoshi ONO\*<sup>3</sup>

*Department of Veterinary Obstetrics  
Faculty of Veterinary Medicine  
Hokkaido University, Sapporo, Japan*

(Received for publication, September 20, 1965)

In the previous papers<sup>5~8,10)</sup>, the present authors reported that there exists a sex-chromosome chimerism (XX/XY) in both freemartins and their co-twins in cattle, and that this gives a fundamental basis for a successful early diagnosis of bovine freemartinism.

In this report are presented chromosomal data of a set of heterosexual triplets consisting of two freemartins and one male, as well as a non-freemartin female from another heterosexual triplets origin and a set of homosexual triple females. Some morphological findings of the freemartins will be described also.

## MATERIALS AND METHODS

Some details of the histories of the individuals and sources of materials subjected to the present study are given in table 1. Nos. 4~7 were multiparous cows, not freemartins. Two animals co-tripled with No. 4 were both males and were not subjected to this study, because of death immediately after delivery. The sources of samples for chromosomal study were the blood, bone marrow, thyroid, kidney, seminal vesicle-like structure, gonad and lung. But, in Nos. 4~7, blood alone was used. The procedures for chromosomal study by means of leukocyte culture, colchicine treatment of bone marrow cells and tissue culture were the same as those described in the previous papers<sup>5~8,10)</sup>.

Nos. 1~3, a set of heterosexual triplets, were slaughtered at the age of one year and 8 months for the purpose of obtaining tissue culture materials. The sexual organs of the freemartins were examined macroscopically and histologically.

## RESULTS

### 1) Chromosomal findings

In table 1 are presented chromosomal findings from blood cultures, bone marrow cells

\*<sup>1</sup> A part of this work was released at the 6th Meeting of the Japanese Association of Zootechnical Veterinarians (Hokkaido) on September 7, 1965 in Sapporo.

\*<sup>2</sup> Zoological Institute, Faculty of Science, Hokkaido University

\*<sup>3</sup> Department of Animal Reproduction, School of Veterinary Medicine, Obihiro Zootechnical College, Obihiro, Japan

TABLE 1 *Some accounts for materials and chromosomal findings*

NO.	ANIMAL NUMBER	AGE	SEX	NO. OF PARTUS	SOURCE	NO. OF CELLS COUNTED	SEX-CHROMOSOME		
							XX	XY	Chimera
		yr.mo.							
1*1	F7-1	1 8	Freemartin	—	Blood	64	30	34	+
					Bone marrow	52	24	28	+
					Thyroid	50	50	0	—
					Kidney	50	50	0	—
					Seminal vesicle-like structure	50	50	0	—
					Gonad	50	50	0	—
2*1	F7-2	1 8	Freemartin	—	Blood	52	24	28	+
					Bone marrow	50	22	28	+
					Thyroid	14	14	0	—
					Kidney	19	19	0	—
3*1	F7-3	1 8	Male	—	Blood	55	27	28	+
					Bone marrow	50	23	27	+
					Lung	105	0	105	—
					Kidney	27	0	27	—
4*2	F16-M	8 8	Female	4	Blood	50	50	0	—
5*3	F23-1	4 9	Female	3	Boold	50	50	0	—
6*3	F23-2				Boold	50	50	0	—
7*3	F23-3				Boold	23	23	0	—

Notes: \*1 A set of heterosexual triplets

\*2 A non-freemartin female from another heterosexual triplets origin

\*3 A set of homosexual triple females

treated with colchicine and tissue cultures of 18 materials from 7 animals.

In blood and bone marrow materials from a set of heterosexual triplets, 2 freemartins (Nos. 1 & 2) and a male (No. 3), 2A-XX/2A-XY chimerism was observed. The chimera ratios of leukocytes and bone marrow cells tended to parallel each other among the triplets. In statistical analyses by means of chi-square test, XX/XY ratios among these three individuals as well as those of leukocytes and bone marrow cells failed to show any significant differences ( $P < 0.05$ ). On the other hand, cultures from 6 tissue materials including thyroid, kidneys, gonads and seminal vesicle-like structures of the 2 freemartins revealed a normal female complement with an XX-mechanism, and also cultures from 2 materials of lung and kidney of the co-tripled male indicated a normal male complement with an XY-mechanism.

Furthermore, a non-freemartin female of another heterosexual triplets origin (No. 4) and a set of homosexual triple females (Nos. 5~7) failed to show any evidence of chimerism; all of the cultured leukocytes examined always had an XX-mechanism without exception.

TABLE 2 *Measurements of sexual organs of freemartins*

NO.	ANIMAL NUMBER	AGE	GONAD* <sup>1</sup>	UTERINE HORN* <sup>2</sup>	SEMINAL VESICLE-LIKE STRUCTURE* <sup>1</sup>	WOLFFIAN DUCT* <sup>3</sup>	VAGINA* <sup>4</sup>	VULVA* <sup>4</sup>
		yr.mo.	cm	cm	cm	cm	cm	cm
1	F7-1	1 8	R: 2.6×2.3×2.0 L: 2.2×1.8×0.5	5.2×1.7×1.7 3.7×1.8×1.7	7.0×1.8×1.5 7.5×1.8×1.4	13.0×0.9 13.0×0.8	8.5	5.0
2	F7-2	1 8	R: 1.5×0.5×0.5 L: 1.5×0.6×0.5	4.0×0.8×0.7 1.5×0.6×0.5	4.0×1.0×0.8 4.0×1.0×0.8	3.0×0.4 ( 0.5×0.2 1.0×0.3	6.5	6.0

Notes \*<sup>1</sup>: Length×width×thickness R: Right side  
\*<sup>2</sup>: Length×width×diameter L: Left side  
\*<sup>3</sup>: Length×diameter  
\*<sup>4</sup>: Length

## 2) Morphological findings of sexual organs of freemartins

Macroscopical appearances of the sexual organs of 2 freemartins are shown in figure 6, and measurements of the main sexual organs are given in table 2.

In both cases, several typical morphological characteristics of freemartin were observed: absence of the oviduct and cervix, the hypoplastic uterus and anterior vagina, the over-developed clitoris, the presence of the seminal vesicle-like structures and rudimentary structures of the Wolffian ducts. The hymen was persistent in No. 1, and the well-developed ovarian blood vessel plexuses were observed bilaterally in No. 2.

Histologically, the right gonad of No. 1 had 5 corpus luteum-like structures (diameter: 0.3~1.9 cm) and one follicle (0.3 cm). The left gonad had 3 small follicles (0.1~0.2 cm) and 2 corpus luteum-like structures (0.1~0.3 cm). These luteal masses included many large luteal cells with irregular shapes. The bilateral gonads of No. 2 had one small follicle (0.1 cm) each, the wall of which was lined with a layer of connective tissue, thus, resembling so-called small cystic degeneration. In the central portion of the bilateral gonads in both cases, a net-like structure, rete ovarii, was observed. In No. 1, at the surrounding portion of the rete ovarii, there existed a mass of small tubes somewhat resembling immature seminiferous tubules. In the uterine horns and seminal vesicle-like structures in both freemartins, undeveloped gland-like structures were observed in the tunica propria. The rudimentary Wolffian ducts had a central cavity, with the surrounding portion containing small gland-like structures scattered here and there.

## DISCUSSION

It has been well known that the bovine freemartin commonly arises among heterosexual twin pregnancies. Likewise, in greater multiples born with males, the incidence of freemartins has been reported<sup>2,4,13)</sup>. Before the chromosomal studies of the freemartin were recently carried out by several investigators including the authors<sup>3,5~12)</sup>, however, the main interest concerning such sexual abnormality has been concentrated on the morphological characteristics of the sexual organs. As described in the previous papers<sup>5~8,10)</sup>, it was an epoch-making event that these chromosomal studies were successful in demonstration of sex-chromosome chimerism (XX/XY) in both freemartins and their co-twin males, whereas no chimerism was detected among normal females co-twin with males as well as single born males or females.

Emphasis should be placed on the fact that such chimerism was also demonstrated in cultured leukocytes and bone marrow cells from a set of bovine heterosexual triplets involving freemartins. In addition, the chimera ratios in the above mentioned cells were parallel with each other among these three individuals. A statistical analysis of the incidental rate of the chimerism among them failed to show significant differences ( $P < 0.05$ ). This fact coincides with the findings in the case of heterosexual twins<sup>5,6)</sup>.

No chimerism was observed in tissue cultures from some organs, such as thyroid, kidneys, gonads or seminal vesicle-like structures, of the triplets, whereas there was chimerism in various degrees in those of twin cases<sup>5,6</sup>), although the incidence of chimerism in the latter is generally low in such organs. The reasons of this discordance are still unknown.

Two freemartins submitted to the present study differed considerably in the macroscopical and histological characteristics of the sexual organs, despite having similar characters in the sex-chromosome chimerism. That is, the degree of morphological deviation in freemartins does not seem to depend upon the degree of the chimerism. In order to draw a decisive conclusion of this subject, however, much more work will be required.

No chimerism was observed, on the other hand, in cultured leukocytes from 4 multiparous cows, one female co-tripled with males and a set of homosexual triple females, which were submitted to this study as controls. This fact may give a fundamental basis for the employing of the chromosomal diagnosis of freemartins to heterosexual bovine triplets. In order to ascertain the diagnosis, it is recommended that all individuals involved in twins or greater multiples should be subjected to be examined chromosomally.

#### SUMMARY

The chromosome constitution of a set of bovine heterosexual triplets consisting of two freemartins and one male was studied by means of blood culture, colchicine treatment of bone marrow cells and tissue cultures from several organs. As controls, four multiparous cows, including one female from another heterosexual triplets origin and a set of homosexual triple females, were also studied chromosomally using the blood culture technique. The sexual organs of the freemartins were examined macroscopically and histologically.

The results are summarized as follows:

1) Cultured leukocytes and bone marrow cells in both freemartins and the co-tripled male manifested 2A-XX/2A-XY chimerism. The chimera ratios were parallel with each other among these three individuals. Tissue cultures from thyroid, kidneys, lung, gonads and seminal vesicle-like structures of these animals failed to show chimerism. No chimerism was observed, on the other hand, in leukocyte cultures from the control animals. Thus, freemartins involved in heterosexual triplets can also be diagnosed chromosomally as well as in the case of twins.

2) Two freemartins submitted to this study considerably differed in the morphological characteristics of the sexual organs, despite having similar characters in sex-chromosome chimerism.

The present authors wish to express their gratitude to Dr. M. MIYAKE, Professor of Department of Animal Reproduction, Obihiro Zootechnical College, for his kindness to provide three animals as materials used in this study.

#### ADDENDUM

During this article in press, OHNO and GROPP reported germ cell chimerism in a set of bovine triple fetuses, 12 mm in crown-rump length, and BASRUR also observed blood cell chimerism in all individuals of a set of heterosexual quintuple calves.

#### REFERENCES

- 1) BASRUR, P. K. (1966): personal communication
- 2) BISSONNETTE, T. H. (1928): *Amer. J. Anat.*, **42**, 29
- 3) FECHHEIMER, N. S., HERSCHLER, M. S. & GILMORE, L. O. (1963): Proc. XI internat. Cong. Genet., **1**, 265
- 4) ISHIHARA, M. (1952): *Bull. Chugoku-Shikoku agric. Exp. Stat.*, (2) 315 (in Japanese with English summary)
- 5) KANAGAWA, H., KAWATA, K. & ISHIKAWA, T. (1965): *Jap. J. vet. Res.*, **13**, 43
- 6) KANAGAWA, H., KAWATA, K. & ISHIKAWA, T. (1966): *Jap. J. Anim. Reprod.*, **12**, 13 (in Japanese with English summary)
- 7) KANAGAWA, H., MURAMOTO, J., KAWATA, K. & ISHIKAWA, T. (1965): *Jap. J. vet. Res.*, **13**, 33
- 8) MAKINO, S., MURAMOTO, J. & ISHIKAWA, T. (1965): *Proc. Jap. Acad.*, **41**, 414
- 9) MAKINO, S., SASAKI, M. S. & SOFUNI, T. (1962): *Ibid.*, **38**, 542
- 10) MURAMOTO, J., ISHIKAWA, T. & KANAGAWA, H. (1965): *Nucleus*, **8**, 25
- 11) OHNO, S. & GROPP, A. (1965): *Cytogenetics*, **4**, 251
- 12) OHNO, S., TRUJILLO, J. M., STENIUS, C., CHRISTIAN, L. C. & TEPLITZ, R. L. (1962): *Ibid.*, **1**, 258
- 13) RAJAKOSKI, E. & HAFEZ, E. S. E. (1963): *Anat. Rec.*, **147**, 457

#### EXPLANATION OF PLATES

##### PLATE I

- Figs. 1 & 2 Lateral and frontal views of a set of heterosexual triplets  
Nos. 1 and 2 are freemartins, and No. 3 is a male.
- Fig. 3 Serial alignments of supposed homologous pairs of chromosomes in cattle, showing female pattern with 2A-XX (upper) and male pattern with 2A-XY (bottom) × 800
- Fig. 4 Metaphase chromosomes with 2A-XX from gonadal culture of a freemartin (No. 1) × 1,000
- Fig. 5 Metaphase chromosomes with 2A-XY from kidney culture of a male (No. 3) × 1,000

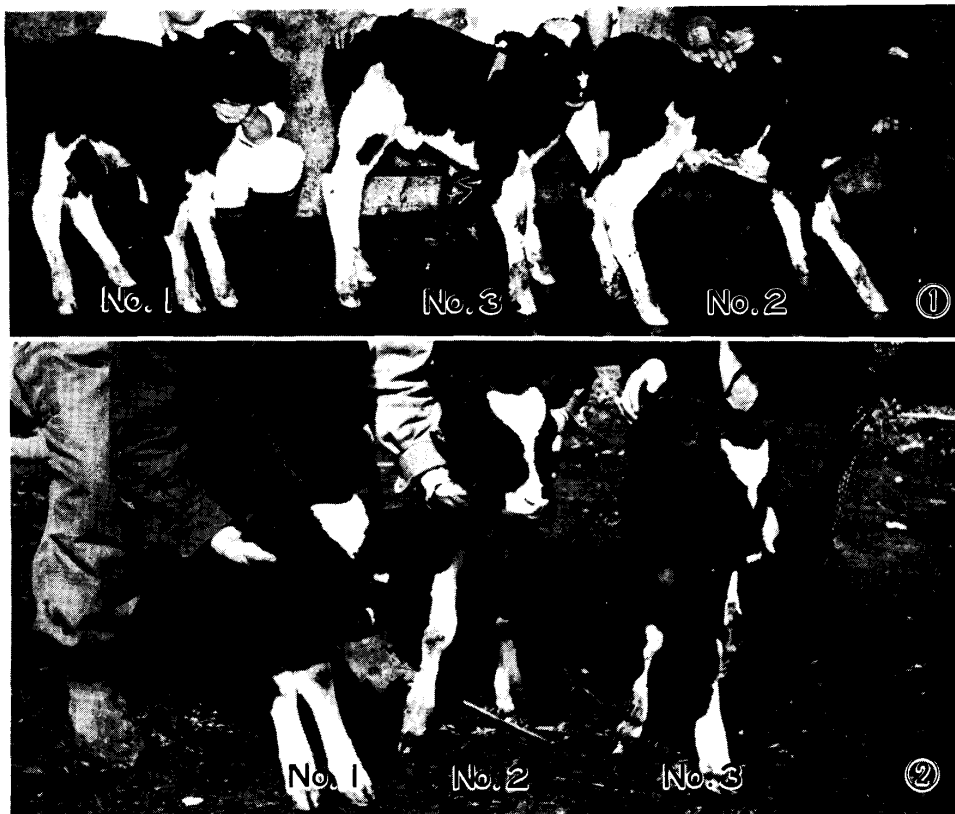




PLATE II

Fig. 6 Dorsal views of sexual organs of 2 freemartins of No. 1 (upper) and No. 2 (bottom)

VA: Vagina

UT: Uterine horns

SV: Seminal vesicle-like structures

GO: Gonads

Fig. 7 Metaphase figures with sex-chromosome chimerism from a blood culture of a freemartin (No. 1)

Note XX (upper) and XY (bottom).

× 1,000

Fig. 8 Sex-chromosome chimerism in a blood culture of a freemartin (No. 2)

Note XX (upper) and XY (bottom).

× 1,000



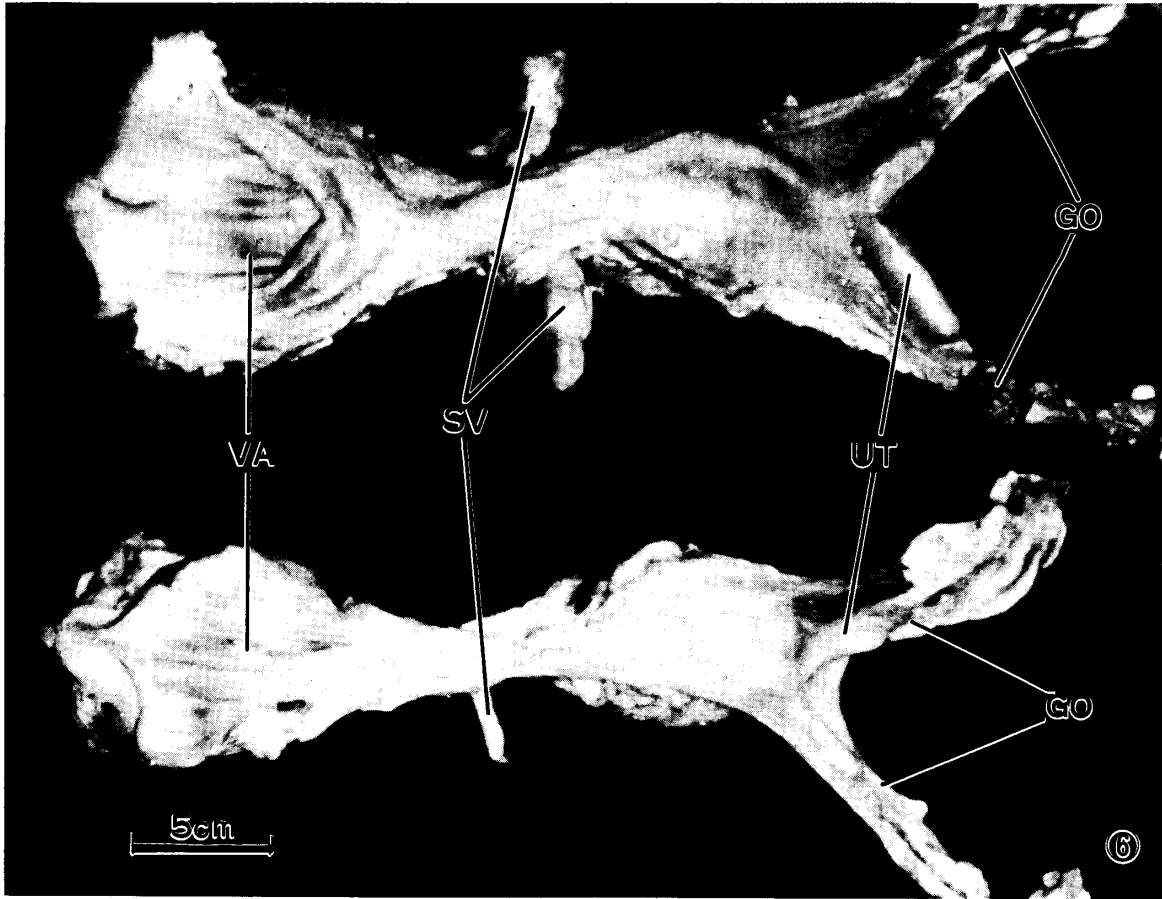


PLATE III Microphotographs of sexual organs of No. 1 (hematoxylin-eosin stain)

- Fig. 9 Left gonad has rete ovarii (right upper), and stroma which contains many small cyst-like structures resembling primary follicles or immature seminiferous tubules. × 140
- Fig. 10 Higher magnification of a part of figure 9  
Small cyst-like structures contain several cells. × 560
- Fig. 11 Right gonad has several small follicles with degenerating follicular walls. × 140
- Fig. 12 A group of large luteal cells in right gonad × 560
- Fig. 13 A part of uterine mucosa with immature uterine glands × 140
- Fig. 14 Seminal vesicle-like structures × 140

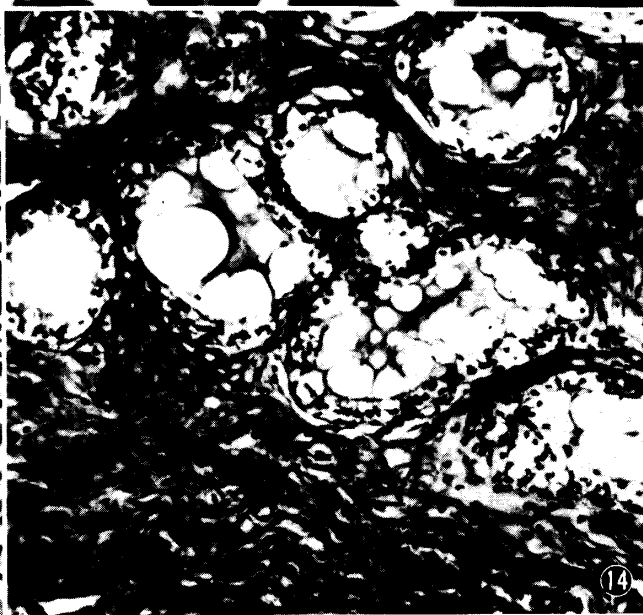
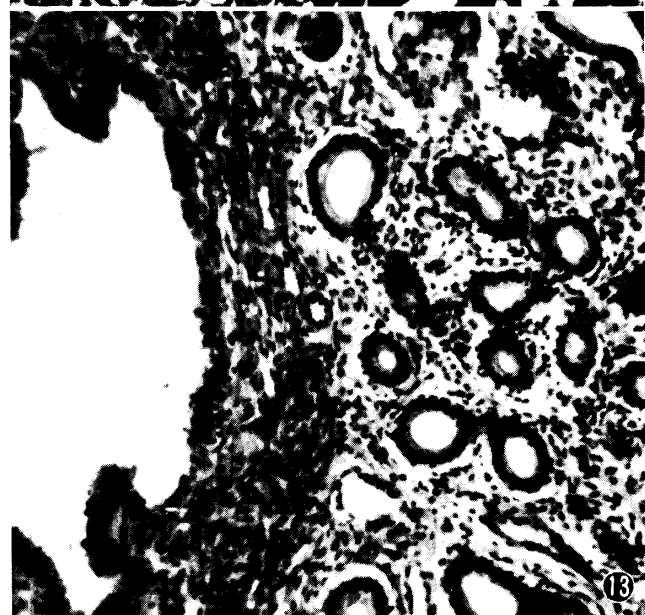
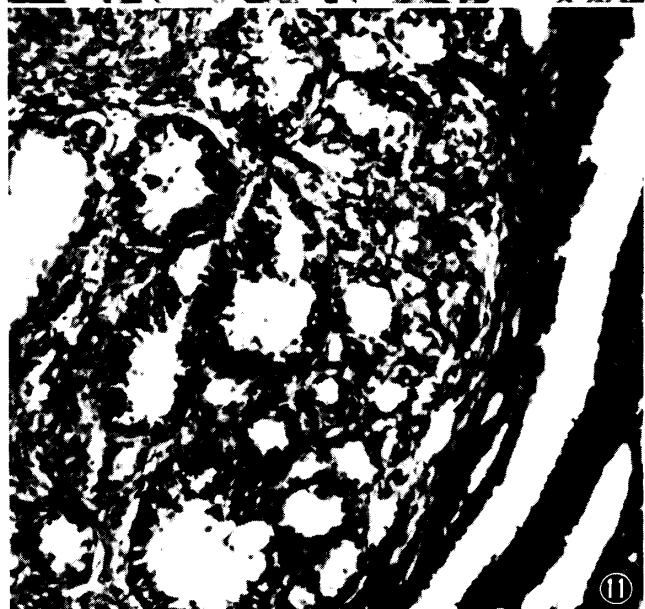
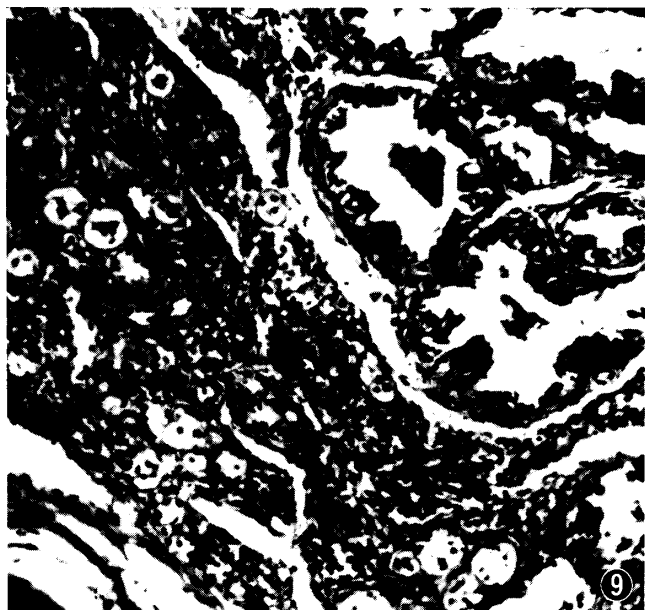


PLATE IV Microphotographs of sexual organs of No. 2 (hematoxylin-eosin stain)

- Fig. 15 Rete ovarii (upper) and stroma of left gonad × 56
- Fig. 16 A part of a small follicle in left gonad  
Zona granulosa is almost absent and theca follicli is replaced by a layer of  
connective tissue. × 140
- Fig. 17 Uterine mucosa with undeveloped glands, some of which are atrophic  
× 140
- Fig. 18 Cut surface of rudimentary Wolffian duct × 56

