



HOKKAIDO UNIVERSITY

Title	ELECTRON MICROSCOPIC OBSERVATIONS ON THE MONONUCLEAR CELLS IN THE PERIPHERAL BLOOD OF THE CLINICALLY NORMAL AND LYMPHOSARCOMA COWS
Author(s)	SONODA, Mitsuo; MARSHAK, Robert R.
Citation	Japanese Journal of Veterinary Research, 18(1), 9-20
Issue Date	1970-03
DOI	https://doi.org/10.14943/jjvr.18.1.9
Doc URL	https://hdl.handle.net/2115/1941
Type	departmental bulletin paper
File Information	KJ00002369813.pdf



**ELECTRON MICROSCOPIC OBSERVATIONS ON THE
MONONUCLEAR CELLS IN THE PERIPHERAL
BLOOD OF THE CLINICALLY NORMAL
AND LYMPHOSARCOMA COWS***

Mitsuo SONODA** and Robert R. MARSHAK

*Department of Clinical Studies, School of Veterinary Medicine
University of Pennsylvania, New Bolton Center
Kennett Square, Pennsylvania, U.S.A.*

(Received for publication, November 20, 1969)

The mononuclear cells obtained from the peripheral blood of the two groups of clinically normal and pre-leukemic lymphosarcoma cows were examined with the use of an electron microscope, and the findings were discussed comparatively.

The results thus obtained were summarized as follows.

1) In the peripheral blood of the clinically normal and lymphosarcoma cows, there were lymphocytes, monocytes, plasmacytes and 4 other types of mononuclear cells which were classified temporarily by the authors into plasmacytic, monocytic, small lymphocytic and large lymphocytic mononuclear cells.

The large lymphocytic mononuclear cells were observed more frequently in the blood of the lymphosarcoma group.

2) In the lymphocytes of the clinically normal group, the cells with nuclear inclusion bodies were sometimes observed and the cells with nucleoli and well-developed Golgi complex were observed rarely. The cells with nuclear invaginations and nuclear defects were not observed at all.

3) In the lymphocytes of the lymphosarcoma group, the cells with nucleoli, nuclear invaginations, nuclear defects and well-developed Golgi complex were sometimes observed, but the cells with nuclear inclusion bodies were observed very rarely.

4) There were no significant differences in the frequency of appearance of these mononuclear cells excepting large lymphocytic mononuclear cells between clinically normal and lymphosarcoma groups.

5) Virus-like particles were observed in the content of a nuclear defect of the lymphocyte in one case of the lymphosarcoma group.

INTRODUCTION

Hematological examinations are the most important routine works^{2,12,27,35)} for the diagnosis of bovine lymphosarcoma. In the differential counting of leukocytes of the peripheral blood smears of the lymphosarcoma, abnormal cells such as "unusual" or atypical lymphocytes and so-called tumor cells have been observed

* This work was supported by Public Health Service Contract 43-65-1013 within the Special Virus Cancer Program of the National Cancer Institute.

** Present address: Department of Veterinary Internal Medicine, Faculty of Veterinary Medicine, Hokkaido University, Sapporo, Japan

by many investigators^{10~13,16,17,19,22~24,30,32,35,36)}

However, these abnormal cells are unspecific for the lymphosarcoma and frequently occur in the blood of normal cattle or cattle with a variety of non-neoplastic conditions^{19,30,32,35~37)}. The characters of these cells have not been very clear so that their clinical diagnostic significances for bovine lymphosarcoma have been disputed^{19,32,36,37)}.

Therefore, the authors have attempted the electron microscopic observations on the mononuclear cells in the peripheral blood of the clinically normal and lymphosarcoma cows in order to clarify further the characters of these cells.

In this paper, the results obtained by the authors are described.

MATERIALS AND METHODS

1 Cows for the experiments

Five clinically normal cows and 6 cows diagnosed as lymphosarcoma by the clinical and hematological examinations and biopsies of the lymph nodes were provided for the experiments.

They were reared in the leukemia farm of the University of Pennsylvania at New Bolton Center and were all Jersey breed.

TABLE 1 *Hematological findings of cows used for the experiments*

GROUPS	COW NO.	AGE	PCV	LEUK.	Hb	LEUKOCYTES					
						Neut.	Ly.	Mon.	Eos.	Bas.	Aty. ly.
			%		g/dl	%	%	%	%	%	%
Normal	1	6	30.5	7,950	.	29.0	52.0	1.5	16.5	0.5	0.5
	2	5	27.5	8,850	.	30.5	61.0	2.0	5.5	0	1.0
	3	3	24.0	7,950	.	31.5	66.0	1.0	1.0	0	0.5
	4	4	26.5	6,950	.	32.5	55.5	0.5	10.0	1.0	0.5
	5	3	25.5	11,500	.	20.5	72.5	0.5	5.0	1.0	0.5
Lympho-sarcoma	6	9	37.0	22,000	12.8	6.0	82.0	3.0	8.0	1.0	0
	7	7	28.5	23,000	9.7	12.0	79.0	0	9.0	0	0
	8	9	32.0	20,000	10.4	13.0	78.0	2.0	5.0	1.0	1.0
	9	9	30.5	30,000	10.7	9.0	88.0	1.0	0	2.0	0
	10	8	31.0	16,800	10.8	9.0	83.0	2.0	5.0	1.0	0
	11	7	27.5	17,000	10.4	11.0	74.0	0	14.0	0	1.0

The hematological findings of the cows were listed in table 1. The total numbers of leukocytes in the lymphosarcoma cases were ranging between 16,800 and 30,000, respectively.

In the hemogram, lymphocytes were observed in high percentages in all of the lymphosarcoma cases. But it may be said that there were no cases with leukemic blood findings in them. They had slightly or moderately increased lymphocytes over all.

2 Collection of blood

From the jugular vein of the cows described above, the blood was collected in bottles containing acid-citrate-dextrose solution.

3 Collection of leukocytes

It was done according to the hemolytic method reported by BEHRENS & ESCH, viz., 10 ml of anti-coagulated whole blood in a beaker was diluted with 20 ml of distilled water and was mixed gently for 20 seconds. Just after that time, it was isotonized by admixing 5 ml of 4.5% NaCl solution. The hemolysate was transfused in conical test tubes of 20 ml and the tubes were centrifuged for 5 minutes at 2,000 rpm. The supernatants were thrown away as perfectly as possible. The sediments thus obtained were mixed clusters of leukocytes and thrombocytes.

4 Fixation and dehydration

The sediments were fixed with phosphate-buffered glutaraldehyde of pH 7.2 for one hour in the conical tubes. At this stage, the sediments became pellets. Then, the sediments were released from the wall of the tube by a small wooden spatel, and they were fixed again for 5 hours to allow complete fixation. The pellets were transferred into new tubes and they were rinsed with a buffered phosphate solution of pH 7.2 for 12 hours. Then, they were postfixed in phosphate-buffered 1% osmic acid solution of pH 7.2 for one hour.

They were dehydrated in a graded series of acetone and were embedded in Durcupan (Swiss Fluka Co.).

5 Cutting and examination

The thin sections were cut with glass knives on an LKB ultra-microtome. After mounting on copper grids, the sections were stained with uranyl acetate and lead citrate solutions, and examined under Siemens electron microscope, Elmicope I at magnifications varying from 3,000 to 10,000.

OBSERVATIONS

Of the cells in the visual fields of the cut planes, the granulocytes such as neutrophils, eosinophils and basophils, and thrombocytes were readily differentiated from the mononuclear cells by their specific granules, the typical shapes of their nuclei and the clearly differentiated cytoplasms in their characteristic pattern.

In all parts of the visual fields, the mononuclear cells always exceeded any kinds of granulocytes in the number of their appearance.

In these observations, the mononuclear cells excepting the granulocytes appearing in the visual fields were examined at random.

1 Lymphocytes

1) Typical lymphocytes

Almost all of the mononuclear cells observed in the visual fields of the sections from both the clinically normal and the lymphosarcoma groups consisted of the typical lymphocytes.

Some of these lymphocytes were shown in figures 1, 2 and 3.

Their shapes were round or ovoid in general but they were slightly irregular in contours. The nuclei of these cells were generally round, oval or irregularly round in form and they frequently had slight or deep indentations. The cells with two separated nuclear lobes were not rarely observed, either. The nuclei were lined with nuclear membranes. The materials making up the background of the nuclei presented a very fine, relatively diffuse density, which was almost similar to that of the cytoplasm.

In the nuclei, two parts, one dense, the other less dense depending upon the amount of chromatin condensation were observed. Especially, these chromatin condensations were found attached to the nuclear membranes, but some of them were scattered all over the nuclei and they had a maculous appearance.

The cytoplasm surrounding the nuclei was always narrow and was delineated sharply by a very fine cell membrane. A fine, dust-like, greyish opacity made up the cytoplasmic background. The innumerable fine point-like granules were distributed closely and evenly throughout the entire cytoplasm. There was a small number of mitochondria in the transverse or longitudinal section. They were round, ovoid or elongated in form in accordance with the cut directions, and the size of the round one was about $0.3\sim 0.5\mu$ in diameter. Furthermore, there were some small endoplasmic reticulum-like vacuoles in the cytoplasm.

In the cytoplasm of some lymphocytes, small round bodies with high electron density were observed. These were supposed to coincide with so-called azure granules.

The centrosomic region of the normal lymphocytes was relatively poorly developed and the Golgi complex was only composed of a few vesicles, therefore, they were not recognizable in almost all of the cut planes of the cytoplasm.

2) Lymphocytes with nuclear inclusion body

In the nuclei of some of the lymphocytes, peculiar nuclear inclusion bodies were observed. The whole figures of these cells and the inclusion bodies were shown in figures 4~9, respectively.

In morphology, there was no difference between the typical lymphocytes and the lymphocytes with inclusion bodies except the existence of the inclusion bodies.

These bodies were always spherical in shape and ranging about $200\sim 1,000\text{ m}\mu$ in diameter. They were invariably composed of two layers, an inner and an outer. The outer layer consisted of numerous filaments in a concentric or spiral arrangement which encircled perfectly the inner layer. On the other hand, the inner layer was usually composed of a homogeneous substance of lower electron density with a variable number of dense granules, and it looked like the core of the body. Sometimes, these dense granules scattered in the outer layer.

Up to the present time, the lymphocytes with nuclear inclusion bodies have been sometimes observed among the lymphocytes obtained from the clinically normal group but very rarely among those obtained from the lymphosarcoma group.

3) Lymphocytes with nucleolus

The nucleoli in the nuclei were pictured in figures 10~13.

The whole figures of these nucleoli were round or irregularly round. They were about $700\sim 1,200\text{ m}\mu$ in size. They were composed of two zones. The inner zones were

about 500 m μ in size and were filled with comparatively dense fine granules. The outer zones which surrounded the inner zones circularly were composed of more dense and fine granules. In some of the lymphocytes, the double structures of the nucleoli were obscure and they looked like maculae.

The nucleoli were sometimes observed in the nuclei of the lymphocytes obtained from the lymphosarcoma group. However, in those from the clinically normal group, they were observed rarely.

4) Lymphocytes with nuclear invagination

Lymphocytes with nuclear invaginations were shown in figures 13~17. In the cut planes of these cells, in some parts of the nuclear margins, the nuclear membranes jutted out into the cytoplasm and made irregular rings. At the inside of these rings, they were filled with the same substance as that of cytoplasm. The projections of the nuclear membranes were very severe in some of the nuclei, but in others, they were very slight.

On the other hand, on the basis of the cubic consideration of these findings, it should be understood that the invagination into the nucleus occurred in a part of the nuclear membrane and at the same time the cytoplasm invaded into the cave.

The nuclear strands which were free in the cytoplasm were always covered with nuclear membranes on both sides, and they had chromatin granules with high electron density between them.

In some of these lymphocytes, both the nucleolus and nuclear invagination were observed in the nucleus.

The lymphocytes with nuclear invaginations were observed only in the lymphocytes obtained from the lymphosarcoma group and never from the clinically normal group.

5) Lymphocytes with nuclear defect

These cells were shown in figures 18~23. The nuclear defects were always observed at the inner parts of the nuclei. There were several kinds of defects in them. Some of them just looked like holes in the nuclei and they sometimes contained a granular substance or a substance which was identical with the cytoplasm inside them. Some of them consisted of a poly-vesicular structure and in these vesiculae, no substance or a substance with low density was present.

In some of the cells, the several small vacuolous defects were present dispersed the nuclei.

These nuclear defects were observed only in the lymphocytes obtained from the lymphosarcoma group.

Furthermore, in the content of a nuclear defect of the lymphocyte only from the lymphosarcoma group, several spherical particles as shown in figure 23 were observed. They had a diameter of approximately 80~140 m μ having dense cores.

6) Lymphocytes with well-developed Golgi complex

As described above, the Golgi complex of the typical lymphocytes was very much reduced in the development. But in some of the lymphocytes, very well-developed Golgi complex were observed.

Some of these Golgi complex were shown in figures 24 and 25.

In the cytoplasm of these cells, around the centrosomic region, clear centrioles and Golgi complex with lamellae and many vesicles were present.

The lymphocytes with well-developed Golgi complex were observed in both of the clinically normal and lymphosarcoma groups, but they were predominant in the latter cases in the number of their appearances.

2 Monocytes

Some of the typical monocytes were shown in figures 26~28. The contour of the cell was limited by the serrated cell membrane.

The nucleus of each monocyte had a distorted aspect with large protuberances. Chromatin was collected in clumps which adhered to the nuclear membrane.

In the cytoplasm, the Golgi complex was represented by lamellae which broke up into numerous small vesicles. Some large vacuoles were distributed throughout the cytoplasm. The granules of the monocytic cytoplasm differed in size and aspect. Some had quite a large homogeneous and gray structure. These seemed to be mitochondria. Other small ones were enclosed by a membrane and corresponded to the azurophil particles of monocytes. There were a number of endoplasmic reticulum scattered throughout the whole cytoplasm and some of them had many ribosomes with them.

Up to the present time, the morphological difference between the monocytes of the clinically normal and lymphosarcoma groups has not been recognized by the authors.

3 Plasmacytes

The plasmacytes observed in these observations were pictured in figures 29~31.

The nuclei of the cells were generally round in form, but sometimes, irregular ones were observed, too. They presented large clumps of chromatin in the nuclei.

The entire cytoplasm was filled with a system of parallel membranes in a more or less concentric arrangement in relation to the nucleus. This was the characteristic of this cell. However, the development of these lamellar structure was very diverse in accordance with each individual cell.

In close contact to one side of these membranes, small dark granules could be seen. The arrangement of these granules was such that there was alternately a space between the two membranes which included granules at both sides.

The mitochondria were always located in this space and surrounded with cytoplasm. The spaces between the smooth side of the membranes were distended and filled with a light gray homogeneous substance.

In these observations, the plasmacytes were seen rarely in both the clinically normal and lymphosarcoma groups.

4 Other mononuclear cells

1) The 1st type

The cells which were temporarily classified in this type were shown in figures 32~35.

The nuclei of these cells were very irregular in form and were maldistributed to one side in the cells. They had several sharp indentations in their contours.

In the nucleus, there was rather dense chromatin. These chromatin condensations were found attached to the nuclear membrane, but they were observed scattered in the inner parts of the nuclei, too.

In some of the cells, nucleoli were observed. In general, the nuclear structure of these cells was similar to that of the lymphocytes.

The cytoplasm was filled with fine point-like substances gathering to form small granules. Several or a large number of mitochondria were observed in the part of the wider side of the cytoplasm. These mitochondria were almost identical with those of the lymphocytes in size.

A well-developed rough surfaced endoplasmic reticulum was distributed throughout the cytoplasm, and it was observed in special abundance in the wider part of it. These endoplasmic reticulum ran irregularly throughout the cytoplasm and did not show a well-regulated lamellar structure like plasmacytes.

These cells were named temporarily plasmacytic mononuclear cells by the authors.

These cells were observed in both the clinically normal and lymphosarcoma groups, and in both groups, they were few in number of appearance.

2) The 2nd type

A typical example of this type was pictured in figure 36. The shape of the cells in this type was almost similar to that of the monocyte described already. However, the marked characteristic of the cells was the presence of abundant endoplasmic reticulum with lamellar structure in the cytoplasm. They had many clear granules along the outside of the lamellar membranes, therefore, it could be said that they formed a rough surfaced endoplasmic reticulum.

In almost all of these cells, the endoplasmic reticulum was observed clearly in some parts of the cytoplasm and rarely in them as a whole.

These cells were classified temporarily into monocytic mononuclear cells by the authors.

They were observed in small number in both of the clinically normal and lymphosarcoma groups.

3) The 3rd type

Among the cells observed in the visual fields of the cut planes, mononuclear cells with a considerably higher electron density of cytoplasm than those of any other cells were detected.

The shape of these cells was round or oval, and they were very similar to the typical lymphocytes in morphology. However, in some points, differences between them were observed. Namely, the nucleus of the cell had several more sharp indentations than that of the lymphocyte. The maculous appearance with two parts more or less dense depending upon the amount of chromatin condensation was more clear than that of the typical lymphocytes, the electron density of the cytoplasm was higher than that of the lymphocytes because of full presence of dust-like microsomes. Furthermore, the contours of these cells were slightly irregular, because there were small or considerably large pseudopodic

projections at the contours of these cells.

The mitochondria were smaller than those of the lymphocytes and were almost the same as those of the monocytes in size.

Some of these cells were shown in figures 37~39.

These cells were classified into small lymphocytic mononuclear cells by the authors.

They were observed sometimes in both the clinically normal and lymphosarcoma groups.

4) The 4th type

The cells classified into this type were shown in figures 40~42.

The nuclei of these cells were round or ovoid in shape. They did not have any indentations or incisions of the nucleus. A considerable amount of chromatin was found attached to the nuclear membrane, but on the inner parts of the nuclei, the distribution of the chromatin was very sparse. Therefore, the maculous appearance of the nuclei of the cells was not as clear as that of the lymphocyte.

The contours of these cells were slightly convoluted, but there were no pseudopodic projections.

The cytoplasm was filled with many point-like granules. Among them, two kinds of granules were identified, viz., some were very fine and had less density, others were larger in size and had a higher density than the former. The distribution of these granules was not even because of the clumping of these granules, and the cytoplasm looked like the imperfect meshes of a net. It contained occasionally small or considerably large vacuoles. Mitochondria which were smaller than those of the lymphocytes were observed in the cytoplasm. In general, they were small in number.

These cells were called temporarily large lymphocytic mononuclear cells in this paper.

The cells of this type were observed in both of the clinically normal and lymphosarcoma groups but they appeared more frequently in the blood of the latter group.

CONSIDERATIONS

In the present work by the use of an electron microscope, the mononuclear cells of the peripheral blood obtained from two groups of the clinically normal and pre-leukemic lymphosarcoma cows were divided into 7 types of cells such as lymphocytes, monocytes, plasmacytes, and other 4 types of mononuclear cells.

In the visual fields of all of the cases, of course, the lymphocytes were most predominantly observed. The minute structures of the typical lymphocytes were not different fundamentally from those of the human^{4,18,31)} and the horse^{5,25)} reported already.

In the detailed observations, some of the lymphocytes with interesting structures were observed in the two groups.

On the basis of these morphological findings, the tendencies of their appearance in these two groups were summarized in table 2.

In the clinically normal group, the lymphocytes with nuclear inclusion bodies³⁴⁾ were sometimes observed and the cells with nucleolus and well-developed Golgi

TABLE 2 *The tendencies of appearance of various lymphocytes*

GROUPS	LYMPHOCYTES					
	Typical	with nuclear inclusion body	with nucleolus	with nuclear invagination	with nuclear defect	with well-developed Golgi
Normal	##	+	±	-	-	±
Lymphosarcoma	##	±	+	+	+	+

Note: # ... abundantly observed
 + ... sometimes observed
 ± ... rarely observed
 - ... not observed

TABLE 3 *The tendencies of appearance of mononuclear cells*

GROUPS	MONOCYTE	PLASMACYTE	MONONUCLEAR CELLS			
			Plasmacytic	Monocytic	Small lymphocytic	Large lymphocytic
Normal	#	±	±	±	+	±
Lymphosarcoma	#	±	±	±	+	+

Note: # ... frequently observed
 + ... sometimes observed
 ± ... rarely observed

complex were rarely observed, respectively. However, the cells with nuclear invaginations and nuclear defects have not been detected up to the present time. On the other hand, in the lymphosarcoma group, the lymphocytes with nuclear inclusion bodies were rarely observed, and four other types of lymphocytes were sometimes observed.

Weber & Fahning found the nuclear inclusion bodies in the lymphocytes of peripheral blood of the clinically normal cows, but either none structurally altered ones in the agranulocytes of pre-leukemic cattle. In our observations, there were no structural differences of nuclear inclusion bodies between these two groups.

KNOCKE¹⁵⁾ pointed out that in the nuclei of the lymphocytes and lymphoid cells of the leukosis cattle, the invaginations of the nuclear membrane with projections of the cytoplasm in the region of the nucleus which in sections appeared as inclusion and these invaginations were similar to the nuclear changes observed in other tumour cells in various species.

In our observations, the nuclear invaginations just like KNOCKE's were observed in the lymphocytes only of the lymphosarcoma group, too. Furthermore, the nuclear defects were observed in the nuclei of some lymphocytes only of the lymphosarcoma group. From the size and structure, they could not be from nuclear invaginations but may be real defects of the nuclear plasm.

In the content of the nuclear defect of one cell of the lymphosarcoma group, there were several spherical particles having a diameter of approximately 80~140 m μ with dense cores. They were similar to those particles reported in lymphosarcoma cattle^{8,9,20,21,26,28,29)} and they resembled morphologically the C-type virus particles described by BERNHARD and DALTON et al.^{6,7)}. This finding is very interesting, but the significance of the presence of these particles cannot be assessed at this time.

In general, the white blood cells with well-developed Golgi complex seemed to be younger and more active ones than those with undeveloped Golgi complex^{4,31)}, therefore, the lymphocytes with well-developed Golgi complex observed by the authors will have the same significance.

Nextly, the tendencies of the appearance of the mononuclear cells excepting lymphocytes were summarized in table 3.

There was no difference in the appearance rate of monocytes and plasmacytes in the two groups, and the fine structures of the monocytes and plasmacytes were similar with those of the human^{4,18,31)} reported already.

Out of the other 4 cell types of mononuclear cells, only large lymphocytic mononuclear cells were more frequently observed in the lymphosarcoma group than in the clinically normal group.

As shown by our observations, it is now clear that the mononuclear cells

in these four cell types have abundant ribosomes in their cytoplasm.

This fact suggests that the cytoplasm of these cells of the blood smears will be stained to a very bluish colour by Giemsa or Wright stain methods.

Considering the findings obtained by the authors, it may be said that the so-called atypical lymphocytes or unusual cells in the peripheral blood of cattle reported already by many workers consist of at least the plasmacytes and 4 types of mononuclear cells classified temporarily by the authors such as monocytic, plasmacytic, small lymphocytic and large lymphocytic mononuclear cells, though it is yet uncertain which types of cells in light microscopy correspond to any cell types in electron microscopy.

ACKNOWLEDGEMENT

The authors wish to express their sincere gratitude to Dr. I. GERSH, Research Professor of the Laboratory of Anatomy, School of Veterinary Medicine, University of Pennsylvania, for his kind advice.

Thanks are also to Miss DOROTHY PROBST for her technical assistance.

REFERENCES

- 1) BEHRENS, M. & ESCH, H. F. (1963): *Experientia*, **19**, 406
- 2) BENDIXEN, H. J. (1960): *Dt. tierärztl. Wschr.*, **67**, 57
- 3) BERNHARD, W. (1960): *Cancer Res.*, **20**, 712
- 4) BESSIS, M. & THIERY, J. (1961): *Int. Rev. Cytol.*, **12**, 199
- 5) BOCCIARELLI, D., TENTORI, L. & VIVALDI, G. (1959): *Rc. Ist. sup. Sanità*, **22**, 1059
- 6) DALTON, A. J., HAGUENAU, F. & MOLONEY, J. B. (1962): *J. natn. Cancer Inst.*, **29**, 1177
- 7) DALTON, A. J. (1962): *Fedn Proc.*, **21**, 936
- 8) DUTCHER, R. M., LARKIN, E. P., & MARSHAK, R. R. (1964): *J. natn. Cancer Inst.*, **33**, 1055
- 9) DUCTCHER, R., LARKIN, E. P., TUMILOWICY, J. J., MARSHAK, R. R. & SZEKELY, I. E. (1966): *Comparative leukemia research*, 37, Oxford & New York: Pergamon Press
- 10) DU TOIT, P. J. (1917): *Arch. wiss. prakt. Tierheilk.*, **43**, 145
- 11) DU TOIT, P. J. (1920): *Z. Hyg. InfektKrankh.*, **20**, 320
- 12) GÖTZE, R., ROSENBERGER, G. & ZIEGENHAGEN, G. (1954): *Mh. VetMed.*, **9**, 517
- 13) GÖTZE, R., ZIEGENHAGEN, G. & MERKT, H. (1953): *Mh. Tierheilk.*, **5**, 202
- 14) KNOCKE, K.-W. (1963): *Folia haemat.*, Neue Folge, **7**, 130
- 15) KNOCKE, K.-W. (1964): *Zentbl. VetMed.*, B, **11**, 1
- 16) KNUTH, P. (1917): *Arch. wiss. prakt. Tierheilk.*, **43**, 129
- 17) KNUTH, P. & DU TOIT, P. J. (1917): *Berl. tierärztl. Wschr.*, **33**, 205
- 18) LOW, F. N. & FREEMAN, J. A. (1958): *Electron microscopic atlas of normal and leukemic human blood*, 1 ed., New York, Toronto, London: McGraw-Hill Book

Company, Inc.

- 19) MARSHAK, R. R., CORIELL, L. L., LAWRENCE, W. C., CROSHAW, J. E. JR., SCHRYVER, H. F., ALTERA, K. P. & NICHOLS, W. W. (1962): *Cancer Res.*, **22**, 202
- 20) MARSHAK, R. R., HARE W. C. D., DUTCHER, R. M., SCHWARTZMAN, R. M., SWITZER, J. W. & HUBBN, K. (1966): *Cancer*, **19**, 724
- 21) NAZERIAN, K., DUTCHER, R. M., LARKIN, E. P., TUMILOWICY, J. J. & EUSEBIO, C. (1968): *Am. J. vet. Res.*, **29**, 387
- 22) NIEPAGE, H. (1953): *Mh. VetMed.*, **8**, 21
- 23) PIENING, C. (1934): *Berl. tierärztl. Wschr.*, **50**, 580
- 24) SCHÖTTLER, F. & SCHÖTTLER, H. (1934): *Ibid.* **50**, 497, 513
- 25) SONODA, M. (1963): Proceeding of the 55th Meeting of the Japanese Society of Veterinary Science, *Jap. J. vet. Sci.*, **25**, 394 (Summary in Japanese)
- 26) SORENSON, G. D. & THEILEN, G. H. (1963): *Ann. N. Y. Acad. Sci.*, **108**, 1231
- 27) TOLLE, A. (1965): *Zentbl. VetMed.*, B, **12**, 281
- 28) UEBERSCHÄR, S. (1963): *Dt. tierärztl. Wschr.*, **70**, 417
- 29) UEBERSCHÄR, S. (1966): *Pathologia vet.*, **3**, 276
- 30) VERTER, W. (1961): *Mh. VetMed.*, **16**, 576
- 31) WATANABE, Y. (1956): *Acta haemat. jap.*, **19**, 329 (in Japanese with English summary)
- 32) WEBER, T. W. (1963): *Ann. N. Y. Acad. Sci.*, **3**, 1270
- 33) WEBER, A. F. & FAHNING, M. L. (1967): *Anat. Rec.*, **157**, 340
- 34) WEBER, A. F. & FROMMES, S. P. (1963): *Science*, **141**, 912
- 35) WINQVIST, G. (1958): *Mh. VetMed.* **13**, 161
- 36) WIRTH, D. (1950): *Grundlagen einer klinische Haematologie der Haustiere*, Wien : Urban & Schwarzenberg
- 37) ZIEGENHAGEN, G. & DÖHMEN, H. (1955): *Dt. tierärztl. Wschr.*, **62**, 532

EXPLANATIONS OF PLATES

PLATE I

Fig. 1 × 12,500

Fig. 2 × 11,250

Fig. 3 × 19,660

These are typical lymphocytes.

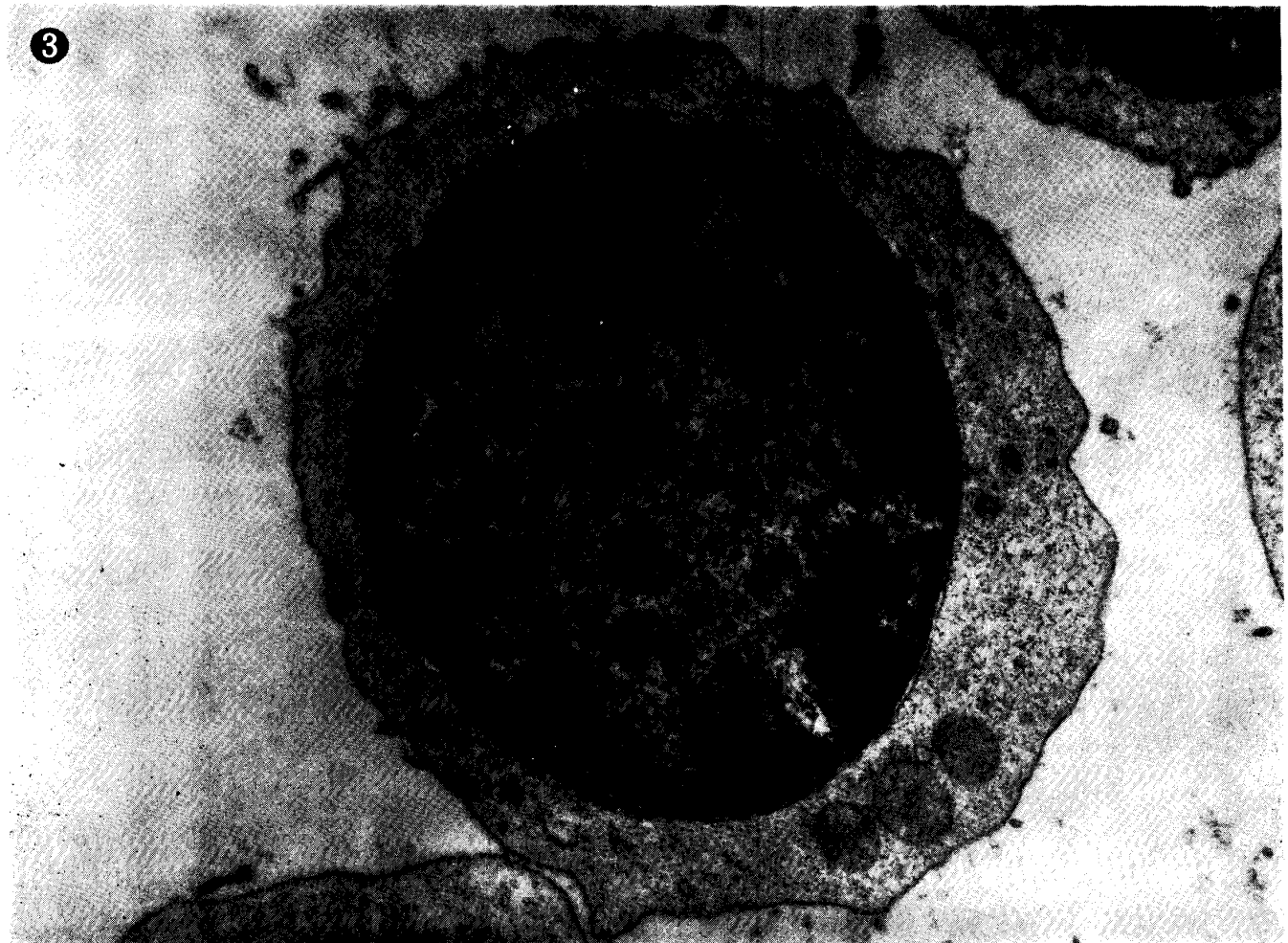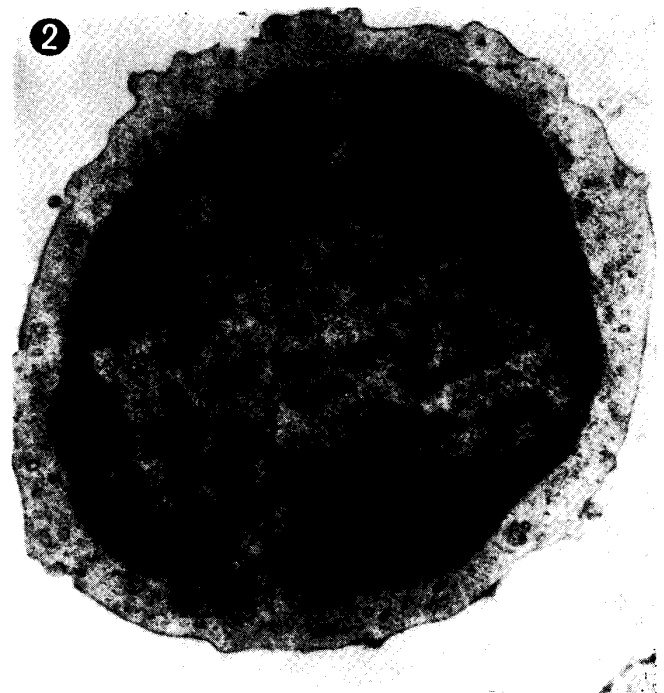

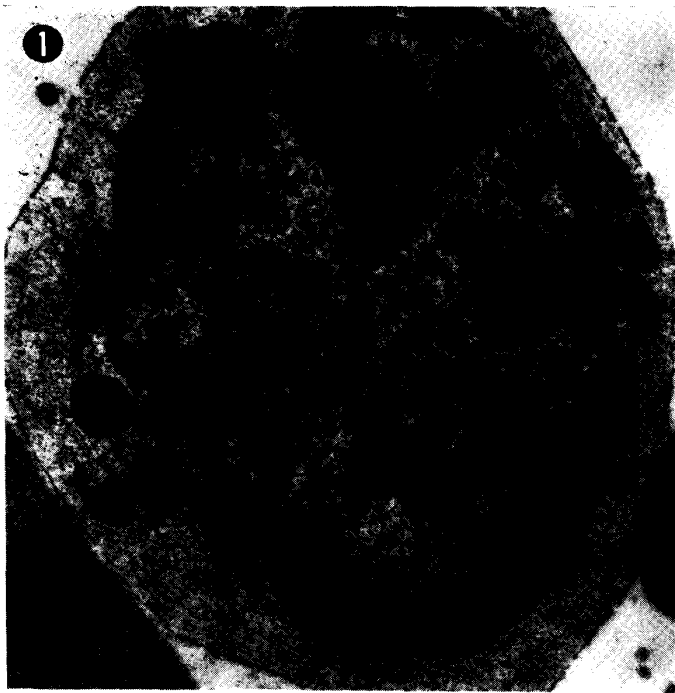
PLATE II

Fig. 4 × 12,500

Fig. 5 × 12,700

These are lymphocytes with nuclear inclusion bodies.

Fig. 6 × 25,000

Fig. 7 × 40,000

Fig. 8 × 40,000

Fig. 9 × 64,000

These are the figures of nuclear inclusion bodies.

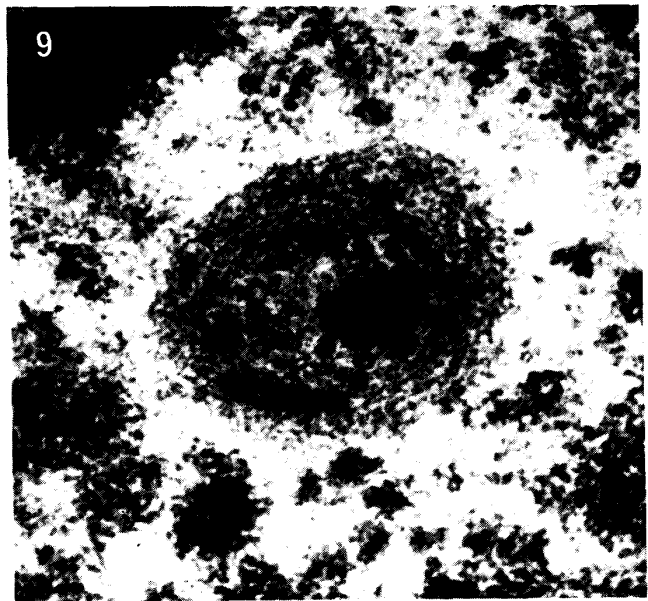
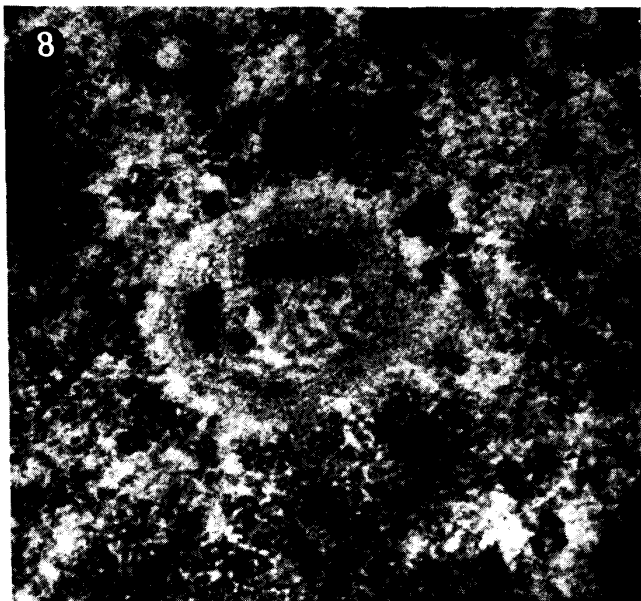
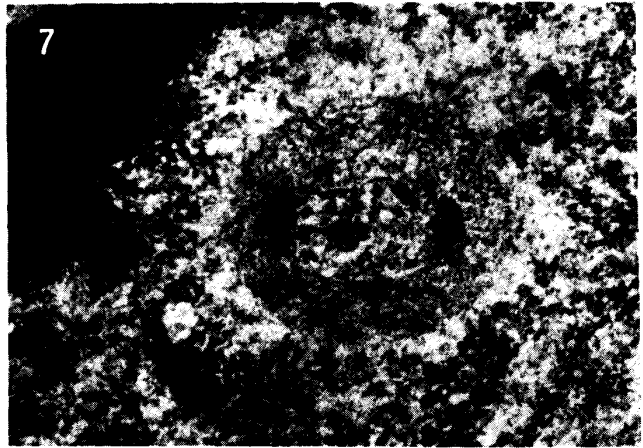
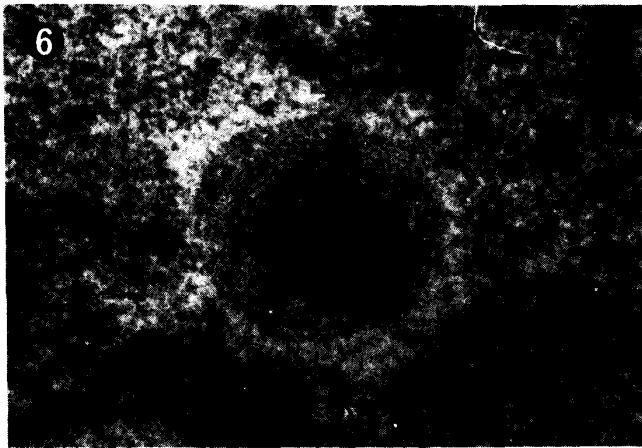
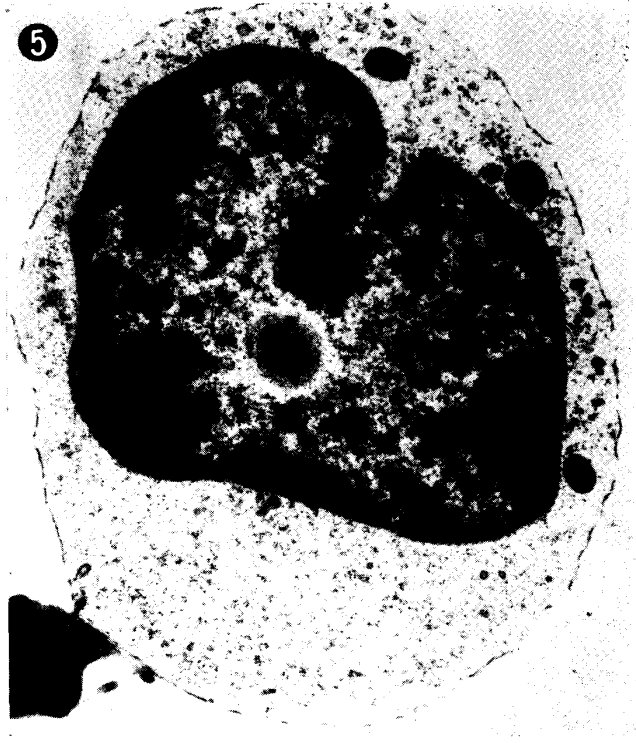
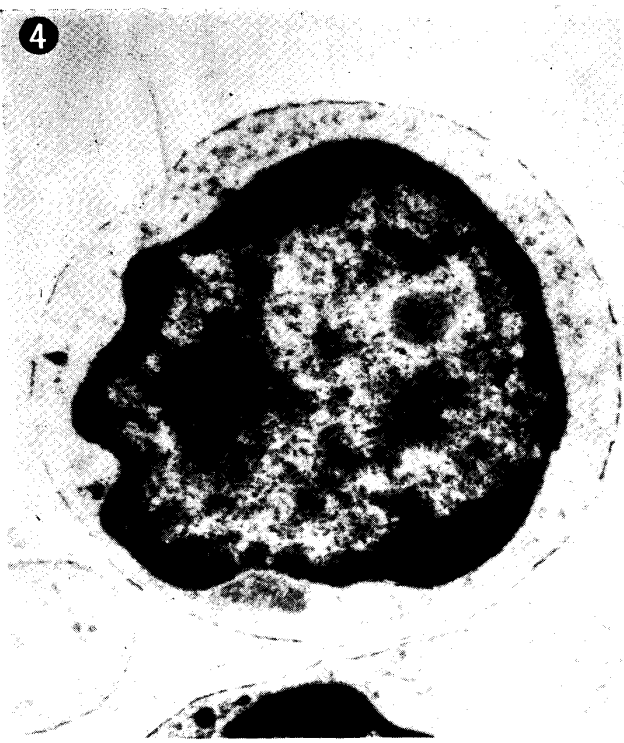
PLATE III

Fig. 10 × 20,000

Fig. 11 × 28,000

Fig. 12 × 25,000

These are nucleoli in the nuclei.

Fig. 13 × 20,000

In this cell, nucleolus and nuclear invagination are observed.

Fig. 14 × 28,000

Fig. 15 × 27,000

Fig. 16 × 37,000

Fig. 17 × 45,000

In these pictures, nuclear invaginations are seen.

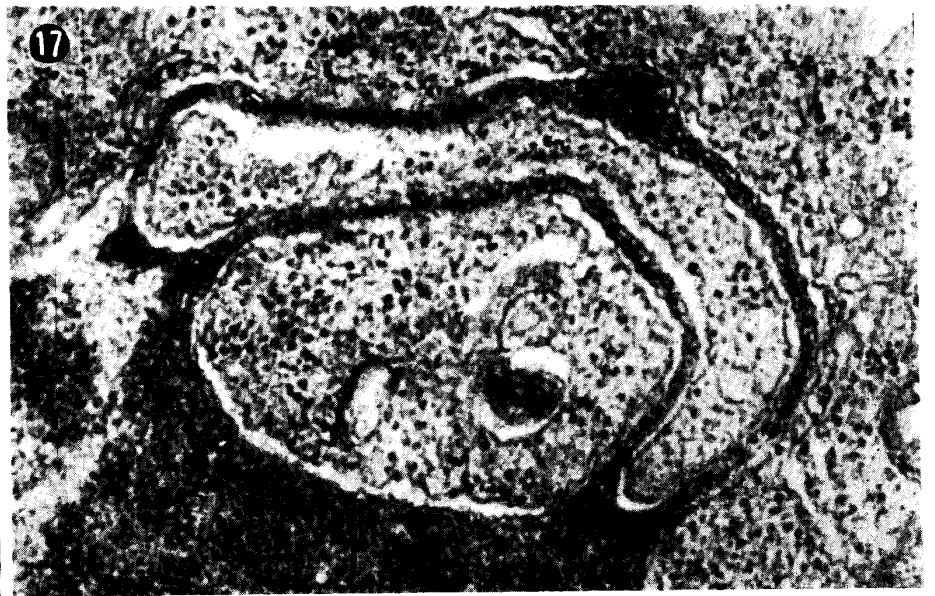
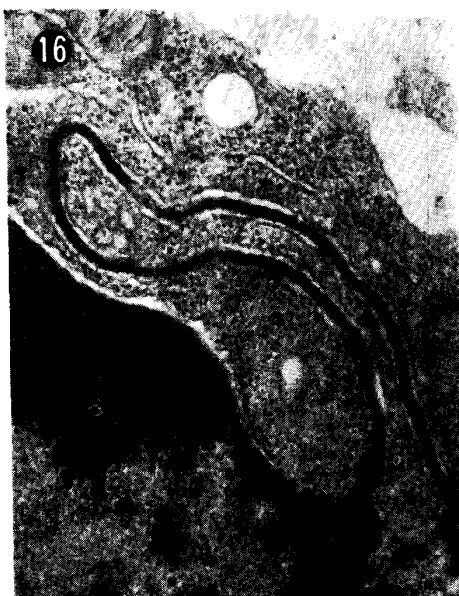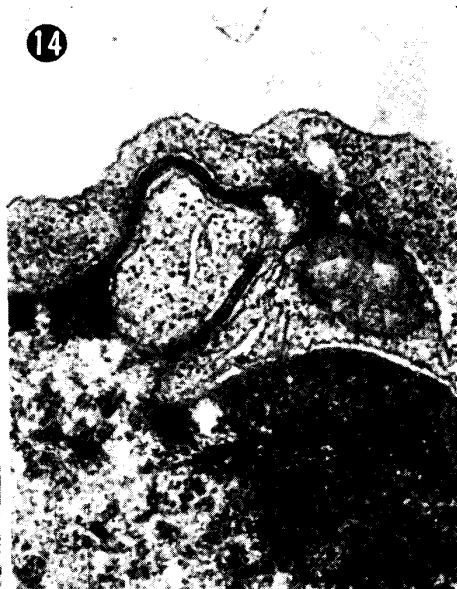
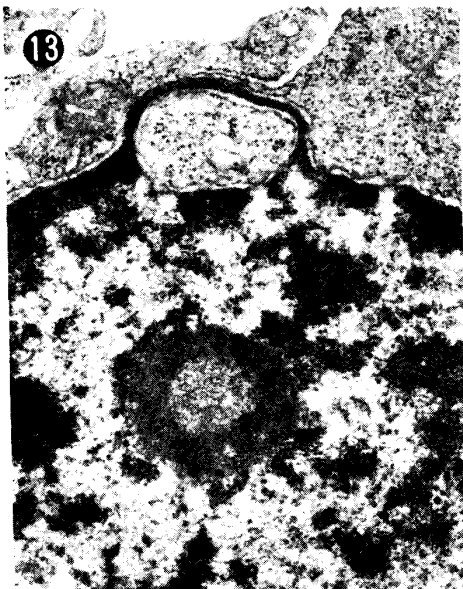
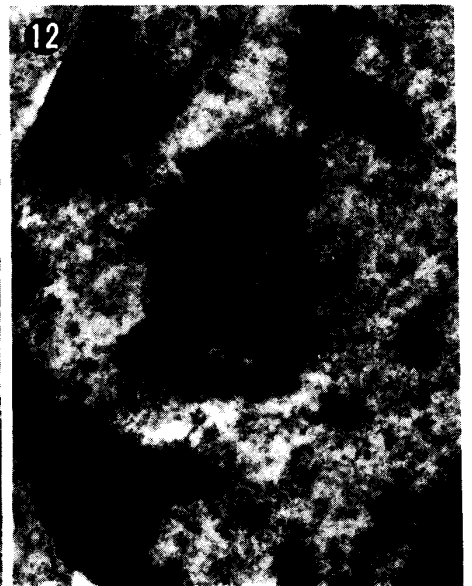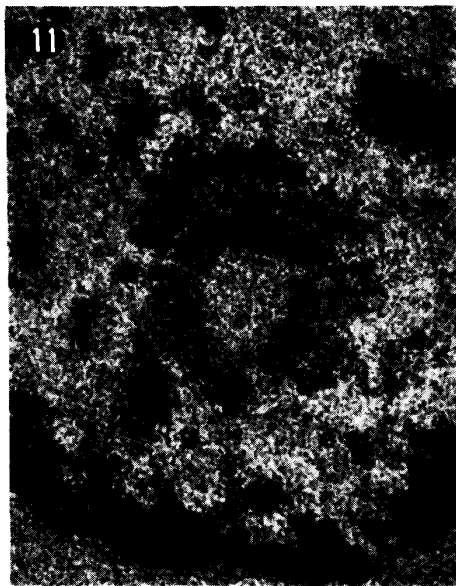
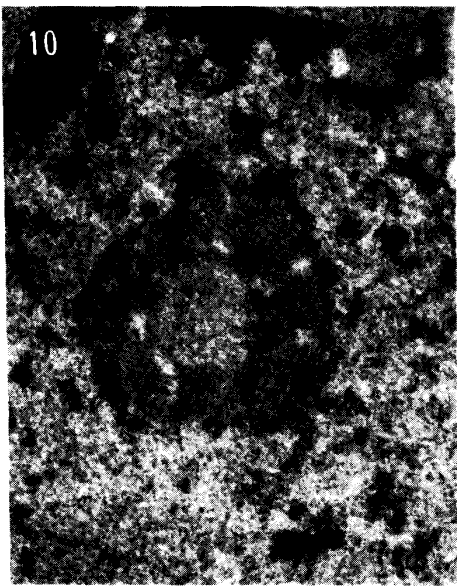


PLATE IV

Fig. 18 × 25,000

Fig. 19 × 35,000

Fig. 20 × 75,000

Fig. 21 × 25,000

Fig. 22 × 50,000

Fig. 23 × 50,000

In these pictures, the nuclear defects are shown, especially in figure 23, virus-like particles are seen (arrows).

Fig. 24 × 45,000

Fig. 25 × 45,000

The parts of well-developed Golgi complex are shown.

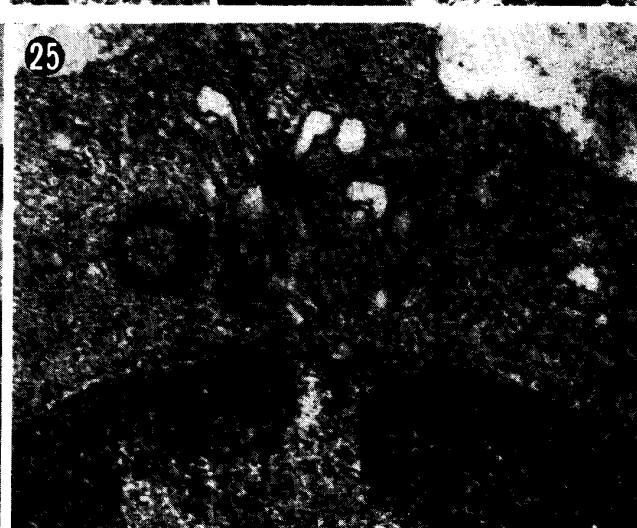
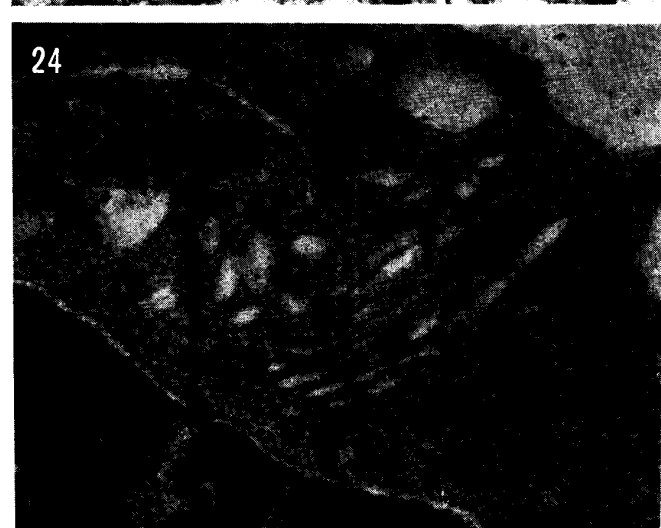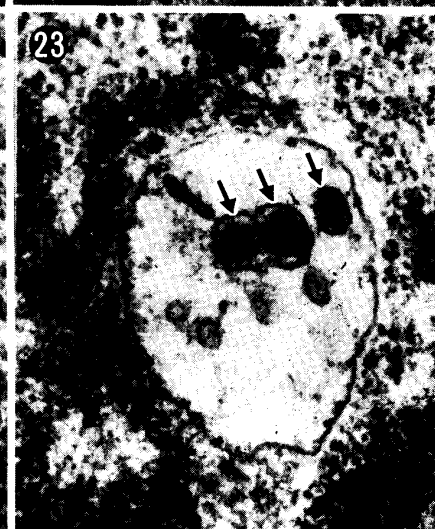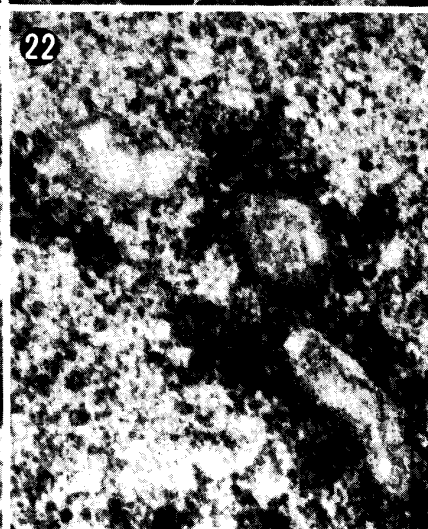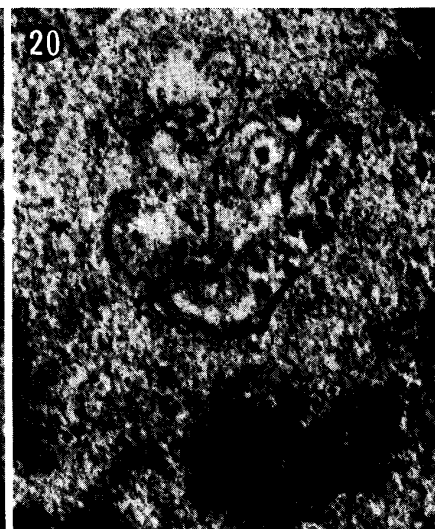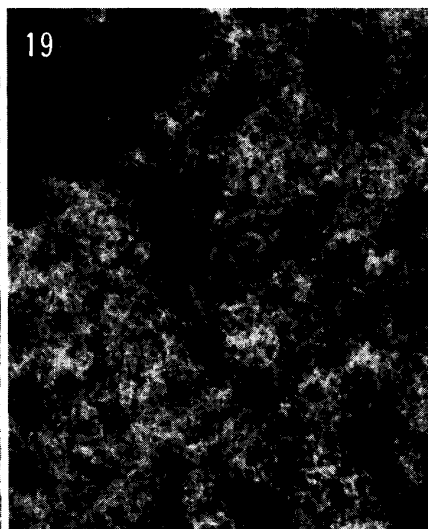
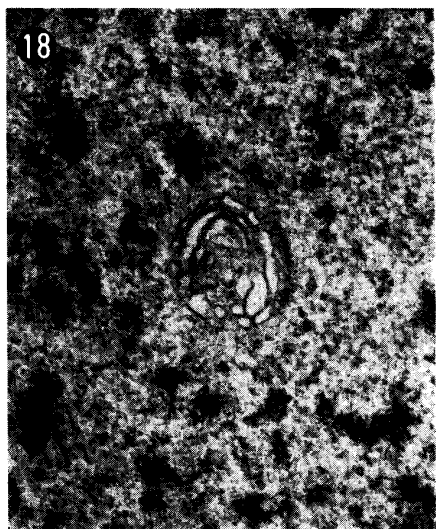


PLATE V

Fig. 26 $\times 17,500$

Fig. 27 $\times 9,000$

Fig. 28 $\times 11,000$

Three of the typical monocytes are shown.

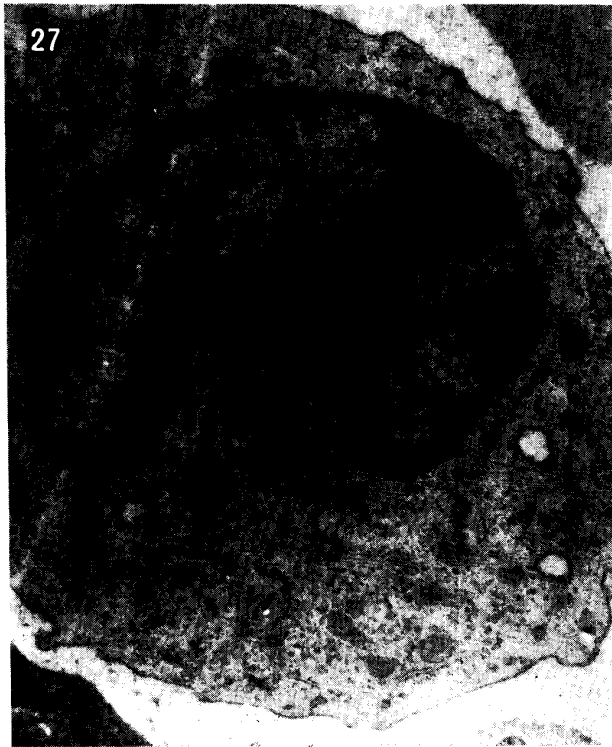
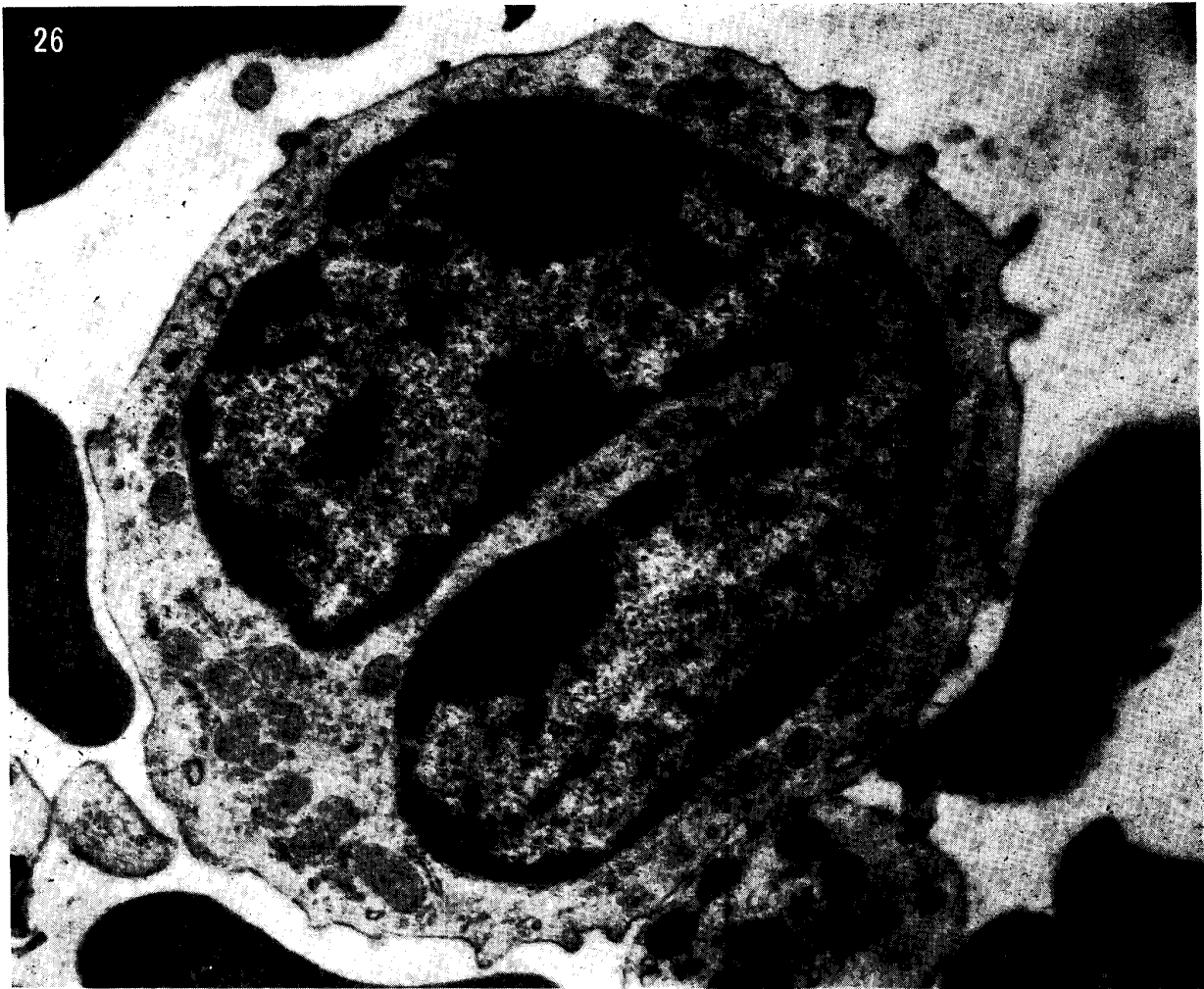


PLATE VI

Fig. 29 × 15,000

Fig. 30 × 30,000

Fig. 31 × 7,500

Typical plasmacytes and the enlarged part of the lamellar endoplasmic reticulum of the cell are shown in figures 29~31, respectively.

Fig. 32 × 9,300

This is a plasmacytic mononuclear cell.

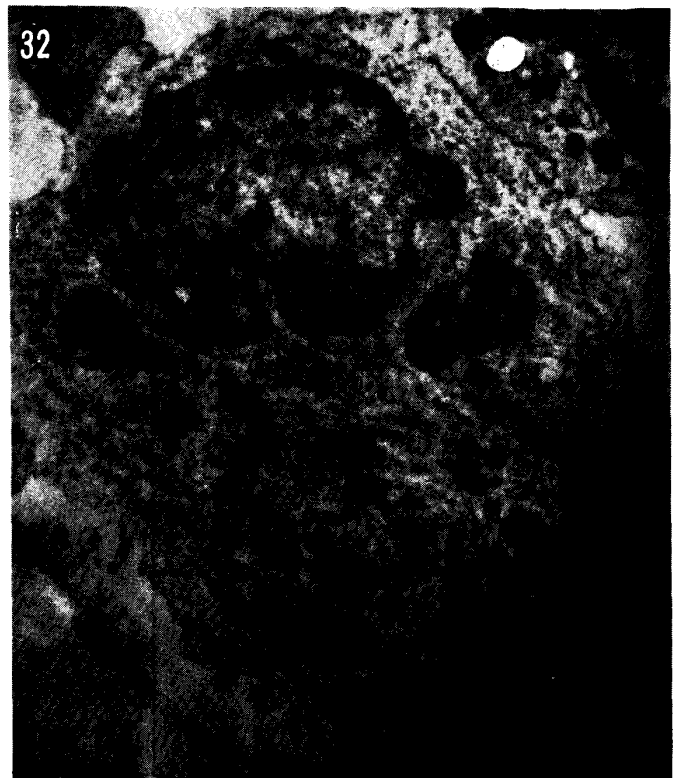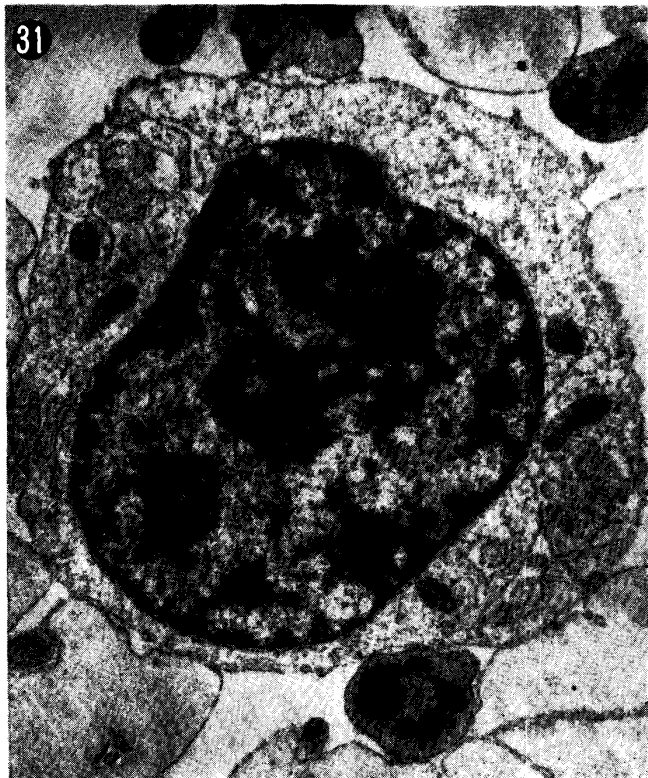

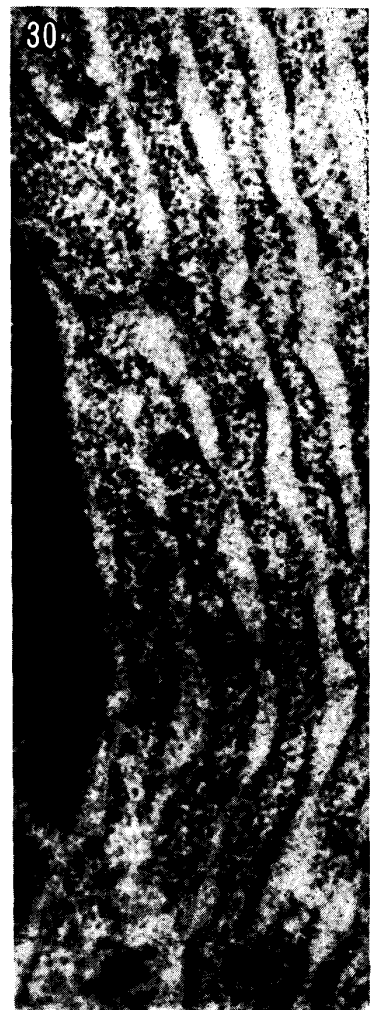
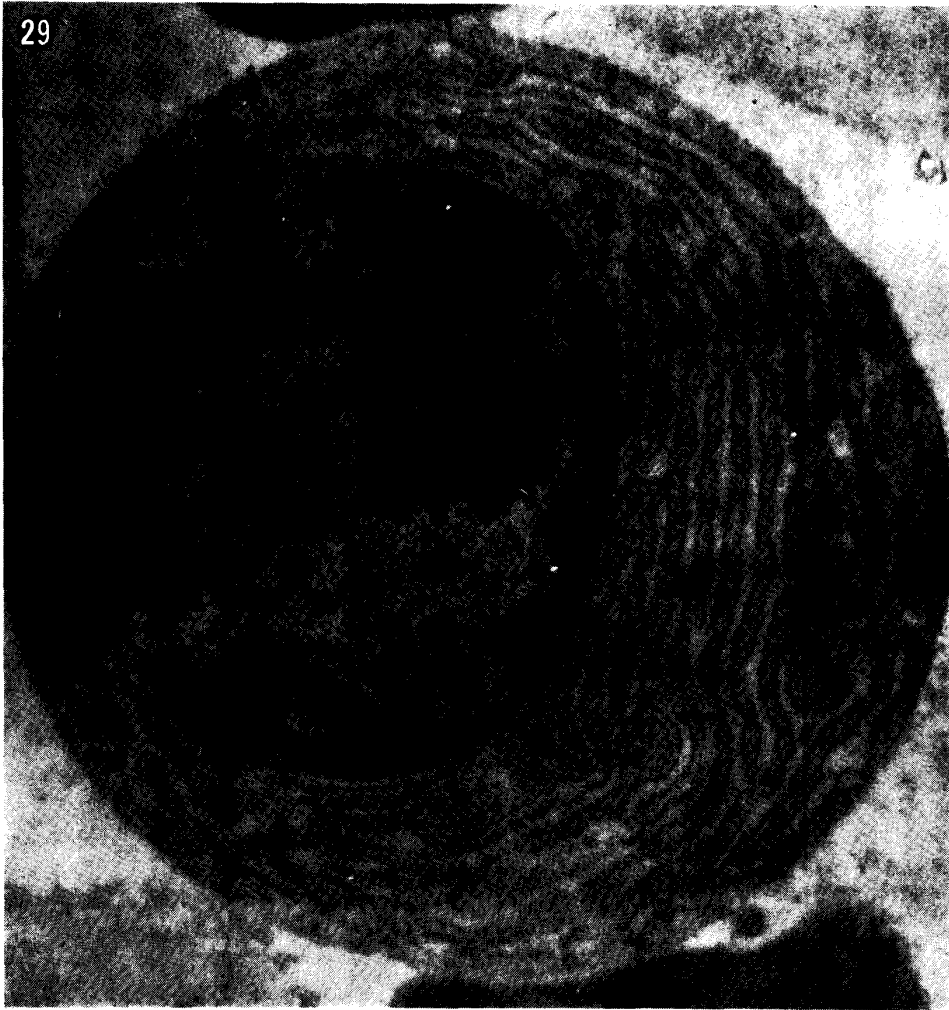PLATE VII

Fig. 33 × 15,000

Fig. 34 × 9,500

Fig. 35 × 9,500

These cells are plasmacytic mononuclear cells.

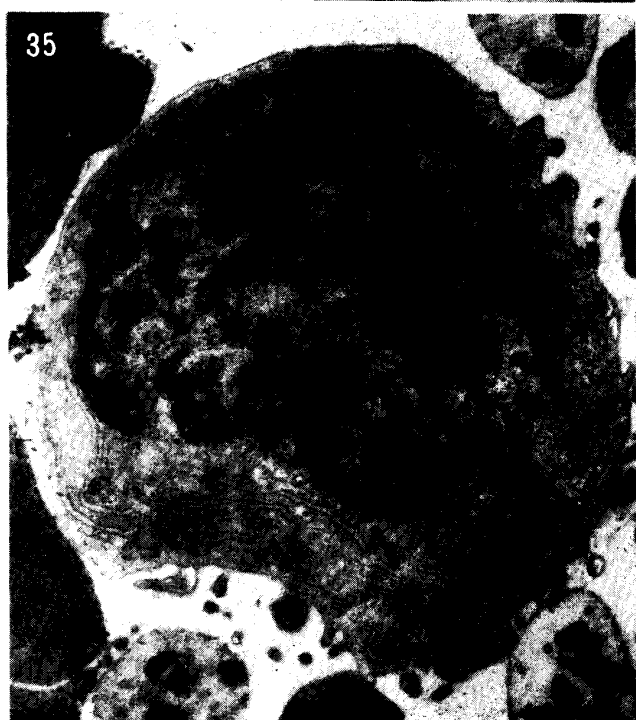
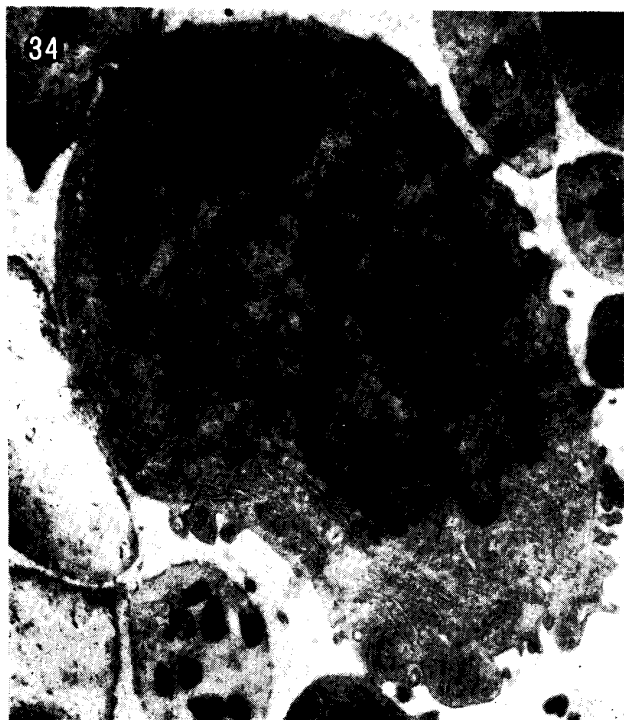


PLATE VIII

Fig. 36 × 17,500

This is a monocytic mononuclear cell.

Fig. 37 × 7,500

Fig. 38 × 10,000

Fig. 39 × 12,000

In figure 37, the mononuclear cell with sharp indentations located in the lower part of the picture has a higher density than those of other cells (arrow). This is the small lymphocytic mononuclear cell.

In figures 38 and 39, typical small lymphocytic mononuclear cells are shown.

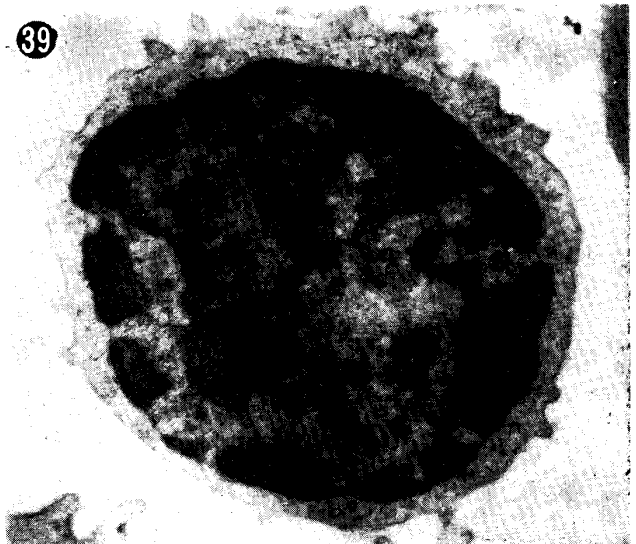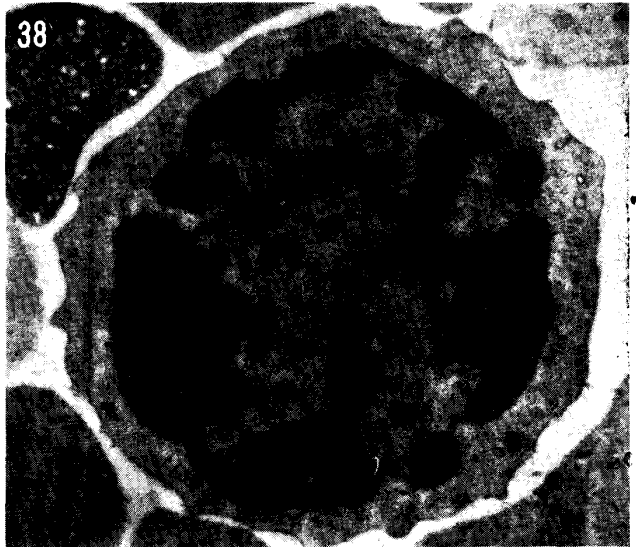
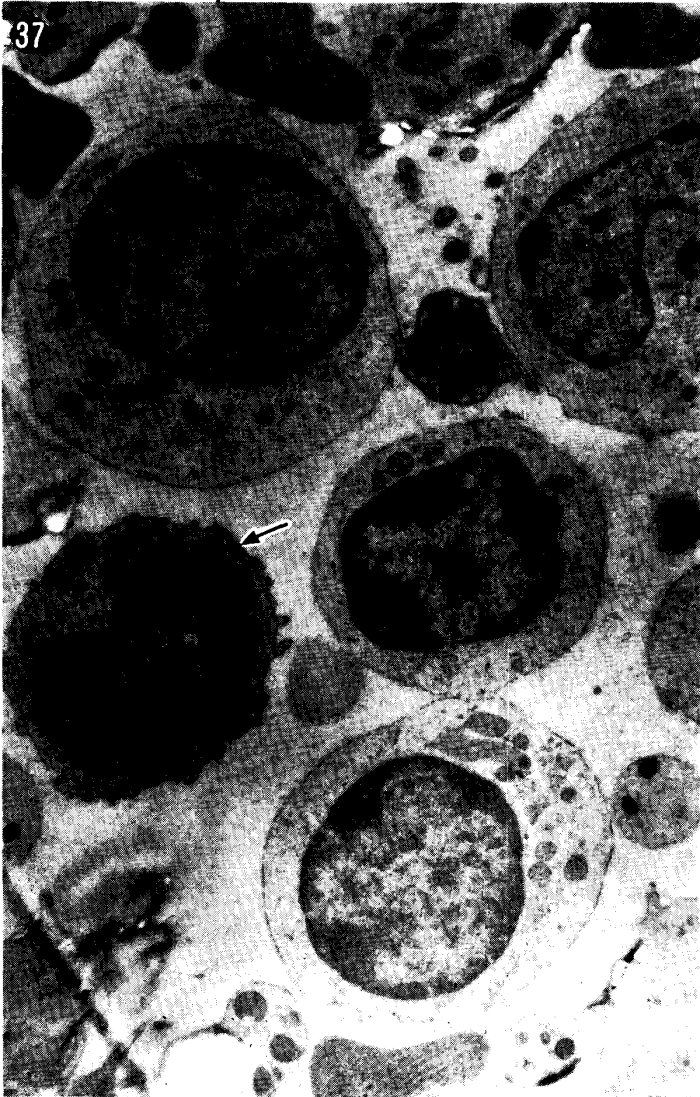
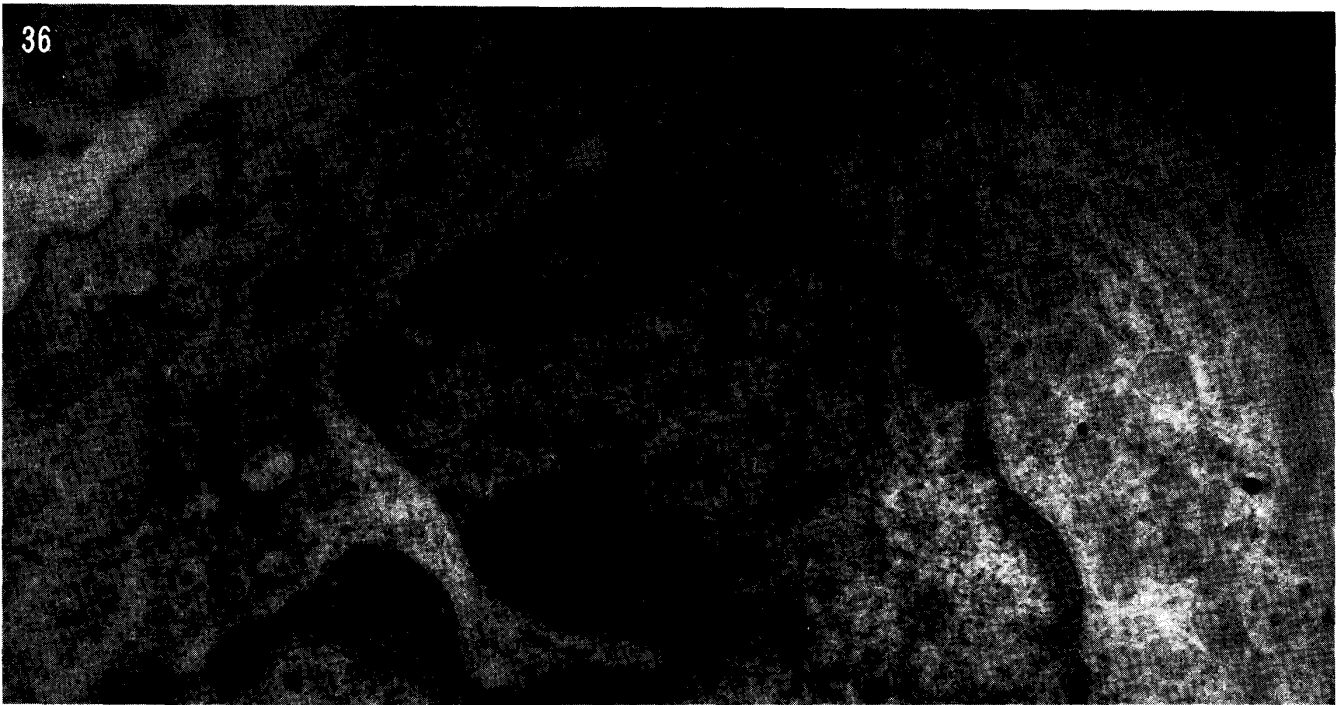


PLATE IX

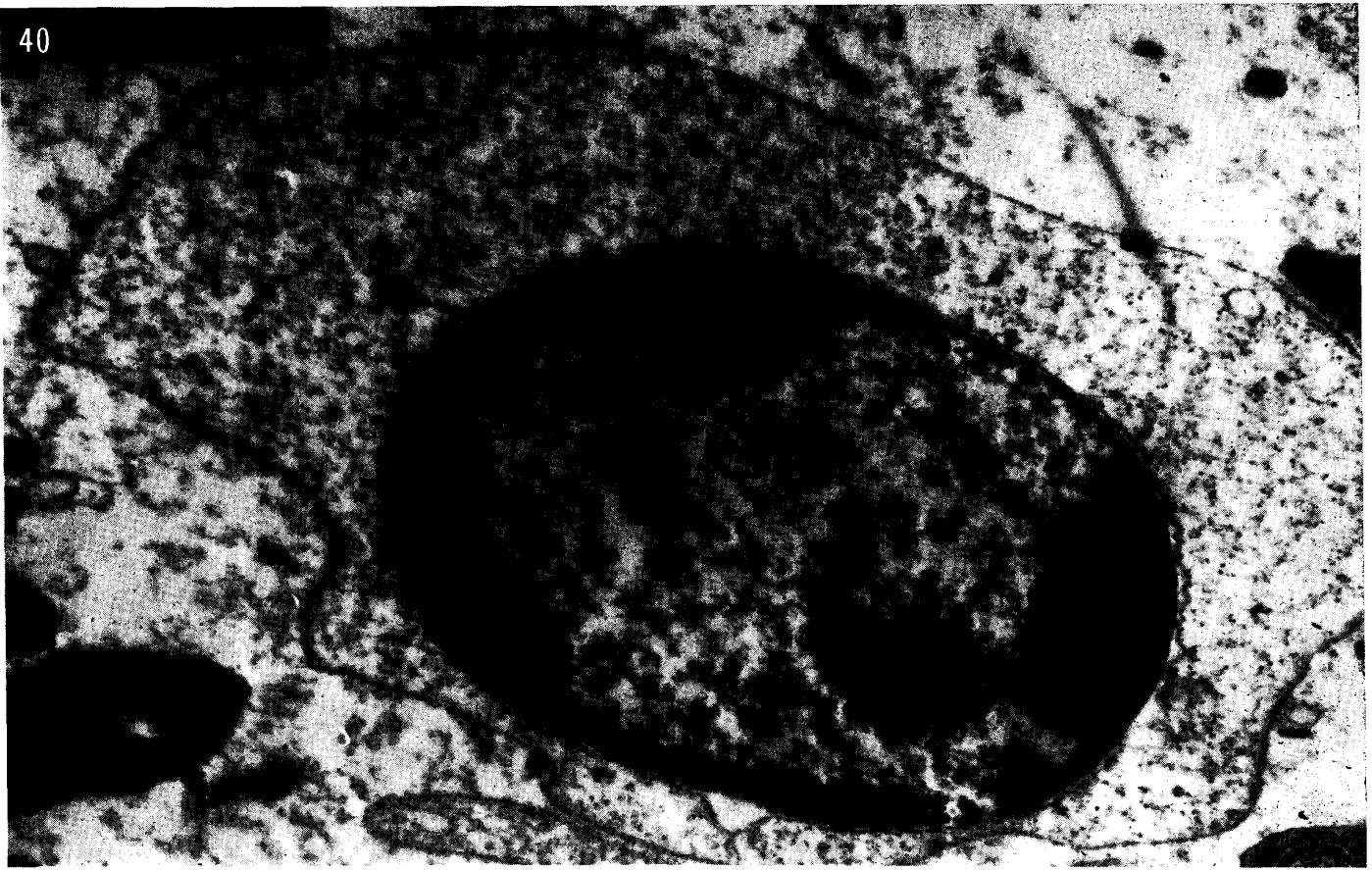
Fig. 40 × 20,000

Fig. 41 × 12,500

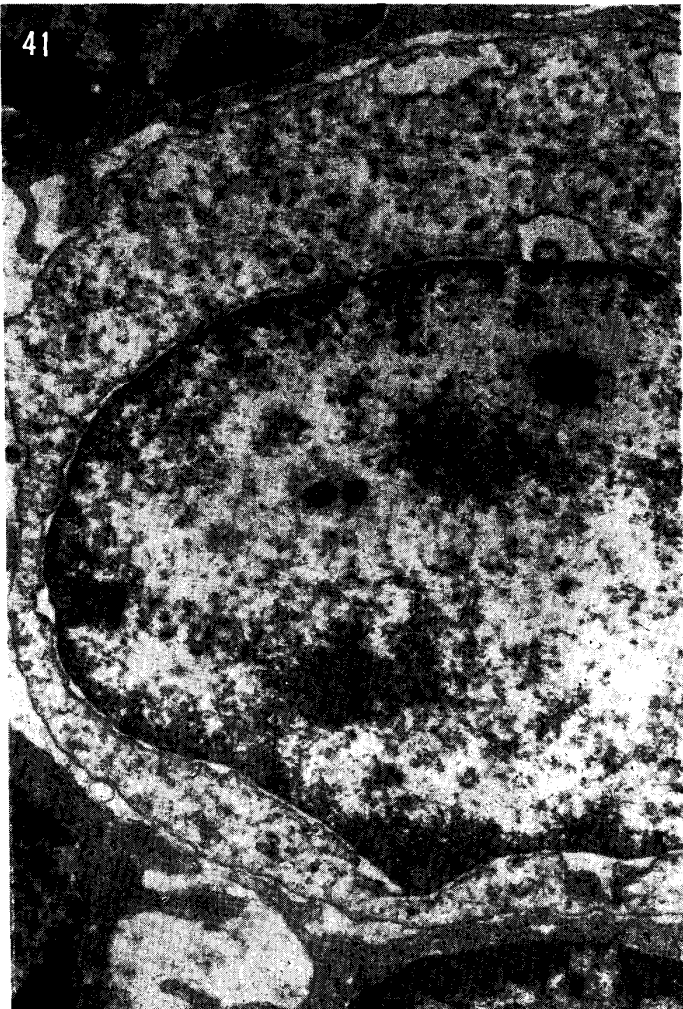Fig. 42 × 14,000

These are large lymphocytic mononuclear cells.

40



41



42

