



HOKKAIDO UNIVERSITY

Title	A CASE OF CANINE FIBROSARCOMA WITH ABNORMAL CHROMOSOMES
Author(s)	SONODA, Mitsuo; NIIYAMA, Masayoshi; MORI, Michiko
Citation	Japanese Journal of Veterinary Research, 18(4), 145-151
Issue Date	1970-12
DOI	https://doi.org/10.14943/jjvr.18.4.145
Doc URL	https://hdl.handle.net/2115/1964
Type	departmental bulletin paper
File Information	KJ00002369889.pdf



A CASE OF CANINE FIBROSARCOMA WITH ABNORMAL CHROMOSOMES

Mitsuo SONODA, Masayoshi NIIYAMA
and Michiko MORI*

*Department of Veterinary Internal Medicine
Faculty of Veterinary Medicine
Hokkaido University, Sapporo, Japan*

(Received for publication, July 8, 1970)

A case of canine fibrosarcoma having prominent metastatic changes over the entire lungs and some other organs was described. Chromosome studies in cultured cells revealed that the tumor cells showed hypodiploid modal chromosome numbers 54 and 56, with many banded chromosomes. The general karyotypic similarity among certain canine tumors such as venereal sarcomas, lymphosarcomas and the present case is discussed.

INTRODUCTION

Neoplastic diseases of the dog have been recognized not rarely in veterinary medicine, and there have been many reports on clinical and pathological observations of those diseases. However, reports pertaining to chromosomal abnormalities in these neoplastic diseases are relatively few except for transmissible venereal tumors^{2,14,20,21}) and lymphosarcomas^{3,4,15}).

In this paper, the results of clinical, clinico-pathological and cytogenetic studies in a case of canine fibrosarcoma will be described.

RESULTS OF EXAMINATIONS

1 Case history

On November 17, 1969, an 8-year-old female Shepherd dog was brought to the clinic of the Faculty of Veterinary Medicine of Hokkaido University.

The owner told us that the swelling of the area around her right eye and several wheat-grain-sized tumors on the fore-chest and wall of the chest had been noticed since about 5 months before and they had been gradually aggravating.

2 Clinical findings

The dog was very poor in physical condition at the initial examination. The rectal temperature was 39.3°C, pulse 102, and a slight staggering was observed. The hairs were dry and lustreless and the loss of hair occurred easily with a slight rub. Respiration was slightly accelerated and labored. By a thorough auscultation of the lungs, it was revealed that the vesicular murmurs were more clear, and moist and dry rales were frequently

* Chromosome Research Unit, Faculty of Science, Hokkaido University, Sapporo, Japan

listened. The palpation on the abdomen indicated no abnormalities of the abdominal organs except almost complete vacancy of the intestinal contents. A perfectly depressed peristalsis of the intestine was revealed by auscultation.

On the right side of the frontal area around the right eye, a considerable diffuse swelling was present. Slightly to the left side of the temporal area, a chestnut-sized tumor was seen. Furthermore, solitary or collected tumor masses of various sizes were observed on the fore-chest, right wall of the chest and around the anus (fig. 1). They were situated in the subcutaneous layer and were movable with the skin. The surface of some tumors was ulcerated and malodorous exudate flowed from them. She was hospitalized on the very same day. Rectal temperatures during the hospitalization were between 38.9~39.6°C and the pulse rate was from 120~180, respectively. From the 5th day following the admission, symptoms such as anorexia, depression and dyspnoea became more severe. From the 9th day, staggering was aggravated and from the 14th day, she could not stand and walk at all. On the 16th day, she was finally sacrificed at the owner's request because of the general aggravation.

3 Hematological and histopathological findings

Hematological examinations were conducted 3 times for the whole course of the disease. The results were listed in table 1. Slight to severe anemia, marked neutrophilic leukocytosis with nuclear shift to the left and the appearance of a number of so-called abnormal or young erythrocytes were the characteristics of the peripheral blood (figs. 3 and 4).

In smear preparations of the tumor tissue stained by Giemsa stain, the nuclei of tumor cells were oval in form and granular in structure (fig. 5). In the nucleus, 2~3 clear nucleoli were present. The cytoplasm of the cells showed one or two extremely long cytoplasmic projections which appeared like tails. A lot of unstained granular bodies were present in the cytoplasm.

In phase-contrast microscopy, the tumor cells were markedly irregular in form, having short or long cytoplasmic projections (fig. 6). The nuclei of the cells were large, round or oval, in which two or three nucleoli were seen clearly.

Histopathological examinations of the specimen biopsied from the tumor tissue on the right wall of the chest were conducted at the initial examination, and the dog was diagnosed as fibrosarcoma in the subcutaneous region (figs. 7 and 8).

Autopsy revealed a lot of gray or black granular tumor masses over the entire lungs, a spherical tumor of the spleen of about 3.5 cm, tumor masses of the subcutaneous region of the right side of the frontalis, swelling of the hilar lymph nodes, several tumor masses in the kidney, and tumor masses on the right temporalis, fore-chest and the right wall of the chest (fig. 2).

Histopathological examinations of the lungs, liver, kidneys and lymph nodes obtained at the time of autopsy provided the findings of fibrosarcoma as that of the cutaneous tumor tissue biopsied.

4 Chromosomal findings

Chromosome analyses were successful in cultured cells derived from the lymph node,

TABLE 1 *Hematological findings*

TIME OF EXAMINATION	ERYTHR.	LEUKO.	HCT.	DIFFERENTIAL COUNT						ABNORMAL RED CELLS			
				St.	Seg.	Ly.	Mon.	Eos.	Bas.	Poly-chromasia	Erythro-blast	Jolly-body	Aniso-cytosis
	(Mill.)		(%)	(%)	(%)	(%)	(%)	(%)	(%)				
1st day	4.23	40,800	30	2.5	92.0	1.5	1.0	2.5	0.5	+	1*	+	+
5th day	2.75	37,000	22	1.5	81.0	6.0	7.0	4.0	0.5	+	2*	+	+
16th day	3.23	72,600	25	9.0	80.0	4.0	5.5	1.5	0	+	2*	+	+

* Number per 200 leukocytes

lung and peripheral blood with or without applying phytohemagglutinin (PHA-M, Difco), while the direct preparations from those three tissues showed no mitoses. As shown in table 2, the majority of cells in the lymph node cultures showed chromosome numbers less than 60 with two distinct modal values at 54 and 56. Karyotypes of these cells were strikingly different from a normal dog pattern characterized by having many biarmed chromosomes and by missing many acrocentrics (figs. 9, 10 and 11). The number of metacentric or submetacentric chromosomes varied from 13 to 25 (table 3). In addition, most of these cells had an unusually large telocentric chromosome with a secondary constriction. On the other hand, the cultures from the peripheral blood and lung tissues did not show such abnormal cells except for one cell from the blood. The cells with 78 chromosomes had a normal karyotype with 76 acrocentric autosomes and 2 submetacentric X chromosomes. A small number of near-diploid cells with 73~77 chromosomes were assumed to be broken cells from normal diploid ones. Most probably those cells with a normal karyotype have originated from non-malignant cells grown in vitro.

Based on the above observations it was concluded that the chromosome constitution of this tumor was grossly different from the normal dog pattern and that the stem line karyotype was represented by 54~56 chromosomes involving 14~23 biarmed elements.

CONSIDERATIONS

In canine medicine, it has been known^{12,13}) that 5~7% of the dogs examined in the clinics showed various kinds of tumors, and among these neoplastic diseases, especially, skin tumors were observed in 8.6~42.1% of them^{1,5,7,17}).

Furthermore, it has been reported^{1,5,18,22}) that the morbidity of the fibrosarcoma was 4.1~8.1% of the neoplasm originated from the skin and associated structure. MULLER & KIRK described that fibrosarcoma was highly invasive locally, and metastasized to the lungs in the dog.

However, so far as the authors know, there are no papers on the canine fibrosarcoma with predominant metastatic changes of the lungs as seen in the present case.

Chromosomal abnormalities in the dog have been reported in association with certain congenital anomalies^{10,19}), venereal sarcomas^{2,14,20,21}), and lymphosarcomas^{3,4,15}). In most cases so far reported one or more excess biarmed chromosomes have occurred in the abnormal cells. Despite the greater variation in the numbers and the morphology of the chromosomes of the hypodiploid cells found in the present specimen, karyotypic features here observed seem to be similar to some cases of venereal sarcoma^{2,14,20,21}) and two cases of lymphosarcoma¹⁵). Judging from the karyotypic similarity in those different cases, it is likely that the phenomenon of centric fusion might be involved as a general tendency of karyological rearrangements in some dog tumor cells as suggested by BARSKI & CORNEFERT-JENSEN, though similar aneuploidies as resulted from a centric chromosome fusion were also reported to occur in cattle^{8,9,11}). Recently,

MILES et al. suggested such a general tendency for this phenomenon to occur in species with telocentric or acrocentric chromosomes. At the present moment, however, any conclusive statement seems premature until more information becomes available on the chromosome abnormalities in dogs and some other telocentric carriers.

ACKNOWLEDGEMENT

The authors would like to thank Dr. Y. FUJIMOTO, Professor of Comparative Pathology of our Faculty, for his direction in the histological diagnosis of the case.

Thanks are also due to Dr. S. SASAKI, Professor of the Chromosome Research Unit of the Faculty of Science of Hokkaido University, for his direction and review of this paper.

REFERENCES

- 1) ANTOINE, LIGEOIS & VERSTRAETE (1934): *Annl. Méd. vét.*, **79**, 354 [OTTOSEN, H. E.¹⁸⁾]
- 2) BARSKI, G. & CORNEFERT-JENSEN, FR.: (1966): *J. natn. Cancer Inst.*, **37**, 787
- 3) BASRUR, P. K. & GILMAN, P. W. (1966): *Cornell Vet.*, **56**, 451
- 4) BENJAMIN, S. A. & NORONHA, F. (1967): *Ibid.*, **57**, 526
- 5) COTCHIN, E. (1951): *Vet. Rec.*, **63**, 67
- 6) COTCHIN, E. (1954): *Ibid.*, **66**, 879
- 7) COTCHIN, E. (1959): *Ibid.*, **71**, 1040
- 8) GUSTAVSSON, I. (1966): *Nature*, **211**, 865
- 9) GUSTAVSSON, I. & ROCKBORN, G. (1964): *Ibid.*, **203**, 990
- 10) HARE, W. C. D., WILKINSON, J. S., McFEELY, R. A. & RISER, W. H. (1967): *Am. J. vet. Res.*, **28**, 583
- 11) HERSCHLER, M. S. & FECHHEIMER, N. S. (1966): *Cytogenetics*, **5**, 307
- 12) KNIGHT, G. C. & DOUGLAS, S. W. (1943): *Vet. Rec.*, **55**, 195
- 13) LASSERRE, R., LOMBARD, C. & LABATUT, R. (1938): *Recl. Méd. vét.*, **90**, 424 [COTCHIN, E.⁵⁾]
- 14) MAKINO, S. (1963): *Ann. N. Y. Acad. Sci.*, **108**, 1106
- 15) MILES, C. P., MOLDAVANNU, G., MILLER, D. G. & MOORE, A.: *Am. J. vet. Res.*, **31**, 783

- 16) MULLER, G. H. & KIRK, R. W. (1969): *Small animal dermatology*, Philadelphia, London, Toronto: W. B. Saunders Company
- 17) MULLIGAN, R. M. (1963): *Ann. N. Y. Acad. Sci.*, **108**, 642
- 18) OTTOSEN, H. E. (1949): *Nord. VetMed.*, **1**, 7
- 19) SHIVE, R. J., HARE, W. C. D. & PATTERSON, D. F. (1965): *Cytogenetics*, **4**, 340
- 20) TAKAYAMA, S. & MAKINO, S. (1961): *Z. Krebsforsch.*, **64**, 253
- 21) WEBER, W. T., NOWELL, P. C. & HARE, W. C. D. (1965): *J. natn. Cancer Inst.*, **35**, 537
- 22) YAMAMOTO, S., ISHIDA, K. & SATO, A. (1964): Proceedings of the 58th Meeting of the Japanese Society of Veterinary Science, *Jap. J. vet. Sci.*, **26**, 507 (Summary in Japanese)

EXPLANATION OF PLATES

PLATE I

- Fig. 1 Several tumor masses on the fore-chest and chest-side
- Fig. 2 A lot of gray or black granular tumor masses of various sizes over the entire lungs
- Fig. 3 Peripheral blood film stained with Giemsa stain
Neutrophilic leukocytosis, hypochromic anemia with anisocytosis and poikilocytosis are seen. $\times 600$
- Fig. 4 Buffy coat film stained with Giemsa stain
All are neutrophilic leukocytes and a nuclear shift to the left is shown. $\times 1,000$
- Fig. 5 Tumor tissue smear stained with Giemsa stain
The nucleus with clear nucleoli is oval in form and granular in structure. The cytoplasm of the cell shows two extremely long cytoplasmic projections. $\times 2,000$
- Fig. 6 A tumor cell in phase-contrast microscopy
The nucleus has 3 clear nucleoli. The cytoplasm is irregular in contour and has a long cytoplasmic projection looking just like a tale. $\times 2,000$
- Figs. 7 & 8 Fibrosarcoma in the subcutaneous region showing whorled and interwoven bundles of anaplastic fibroblasts and a moderate number of collagen fibers
Hematoxylin-eosin stain
Fig. 7 $\times 225$, Fig. 8 $\times 900$

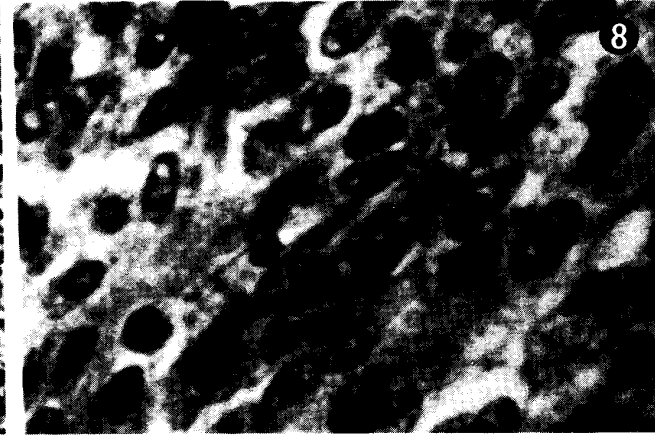
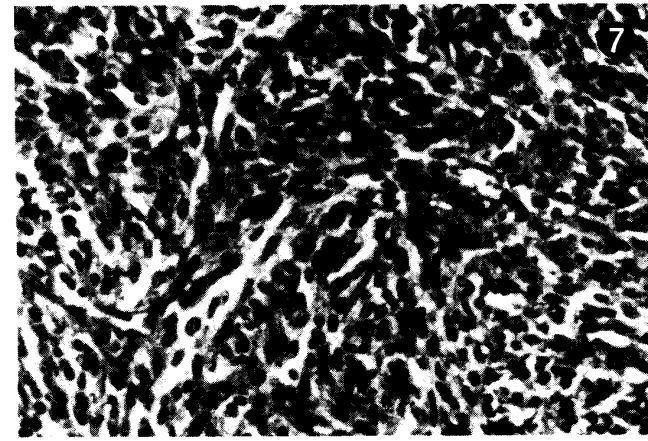
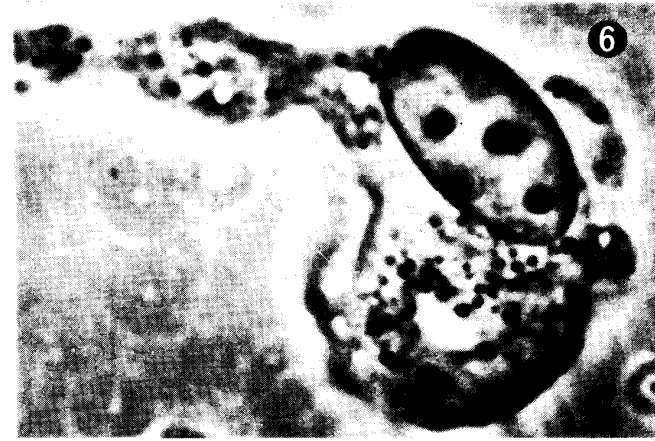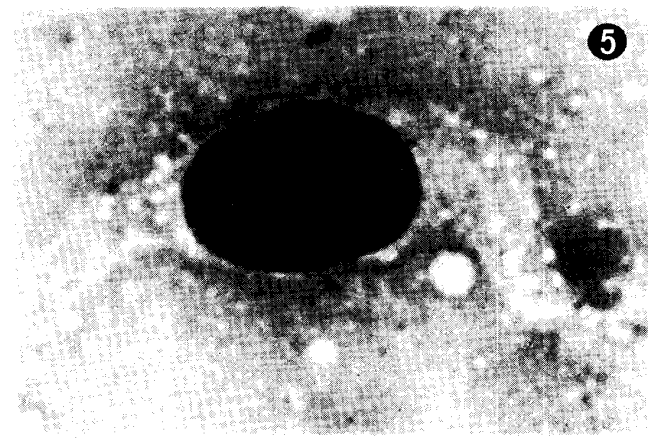
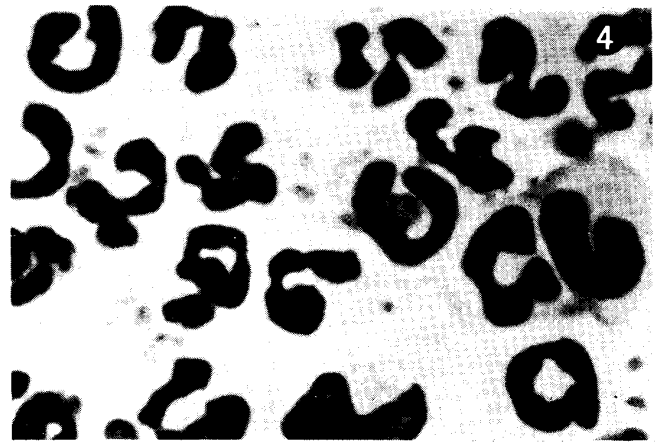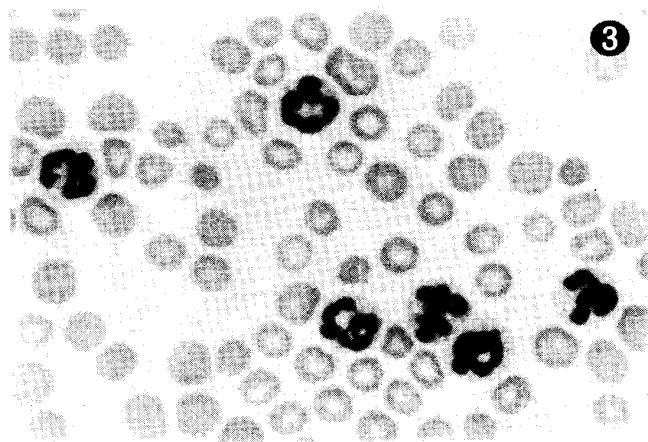

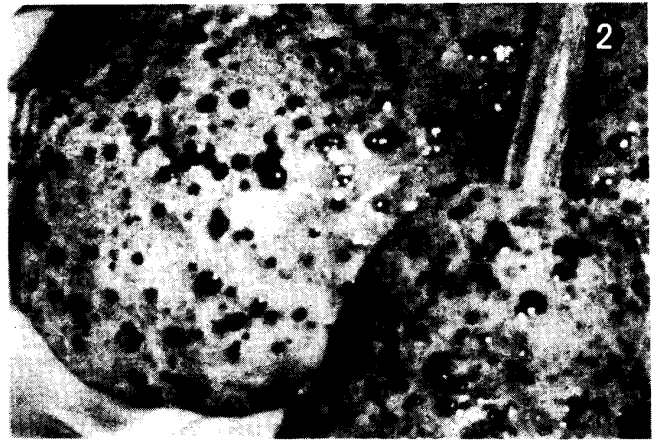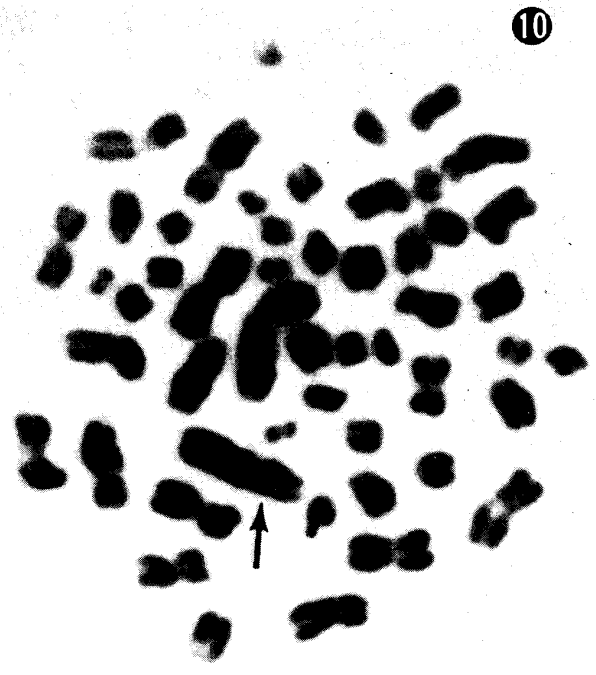


PLATE II


- Fig. 9 Metaphase cell with 78 chromosomes from a cultured lung cell, showing a normal female karyotype of the dog
Arrows indicate two X chromosomes. $\times 1,500$
- Fig. 10 Metaphase cell with 56 chromosomes from a lymph node culture
An arrow shows an unusually large acrocentric chromosome.
 $\times 1,500$
- Fig. 11 Karyotype of a hypodiploid cell from a lymph node culture: 54 chromosomes consisting of 18 biarmed (upper two rows) and 36 acro- or telocentric chromosomes (lower three rows)
An arrow indicates a large acrocentric chromosome. $\times 1,500$



9



10



11