



HOKKAIDO UNIVERSITY

Title	INFECTION TO COLOSTRUM-DEPRIVED BABY PIGS WITH A PORCINE ENTEROVIRUS (Kr 69TC STRAIN) ISOLATED FROM THE LUNG
Author(s)	WATANABE, Hiroshi; POSPISIL, Zdenek; MENSIK, Jarmir
Citation	Japanese Journal of Veterinary Research, 19(4), 107-112
Issue Date	1971-12
DOI	https://doi.org/10.14943/jjvr.19.4.107
Doc URL	https://hdl.handle.net/2115/1985
Type	departmental bulletin paper
File Information	KJ00002369927.pdf



**INFECTION TO COLOSTRUM-DEPRIVED BABY PIGS
WITH A PORCINE ENTEROVIRUS
(Kr 69TC STRAIN) ISOLATED FROM THE LUNG*1**

Hiroshi WATANABE*2

Zdeněk POSPÍŠIL and Jarmír MENŠÍK

*Department of Infectious Disease
Veterinary Research Institute
Brno, Czechoslovakia*

(Received for publication, September, 2, 1971)

The pathogen-free, colostrum-deprived pigs infected intranasally with a lung-isolated enterovirus showed pneumonitis in the early stage of infection and viremia was recognized 2 days after infection (DAI). Specific fluorescence appeared clearly only in the lungs of the pigs. The fluorescent cells consisted of the epithelial cells of bronchus, alveolar septum and possibly the endothelial cells of alveolar septal capillary. Appearance of the fluorescent cells was markedly characterized by the local existence in the lung. Fluorescence appeared in the bronchial epithelial cells only 2 and 8 DAI, when alveolar septum was rich in fluorescent cells. Rectal temperature also showed 2 peaks corresponding to the appearance of fluorescence in the lung. No fluorescence was seen in the other organs.

INTRODUCTION

It has been known that some strains of a porcine enterovirus produce pneumonitis. S 180/4 isolate originating from a clinically healthy pig produced polioencephalomyelitis and inflammatory changes in the lung (SIBALIN & LANNEK, 1960). S 180/4 and T 80-T 52A strains of a porcine enterovirus group were shown to be antigenically identical or closely related to each other, though T 80-T 52A strain did not produce pneumonitis (SIBALIN, 1961). ECPO-6 strain also has the similar ability to S 180/4 strain^{1,3,8}). Kr 69TC strain isolated from the lung of a healthy pig was pronounced to produce lung lesions in a conventional piglet (GÓIŠ & VALÍČEK, 1967). VĚŽŇKOVÁ et al. (1969) divided 13 strains including Kr 69TC strain isolated from the pneumonic porcine lungs into 3 serological groups.

It is interesting to know how a porcine enterovirus multiplies in the porcine lung and causes pneumonitis, so the authors studied it by indirect fluorescent antibody (FA) technique.

*1 This work was supported by the Czechoslovakian Ministry of Agriculture.

*2 Address: Department of epizootiology, Faculty of Veterinary Medicine, Hokkaido University, Sapporo, Japan

MATERIALS AND METHODS

Virus Kr 69TC strain, a porcine enterovirus, isolated from the lung of an apparently healthy pig in Moravia, Czechoslovakia was supplied by D. VĚŽŇKOVÁ of the Veterinary Research Institute. It had been passaged 35 times in porcine kidney cell culture and the infective titer was $10^{9.5}$ tissue culture infective dose (TCID)₅₀/0.1 ml.

Antiserum Adult rabbits which supplied the antiserum were inoculated subcutaneously with the infectious cell culture fluid according to the previous report¹⁰.

Cell culture Primary monolayer cultures were prepared from the kidneys of young pigs according to the previous report¹⁰.

Animals Ten experimental pigs of 3-day-old were pathogen-free, colostrum-deprived baby pigs taken by hysterectomy and kept away from possible contamination. Seven of the pigs were inoculated with the infectious cell culture fluid of Kr 69TC strain and the remaining 3 were injected with a sterilized physiological saline solution for control.

All experimental pigs were housed under the strict isolation and proper temperature in 2 isolation chests during the experimental period. Filtered air was provided and the instruments needed were put into the chests through a box filled up an antiseptic solution.

Infection procedure All pigs were anesthetized with ether, then one ml of the cell culture fluid or a physiological saline solution was dropped into the both nostrils, respectively, with a syringe.

Clinical signs The pigs were observed daily and clinical signs were recorded. Rectal temperature was also recorded. The infected pigs were killed for postmortem examinations in every 2 days from 2 to 12 DAI and 13 DAI. Control pigs were killed one and 13 DAI.

Tissue collection At slaughter, the pigs were bled from the axillary artery and the serum samples were stored at -20°C until used. At necropsy, rectal feces were collected for virus isolation and an approximately 10% suspension of the feces was prepared in Earle's buffered salt solution containing a final concentration of 1,000 U/ml of penicillin, 1,000 $\mu\text{g/ml}$ of streptomycin and 500 U/ml of mycostatin. The suspension was frozen and dissolved once, centrifuged at 4,000 rpm for 30 minutes, then stored at -20°C .

The motor cortex of the cerebrum, the olfactory bulb, the cerebellum, the thalamus, the cervical and the lumbar parts of the spinal cords, 2 parts of the lung, the mesenteric lymph node, 2 parts of the duodenum, the colon and the rectum were removed. They were divided into portions and the portions were immediately treated for FA examinations.

Virus isolation The serum and the fecal suspension were added onto primary porcine kidney cultured cells by the method described in another report¹¹.

The samples considered to be virus-positive were identified with the homologous antiserum to Kr 69TC strain.

Neutralization tests The serums collected at slaughter were titrated according to another report¹¹.

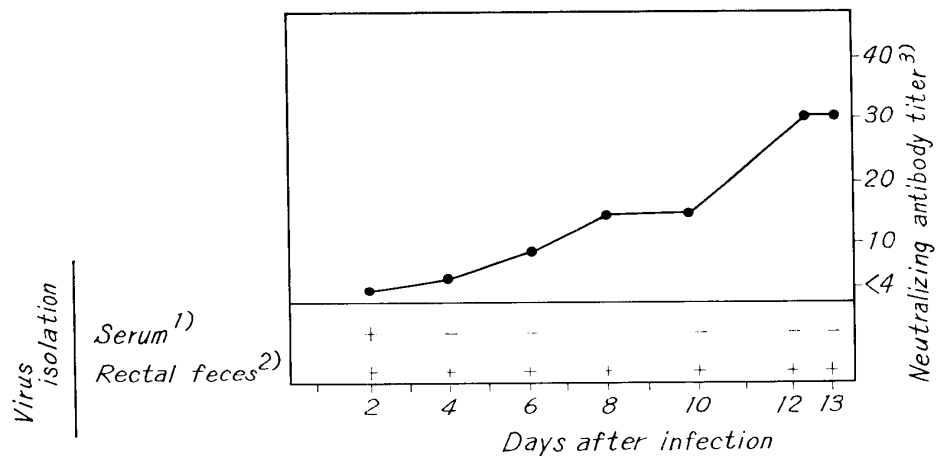
Fluorescent antibody technique Tissue portions were fixed in acetone at 4°C overnight and embeded in paraffin by the method of SAINT-MARIE (1962). The sections

of the tissue were indirectly stained for FA examinations by the method described by the authors¹¹⁾ and observed under a fluorescent microscope.

RESULTS

Clinical signs On the first day, a few baby pigs were already shown mild depression, soft feces and weakness of the hind limbs. Rapid breathing and high rectal temperature were also observed 2 DAI, when 4 of 7 pigs often sat down like dogs and tottered as they walked. Rectal temperature further increased and the febrile peak continued till 6 DAI. Clinical signs other than high rectal temperature followed more indistinctly and were sometimes observed till 9 DAI. Two peaks of temperature were recognized during the experimental period. The bottom of the curve of the rectal temperature was observed 7 DAI. Daily difference in the temperature was 0.5°C on the average. The second peak appeared 9 DAI. The temperature then decreased till 12 DAI and again tended increase 13 DAI, the last experimental day.

Fig. 1 Antibody production and virus excretion in the colostrum-deprived pigs infected intranasally with Kr 69 TC strain



- : negative + : positive

1): judged after one blind passage

2): judged after two blind passages

3): 50% end point

The virus used was a titer of 460 TCID₅₀/0.1 ml.

Recovery of virus The virus identified with Kr 69 TC strain was recovered from one blood sample of the pig examined 2 DAI. No virus was isolated from other blood samples. The virus was recovered from all fecal samples during the experimental period (fig. 1).

Development of antibody. No detectable neutralizing antibody was found till 2 DAI. The antibody titer, thereafter, rose to 1:4 four DAI. On the following days, the titer increased, reaching to 1:32 twelve DAI (fig. 1).

Gross changes of the organs Pneumonitis characterized by inflammatory lesions was observed in the lung from 2 to 10 DAI. The severest pneumonitis involving all over the diaphragmatic lobe of the left lung, was found 4 DAI. However, very mild inflammatory changes were seen 8 and 10 DAI. The stomach and the intestine were filled with gas and mildly congested and a small amount of mucus was found in the stomach 4 DAI. These changes followed milder and maintained till 10 DAI. No obvious gross changes were observed in the other organs.

Fluorescence in the organs The fluorescence was found in the epithelial cells of a few bronchi of an infected pig 2 DAI. The fluorescent cells were characterized by concentrating locally in a row of the epithelial cells (fig. 2). Fluorescence was often condensed in the only tip cytoplasm of the epithelial cells. There were fluorescent detritous masses of the epithelial cells in the bronchi manifesting fluorescence in the epithelial cells. Other kinds of fluorescent cells appeared in alveolar septum of the lung. More fluorescent cells with one to 3 large fluorescent granules in the cytoplasm (fig. 3) were concentrated in alveolar septum within a few limited parts of the lung. This was a constant finding throughout the experimental period. The cells in the septum with fluorescence were considered to consist of epithelial cells of the septum and possibly endothelial cells of the septal capillary. Four DAI, fluorescent cells decreased in number in the septum. However, dense fluorescence was usually present in the whole cytoplasm of the septal cells and fluorescent detritous masses increased in alveoli. Number of septal fluorescent cells again

TABLE *Fluorescence in the colostrum-deprived pigs infected intranasally with Kr 69 TC strain*

ORGANS & TISSUES	DAYS AFTER INFECTION						
	2	4	6	8	10	12	13
Cerebral cortex	-	-	-	-	-	-	-
Cerebellum	-	-	-	-	-	-	-
Thalamus	-	-	-	-	-	-	-
Olfactory bulb	-	-	-	-	-	-	-
Spinal cord ¹⁾	-	-	-	-	-	-	-
Lung ¹⁾	Bronchial epithelium	+	-	-	+	-	-
	Alveolar septum	##	#	###	###	+	+
	Detritous mass						
	in bronchus	#	-	-	+	-	-
	in alveolus	-	#	+	-	-	+
Mesenteric lymph node	-	-	-	-	-	-	-
Small intestine ¹⁾	-	-	-	-	-	-	-
Large intestine ²⁾	-	-	-	-	-	-	-

- : negative +-### : very weak fluorescence - : very strong fluorescence.

1): Two levels were examined.

2): The colon and the rectum were examined.

increased from 6 to 8 DAI and the cells peeling off into alveoli often showed fluorescent granules in the whole cytoplasm (fig. 4).

It was interesting that fluorescence appeared again in bronchial epithelial cells 8 DAI (fig. 5). The fluorescent bronchi were a few and local appearance of fluorescent epithelial cells was noticed again. Detritous masses in that bronchi were noticed to be a very few. Septal fluorescent cells decreased in number rapidly, revealing varied pictures, granular or thick fluorescence, 10 and 12 DAI. The cell number in alveolar septum tended again increase 13 DAI, the last experimental day (table). It was noticeable that fluorescence was not found at all in the other organs than the lung.

The findings stated above were not obtained in the lung of control pigs during the experimental period.

DISCUSSION

Only the lung of the pigs infected with Kr 69TC strain demonstrated fluorescence. It might be sure that the lung was the most important target organ of Kr 69TC strain of a porcine enterovirus. On the other hand, the infected pigs showed weak paralysis of the hind limbs, further uncertain fluorescence was found in the capillary endothelial cells in the brain. So it is possible that Kr 69TC strain has the tendency of infection into the brain as SIBALIN & WINQVIST (1963) described that many strains of a porcine enterovirus might be able to cause nonspecific nonpurulent encephalitis.

Fluorescence was already shown in the bronchial epithelial cells, alveolar septal epithelial cells and possibly alveolar septal capillary endothelial cells 2 DAI when viremia was recognized. On the following days, antibody titer increased, fluorescence disappeared in the bronchus and decreased in the alveolar septum. But fluorescence increased again in alveolar septum 6 to 8 DAI and reappeared in bronchus 8 DAI. The increase and the occurrence of fluorescence concurred to the onsets of 2 peaks of rectal temperature; the each peak continued approximately 4 days. On the last experimental day, both fluorescence in alveolar septum and rectal temperature tended again to increase.

The results described above suggest following correlation or competition between virus multiplication and response of the host. That is, the regular cycles of fluorescent appearance and high temperature might have to reflect the cycle of the virus multiplication. Invasion of the virus into lung tissue of the pigs, following to multiplication in the points of the lung, activates local immune response in the tissue. The local immune response might result the secondary multiplication of the virus in other points of the lung.

ACKNOWLEDGEMENTS

The authors wish to thank Dr. J. ŠŤEPÁNEK of the veterinary research institute for his help. The authors are glad to thank Dr. D. VĚŽŇKOVÁ supplied Kr 69TC strain. They further wish to express their gratitude to Mrs. M. BRYMOVÁ for her skillful technical assistance of FA examinations.

REFERENCES

- 1) BABA, S. P., BOHL, E. H. & MEYER, R. C. (1966): *Cornell Vet.*, **56**, 386
- 2) GÓIŠ, M. & VALÍČEK, L. (1967): *Docum. vet. Brno*, **6**, 179
- 3) MEYER, R. C., WOODS, G. T. & SIMON, J. (1966): *J. comp. Path.*, **76**, 397
- 4) SAINT-MARIE, G. (1962): *J. Histochem.*, **10**, 250
- 5) SIBALIN, M. (1961): *Arch. ges. Virusforsch.*, **11**, 326
- 6) SIBALIN, M. & LANNEK, N. (1960): *Ibid.*, **10**, 31
- 7) SIBALIN, M. & WINQVIST, G. (1963): *Acta vet. scand.*, **4**, 395
- 8) SINGH, K. V., BOHL, E. H. & SANGER, V. L., (1964): *Cornell Vet.*, **54**, 612
- 9) VĚŽŇKOVÁ, D., GÓIŠ, M. & ČERNÝ, M. (1969): *Arch. exp. VetMed.*, **23**, 59
- 10) WATANABE, H. (1971): *Jap. J. vet. Res.*, **19**, 1
- 11) WATANABE, H., POSPÍŠIL, Z. & MENŠÍK, J. (1971): *Ibid*, **19**, 87

EXPLANATION OF A PLATE

- Fig. 2 Fluorescent epithelial cells (E) in the bronchus
Fluorescence is often found only in the tip of the cells. Fluorescent detritous mass (D) in the bronchus.
Two days after infection × 240
- Fig. 3 Fluorescent cells (F) in alveolar septum
Fluorescence is found in the limited one to three parts of the cytoplasm.
Two days after infection × 240
- Fig. 4 Fluorescence in the whole cytoplasm of the cells in alveolar septum
Detritous mass (D) in alveoli
Six days after infection × 240
- Fig. 5 Fluorescence in the cytoplasm of the epithelial cells of the bronchus (B)
Eight days after infection × 240

