



HOKKAIDO UNIVERSITY

Title	Positive correlation between vitreous levels of advanced glycation end products and vascular endothelial growth factor in patients with diabetic retinopathy sufficiently treated with photocoagulation
Author(s)	Yokoi, Masahiko; Yamagishi, Sho-ichi; Takeuchi, Masayoshi et al.
Citation	British Journal of Ophthalmology, 91(3), 397-398 https://doi.org/10.1136/bjo.2006.100198
Issue Date	2007-03
Doc URL	https://hdl.handle.net/2115/20277
Type	journal article
File Information	BJ091-3.pdf





Positive correlation between vitreous levels of advanced glycation end products and vascular endothelial growth factor in patients with diabetic retinopathy sufficiently treated with photocoagulation

Masahiko Yokoi, Sho-ichi Yamagishi, Masayoshi Takeuchi, Takanori Matsui, Yumiko Yoshida, Kazuhiro Ohgami, Tamami Amano-Okamoto and Shigeaki Ohno

Br. J. Ophthalmol. 2007;91:397-398
doi:10.1136/bjo.2006.100198

Updated information and services can be found at:
<http://bjo.bmj.com/cgi/content/full/91/3/397>

These include:

References

This article cites 5 articles, 2 of which can be accessed free at:
<http://bjo.bmj.com/cgi/content/full/91/3/397#BIBL>

Rapid responses

You can respond to this article at:
<http://bjo.bmj.com/cgi/eletter-submit/91/3/397>

Email alerting service

Receive free email alerts when new articles cite this article - sign up in the box at the top right corner of the article

Notes

To order reprints of this article go to:
<http://www.bmjournals.com/cgi/reprintform>

To subscribe to *British Journal of Ophthalmology* go to:
<http://www.bmjournals.com/subscriptions/>

Derek Stephens

Population Health Sciences, The Hospital for Sick Children, University of Toronto, Toronto, Ontario, Canada

Jane D Kivlin

Department of Ophthalmology, Medical College of Wisconsin, Milwaukee, Wisconsin, USA

Alex V Levin

Departments of Paediatrics and Ophthalmology and Vision Science, The Hospital for Sick Children, University of Toronto, Toronto, Ontario, Canada

Correspondence to: Dr A V Levin, Department of Ophthalmology and Vision Sciences, The Hospital for Sick Children, 555 University Avenue, M158 Toronto, Ontario, Canada M5G 1X8; alex.levin@sickkids.ca

doi: 10.1136/bjo.2006.099481

Accepted 2 July 2006

Competing interests: None declared.

References

- Duhaime AC, Christian CW, Rorke LB, *et al*. Non-accidental head injury in infants – the “shaken-baby syndrome”. *N Engl J Med* 1998;**338**:1822–9.
- Levin AV. Retinal haemorrhages and child abuse. In: David TJ, eds. *Recent advances in paediatrics*. London: Churchill Livingstone, 2000;**18**:151–219.
- Kivlin JD, Simons KB, Lazowitz S, *et al*. Shaken baby syndrome. *Ophthalmology* 2000;**107**:1246–54.
- Ganesh A, Jenny C, Geyer J, *et al*. Retinal hemorrhages in Type I osteogenesis imperfecta after minor trauma. *Ophthalmology* 2004;**111**:1428–31.
- Morad Y, Kim YM, Armstrong DC, *et al*. Correlation between retinal abnormalities and intracranial abnormalities in the Shaken Baby Syndrome. *Am J Ophthalmol* 2002;**134**:354–9.
- Aoki N, Masuzawa H. Infantile acute subdural hematoma. Clinical analysis of 26 cases. *J Neurosurg* 1984;**61**:273–80.
- Ikeda A, Sato O, Tsugane R, *et al*. Infantile acute subdural hematoma. *Childs Nerv Syst* 1987;**3**:19–22.
- Gardner HB. Retinal and subdural haemorrhages: Aoki revisited. *Br J Ophthalmol* 2003;**87**:919–20.
- Armitage P, Berry G. *Statistical methods in medical research*, 3rd edn. Oxford, UK: Blackwell, 1994:111–13.
- Barr RG, Trent RB, Cross J. Age-related incidence curve of hospitalized Shaken Baby Syndrome cases: convergent evidence for crying as a trigger to shaking. *Child Abuse Negl* 2006;**30**:7–16.

Positive correlation between vitreous levels of advanced glycation end products and vascular endothelial growth factor in patients with diabetic retinopathy sufficiently treated with photocoagulation

We investigated whether vitreous levels of advanced glycation end products (AGEs) were positively correlated with vascular endothelial growth factor (VEGF) in patients with diabetic retinopathy patients sufficiently treated with retinal photocoagulation. Vitreous AGE and VEGF levels were significantly higher in patients with diabetes than in controls. Positive correlation between AGE and VEGF was found in patients with diabetic retinopathy sufficiently treated with retinal photocoagulation ($r = 0.44$, $p < 0.05$), but not in those who were insufficiently treated ($r = 0.26$, $p = 0.18$). The present observations

suggest that AGE may induce VEGF expression in an ischaemia-independent mechanism. AGE could be one of the important determinants of VEGF in diabetic retinopathy without obvious ischaemic regions.

Background

Vascular endothelial growth factor (VEGF) elicits retinal vascular hyperpermeability, thrombosis and angiogenesis, having a central role in the pathogenesis of diabetic retinopathy.¹ Furthermore, vitreous VEGF levels are increased in proliferative diabetic retinopathy, whereas the levels are decreased after treatment with panretinal photocoagulation (PRP).² These observations suggest that retinal ischaemia and resultant hypoxia could mainly contribute to VEGF induction in diabetic retinopathy.

Advanced glycation end products (AGEs), senescent macroprotein derivatives formed at an accelerated rate under diabetes, also stimulate VEGF expression in cell cultures and animal models.^{3,4} In addition, vitreous AGE levels are positively correlated with VEGF in patients with diabetic retinopathy, suggesting that AGEs may be a stimulant of VEGF *in vivo*.⁵ However, as AGEs predispose the retinal vessels to thrombogenesis,³ whether AGEs could induce VEGF expression in an ischaemia-independent manner remains unknown. Therefore, in this study, we determined the relationship between vitreous levels of AGEs and VEGF in patients with diabetic retinopathy who were sufficiently treated with PRP for controlling retinal ischaemia.

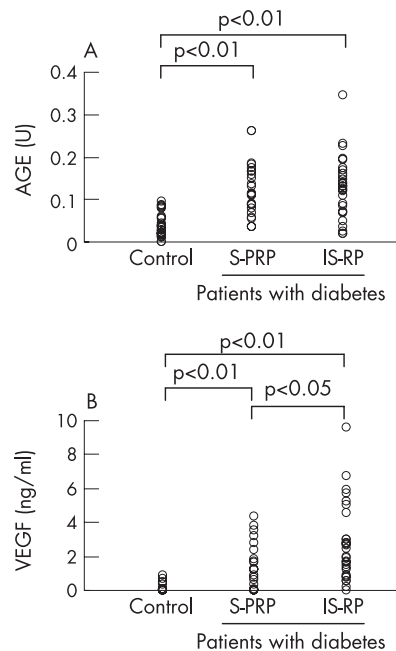


Figure 1 Vitreous levels of advanced glycation end products (AGEs; A) and vascular endothelial growth factor (VEGF; B) in controls without diabetes and in patients with diabetes, including the sufficiently treated group with panretinal photocoagulation (S-PRP) and the insufficiently treated group with no or focal photocoagulation (IS-RP). Data analysed by Mann-Whitney U test.

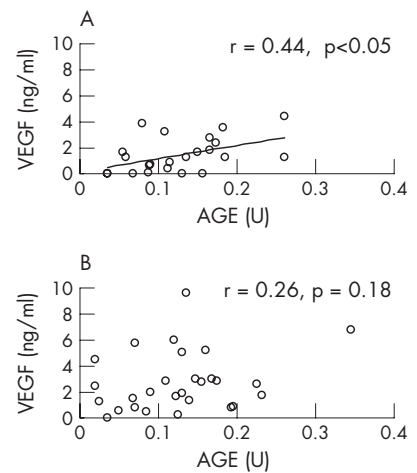


Figure 2 Correlation between the vitreous levels of advanced glycation end products (AGEs) and vascular endothelial growth factor (VEGF) in the sufficiently treated group with panretinal photocoagulation (S-PRP; A) and in the insufficiently treated group with no or focal photocoagulation (IS-RP; B). Spearman's correlation coefficient calculated by rank test.

Patients and methods

The study protocol was approved by our institutional ethics committee, and informed consent was obtained from all patients. Undiluted vitreous samples were collected during vitrectomy from patients with diabetes with a mean (standard deviation (SD)) age of 53 (12.6) years (45 samples from patients with proliferative diabetic retinopathy and 6 from those with diabetic macular oedema). Twenty eight samples from patients without diabetes with a mean (SD) age of 65.3 (6.7) years, having idiopathic macular hole or epiretinal membrane, served as controls. Vitreous levels of AGEs and VEGF were measured as described previously.⁷ We classified patients with diabetes into two groups: a sufficiently treated group with PRP (S-PRP; $n = 23$) and an insufficiently treated group (no or focal retinal coagulation; IS-RP; $n = 28$), on the basis of the extent of retinal photocoagulation before vitrectomy as described previously.⁶ The data were analysed by the Mann-Whitney U test and Spearman's correlation coefficient by rank test.

Results

Vitreous levels of AGEs and VEGF were significantly higher in patients with diabetes than in controls (mean (SD) 0.13 (0.07) v 0.04 (0.03) U and 2.15 (2) v 0.12 (0.23) ng/ml, respectively; $p < 0.01$). As fig 1A and B shows, vitreous VEGF levels were higher in IS-RP than those in S-PRP (2.75 (2.3) v 1.4 (1.3) ng/ml, respectively; $p < 0.05$), whereas there was no significant difference of vitreous levels of AGEs between IS-RP and S-PRP (0.13 (0.07) v 0.13 (0.06) U, respectively). A positive correlation was found between AGEs and VEGF in S-PRP ($r = 0.44$, $p < 0.05$), but not in IS-RP ($r = 0.26$, $p = 0.18$; fig 2 A,B).

Comment

Our observations suggest that AGEs may induce VEGF expression in an ischaemia-independent mechanism. In this study, the

positive correlation between vitreous AGEs and VEGF levels disappeared when retinal ischaemia was not sufficiently controlled. Therefore, with the progress of diabetic retinopathy, retinal ischaemia and subsequent hypoxia may become a major determinant of VEGF. Our findings suggest that inhibition of AGE formation could prevent the development of early diabetic retinopathy by suppressing VEGF expression.

Masahiko Yokoi

Department of Ophthalmology and Visual Sciences, Hokkaido University Graduate School of Medicine, Hokkaido, Japan

Sho-ichi Yamagishi

Department of Internal Medicine, Division of Cardiovascular Medicine, Kurume University School of Medicine, Kurume, Japan

Masayoshi Takeuchi

Department of Biochemistry, Faculty of Pharmaceutical Science, Hokuriku University, Kanazawa, Japan

Takanori Matsui, Yumiko Yoshida

Department of Internal Medicine, Division of Cardiovascular Medicine, Kurume University School of Medicine, Kurume, Japan

Kazuhiro Ohgami

Department of Ophthalmology and Visual Sciences, Hokkaido University Graduate School of Medicine, Hokkaido, Japan

Tamami Amano-Okamoto

Department of Ophthalmology, Nippon Telegraph and Telephone East Corporation Sapporo Hospital, Sapporo, Japan

Shigeaki Ohno

Department of Ophthalmology and Visual Sciences, Hokkaido University Graduate School of Medicine, Hokkaido, Japan

Correspondence to: Dr Masahiko Yokoi, Department of Ophthalmology, Teine-Keijinkai Hospital, Maeda 1-12, Teine-ku, Sapporo 006-8555, Japan; zoyokoi.tdr@keijinkai.or.jp

doi: 10.1136/bjo.2006.100198

Accepted 20 July 2006

Funding: This work was supported in part by Grants of Venture Research and Development Centers from the Ministry of Education, Culture, Sports, Science and Technology, Japan (SY), and the Specific Research Fund of Hokuriku University, Japan (MT).

Competing interests: None declared.

References

- 1 Tolentino MJ, Miller JW, Gragoudas ES, *et al*. Intravitreal injections of vascular endothelial growth factor produce retinal ischemia and microangiopathy in an adult primate. *Ophthalmology* 1996;**103**:1820-8.
- 2 Aiello LP, Avery RL, Arrigg PG, *et al*. Vascular endothelial growth factor in ocular fluid of patients with diabetic retinopathy and other retinal disorders. *N Engl J Med* 1994;**331**:1480-7.
- 3 Yamagishi S, Imaizumi T. Diabetic vascular complications: pathophysiology, biochemical basis and potential therapeutic strategy. *Curr Pharm Des* 2005;**11**:2279-99.
- 4 Yamagishi S, Amano S, Inagaki Y, *et al*. Advanced glycation end products-induced apoptosis and overexpression of vascular endothelial growth factor in bovine retinal pericytes. *Biochem Biophys Res Commun* 2002;**29**:973-8.
- 5 Yokoi M, Yamagishi S, Takeuchi M, *et al*. Elevations of AGE and vascular endothelial growth factor with decreased total antioxidant status in the vitreous fluid of diabetic patients with retinopathy. *Br J Ophthalmol* 2005;**89**:673-5.

6 Mitamura Y, Takeuchi S, Matsuda A, *et al*. Monocyte chemoattractant protein-1 in the vitreous of patients with proliferative diabetic retinopathy. *Ophthalmologica* 2001;**215**:415-18.

Postoperative subconjunctival 5-fluorouracil in the management of recurring pterygium

The treatment of choice for pterygium is surgical excision. Recurrence is the most common undesirable treatment outcome. Surgery and other modalities of treatment including β -irradiation, topical thiotepa, intraoperative and postoperative use of mitomycin C, 5-fluorouracil (5-FU) and daunorubicin, have been described to reduce recurrence.¹⁻⁹ Multiple surgery is itself a risk factor for recurrence.⁹ We present a case in which the fourth surgery for recurrent pterygium resulted in further recurrence, which was thwarted by multiple intralesional injections of 5-FU.

Case report

A 34-year-old Afro-Caribbean woman was referred to us in October 2004 for the management of recurrent pterygium in the right eye. She had two previous surgeries, the first in 2002 with conjunctival autograft and the second in 2003 leaving behind bare sclera. A third attempt at removal in 2004 was aborted owing to excessive intraoperative bleeding.

Her unaided visual acuity was 6/9 right eye and 6/6 left eye. The right eye showed a highly vascularised, fleshy nasal pterygium measuring 11 \times 8 mm. It had encroached 2.5 mm into the cornea (fig 1A). The recurrent pterygium in the right eye was excised for the third time in March 2005. On this occasion, mitomycin C (0.04%) was applied intraoperatively to the

scleral bed for 5 min and a double-layered amniotic membrane was grafted to cover the conjunctival defect. A recurrence at the original site was noted 2 months later (fig 1B), and in an attempt to arrest progression, topical 0.02% mitomycin C was given four times daily for 7 days (three cycles with an interval of 10 days between cycles). The recurrent pterygium, however, progressed to encroach on to the cornea (Fig 1C). At this point, subconjunctival injections of 5-FU into the advancing lesion, under topical anaesthesia, was started. A 26-gauge needle was used to deposit the injection in the core of the fibrovascular tissue away from the cornea. Over 5 months, she received 10 injections of 5-FU (5 mg in 0.2 ml/injection) given 1-2 weeks apart until the recurrent pterygium became less vascular and atrophic. No complications were noted. Now, 8 months after the last injection, there is no progression (fig 1D).

Comment

Pterygium recurrence is thought to be due to fibroblast proliferation and migration and hence use of 5FU, which inhibits fibroblastic activity, is believed to reduce recurrence rates. 5-FU is toxic only to proliferating cells and is considered to be safer than other agents.¹⁰ Postoperative use of 5-FU to halt the progression of recurrence has been described before, but involved a maximum of four injections with a maximum dose of 3 mg.¹¹ Our patient received 10 injections totalling 50 mg of 5-FU with no complications.

In cases with a high risk of recurrence, such as the one described, intralesional subconjunctival injection of 5-FU even at large doses seems to be safe, effective and well tolerated by the eye. Such an intervention should be considered as an option in the management of difficult cases of recurrent pterygium.

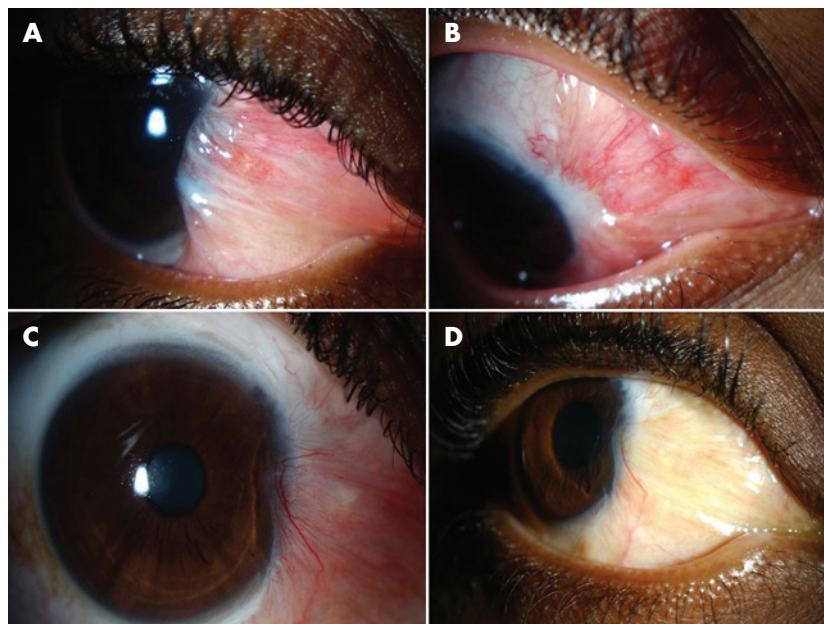


Figure 1 (A) Anterior segment photograph showing the fleshy recurrent pterygium before the third excision. (B) Photograph showing conjunctival recurrence of the pterygium 2 months after the third excision with intraoperative mitomycin C and amniotic membrane. (C) Photograph showing progression of recurrence and encroachment into the cornea. (D) Photograph showing appearance of the pterygium 8 months after the tenth 5-fluorouracil injection. Informed consent was obtained for publication of this figure.