



HOKKAIDO UNIVERSITY

Title	TRANSPLANTATION OF CANINE TRANSMISSIBLE VENEREAL SARCOMA : AUTORADIOGRAPHIC STUDY WITH ³ H-THYMIDINE
Author(s)	KUDO, Tadaaki; KOIKE, Toshio; OTOMO, Kanjuro et al.
Citation	Japanese Journal of Veterinary Research, 22(4), 105-110
Issue Date	1974-10
DOI	https://doi.org/10.14943/jjvr.22.4.105
Doc URL	https://hdl.handle.net/2115/2055
Type	departmental bulletin paper
File Information	KJ00002371175.pdf



**TRANSPLANTATION OF CANINE TRANSMISSIBLE
VENEREAL SARCOMA :
AUTORADIOGRAPHIC STUDY WITH ³H-THYMIDINE**

Tadaaki KUDO, Toshio KOIKE, Kanjuro OTOMO
and Tamotsu SAKAI

*Department of Veterinary Surgery
Faculty of Veterinary Medicine
Hokkaido University, Sapporo, Japan*

(Received for publication, March 8, 1974)

Canine transmissible venereal sarcoma, maintained from puppy to puppy since 1967, was labeled with ³H-thymidine and transplanted by subcutaneous injection in the hypogastric regions of two puppies. It was observed that the newly formed tumors were canine transmissible venereal sarcoma and that the tumor cells contained ³H-thymidine. It was proved that the new tumors were caused by multiplication of the transplanted tumor cells.

INTRODUCTION

Since the work of NOVINSKY (1876), many investigators have studied canine transmissible venereal sarcoma. Regarding the transplantation of this tumor, the following assumptions have been made: 1) The new tumor was caused by multiplication of the transplanted tumor cells; 2) The new tumor was caused by multiplication of both the transplanted tumor cells and stroma; 3) The transplanted tumor cells stimulated the tissue of the host and thus gave rise to the new tumor.

Autoradiography with ³H-thymidine labeling provides a direct approach to the cause of this tumor. It is the purpose of this paper to report the presence of radioisotopically labeled tumor cells in the newly formed tumor tissues after inoculation of the ³H-thymidine-labeled tumor cells.

MATERIALS AND METHODS

In our laboratory canine transmissible venereal sarcoma was passed through 30 generations of puppies over a period of 8 years by subcutaneous injections in the right and left hypogastric regions of each puppy^{8,9)}. The tumor used in this work came from the 24th generation. The donor, weighing 5.5 kg, was injected intravenously with 2.5 mCi of ³H-thymidine (specific activity, 5.0 Ci/mM), 0.2 mCi/ml diluted with Ringer's solution, and 0.5 mCi of the ³H-thymidine was injected into the right tumor tissue at the same time. The right and left tumor

tissues were enucleated 6 hours after the injection. A portion of the right tumor tissue was used for inoculations given to recipients⁷⁾, and the left tumor tissue was used as the control. The right and left hypogastric regions of the recipients (two puppies weighing 3 kg) were inoculated subcutaneously with 3 ml (5×10^4 cells/ml) of the tumor cell suspension (cell viability = 35%)⁷⁾. The newly formed tumors were excised from each of the sites five and ten days after implantation. All specimens were fixed in Bouin's fluid, embedded with paraffin, and cut to 4 microns.

The slides were dipped for 3 seconds in Sakura NR-M2 nuclear emulsion at 45°C, diluted with an equal volume of distilled water, and then exposed for 10 days in a refrigerator (4~6°C). After development, the slides were stained in the usual manner with hematoxylin and eosin and mounted. The slides thus prepared were employed to swing the labeled tumor cells. One thousand cells of the tumor were examined for each determination.

Cells with two or more silver grains were considered to be labeled cells. This value was based on a background grain count never higher than 0.5 grain per 50 square microns^{6,11)}.

RESULTS

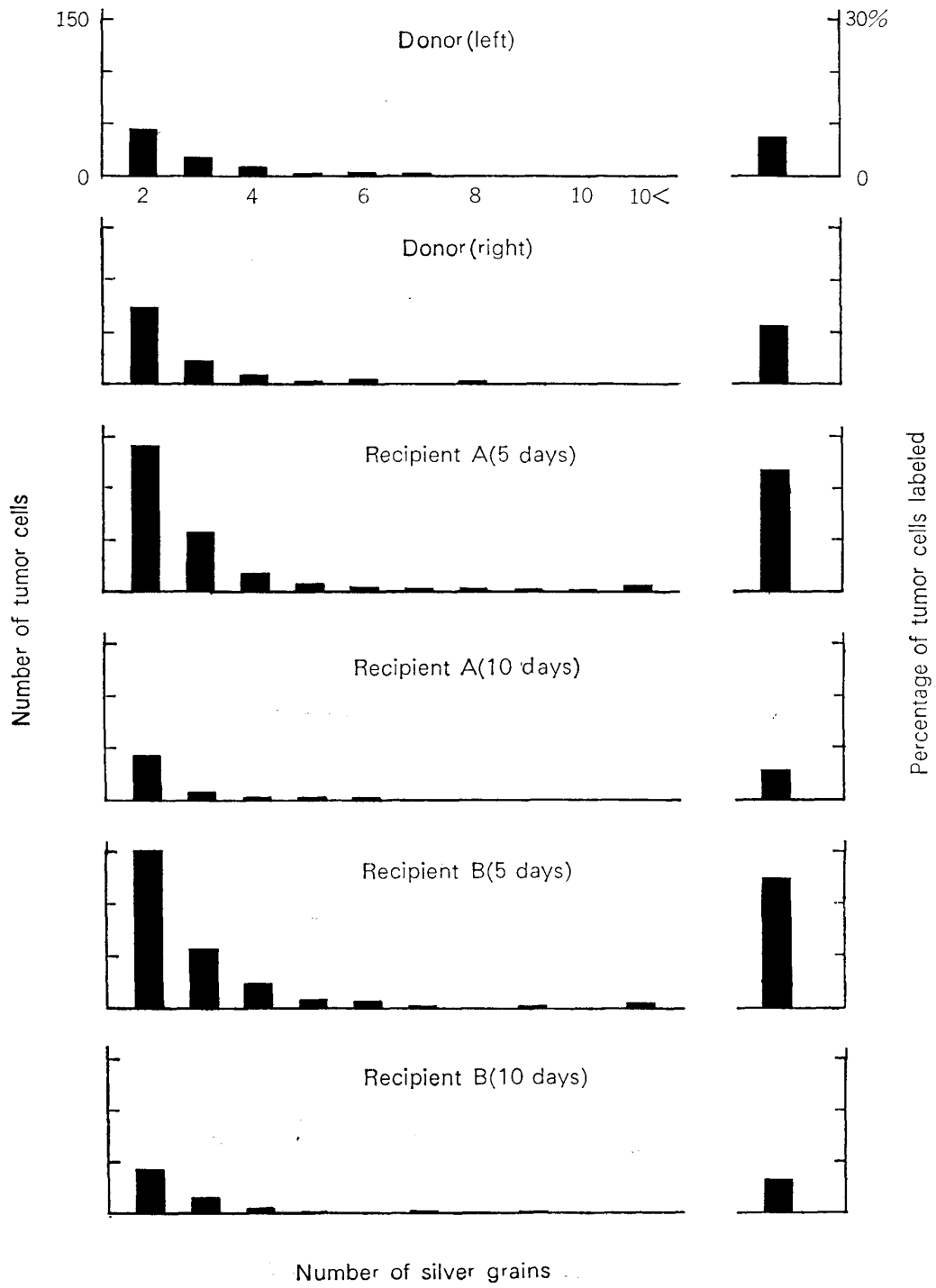
Histological findings

The tumors of the donor and recipients showed typical features of canine transmissible venereal sarcoma. In the donor, the tumor tissues were surrounded with loose fibrous tissues and the tumor cells were densely packed. The tumor tissues had scanty fibrous stroma. The tumor cells were palestained with amorphilic cytoplasm, and the cell margins were indistinct. These nuclei were round or oval in shape. They contained a granular chromatin pattern and had distinct nucleoli. Histological features of the tumor tissues of the recipients were similar to those of the donors' tissues. The tumor tissues of the recipients were examined on the fifth day after implantation of the tumor and fibroblastic proliferation and especially a small number of neutrocytic and lymphocytic infiltrations were seen in the peripheral portions of the tumor tissues. The tumor cells were arranged in rows or cords along delicate strands of fibrous stroma and a large number of lymphocytes had infiltrated in the peripheral portions of the tumor tissues on the tenth day after implantation of the tumor.

Autoradiographical findings

The ³H-thymidine-labeled nuclei of these tumor cells were observed in the donor and recipients (figs. 2~4). The contents of this work which were evalu-

FIGURE 1 *Distribution of tumor cell grain counts and percentage labeled tumor cells*



ated by using the autoradiographic technique are shown on figure 1. The percentage of the labeled tumor cells in the left tumor of the donor was 7.4%. The maximum number of silver grains on the tumor cell nucleus was 7. The percentage in the right tumor of the donor was 11.2%. The maximum number of silver grains was 8.

The percentage in the labeled tumor of recipient A was 23.6% on the fifth day and 5.5% on the tenth day after implantation. The maximum number of silver grains was 33 on the fifth day after implantation and 6 on the tenth day.

The percentage in the tumor of recipient B was 24.8% on the fifth day and 6.6% on the tenth day after implantation. The maximum number of silver grains was 29 on the fifth day after implantation and 9 on the tenth day.

DISCUSSION

Experimental transmission of this tumor may be accomplished by using only viable cells^{4,10,15,16}). The previous reports were confirmed by our experimental transmission of this tumor.

On the transplantation of this tumor the following facts were observed. BASHFORD et al. (1905) concluded that all of the transplanted tumor cells died within three or four days after the inoculation, but that the connective tissue cells at the site of inoculation were transformed into tumor cells which were indistinguishable from those of the primary growth. WADE (1908) decided that the tumor which developed after inoculation of the tumor was formed in part by the transplanted cells and in part by the transformed cells of the host. BEEBE & EWING (1906) found that the central portions of the transplanted tissue underwent necrosis, but that some of the tumor cells in the peripheral portions persisted and multiplied by mitosis to form new tumors. HÖRNER (1936) allo-transplanted the tumor tissue of a mouse into the subcutaneous tissue. He found that a large percentage of transplanted tumor tissue underwent necrosis, but that some of the tumor cells in the peripheral portions persisted and multiplied by mitosis to form new tumors, and that all stroma in the transplanted tissue underwent necrosis. AJELLO & GIMBO (1965), however, reported that they were able to transmit this tumor by inoculation of extracts from tumor tissue. SAPP & ADAMS (1970) reported the existence of C-type viral particles in these tumor cell cultures.

The present investigators observed that the newly formed tumors were labeled with ³H-thymidine on the fifth and tenth day after the inoculation of the tumor (fig. 1). OHKITA (1967) reported that ³H-thymidine released from breakdown cells influenced scarcely to the radiographic observation. Therefore, it was not thought that the ³H-thymidine-labeled tumor cells of recipients were

produced from the fibroblasts of recipients within five and ten days after the inoculation of the tumor. It was observed in this experiment that the percentage of labeled tumor cells in the donor was lower than in the recipients on the fifth day after inoculation, and that it was not so much higher than that of the recipients on the tenth day after inoculation. Therefore, it is impossible that the fibroblasts of the recipients were transformed into tumor cells.

Thus, it has been proved that the new tumor arises by multiplication of the transplanted tumor cells.

ACKNOWLEDGEMENTS

The authors are grateful to Prof. G. YOSHII and Dr. Y. H. NAKANISHI, Department of Experimental Radiobiology, Faculty of Veterinary Medicine, Hokkaido University, for their kind advice regarding various problems in radiology.

REFERENCES

- 1) AJELLO, P. & GIMBO, A. (1965): *Archo vet. ital.*, **18**, 275
- 2) BASHFORD, E. F., MURRAY, J. A. & CRAMER, W. (1905): *Scient. Dep. Invest. imp. Res. Fund*, (2) Part 2, 33
[DEMONBREUN, S. P. & GOODPASTURE, E. W. (1934): *Am. J. Cancer*, **21**, 295]
- 3) BEEBE, S. P. & EWING, J. (1906): *J. med. Res.*, **15**, 209
- 4) DEMONBREUN, S. P. & GOODPASTURE, E. W. (1934): *Am. J. Cancer*, **21**, 295
- 5) HÖRNER, O. (1936): *Z. Krebsforsch.*, **43**, 377
- 6) KOIKE, T. & NODA, H. (1971): *Jui-chikusan Shinpo (J. vet. Med.)*, (553) 1082 (in Japanese)
- 7) KOIKE, T., NODA, H. & SAKAI, T. (1972): *J. Hokkaido vet. med. Ass.*, **16**, 199 (in Japanese)
- 8) KOIKE, T., MATSUBARA, K. & SAKAI, T. (1973): *Chromosome Inf. Serv.*, (14) 33
- 9) KOIKE, T., NODA, H. & OTOMO, K. (1973): *Med. Biol.*, **86**, 345 (in Japanese)
- 10) MATSUBA, S. & HIROYE, I. (1927): *Jap. J. vet. Sci.*, **6**, 167
- 11) MURREY, R. G. & MURREY, A. (1961): *Blood*, **20**, 737
- 12) NOVINSKY, M. (1876): *Zentbl. med. Wiss.*, **14**, 790
- 13) OHKITA, T. (1967): *Acta haemat. jap.*, **30**, 507
- 14) SAPP, W. J. & ADAMS, E. W. (1970): *Am. J. vet. Res.*, **31**, 1321
- 15) STICKER, A. (1906): *Z. Krebsforsch.*, **4**, 277
- 16) STUBBS, E. L. & FURTH, J. (1934): *Am. J. Path.*, **10**, 275
- 17) WADE, H. (1908): *J. Path. Bact.*, **12**, 384

EXPLANATION OF PLATE

Fig. 2 ^3H -thymidine-labeled tumor cells (arrows) of donor (right hypogastric region)

× 1,700

Fig. 3 ^3H -thymidine-labeled tumor cell (arrow) of recipient B (5 days after inoculation of tumor cells)

× 1,700

Fig. 4 ^3H -thymidine-labeled tumor cells (arrows) of recipient A (10 days after inoculation of tumor cells)

× 1,700

