



HOKKAIDO UNIVERSITY

Title	PARASITES OF THE JAPANESE BADGER, MELES MELES ANAKUMA TEMMINCK, ESPECIALLY ON ISTHMIOPHORA MELIS (SCHRANK, 1788) LUHE, 1909
Author(s)	KAMIYA, Haruo; SUZUKI, Yoshitaka
Citation	Japanese Journal of Veterinary Research, 23(4), 125-130
Issue Date	1975-10
DOI	https://doi.org/10.14943/jjvr.23.4.125
Doc URL	https://hdl.handle.net/2115/2070
Type	departmental bulletin paper
File Information	KJ00002371230.pdf



PARASITES OF THE JAPANESE
BADGER, *MELES MELES ANAKUMA* TEMMINCK,
ESPECIALLY ON *ISTHMIOPHORA MELIS*
(SCHRANK, 1788) LÜHE, 1909

Haruo KAMIYA and Yoshitaka SUZUKI*

Department of Parasitology
Faculty of Veterinary Medicine
Hokkaido University, Sapporo, Japan

(Received for publication, July 11, 1975)

A trematode species, *Isthmiophora melis* (SCHRANK, 1788) LÜHE, 1909, was found in the small intestine of a badger, *Meles meles anakuma* TEMMINCK, captured in Gifu, central Japan, on June 10, 1974. The differentiation among *I. melis*, *Euparyphium beaveri*, YAMAGUTI, 1958, and *Echinostoma hortense* ASADA, 1926, was discussed. A coccidian parasite, *Eimeria* sp., was also found in the mucosal epithelium of the jejunum. Furthermore, an unidentified nematode was observed in the jejunal mucosa.

INTRODUCTION

There are a few reports about the parasites of the badger, *Meles meles anakuma*, in Japan, such as *Toxocara canis* and *Tetragomphius melis* by YAMAGUTI (1941) and OHBAYASHI et al. (1974), respectively. On the other hand, *Isthmiophora melis* (SCHRANK, 1788) LÜHE, 1909, was found only in the weasel (*Mustela sibirica*) by YOSHIDA et al. (1932) and in the dog by YAMASHITA (1939) in Japan. In this paper, we compare *I. melis* with several allied echinostomid species, and deal with a coccidian parasite, *Eimeria* sp., and an unidentified nematode recognized in histological section preparations of the small intestine.

MATERIALS AND METHODS

The worms were obtained from a small intestine preserved in 10% formalin solution. Some whole-mounted specimens were stained with Semichon's carmine, and paraffine sections for microscopy were stained with hematoxylin-eosin.

* Present address: Department of Veterinary Anatomy, Faculty of Agriculture, Gifu University, Gifu, Japan

DESCRIPTIONS AND DISCUSSIONS

1) *Isthmiophora melis* (SCHRANK, 1788) LÜHE, 1909
(Trematoda: Echinostomatidae)

The number of worms obtained from the duodenum, jejunum, and ileum was 4, 57, and 14, respectively. Some of them were tightly attached to the mucosa by their head collar and suckers. The measurements were based on 10 matured specimens.

Description: Body elongate, leaf-shape, abruptly tapering anterior to acetabulum, more gradual in hind body. Matured worms 4.778~5.957 mm in length, with the maximum width at or just back of acetabulum, 0.897~1.248 mm. Cuticle 0.016~0.020 mm thick. Cuticular spines, stout, well developed, showing tilelike appearance, extending to acetabulum dorsally and to testis ventrally. Oral sucker subterminal, elliptical, 0.176~0.218×0.196~0.248 mm in size. Head collar well developed, 0.326~0.391 mm in diameter. Collar spines 27 in number, tightly attached to head collar. Crown of spines double, dorsally uninterrupted. Dorsal spines 0.049~0.075 mm long by 0.013~0.016 mm wide. Marginal spines not abruptly pointed 0.062~0.082 mm long by 0.013~0.022 mm wide. Prepharynx scarcely recognizable. Pharynx well developed, elongated oval, 0.111~0.163×0.196~0.228 mm in size. Narrow esophagus, short 0.130~0.163 mm long. Bifurcation of esophagus immediately in front of acetabulum. Narrow ceca extending just at posterior end. Acetabulum well developed, oval, 0.507~0.650×0.546~0.754 mm in size, situated one-fourth into the anterior part. Distance from anterior end to middle of acetabulum 0.806~0.910 mm long. Testes tandem, usually contiguous in each other, situated, approximately in the equatorial position. Anterior testis always wider than length, but posterior testis always longer than width. Testis varies in shape with some notches. Size of anterior testis and of posterior testis 0.440~0.637×0.339~0.545 mm and 0.326~0.544×0.481~0.624 mm, respectively. Cirrus sac big, oval in shape, situated between bifurcation of esophagus and about middle of acetabulum, 0.196~0.325×0.388~0.598 mm in size. Genital pore at just behind esophageal bifurcation. Ovary regular in outline, spherical to oval, located on right side of anterior testis, 0.241~0.313×0.186~0.303 mm in size. The most proximal portion of uterus forms seminis receptaculum uterium; true seminal receptacle obscure. Uterus short with few eggs, about 25~120 in number. Eggs 0.114~0.130×0.052~0.069 mm in size. Eggs deposited in the villi of intestine. Mehlis' gland well developed. Distance from posterior end of acetabulum to anterior margin of fore-testis, 0.819~1.040 mm. Follicular vitellaria extending from lateral side of anterior margin of ovary to posterior end of ceca. Vitelline reservoir posterior

and dorsal to Mehlis' gland, receiving vitelline ducts from each side of body just along anterior margin of fore-testis. Vitellaria extracecal up to posterior to hind-testis, and then intercecal. Excretory pore subterminal and dorsal.

Pathological findings: In spite of numerous body spines of the trematode, the damage produced in the mucosa of the intestine is minimal. The destruction of the mucosa, however, was observed at the portion of attachment of head collar and suckers, especially the acetabulum. The cellular reactions were scarcely recognizable.

Discussion: *I. melis* was reported in the weasel (*Mustela sibirica*) and the dog of Japan by YOSHIDA et al. (1932) and YAMASHITA (1939), respectively. The seminal receptacle in this species, however, was not clearly recognizable. The measurement corresponded well to that of the latter. On the other hand, DÖNGES (1967 & 1968) considered that *Euparyphium suinum* CIUREA, 1921, and *E. spiculator* (DUJARDIN, 1845) were synonyms of *I. melis*, and that the differentiations of measurement among these species corresponded to the host species. Furthermore, Hsü (1940) considered that *E. jassyensis* LEON et CIUREA, 1922, from a human case, was a synonym for *I. melis*.

For *E. melis* by BEAVER (1941), *Euparyphium beaveri* was established by YAMAGUTI (1958) as a new species based on the collar spines being abruptly tapered at the outer end, the cirrus being heavily spined, and the eggs being definitely narrower than *I. melis*. The egg size of the present specimens is similar to that of *E. beaveri*, but the former differs from the latter in the shape of collar spines, body spines, testes, etc. The difference of egg size between the present specimens and that of DÖNGES (1967) may be due to the methods of fixation used.

LUMSDEN & ZISCHKE (1961) redescribed *E. beaveri* from *Mustela vison*, but their specimens apparently differ from the present ones in the shape of body, testes and the distribution of testes, etc. In this examination we identified the present specimens as *I. melis*, considering the above-mentioned characteristics. For more detailed differentiation between the two species, we are of the opinion that it is necessary to study the specimens of adult and larva at various developmental stages obtained by experimental infection.

In addition, we compared *I. melis* with *Echinostoma hortense* ASADA, 1926, since both species possess 27 collar spines. *I. melis*, however, is easily distinguished from *E. hortense* in body shape, in the shape and size of collar spines, and in the diameter of head collar, the outline of testis, etc.

2) *Eimeria* sp. (Sporozoa: Eimeriidae)

Eimeria sp. were detected in the jejunal mucosa. Numerous oocysts 0.020 ~ 0.021 × 0.014 ~ 0.017 mm in size, a small number of macrogametocytes, and

a few microgametocytes were observed in the epithelium. Macrogametocytes with many basophilic and a few eosinophilic granules, $0.015\sim 0.022\times 0.013\sim 0.020$ mm in size. Microgametocytes with many microgametes, about 0.020 mm in diameter.

Discussion: Two species of Eimeriidae, *Eimeria melis* KOTLÁN & POSPESCH, 1933, and *Isospora melis* (KOTLÁN & POSPESCH, 1933) PELLÉRDY, 1955, are known to be found in the badger, *Meles meles* LINNAEUS (PELLÉRDY, 1965). The size of oocysts is $0.017\sim 0.024\times 0.013\sim 0.017$ mm in the former and $0.026\sim 0.034\times 0.020\sim 0.027$ mm in the latter. The coccidian parasite in this study probably belongs to genus *Eimeria*, but final identification must be made in the future after detailed investigations of various developmental stages.

Appendix Nematoda gen. sp. was recognized in histological section preparations. The worms were detected in the mucosal epithelium of the jejunum. The diameter of the worm in the intestinal portions was $0.025\sim 0.030$ mm. Cellular reactions to the worms were not observed in the surrounding tissue. It was difficult to clarify the proper taxonomical portion at present, due to limited materials.

ACKNOWLEDGEMENTS

The authors wish to express their gratitude to Asst. Prof. M. OHBAYASHI of this Department for his kind direction and review. Further thanks are offered to Mr. H. INUMA, Gifu Municipal Office, for providing the badger examined.

REFERENCES

- 1) BEAVER, P. C. (1941): *J. Parasit.*, **27**, 35
- 2) DÖNGES, J. (1967): *Z. ParasitKde.*, **29**, 1
- 3) DÖNGES, J. (1968): *Ibid.*, **30**, 179
- 4) HSÜ, H. F. (1940): *Chin. med. J.*, **58**, 552
- 5) KOTLÁN, A. & POSPESCH, L. (1933): *Parasitology*, **25**, 102
- 6) LUMSDEN, R. D. & ZISCHKE, J. A. (1961): *Tulane Stud. Zool.*, **9**, 77
- 7) OHBAYASHI, M., SUZUKI, Y. & ARAKI, J. (1974): *Jap. J. vet. Res.*, **22**, 43
- 8) PELLÉRDY, L. (1955): *Acta vet. hung.*, **5**, 421
- 9) PELLÉRDY, L. (1965): "Coccidia and coccidiosis" led., Budapest: Akadémiai Kiadó
- 10) YAMAGUTI, S. (1941): *Jap. J. Zool.*, **9**, 409
- 11) YAMAGUTI, S. (1958): "The digenetic trematodes of vertebrates" *Systema helminthum*, **1**, New York & London: Interscience Publ.
- 12) YAMAGUTI, S. (1971): *Synopsis of digenetic trematodes of vertebrates*, Tokyo: Keigaku Publ.
- 13) YAMASHITA, J. (1939): *Oyo-Dobuts.-Zasshi*, **11**, 25 (in Japanese with English summary)
- 14) YOSHIDA, S., IWATA, S. & TOYOTA, K. (1932): *Trans. Soc. path. jap.*, **22**, 76 (in Japanese)

EXPLANATION OF PLATE

Figs. 1~6 *Isthmiophora melis* (SCHRANK, 1788)

Fig. 1 General view

Fig. 2 Head collar with unclear double rows of collar spines and body spines showing a tilelike appearance; ventral view

Fig. 3 Collar spines showing clear double rows; dorsal view

Fig. 4 Morphological variations of anterior testes

Fig. 5 Morphological variations of posterior testes

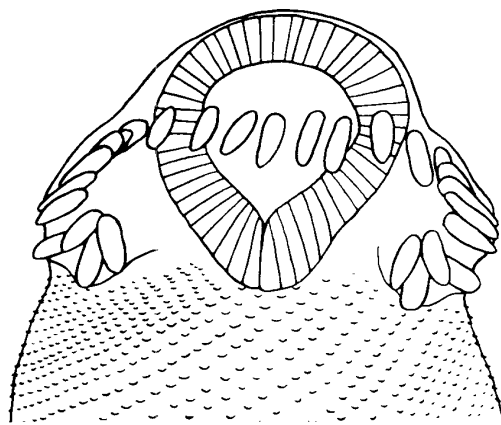
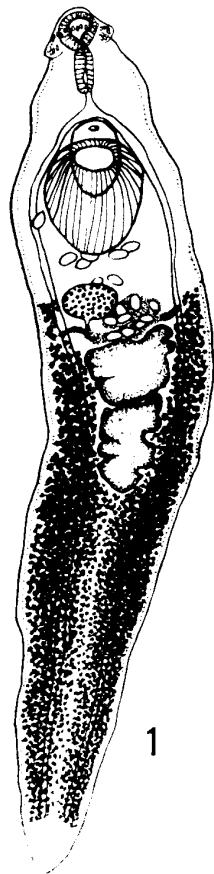
Fig. 6 Section of small intestine showing the mucosal destruction through attachment by acetabulum
Hematoxylin-eosin (H.-E.) stain

Figs. 7 & 8 *Eimeria* sp., section preparations

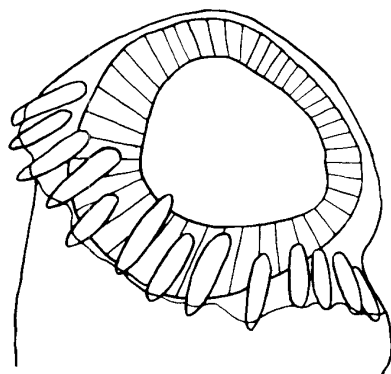
Fig. 7 Small intestine showing numerous oocysts H.-E. stain

Fig. 8 Small intestine showing macrogametocytes H.-E. stain


Fig. 9 Small intestine showing cross sections of unidentified nematode




2



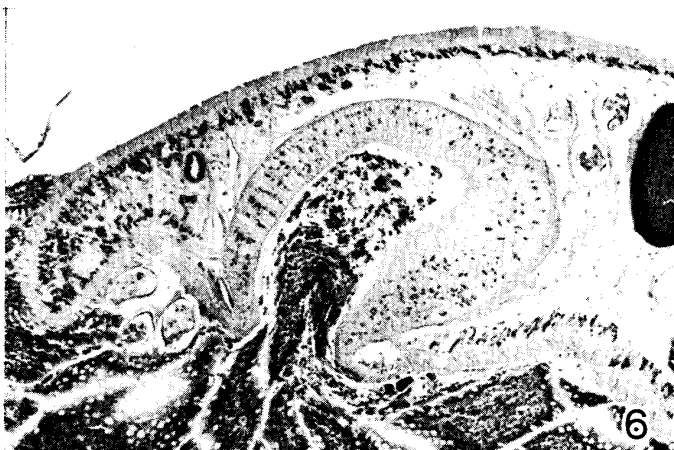3



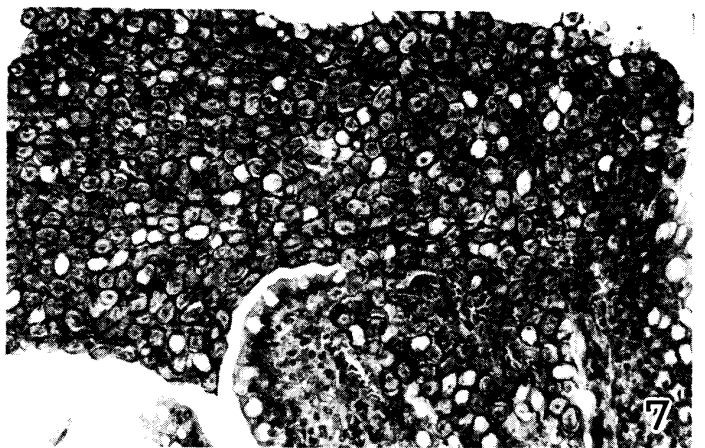
4



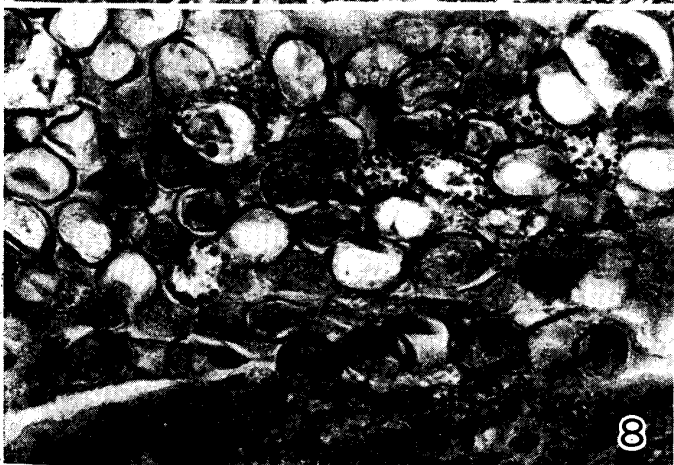5



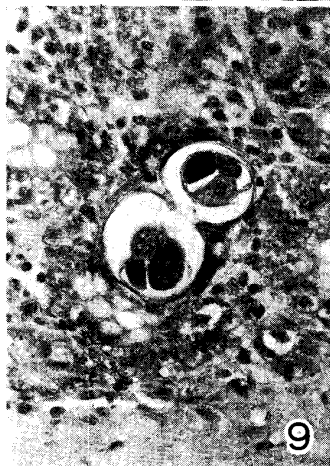6



7



8



9

1 mm	: 1
0.2 mm	: 2
0.2 mm	: 3
0.5 mm	: 4, 5
0.3 mm	: 6
0.1 mm	: 7
0.05 mm	: 8
0.1 mm	: 9