



# HOKKAIDO UNIVERSITY

Title	EXPERIMENTAL STUDIES IN INTESTINAL HEALING OF THE DOG : III AN END-TO-END INTESTINAL ANASTOMOSIS USING A DECALCIFIED BONE TUBE
Author(s)	HAGIO, Mitsuyoshi; KOIKE, Toshio; SAKAI, Tamotsu
Citation	Japanese Journal of Veterinary Research, 24(1-2), 25-30
Issue Date	1976-05
DOI	<a href="https://doi.org/10.14943/jjvr.24.1-2.25">https://doi.org/10.14943/jjvr.24.1-2.25</a>
Doc URL	<a href="https://hdl.handle.net/2115/2077">https://hdl.handle.net/2115/2077</a>
Type	departmental bulletin paper
File Information	KJ00002373169.pdf



EXPERIMENTAL STUDIES IN INTESTINAL  
HEALING OF THE DOG  
III AN END-TO-END INTESTINAL ANASTOMOSIS  
USING A DECALCIFIED BONE TUBE

Mitsuyoshi HAGIO, Toshio KOIKE  
and Tamotsu SAKAI

*Department of Veterinary Surgery  
Faculty of Veterinary Medicine  
Hokkaido University, Sapporo, Japan*

(Received for publication, February 4, 1976)

This study was carried out in order to seek further rational method of the end-to-end small intestinal anastomosis in the dogs. An experimental method using a decalcified bone tube and the standard inverting two-layer anastomosis were compared in 20 healthy, mongrel dogs. The decalcified bone tube (2.5~3.0 cm×1.2~1.8 cm) inserted into the intestinal lumen at the anastomotic site, greatly facilitated suturing as an aid. The animals were sacrificed 1 and 2 weeks after the operation. Clinical, histological and angiographical observations were performed. The experimental method appeared to be superior to the standard method.

INTRODUCTION

In our experience, intestinal obstruction in the dogs almost invariably concerns the small intestine; furthermore, this disease occurs most commonly in the dogs of less than one year old. In these cases, the excessive inverted cuff usually formed after the standard two-layer end-to-end anastomosis, constitutes an obstruction hazard because of a narrow intestinal lumen.

To lessen the problem of stenosis, the techniques such as, the single-layer inverting and everting intestinal anastomosis have been tried in the dogs,<sup>1,2,4,17,19)</sup> but none have been generally accepted in our veterinary field.

Intestinal anastomosis using some prosthesis, is a unique technique, which developed early in the nineteenth century, having many followers, but its popularity declined later. Recently, several investigators<sup>3,5,6,17,19)</sup> have reported this kind of techniques, with successful results.

This study was designed to further evaluate the effectiveness of this type of anastomosis. We compared the experimental method using a decalcified bone tube as a prosthesis with the standard two-layer anastomosis.

## MATERIALS AND METHODS

Anastomoses were performed with 20 healthy mongrel dogs of 40 to 60 weeks old, average weight 10 kg. The pre- and postsurgical treatments were made by methods previously described<sup>11)</sup>. The animals were anesthetized with sodium pentobarbital. After opening the abdomen through the midline incision, the intestine was transected 15 to 30 cm from the ileocecal junction. The animals were divided into two groups.

## Control group

The standard two-layer end-to-end anastomosis to be used has been provided in the previous report<sup>10)</sup>.

## Experimental group (figs. 1~8)

The electrically decalcified bone tube, obtained from an adult sheep's tibia, was used in this group as a prosthesis. The tube was 2.5~3.0 cm in length and 1.2~1.8 cm in the outside diameter. The bone tube was inserted into proximal lumen of the severed ends, and fixed to the inner wall with four silk sutures. The tube was then introduced into distal lumen to be joined, and interrupted Czerny sutures were placed around the circumference of the intestine. Eight to ten interrupted sutures were usually needed.

After completing the anastomosis, the anastomotic defects of both types of anastomoses were covered with the omentum, but the omentum was not fixed in its place by sutures. The intestine was then returned to the abdomen.

The time required for completing each type of anastomoses was recorded. Five animals in each group were sacrificed on the 7th and 14th day, respectively, after completion of the anastomosis to study the changes at the operated site of intestine. Immediately thereafter, the procedures described previously were done for the histological and microangiographic assessments<sup>11)</sup>. The daily clinical observation was also performed until the time of sacrifice in each dog.

## RESULTS

## Operating time

The operation in the control method averaged 30 minutes and the experimental one 14 to 17 minutes.

## Fate of the decalcified bone tube

The decalcified bone tube was passed with the discharges 3 to 4 days after surgery, which became softend and disintegrated or remained unchanged.

### Clinical observations

Death did not occur in both types of anastomoses. Nine of 10 experimental group dogs showed normal appetite sooner, passed normal feces earlier, and gained weight normally. In contrast, recovery of the control group dogs was generally delayed. There were also 3 cases which showed good recovery in the early stage of the observation period, but then their condition deteriorated during the remainder of the period. On the 2nd to 4th day after surgery, 3 of 10 dogs in control group showed vomiting, which was suggestive of a partial obstruction of the intestinal tract. Thereafter, these 3 dogs showed no signs of vomiting until the time of killing.

### Gross findings

At necropsy, adhesions between the omentum and the anastomotic site were more prominent in the experimental group dogs than in the control group dogs after one and two weeks. In both types of anastomoses, adhesions were confined to the anastomotic site. Dilation of the intestinal lumen proximal to the anastomotic site was found in 2 of 10 cases in the control group, which were vomiting within the first 2~4 days after surgery. In contrast, there was no noticeable dilation of the proximal portion of the lumen at the anastomotic site in the experimental group.

### Histological findings (figs. 9~12)

The control method 7 days after surgery showed a marked inverted tissue of all intestinal layers, with a moderate degree of inflammation. Mucosal regeneration on the defect was as yet incomplete. In some sections, necrotic tissue within the inner silk suture was noted. In the 14-day specimens taken from the same anastomosis, there was still a substantial intraluminal protrusion, with very little evidence of inflammation. The connective tissue on the serosal surfaces was more dense, and mucosal coverage was almost completed.

The experimental method, 7 and 14 days after surgery, resulted in the surprising minimal turn-in of the intestinal wall. The specimens taken at 7 days in this anastomosis showed that a small amount of young connective tissue joined all layers of intestine, and that on the luminal side of this connective tissue, a layer of mucosal epithelium was regenerating from both sides. A moderate degree of inflammation was seen at the anastomotic site and its vicinity. In the 14-day specimens with this anastomosis, there was a densely formed connective tissue bridging all layers of intestine. Tissue reaction subsided, and mucosal coverage was complete.

### Angiographic findings (figs. 13~16)

Angiograms made on the 7th day following surgery in the control method

revealed that at the anastomosed portion, a number of minute blood vessels were regenerated from the serous blood vessels of both sides. At 14 days, a small increase in vascularity at the anastomotic site was generally seen, and there was, in part, a vascular contact between the apposed serosal surfaces.

The experimental method at 7 days showed a poor vascularity on the mucosal side, with a few minute blood vessels regenerated from the submucous vessels. On the serosal side, a quite number of new vessels were seen in the adherent area between the serosa and omentum. At 14 days, a good vascularity was maintained at the anastomotic site, where new vessels regenerated from the serous and omental vessels, predominated.

#### DISCUSSION

In determining the results of all types of anastomoses, the following facts are very important: 1) the anastomosis could be easily accomplished even by inexperienced surgeons, and require the least time; 2) it should have no anastomotic complications, such as leakage, stenosis, and adhesions; 3) its wound could heal and function normally as soon as possible.

As early as 1887, SENN recommended the decalcified bone plates as the prosthesis, after many trials with materials of different kinds. Recent investigators<sup>3,5,6,17,19)</sup> obtained good results with this type of anastomosis, using macaroni, spaghetti, plastic tube, and other digestible substances as the prosthesis. In this study, we used the decalcified bone tube, which offered a rigid base, so that suturing the soft and fragile intestine was readily made. The decalcified bone tube inserted was passed without any difficulty in a few days after surgery. On the other hand, the control anastomosis needs great skill, and also great care must be paid in suturing to avoid the luminal obstruction at the anastomotic site. In addition, the time required for the completion of the experimental method, was almost half of that required for the control method, which fact is of great importance in the operation for the intestinal obstruction, as the dogs brought to the clinic are usually greatly exhausted before the operation.

It is surprising that the experimental group was distinctly superior, for general conditions of the dogs after surgery, to the control group, which was regarded as the safest method. The signs of vomiting, gradual weight loss, no appetite, and proximal distention seen in some dogs with the control method may be largely due to the excessively formed inverted tissue at the anastomotic site.

In comparative studies of the single-layer and two-layer intestinal anastomoses in the dog and rat, some workers<sup>13,15)</sup> have observed less tissue damage

and more rapid healing after the single-layer anastomosis, while others<sup>8,14)</sup> have found no difference between them. Our results based on the histological findings would rather support the former. Anastomotic healing in the control method was more delayed in view of mucosal coverage on the defect, inflammatory response, and tissue destruction than in the experimental anastomosis. It is of further importance that the anastomotic site after the experimental method returned more nearly to normal structures of intestine sooner than the control method.

However, the marked adhesions between the anastomotic site and omentum could not be avoided by the experimental anastomosis, while the adhesions for the control anastomosis is negligible. Although this omental adhesions for the experimental anastomosis appeared to be not clinically significant in our short-term observation, further studies related to long-term safety would be necessary.

In the single-layer gastrointestinal anastomosis of the dogs, IKEGAMI (1958) reported that the anastomotic site was protected by accretion of serous blood vessels, followed by minute blood vessels regenerated centering around the sutures, as well as minute blood vessels regenerated from the submucous blood vessels. On the other hand, KITAJIMA (1974) showed in the similar experiment that the vascular regeneration and communications occurred mainly in the submucous blood vessels. In our study, the newly formed blood vessels regenerated from the serous blood vessels was noted in the control method, while in the experimental method, this and a number of new vessels regenerated from the omental vessels, was noted.

The conclusion that can be drawn for this study is that for the small intestinal anastomosis of the dogs, the experimental method has more advantages over the standard two-layer anastomosis in terms of its technical simplicity, less time consuming, good conditions of the dogs after surgery, minimum narrowing of the intestinal lumen, and rapidness of repair.

#### REFERFNCS

- 1) ABRAMOWITZ, H. B. & BUTCHER, H. R. (1971): *Am. J. Surg.*, **121**, 52
- 2) BENNETT, R. R. & ZYDECK, F. A. (1970): *J. Am. vet. med. Ass.*, **157**, 2075
- 3) DAIDO, R., KANO, M., KIROTANI, K., NAKAMURA, M. & OHASHI, I. (1971): *Jap. J. Surg.*, **1**, 63 (in Japanese)
- 4) GETZEN, L. C. & HOLLOWAY, C. K. (1966): *Surgery Gynec. Obstet.*, **123**, 1219
- 5) GRICE, H. C. (1962): *Can. vet. J.*, **3**, 352
- 6) HOPCROFT, S. C. (1972): *Med. J. Aust.*, **1**, 118
- 7) IKEGAMI, K. (1958): *Nihon geka hōkan (Arch. jap. Chir.)*, **28**, 467 (in Japanese with English summary)

- 8) IRVIN, T. T., GOLIGHER, J. C. & JOHNSTON, D. (1973): *Br. J. Surg.*, **60**, 453
- 9) KITAJIMA, M. (1974): *Jap. J. Surg.*, **75**, 538 (in Japanese)
- 10) KOIKE, T., HAGIO, M., KUDO, T. & SAKAI, T. (1976): *Jap. J. vet. Res.*, **24**, 19
- 11) KOIKE, T., OTOMO, K., ABE, I. & SAKAI, T. (1976): *Ibid.*, **24**, 13
- 12) LEIGHTON, R. L. (1967): *Vet. Med. small Anim. Clin.*, **62**, 239
- 13) LETWIN, E. & WILLIAMS, H. T. G. (1967): *Can. J. Surg.*, **10**, 109
- 14) MCADAMS, A. J., MEIKLE, A. G. & TAYLOR, J. O. (1970): *Am. J. Surg.*, **120**, 546
- 15) ORR, N. W. M. (1969): *Br. J. Surg.*, **56**, 771
- 16) OTT, B. S., DOYLE, M. D. & GREENAWALD, K. A. (1968): *J. Am. vet. med. Ass.*, **153**, 1742
- 17) PARASAD, B., AHMED, S. & BHATT, G. A. (1972): *Ceylon vet. J.*, **20**, 773
- 18) SENN, N. (1888): *Ann. Surg.*, **7**, 264
- 19) TSIAMITAS, J. (1968): *A. Rep. vet. Coll. Univ. Thessaloniki* **9**, 649 [GAGATSI, N. (1968): *Chir. Vet.*, **5**(4), 165]

#### EXPLANATION OF PLATES

##### PLATE I    Technique for the experimental method using a decalcified bone tube

- Fig. 1    The decalcified bone tube with 4 pairs of silk sutures
- Fig. 2    Severing the intestine
- Fig. 3    The severed intestine
- Figs. 4 & 5    Fixing the decalcified bone tube to the proximal intestinal lumen by 4 pairs of silk sutures
- Figs. 6 & 7    Uniting the segments of intestine with interrupted stitches of silk; interrupted Czerny suture
- Fig. 8    The completed anastomosis

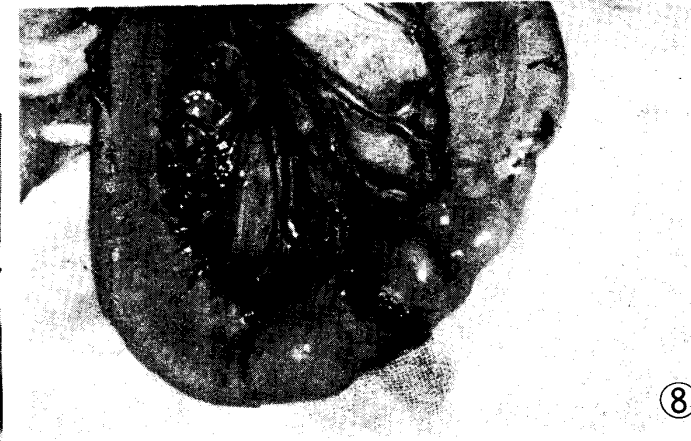
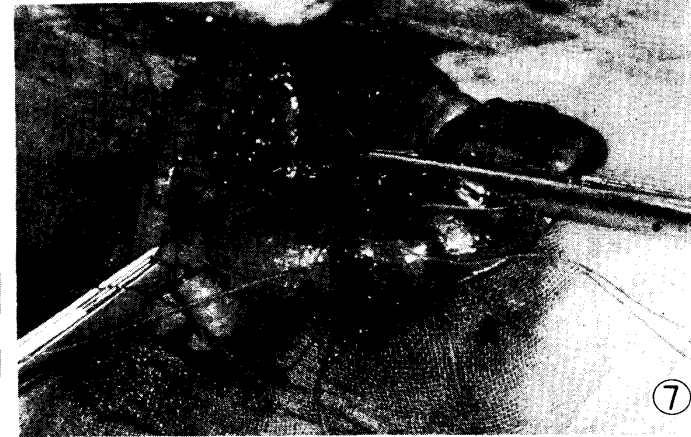
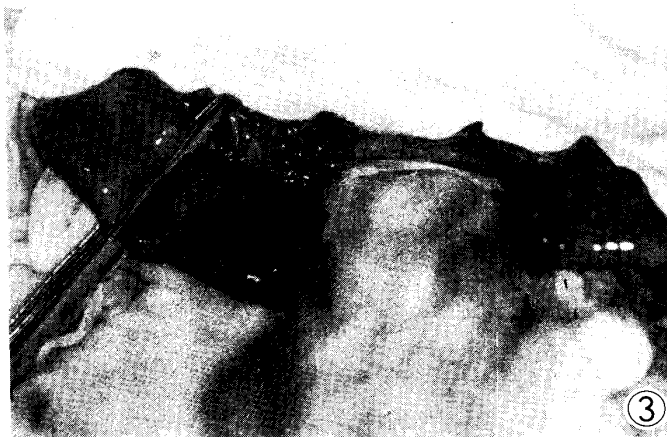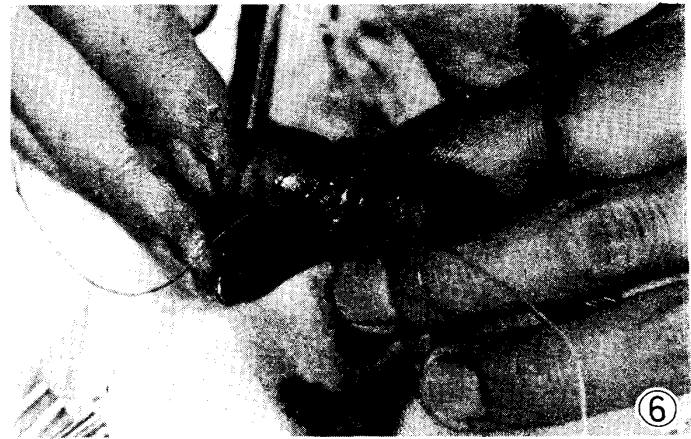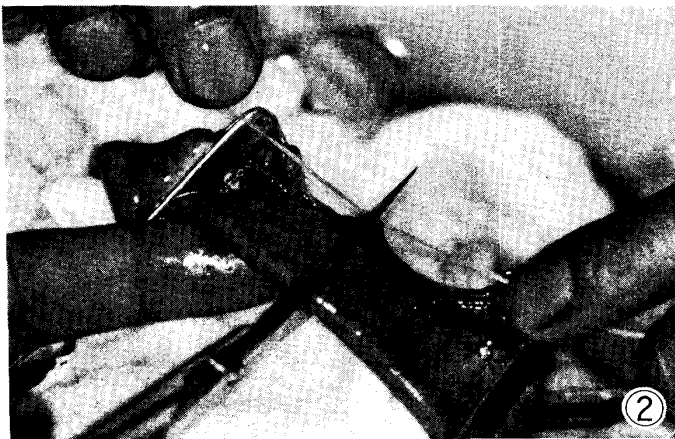
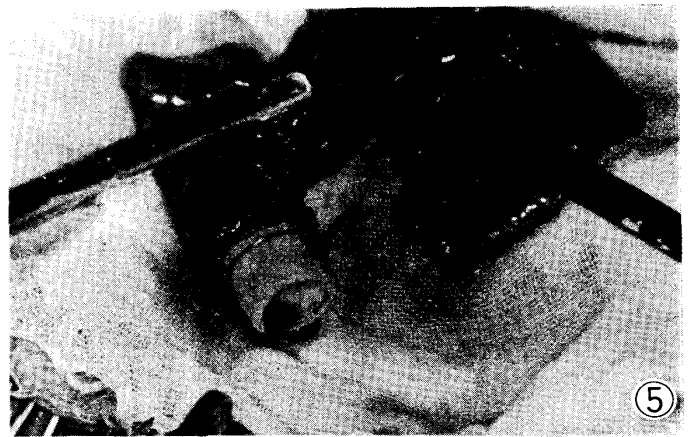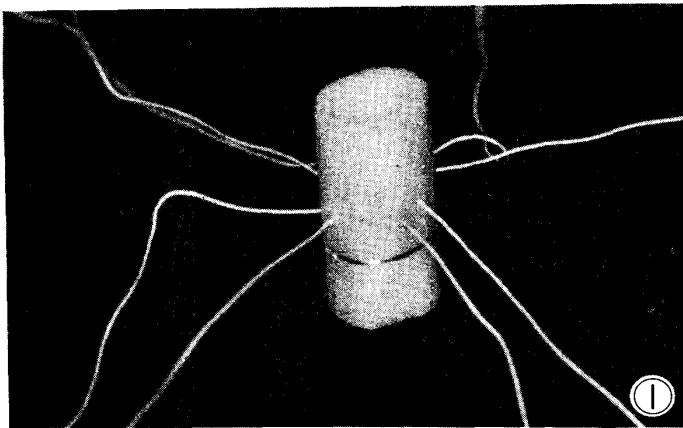


PLATE II

Fig. 9~12 Histological findings of anastomoses Hematoxylin and eosin  
×5

Fig. 9 Control method at 7 days after the operation

Fig. 10 Control method at 14 days

Fig. 11 Experimental method at 7 days

Fig. 12 Experimental method at 14 days

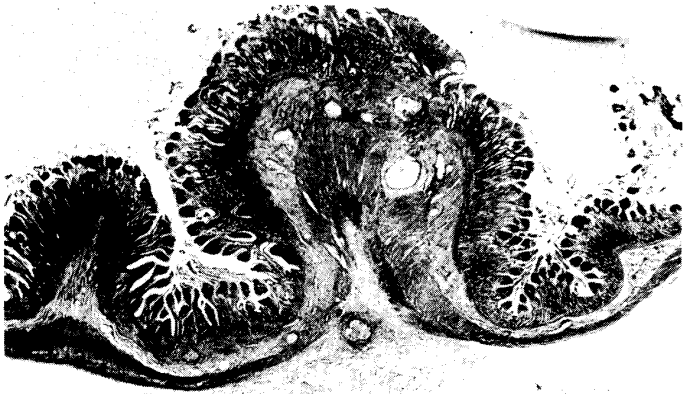
Fig. 13~16 Angiographic findings of anastomoses ×5

Fig. 13 Control method at 7 days

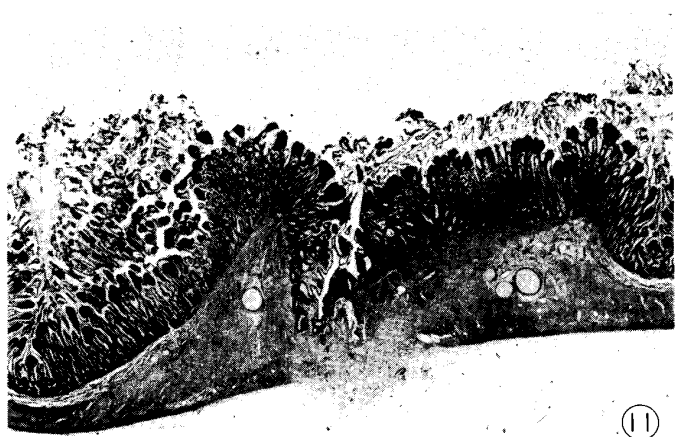
Fig. 14 Control method at 14 days

Fig. 15 Experimental method at 7 days


Fig. 16 Experimental method at 14 days



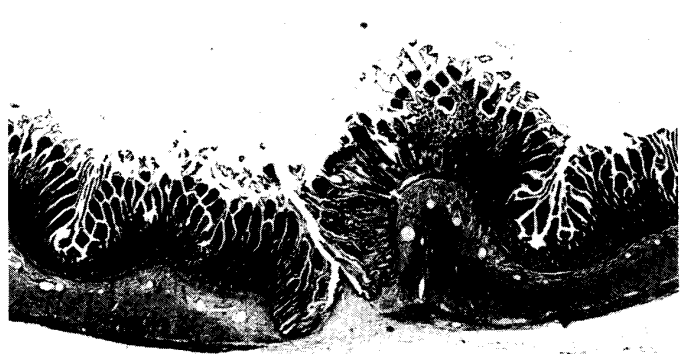9



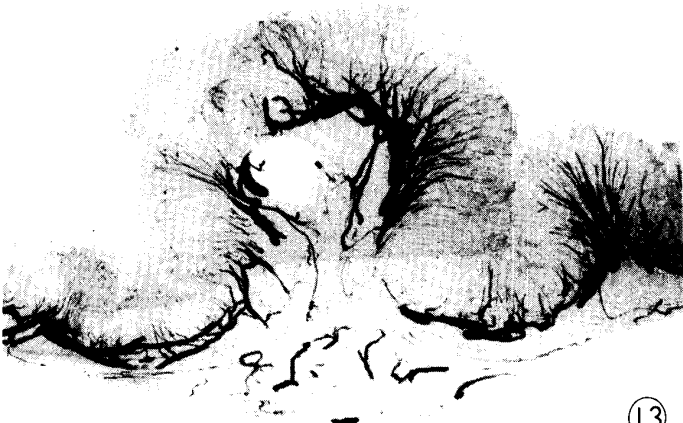11



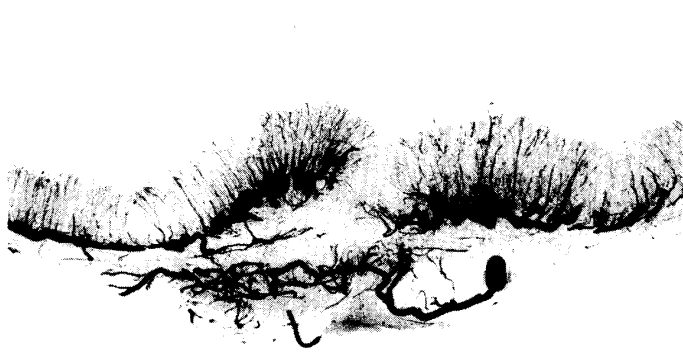10



12



13



15



14



16