



HOKKAIDO UNIVERSITY

Title	EFFECT OF CYCLOPHOSPHAMIDE ON THE THYMUS AND THE BURSA OF FABRICIUS IN CHICKENS
Author(s)	HIRAGA, Takeo; SUGIMURA, Makoto; KUDO, Norio
Citation	Japanese Journal of Veterinary Research, 24(3-4), 87-98
Issue Date	1976-10
DOI	https://doi.org/10.14943/jjvr.24.3-4.87
Doc URL	https://hdl.handle.net/2115/2084
Type	departmental bulletin paper
File Information	KJ00003407784.pdf



EFFECT OF CYCLOPHOSPHAMIDE ON THE THYMUS AND THE BURSA OF FABRICIUS IN CHICKENS

Takeo HIRAGA, Makoto SUGIMURA and Norio KUDO

*Department of Veterinary Anatomy
Faculty of Veterinary Medicine
Hokkaido University, Sapporo, Japan*

(Received for publication, May 31, 1976)

The effect of cyclophosphamide (Cy) on the thymus and the bursa of Fabricius in chickens, aged one day to 7 weeks, was examined morphologically. Chickens, which were daily injected i. m. with 6 mg Cy 1, 2, or 3 times from the hatching day, were compared with saline control chickens.

The relative weights of both the thymus and the bursa decreased abruptly just after the injection of Cy. The weight of the thymus had an involutinal bottom at the age of 4~5 days, and thereafter recovered to the normal level at age 3 weeks, while that of the bursa never returned to the control level until age 7 weeks.

The histological changes in the thymus appeared to be greater in the cortex than in the medulla. A degeneration of lymphocytes, an increase of macrophages, hypertrophy of the reticular cells, and a disappearance of mitotic cells were observed in the cortex during early involution. Recovery began as soon as the large lymphocytes appeared in the cortex, and the histological structures of the thymuses in the Cy-treated birds recovered completely at age 3 weeks. The effect of Cy in the bursa was similar to that in the thymus, but these changes were seen earlier than they were in the thymus. Restoration of the lymphoid follicles was observed from 5 to 10 days of age mainly in the groups treated with a smaller quantity of Cy. In the chickens treated with 18 mg Cy, however, only a few restorative follicles were found.

INTRODUCTION

Since LERMAN & WEIDANZ ('70) reported that chickens treated with the immunosuppressant, cyclophosphamide (Cy), failed to produce specific antibodies, many immunological investigations have been carried out using this drug for bursectomy in the chicken (GLICK, LINNA et al., ROUSE & SZENBERG, SORVARI et al., TOIVANEN et al.¹²⁻¹⁵), TOIVANEN & TOIVANEN) and in the duck (SUGIMURA et al., SUGIMURA & HASHIMOTO). According to these reports, it is clear that Cy selectively suppresses the bursa-dependent functions, destroys the normal bursal structures, momentarily involutes the thymus, and causes the absence of the

bursa-dependent tissues and cells in peripheral lymphoid organs, such as the spleen or the caecal tonsils. In most of these reports, however, the effect of Cy on the morphology of the lymphoid organs, including the bursa, was not so detailed.

The purpose of this study is: a) to clarify the weight and histological changes of the thymus and the bursa of Fabricius in Cy-treated chickens, especially at an early stage after Cy administration; and b) to show the differences between the cellular changes of the two organs from involution to recovery due to different Cy dosages or frequency of treatment.

MATERIALS AND METHODS

Two hundred two White Leghorn male chickens of the Babcock B-300 strain aged one day (hatching day) to 7 weeks were used in this study. All chickens were given stock diet from 3 days of age and water ad libitum in their usual environment.

They were divided into four groups. Three groups were injected i.m. with 6 mg cyclophosphamide (Endoxan; Shionogi, Japan) dissolved in 0.3 ml of distilled water only on the hatching day (group E6), during the first two days after hatching (group E12), and during the three days after hatching (group E18). The fourth group was the saline control (group C).

The chickens were examined at intervals of 4, 5, 7 and 10 days, and at intervals of 2, 3, 5 and 7 weeks. In order to observe the early stages after Cy-treatment, chickens in group E6 were sacrificed at 2, 6, 12, 24 and 48 hours after the first injection of Cy, and the birds in group E12 were examined 24 hours after the second injection.

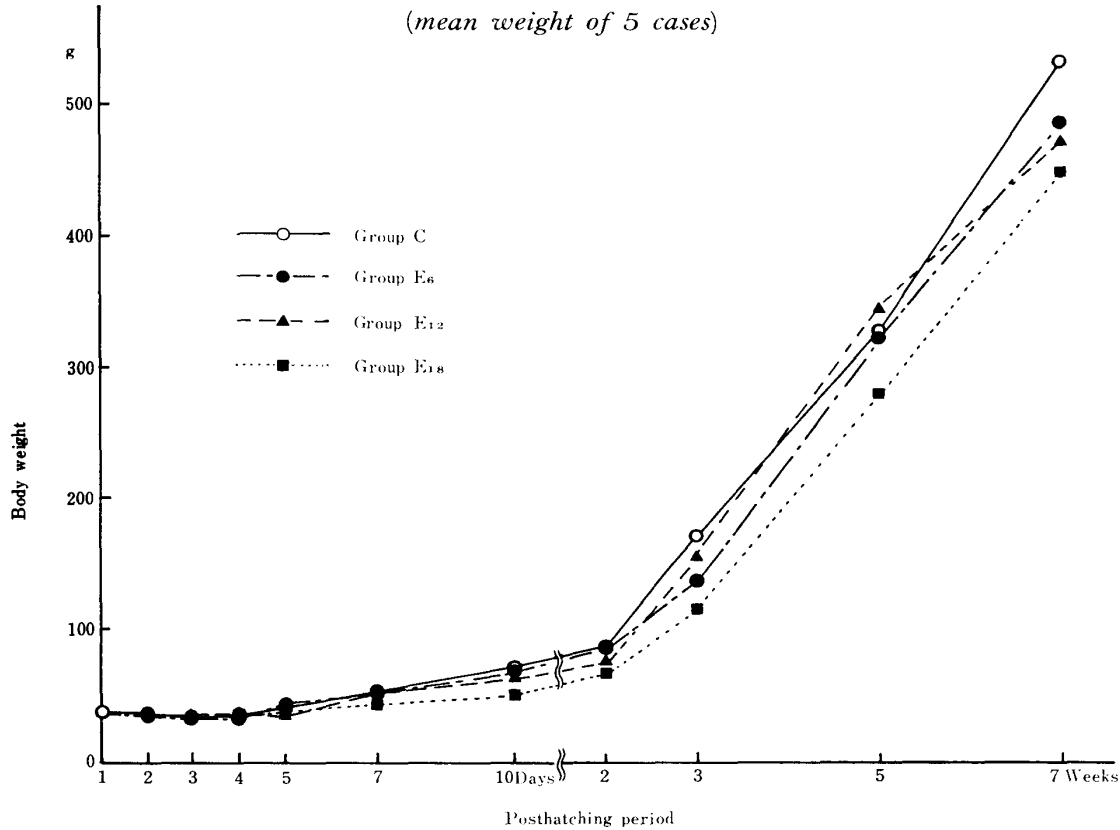
The thymus and the bursa were fixed in Carnoy's fluid for four hours. Following fixation, the specimens were weighed and embedded in paraffin. The sections were stained with hematoxylin-eosin, toluidine blue, Mallory's trichrome, PAS-hematoxylin and methylgreen-pyronine.

RESULTS

1 Body weight and weights of the thymus and the bursa of Fabricius

Body weights and weights of the thymus and the bursa of chickens aged one day to 7 weeks are shown in text-figures 1, 2 and 3. The body weights gradually increased from 5 days of age in the control group, while no increase of body weight was found in the Cy-treated groups, especially in group E18, from ages 7 days to 3 weeks. There was no difference, however, found between C and Cy-treated groups after age 5 weeks.

TEXT-FIGURE 1 *Body weight of four groups at each period*
(mean weight of 5 cases)



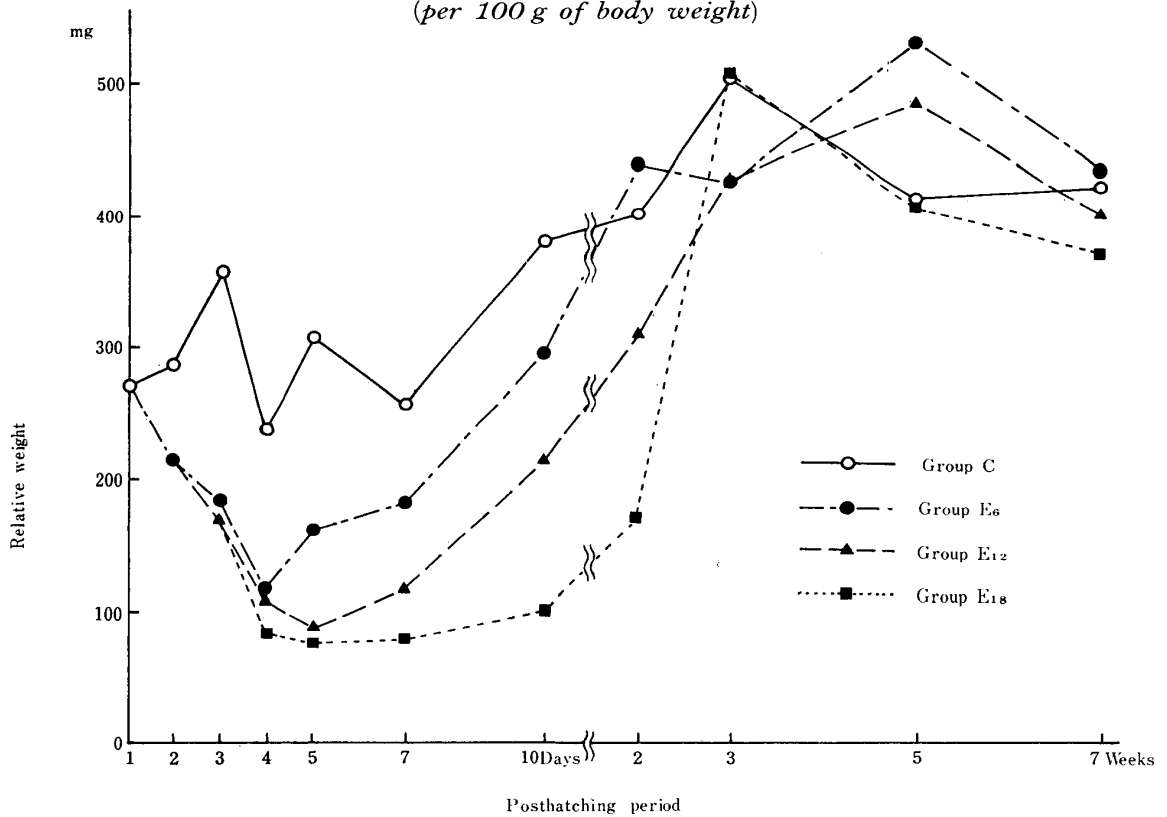
The relative thymic weight in Cy-treated groups decreased abruptly just after the first injection of Cy on the hatching day and showed its minimum weight at the age of 4 days in group E6 and at 5 days in groups E12 and E18. No difference among the groups, however, was found after age 3 weeks.

The relative weight of the bursa in all chickens treated with Cy significantly diminished in comparison with that of the control chickens from ages 3 days to 7 weeks. In group E6 and group E12, a slight recovery of the weight was found with considerable variation after age 5 weeks.

2 Histological changes in the thymus

The thymus of the control chickens consisted of the cortex and the medulla (fig. 1), it contained a lobular structure separated by connective tissues on the hatching day. The cellular elements in the cortex were mainly comprised of large and small lymphocytes and a small number of reticular cells and macrophages. The lymphocytes in the medulla, which had larger nuclei than those of the small ones in the cortex, were distinguished as medium lymphocytes (fig. 2). There were almost no changes found in these cellular components of

TEXT-FIGURE 2 *Thymic relative weight of four groups at each period*
(per 100 g of body weight)



the cortex and medulla in the group C thymus until age 7 weeks.

Histological changes in the thymus of Cy-treated birds occurred more predominantly in the cortex than in the medulla. A degeneration and diminution of lymphocytes and an increase of macrophages in the cortex were observed 12 hours after the first injection of Cy (fig. 3).

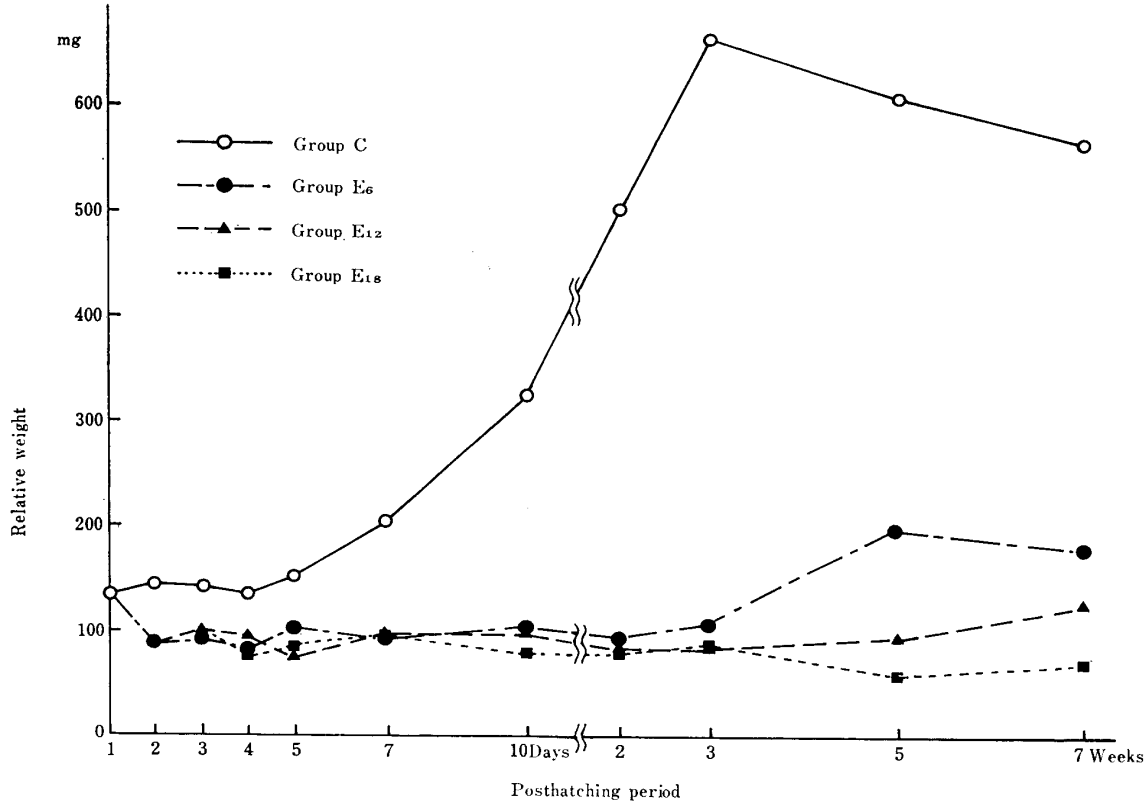
Because of these findings, thymic histological figures in each group from age one day to 7 weeks were divided into 8 types: one type of normal phase (type I); 4 types of involutinal phases (types II~V); and 3 types of regenerative phases (types VI~VIII), as shown below.

Type I: Normal structure shown in group C (figs. 1, 2 & 7)

Type II: Owing to the diminution of lymphocytes and hypertrophy of the reticular cells, the cortex showed a mosaic-like structure (fig. 8).

Type III: The small lymphocytes remained only as clusters. The large lymphocytes and their mitotic figures disappeared in the cortex and hypertrophy of the reticular cells were found (fig. 9).

Type IV: The clusters of small lymphocytes became smaller and were scattered only in the cortico-medullary junction. Hypertrophy of the reticular

TEXT-FIGURE 3 *Bursal relative weight of four groups at each period*

cells were strongly seen (fig. 10).

Type V: Almost all of the small lymphocytes in the cortex disappeared; thus, this type was recognized as an inverted type (fig. 11).

Type VI: The large lymphocytes developed particularly in the subcapsular region or around the remaining small lymphocytes in the cortico-medullary junction, and often showed mitotic figures (fig. 12).

Type VII: The large, medium, and small lymphocytes were intermingled in the cortex; consequently, the boundary between the cortex and the medulla became obscure (fig. 13).

Type VIII: The cortical layer, consisting of small lymphocytes, increased in thickness; however, there was a light zone, which mainly included the large lymphocytes and reticular cells in the subcapsular region (fig. 14).

The appearance of 8 types of thymus at each period in the four groups is shown in text-figure 4. It was found that the period of the involutinal bottom and the type found in this period differed among the three Cy-treated groups. The involutinal bottom was seen in 4 day-old chickens as type III in group E6, in 5 day-old ones as type IV in group E12, and in 7~10 day-old ones as type V in group E18, respectively. The histological structures of the thymuses

TEXT-FIGURE 4 *Histological changes in thymus*

I.P.	Posthatching period											R.P.
	1D	2D	3D	4D	5D	7D	10D	2W	3W	5W	7W	
I	☆☆☆☆	☆☆☆☆ ●●	☆☆☆☆	☆☆☆☆	☆☆☆☆	☆☆☆☆ ○	☆☆☆☆ △	☆☆☆☆ ○○ △△	☆☆☆☆ ○○○○ △△△△ □□□□	☆☆☆☆ ○○○○ △△△△ □□□□	☆☆☆☆ ○○○○ △△△△ □□□□	I
II		●●	●●●● ▲▲▲▲	●	○○	○○	○○○ △△	△△ □				VII
III			▲	●●●● ▲▲▲▲ ■ ■ ■ ■	○○ ■ ■	○ △△		△ □□				VII
IV				■	▲▲▲ ■ ■ ■	△ ■	△△ □□	□				VI
V						■ ■ ■ ■	■ ■					

☆ Group C
 ●○ Group E₆
 ▲△ Group E_{1,2}
 ■□ Group E_{1,8}

I.P. : Types of involutinal phases
 R.P. : Types of regenerative phases
 Black and white symbols show I.P. and R.P. respectively.

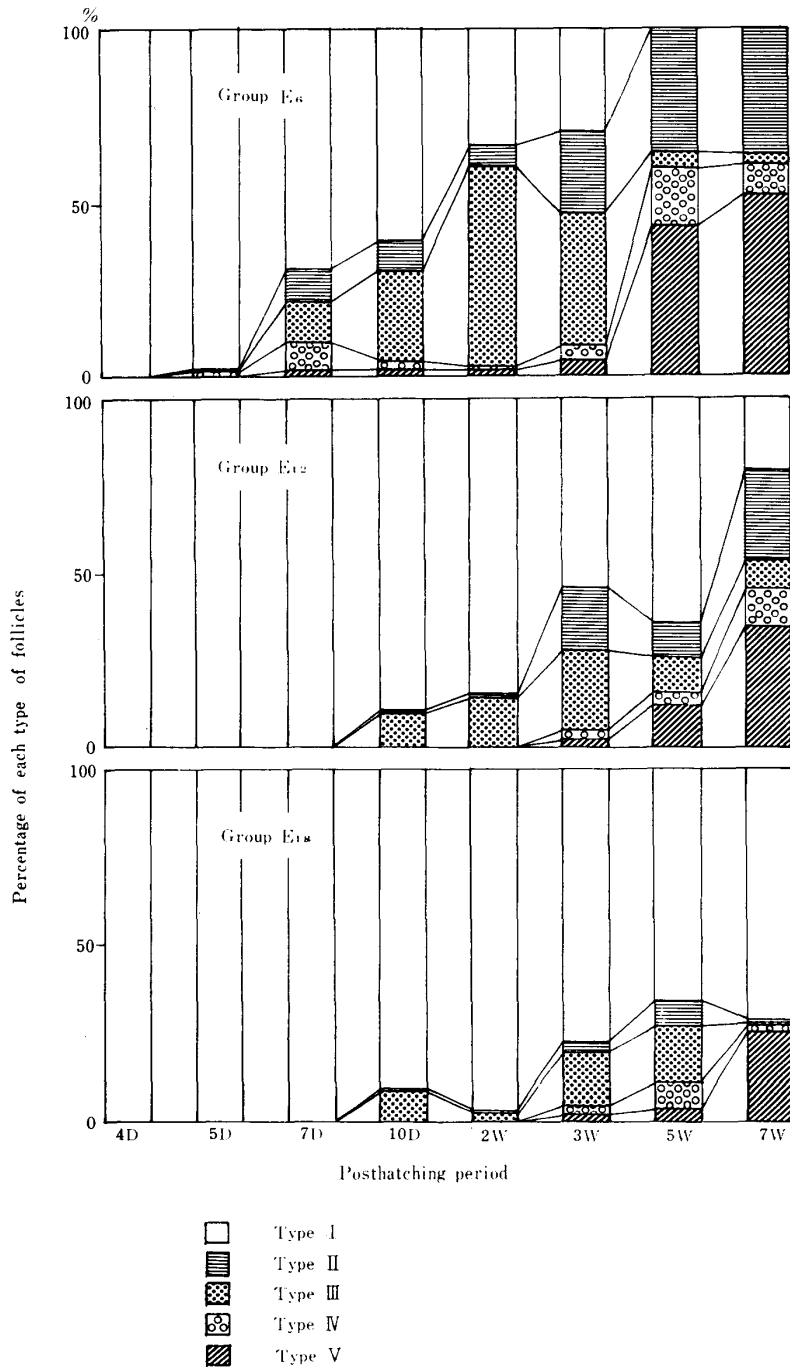
in the Cy-treated chickens completely recovered in all groups at 3 weeks of age.

3 Histological changes in the bursa of Fabricius

In the chickens of group C, the bursal follicles were filled with many lymphoid cells, large, medium, and small lymphocytes. Two kinds of epithelia, the interfollicular and follicle-associated epithelium, were already distinguished on the surface of the bursal cavity on the hatching day (fig. 4). Formation of the cortex in the follicles was not clear until the chickens in group C became 7 days of age.

Six hours after the first injection of Cy, a marked degeneration of lymphocytes and an increase of macrophages were found (fig. 5) and almost no lymphocytes existed in the follicles at 12 hours after Cy-treatment. A few large lymphocytes showing vesicular swelling, however, remained in the medulla (fig. 6). Thereafter, the lymphoid follicles in all Cy-treated groups were completely lacking in lymphocytes and consisted only of reticular cells until 4 days of age. The reticular cells did not appear to be affected by Cy. The lymphoid follicles of the Cy-treated groups began to recover with structural variations (fig. 15) after 5 to 10 days of age and could be divided into 5 types.

TEXT-FIGURE 5 Frequency of each type of bursal follicles



Type I: Almost no lymphoid cells were found in the follicles (fig. 16).

Type II: Many plasma cells were found in the medullary portion of the follicles and in the peripheral connective tissues (figs. 17 & 18).

Type III: Pyroninophilic lymphoid cells gathered around the follicles of type I, but there were almost no lymphoid cells in the medulla (fig. 19).

Type IV: Lymphoid cells appeared and proliferated in the medulla, which were partially surrounded by the cortex (fig. 20).

Type V: Normal structure of the bursal follicles, as shown in group C after 7 days (fig. 21)

The frequency of these 5 types of follicles at each period in the three Cy-treated groups is shown in text-figure 5. In groups E6 and E12, restoration of numerous lymphoid follicles started from age 5 to 10 days, and a few restorative ones in group E18 were also observed. In 5 chickens of group E18 at age 7 weeks, 2 bursae had only type I follicles. The tendency of change from type I, type III and type IV to type V is shown in this figure. On the other hand, type II, which included many plasma cells in the follicles, seemed to have no consistent tendency.

DISCUSSION

The effect of cyclophosphamide on the thymus and the bursa of Fabricius was studied morphologically in this report.

The morphology of the thymus in Cy-treated chickens has been described briefly^{2,5,7)}. In these reports, however, the thymic changes in weight and histology during involution to recovery were not discussed in detail. This study showed that the thymic weight decreased abruptly just after the first injection of Cy on the hatching day and had an involutinal bottom at the age of 4~5 days. The weight was recovered in the three Cy-treated groups at 3 weeks of age. The histological changes were timely similar to the weight changes. A degeneration of lymphocytes, an increase of macrophages, hypertrophy of the reticular cells, and a disappearance of mitotic cells in the cortex took place, the findings of which are similar to those described in ITO & HOSHINO's report on the treatment of hydrocortisone in mice. These changes were observed during early involution (as early as 12 hours after the first injection of Cy). Almost no changes in the medulla, including the medium lymphocytes, were found. Recovery began as soon as the large lymphocytes appeared at the subcapsular region of the surviving cortex and the thymuses of Cy-treated birds showed normal structure at age 3 weeks.

The bursa of Fabricius is very sensitive to Cy, as mentioned above; however, previous reports (GLICK, LINNA et al., ROUSE & SZENBERG, SORVARI et al.,

SUGIMURA et al., SUGIMURA & HASHIMOTO, TOIVANEN et al.^{12,13)}, have not adequately covered the weight and histological changes caused by Cy in the early stage after Cy-treatment. Unlike the thymic weight changes, the bursal weight in Cy-treated groups did not reach the weight of group C even in the 7 weeks after hatching. In the histological observation of the present study, an almost complete disappearance of lymphocytes in the follicles was detected 12 hours after Cy-treatment. Recovery of histological figure in the bursal follicles was found mostly in groups E6 and E12.

In this study, 5 types of follicles (types I~V) were observed in the recovery phases of the bursa. The follicular recovery occurred possibly in the following steps: Step 1—a gathering of large or medium-sized pyroninophilic lymphoid cells around the involutinal follicles, probably from an organ other than the bursa; Step 2—appearance and proliferation of these cells in the medullary portion with partial development of the cortex; and Step 3—normal structure of the bursal follicles. The follicles of type II, including many plasma cells, were also found during the regenerative process. This type of follicles showed no tendency to recover to the normal follicles and they also included many plasma cells in the peripheral connective tissue. These follicles appear to be peculiar ones caused by changes of the bursal microenvironment as suggested by LERMAN & WEIDANZ and ROUSE & SZENBERG.

An increase of plasma cells after Cy-treatment has been observed in the spleen and the bursa of the duck¹⁰⁾. Further investigation is needed to confirm the theory that the presence of the plasma cells is dependent upon the bursa of Fabricius. LINNA et al. reported that the peripherized bursa-derived cells before hatching were destroyed by Cy-treatment, therefore, these lymphoid cells restoring the bursal follicles are seemingly derived from blood-borne progenitor cells, as mentioned by MOORE & OWEN. In this observation of thymic regeneration, it is very interesting that these lymphoid cells appeared in the bursa at the same age as did the large lymphocytes in the cortex of the thymus. Using chickens treated with hydrocortisone, FUKUDA suggested the possibility that the lymphocytes, which infiltrate the bursal connective tissue, especially around the vessels, are derived from the medullary lymphocytes in the thymus.

TOIVANEN et al.^{12,15)} pointed out the differences in sensitivity to Cy action according to strains of chickens. Two treatments of 2.5 mg Cy immediately after hatching caused an almost complete bursectomy in ducks^{9,10)}. These and the present findings indicate that there are differences in sensitivity to Cy treatment among various species, strains and individuals; thus, it is very difficult to determine the Cy dosage or frequency of treatment which cause complete bursectomy. This experiment showed that when chickens were treated

with high dosages and frequent treatments of Cy, strong involution occurred and there was a feeble recovery in the bursa. In 5 chickens of group E18 at age 7 weeks, 2 bursae showed no regenerative follicle; therefore, it may be said that they undergo a complete bursectomy, as reported by GLICK, who found that the histology of the bursa indicates the development of antibody-mediated immunity in Cy-treated chickens.

Differences in sensitivity to Cy action were also observed among the lymphocytes, depending upon their size and location. Cy-sensitive lymphocytes were the small and medium ones found in the bursal follicles and the small ones found in the cortex of the thymus, while Cy-resistant lymphocytes were the small ones found in the cortico-medullary junction and the medium ones found in the medulla of the thymus. It is thought that the differences among these lymphocytes may be related to their functional role or degree of maturation.

REFERENCES

- 1) FUKUDA, K. (1971): *Acta anat. nippon.* **46**, 159 (in Japanese with English summary)
- 2) GLICK, B. (1971): *Transplantation*, **11**, 433
- 3) ITO, T. & HOSHINO, T. (1962): *Z. Zellforsch. mikrosk. Anat.*, **56**, 445
- 4) LERMAN, S. P. & WEIDANZ, W. P. (1970): *J. Immun.*, **105**, 614
- 5) LINNA, T. J., FROMMEL, D. & GOOD, R. A. (1972): *Int. Archs Allergy appl. Immun.*, **24**, 296
- 6) MOORE, M. A. S. & OWEN, J. J. T. (1966): *Devl Biol.*, **14**, 40
- 7) ROUSE, B. T. & SZENBERG, A. (1974): *Aust. J. exp. Biol. Med. Sci.*, **52**, 873
- 8) SORVARI, T., TOIVANEN, A. & TOIVANEN, P. (1974): *Transplantation*, **17**, 584
- 9) SUGIMURA, M., HASHIMOTO, Y. & YAMADA, J. (1974): *Igaku no Ayumi*, **91**, 335 (in Japanese)
- 10) SUGIMURA, M. & HASHIMOTO, Y. (1976): *J. Reticuloendothel. Soc.*, **19**, 201
- 11) TOIVANEN, P. & TOIVANEN, A. (1973): *Eur. J. Immun.*, **3**, 585
- 12) TOIVANEN, P., TOIVANEN, A. & GOOD, R. A. (1972): *J. Immun.*, **109**, 1058
- 13) TOIVANEN, P., TOIVANEN, A., LINNA, T. J. & GOOD, R. A. (1972): *Ibid*, **109**, 1071
- 14) TOIVANEN, P., TOIVANEN, A. & SORVARI, T. (1974): *Proc. natn. Acad. Sci. U.S.A.*, **71**, 957
- 15) TOIVANEN, P., TOIVANEN, A. & TAMMINEN, P. (1974): *Eur. J. Immun.*, **4**, 405

EXPLANATION OF PLATES

PLATE I

- Fig. 1 The thymus of a day-old control chicken consists of the cortex and the medulla. Hematoxylin-eosin × 240
- Fig. 2 High magnification of figure 1 at cortico-medullary junction
Note the lymphocytes in the medulla (lower) which have larger nuclei than those in the cortex (upper). × 470
- Fig. 3 The thymus of group E6 12 hours after the first injection of Cy
Degeneration of lymphocytes and an increase of macrophages in the cortex are observed. Hematoxylin-eosin × 280
- Fig. 4 The bursa of a day-old control chicken
The follicles are filled with many lymphoid cells, but the formation of the cortex is incomplete. PAS-hematoxylin × 280
- Fig. 5 The bursal follicles of group E6 6 hours after Cy-treatment on the hatching day
Degeneration of lymphocytes and numerous macrophages are seen in the follicles. Mallory's trichrome × 280
- Fig. 6 The bursal follicles of group E6 12 hours after Cy-treatment
Only a few large lymphocytes, which degenerate to show a vesicular swelling, remain in the follicles. Hematoxylin-eosin × 280

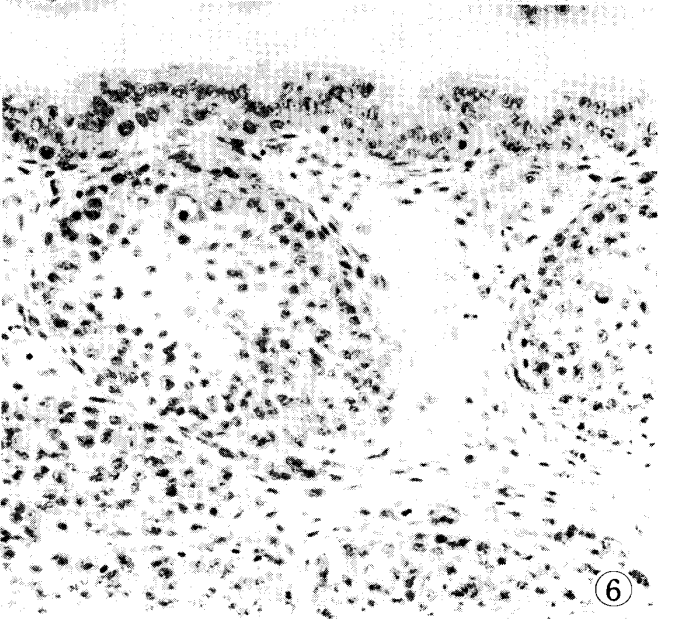
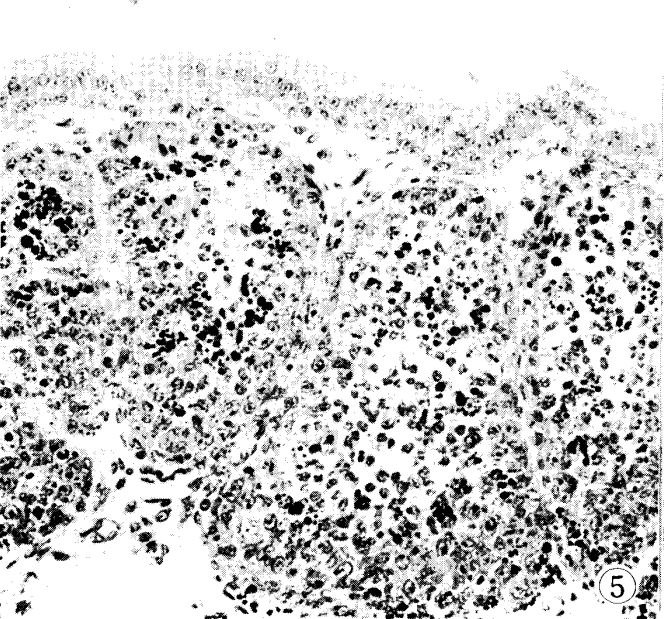
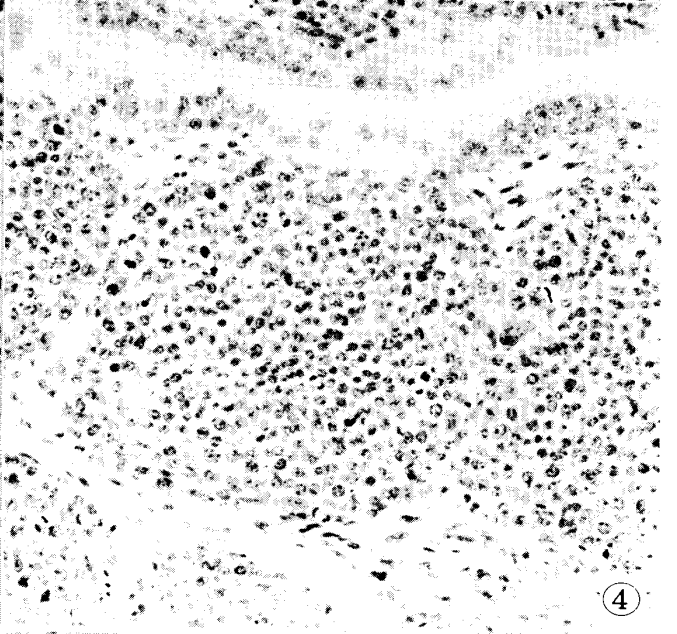
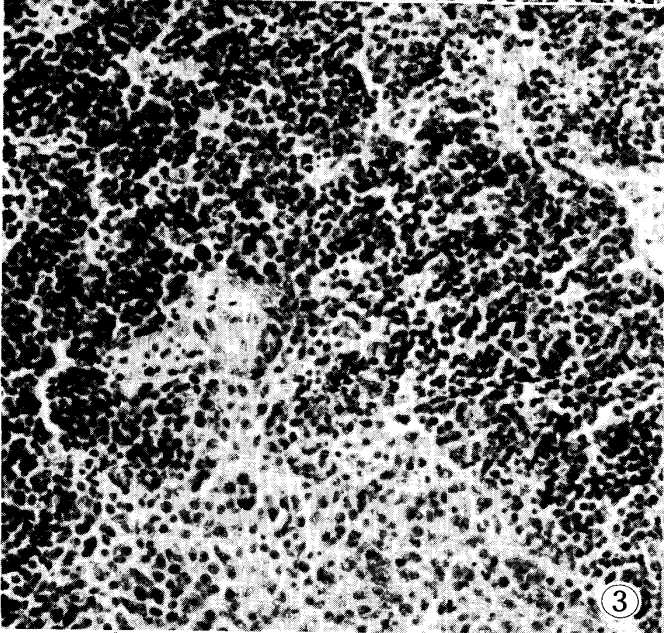
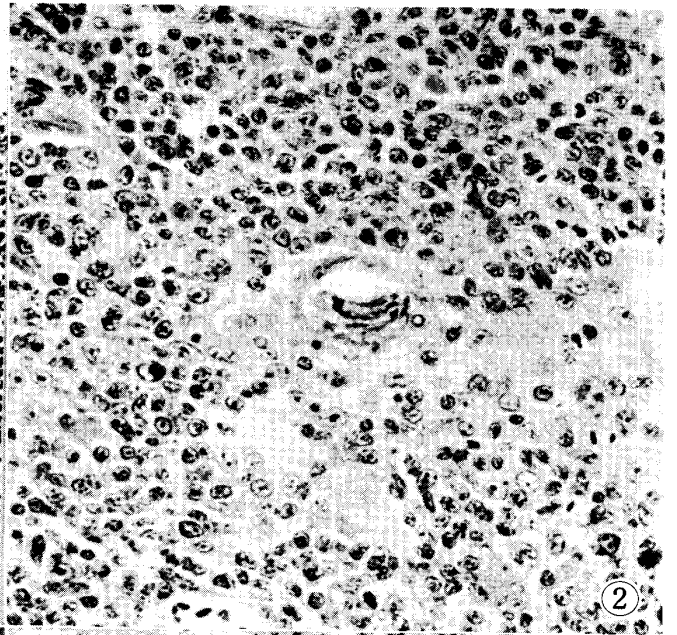
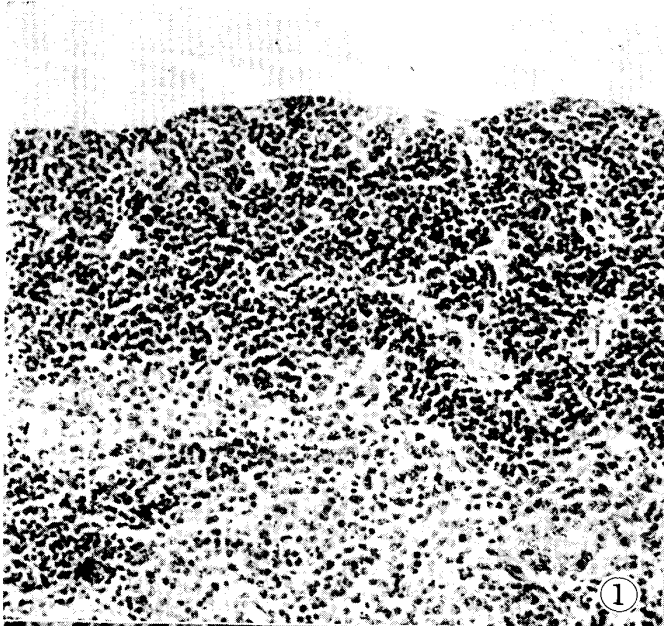

PLATE II

- Fig. 7 The thymus of type I on the hatching day of a control chicken
Numerous large and small lymphocytes and mitotic cells are
seen. Hematoxylin-eosin × 470
- Fig. 8 The thymus of type II in group E12 at 3 days of age
Note degeneration of lymphocytes and the increase of macro-
phages. Hematoxylin-eosin × 470
- Fig. 9 The thymus of type III in group E6 at 4 days of age
The small lymphocytes in the cortex remain as clusters.
Hematoxylin-eosin × 470
- Fig. 10 The thymus of type IV in group E12 at 5 days of age
A few small lymphocytes remain at the cortico-medullary
junction. Hematoxylin-eosin × 470
- Fig. 11 The thymus of type V in group E18 at 7 days of age
The medulla is darker than the cortex because of a denser
distribution of lymphocytes. Hematoxylin-eosin × 240
- Fig. 12 The thymus of type VI in group E12 at 10 days of age
A few large lymphocytes and their mitotic figures are seen in
the cortex. Hematoxylin-eosin × 470
- Fig. 13 The thymus of type VII in group E6 at 5 days of age
Various sizes of lymphocytes are intermingled in the cortex.
Hematoxylin-eosin × 470
- Fig. 14 The thymus of type VIII in group E6 at 10 days of age
The subcapsular light zone and the deep layer of the small
lymphocytes are distinguished.
Hematoxylin-eosin × 240


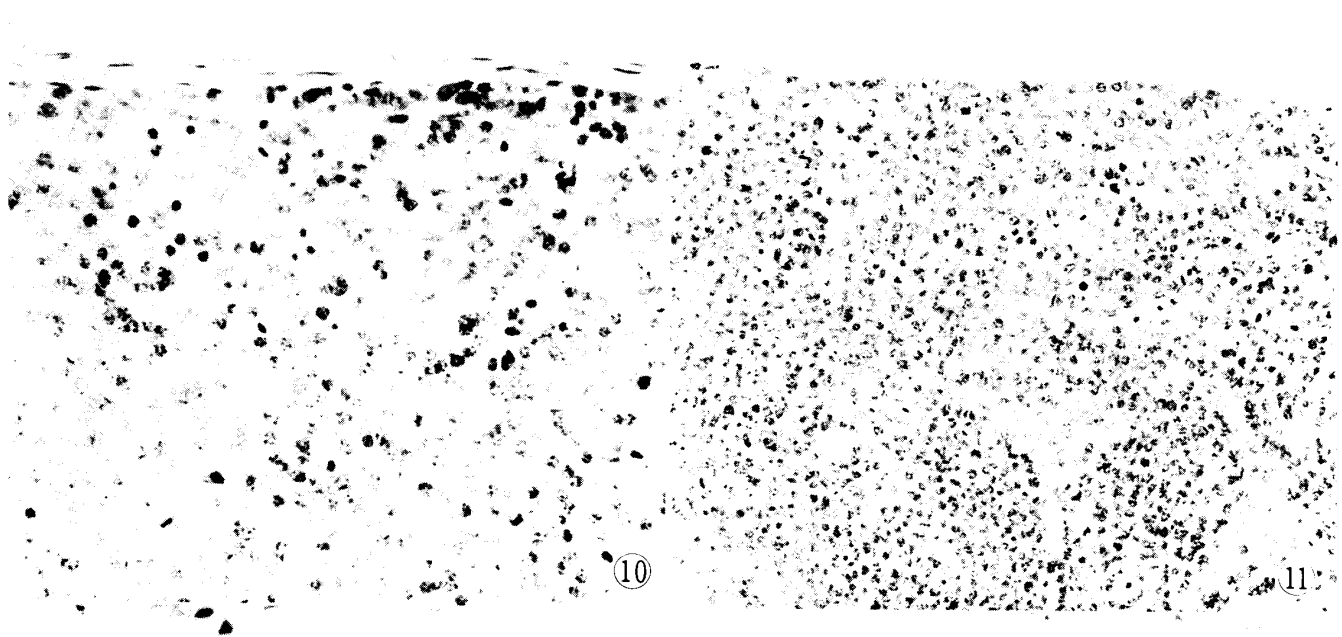


PLATE III

- Fig. 15 The bursa of a 5 week-old chicken in group E12
Various types of regenerative follicles are seen even in this magnification. PAS-hematoxylin × 50
- Fig. 16 The bursa of a 5 week-old chicken in group E12
These follicles lack lymphocytes and consist only of reticular cells; they are distinguished as type I follicles. A cluster of small lymphocytes is found around the vessels in the connective tissue. Hematoxylin-eosin × 120
- Fig. 17 The follicles of type II in group E6 at 5 weeks of age
Many plasma cells are seen in the follicles and in the peripheral connective tissue. Hematoxylin-eosin × 190
- Fig. 18 A part of figure 17
Plasma cells are clearly distinguished in this magnification. × 470
- Fig. 19 The follicles of type III in group E6 at 5 weeks of age
Large or medium-sized basophilic lymphoid cells gather around the follicles. Toluidine blue × 190
- Fig. 20 The follicles of type IV in group E6 at 5 weeks of age
Many lymphocytes and mitotic figures in the follicles are observed; the cortex is still only partially formed. PAS-hematoxylin × 160
- Fig. 21 High magnification of the follicles of type V in a week-old control chicken
The distinction between the cortex and the medulla is clearly seen. Mallory's trichrome × 310

