



# HOKKAIDO UNIVERSITY

Title	THYMUS- AND BURSA-DEPENDENT AREAS IN DUCK LYMPH NODES
Author(s)	SUGIMURA, Makoto; HASHIMOTO, Yoshiharu; NAKANISHI, Yuh H.
Citation	Japanese Journal of Veterinary Research, 25(1-2), 7-16
Issue Date	1977-04
DOI	<a href="https://doi.org/10.14943/jjvr.25.1-2.7">https://doi.org/10.14943/jjvr.25.1-2.7</a>
Doc URL	<a href="https://hdl.handle.net/2115/2101">https://hdl.handle.net/2115/2101</a>
Type	departmental bulletin paper
File Information	KJ00003407811.pdf



## THYMUS- AND BURSA-DEPENDENT AREAS IN DUCK LYMPH NODES\*<sup>1</sup>

Makoto SUGIMURA, Yoshiharu HASHIMOTO  
and Yuh H. NAKANISHI\*<sup>2</sup>

*Department of Veterinary Anatomy  
Faculty of Veterinary Medicine  
Hokkaido University, Sapporo 060, Japan*

(Received for publication, March 30, 1977)

The thymus (T)- and bursa (BF)-dependent areas of the duck lymph node were histologically examined by means of chemical bursectomy using cyclophosphamide-treatment, surgical thymectomy, and/or X-ray irradiation. The T-dependent area was represented by the deep area of lymphatic nodules comprised of small lymphocytes. The BF-dependent one was represented by lymphatic cords consisting of small and medium-sized lymphocytes, and possibly by germinal centers. On the other hand, the parasinusoidal area of lymphatic nodules and the existence of plasma cells seemed to be independent from both the thymus and the bursa of Fabricius. The relationship between avian and mammalian lymph nodes was discussed with special reference to T-, BF-, and bone marrow (BM)-dependent systems.

### INTRODUCTION

It has been reported that peripheral lymphoid organs, such as the spleen, have two distinct areas consisting of T- or BF-driven cells in the chicken (COOPER et al., '66; WARNER et al., '62). The duck has two pairs of true lymph nodes, namely the cervico-thoracal and the lumbar nodes (LINDNER, '61; MANABE, '30), but up until the present there has been no report concerning the T- and BF-dependent systems of nodal elements in avian lymph nodes. Mammalian lymph nodes, however, show a paracortical area which is T-dependent, while T-independent areas, such as the cortical area, the medullary cords, and the germinal centers, are believed to be BM-dependent (PARROTT & DE SOUSA, '71). In birds, it is well-known that the origin of B cells and their antibody-producing capability are controlled by the bursa of Fabricius, but in mammals the bursa-equivalent organ has not yet been found. In this paper, the T- and BF-dependent areas of duck lymph nodes, as well as the phylogenetic relationship between the avian BF- and the mammalian BM-systems of the lymph nodes, are discussed.

---

\*<sup>1</sup> This work was supported in part by grants (137003 and 176183) from the Ministry of Education, Science and Culture, Japan.

\*<sup>2</sup> Department of Experimental Radiobiology

## MATERIALS AND METHODS

Thirty-one White Pekin ducks were used as materials.

**Surgical thymectomy:** The thymuses were surgically removed from the dorsal side of the neck on hatching day.

**Chemical bursectomy:** The ducklings received daily i. m. injections of 2.5 mg cyclophosphamide (Endoxan: Shionogi & Co., Ltd., Osaka, Japan) during the first 2 days after hatching, as reported in previous papers (HASHIMOTO & SUGIMURA, '76; SUGIMURA et al., '74).

**X-ray irradiation:** The irradiation was done with 190 kVp, 25 mA, and the target distance was 40 cm without filtration at a dose rate of 342 R per minute. The 2 day-old ducklings (the next day after the surgical thymectomy) were packed in a carton and irradiated in air at a total dose of 650 R.

The six groups designated for this experiment were as follows: Untreated control duck (C); sham-operation of the neck on the day of hatching in combination with X-ray irradiation the next day (CX); surgical thymectomy on the day of hatching (Tx); surgical thymectomy on the day of hatching with X-ray irradiation the next day (Tx-X); bursectomy by cyclophosphamide-treatment (Bx); and surgical thymectomy on the day of hatching with bursectomy by cyclophosphamide-treatment (Tx-Bx).

The ducks were sacrificed at 7 weeks old. The body weight and the weights of the lymphoid organs were recorded. The cervico-thoracal and lumbar lymph nodes were fixed in 10% formalin and 3% glutaraldehyde or Carnoy's solution. The fixed organs were embedded in paraffin, sectioned to 5 to 7  $\mu$  in thickness, and stained with hematoxylin-eosin, PAS-hematoxylin, Mallory's trichrome, toluidine blue, pyronine-methyl green, and Gomori's silver impregnation for reticular fibers. Some of the nodes were doubly fixed with 3% glutaraldehyde and 1% osmic acid, and embedded in epoxy resin. Epon thick sections were stained with toluidine blue.

## RESULTS

## 1 Weights of lymphoid organs

The weight of the lymph nodes was impossible to measure because of their small size and the difficulty of separating them from neighboring tissues. To estimate the effect of the thymectomy and bursectomy, the relative weights of the thymus, bursa of Fabricius and spleen were reported, as shown in table 1.

The relative thymic weight was significantly heavier in group Bx than in group C. The bursal weight was significantly smaller in groups Bx and Tx-Bx than in other groups; the development of the bursa seemed to be greatly depressed by cyclophosphamide-treatment. The splenic weights of groups Tx-X and Tx-Bx were significantly

TABLE 1 *Weights of lymphoid organs (mg) per 100 g of body weight of ducks*

	C(6)	CX(4)	Tx(5)	Tx-X(6)	Bx(5)	Tx-Bx(5)
Thymus	373.0 ± 119.4	481.5 ± 76.9			680.4 ± 128.9†	
Bursa	115.2 ± 15.4	103.5 ± 25.0	90.0 ± 41.0	107.7 ± 13.4	33.8 ± 4.4*	31.4 ± 5.0*
Spleen	105.3 ± 13.3	62.5 ± 39.4	96.0 ± 35.5	35.7 ± 5.6*	126.6 ± 53.6	33.8 ± 11.0*

( ): Number of ducks examined.

\* and †: Mean significantly decreases and increases from control mean, respectively ( $P < 0.05$ ).

less than in group C; the development of the spleen seemed to be affected by thymectomy and X-ray irradiation.

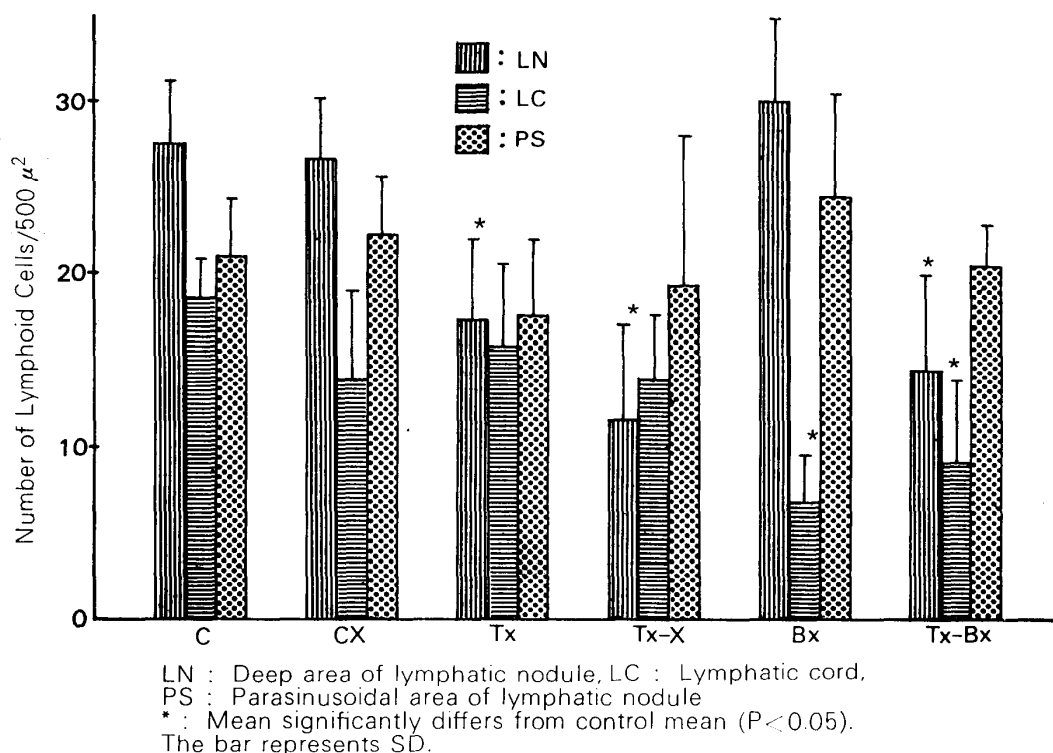
## 2 Histological changes of lymph nodes

In the control ducks, the lymph nodes consisted of a mass of lymphoid cells, the lymphatic sinus, and the supporting framework. The mass of lymphoid cells was distinguished into three elements: Lymphatic nodules packed mainly with small lymphocytes; lymphatic cords consisting of small and medium-sized lymphocytes; and germinal centers (figs. 1~4). Unlike mammalian lymph nodes, the lymphatic nodules were randomly distributed without showing an arrangement in the outer cortex and the inner medulla. Postcapillary venules were observed in the nodules. The lymphatic cords were connected to the periphery of the nodules, and germinal centers were found in the nodules. The lymphatic sinuses were divided into the intercordal and central sinuses (MANABE, '30). There was a reticular framework in the narrow intercordal sinus, while the wide central sinus occasionally showed valves but no reticular framework (fig. 2). The latter was an intranodal lymphatic vessel rather than sinus, which may be a primitive feature of the duck lymph node. No peripheral sinus was found in the duck node. The supporting framework was comprised of a capsule and a network of cords. Unlike the above-described lymphatic cords, the network consisted of collagenous and reticular tissues without lymphocytes; these were named "fibrous cords" in this paper (fig. 5). There were no trabeculae in the duck node. A few plasma cells were found in the lymphatic and fibrous cords (fig. 6). Mast cells were also found in the cords and the sinus (fig. 7).

The density of lymphocytes in different nodal elements decreased in variable degrees in the thymectomized and/or bursectomized group, as shown in text-figure 1.

In groups Tx, Tx-X and Tx-Bx, the lymphocytes of the large area of lymphatic nodules greatly decreased (figs. 9, 10 and 13), but those of the parasinusoidal area facing the central sinus did not decrease (fig. 13). In groups Bx and Tx-Bx, on the other hand, the lymphocytes of the lymphatic cords almost completely disappeared (figs. 11

TEXT-FIGURE 1

*Density of lymphoid cells in different areas of duck lymph nodes*TABLE 2 *Germinal centers, plasma cells and mast cells in duck lymph nodes*

	C	CX	Tx	Tx-X	Bx	Tx-Bx
Germinal centers <sup>a)</sup>	1/12	0/6	4/9	2/10	0/14	0/10
Plasma cells /80,000 $\mu^2$	12.3 $\pm$ 6.3	6.8 $\pm$ 3.5	13.6 $\pm$ 4.9	8.3 $\pm$ 3.3	15.4 $\pm$ 15.5	12.1 $\pm$ 11.9
Mast cells /80,000 $\mu^2$	11.3 $\pm$ 18.2	16.6 $\pm$ 15.0	4.7 $\pm$ 3.9	16.7 $\pm$ 9.0	6.9 $\pm$ 5.5	6.0 $\pm$ 4.1

a): Numeral shows the number of lymph nodes with germinal centers  
 /the number of lymph nodes observed.

to 13), but not in the other groups (fig. 8). The changes of the germinal centers, plasma cells, and mast cells are shown in table 2.

The germinal centers were found in some nodes of groups, C, Tx and Tx-X (figs. 1 and 8), but not in groups CX, Bx and Tx-Bx. No difference in the number of plasma cells and mast cells was found among the six groups; however the number of mast cells seemed to increase in groups CX and Tx-X.

## DISCUSSION

The thymectomy and bursectomy clearly demonstrated that peripheral lymphoid organs, such as the spleen and caecal tonsil, are comprised of two morphologically and functionally distinct cell systems, called T- and BF-dependent areas, in the chicken (COOPER et al., '66; HOSHI, '72; ISAKOVIĆ & JANKOVIĆ, '64; JANKOVIĆ & ISAKOVIĆ, '64; SORVARI & TOIVANEN, '76 and WARNER et al., '62) and in the duck (SUGIMURA & HASHIMOTO<sup>29</sup>, '76).

At present, however, there have been no reports on the T- and BF-dependent systems of avian lymph nodes. The present experiment on duck lymph nodes showed that the T-dependent area was represented by a deep area of lymphatic nodules, and that the BF-dependent one showed lymphatic cords, and possibly germinal centers. On the other hand, the development of the parasinusoidal area of the lymphatic nodules, as well as the existence of plasma cells, seemed to be independent from both central lymphoid organs.

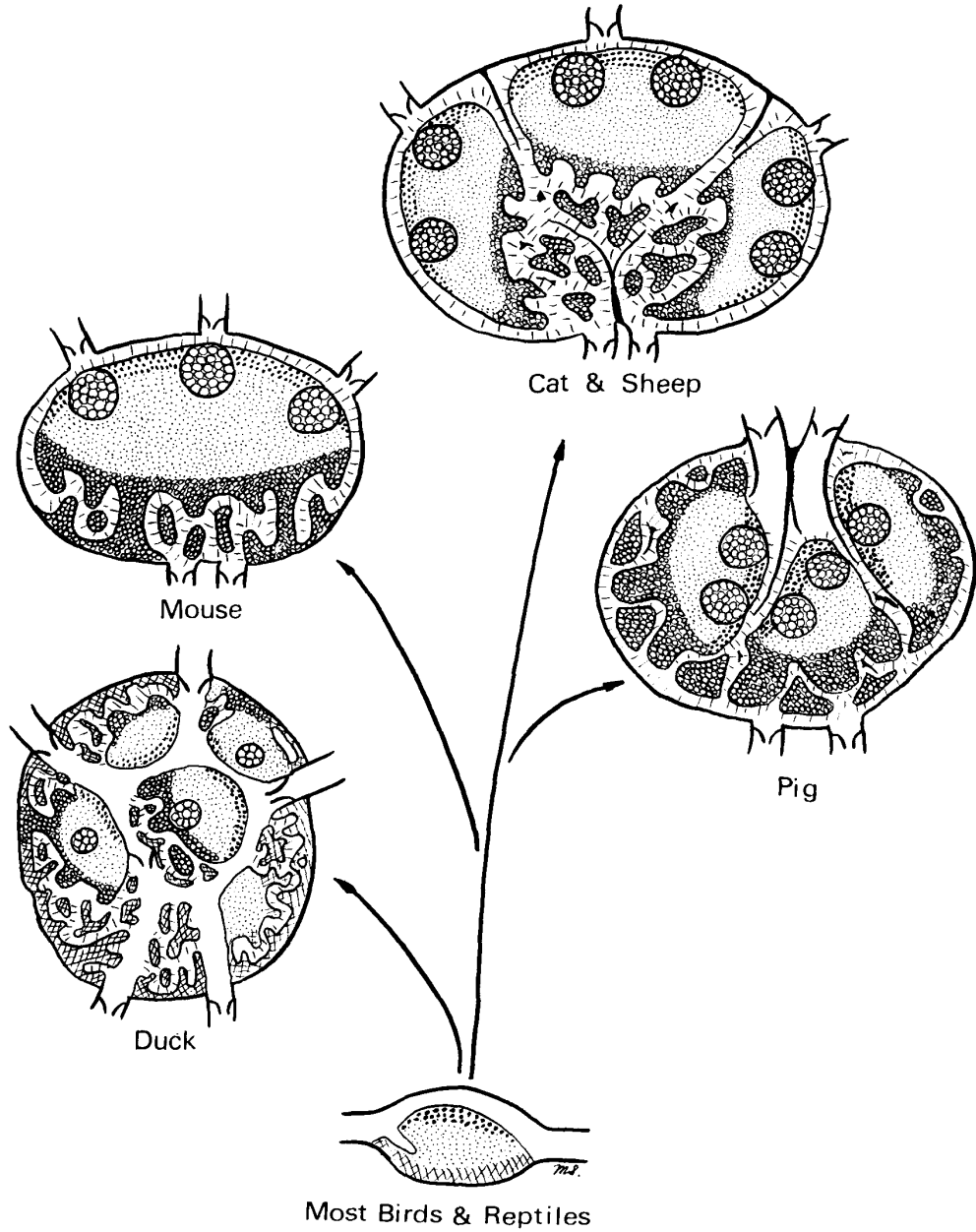
The results of current investigations in rodent lymph nodes revealed that the T- and BM-driven lymphocytes occupied the paracortex (mid and deep cortex) and the cortical area (perifollicular area or primary follicle), respectively, based on findings by thymectomy (PARROTT et al., '66; PARROTT & DE SOUSA, '71 and WAKSMAN et al., '62), immunofluorescence (GOLDSCHNEIDER & MCGREGOR, '73 and GUTMAN & WEISSMAN, '72), cell traffic (GOLDSCHNEIDER & MCGREGOR, '68; HOWARD et al., '72 and NIEUWENHUIS & FORD, '76) and by using nude, thymusless mice (MUENTNER et al., '75). The germinal centers and the medullary cords are generally believed to be BM-dependent (PARROTT & DE SOUSA, '71). Recently, however, it was reported that the thymus or T cells participated in the formation of germinal centers (JACOBSON et al., '74 and GUTMAN & WEISSMAN, '72).

Although duck lymph nodes have some primitive structures as compared to mammalian ones, the suggested homology of the nodal elements in the duck and the rodent are as follows: The deep area of lymphatic nodules (T-dependent) corresponds to the paracortex (T-dependent); the parasinusoidal area of lymphatic nodules (T- and BF-independent) corresponds to the cortical or perifollicular areas (BM-dependent), and the lymphatic cords (BF-dependent) correspond to the medullary cords (BM-dependent?), respectively. The origin of the germinal center is in dispute, but T, BF and/or BM cells seem to participate in its development in mammals (GUTMAN & WEISSMAN, '72; JACOBSON et al., '74; KOTANI et al., '74; MUENTNER et al., '75 and PARROTT & DE SOUSA, '71) as well as in chickens (HOSHI & MORI, '73).

A central lymphoid organ for B cells is the bursa of Fabricius in the bird, but the bursa-equivalent organ is unknown in mammals. If a phylogenetic line is drawn between avian and mammalian lymph nodes, it is reasonable to suggest that there are

TEXT-FIGURE 2

PHYLOGENY OF LYMPH NODE



- : Thymus-dependent area
  - : Bursa (equivalent organ)-dependent area
  - : Thymus- and bursa-independent area (Bone marrow dependent area?)
- : Bursa (equivalent organ)-dependent area?
  - : Collagenous stroma

three systems of lymphoid cells: 1) the thymus, 2) the bursa or bursa-equivalent, and 3) the bone marrow or its equivalent systems. With reference to the histology of lymph nodes in mice (HWANG et al., '68), cats (SUGIMURA, '62), and pigs (HUNT, '68 and MCFARLIN & BINNS, '73), the phylogeny of the lymph nodes having T-, BF- and BM-dependent elements is shown in text-figure 2.

The existence of the T- and BF-independent lymphocytes is also seen in the peri-venous lymphoid tissue of the thymectomized and bursectomized duck spleen (SUGIMURA & HASHIMOTO<sup>28</sup>, '76). This implies the existence of a third population of lymphocytes other than T and BF cells; however further studies are needed to clarify whether or not the avian T- and BF-independent system is equivalent to the mammalian BM-dependent system.

It has been firmly believed that plasma cells show bursa-dependency in the chicken (GLICK, '71; LERMAN & WEIDANZ, '70; LINNA et al., '72 and SORVARI & TOIVANEN, '76); nevertheless, it is an interesting fact that there was no decrease of plasma cells in the lymph nodes nor in the spleens of bursectomized ducks (SUGIMURA & HASHIMOTO<sup>29</sup>, '76), in which antibody-producing capability to *Salmonella pullorum* was severely eliminated (HASHIMOTO & SUGIMURA, '76). This finding shows that the plasma cells may not originate from the bursa. This difference between the duck and the chicken suggests that cyclophosphamide-treatment may be more severe for elimination of the precursor of plasma cells in the chicken than in the duck.

#### REFERENCES

- 1) COOPER, M. D., PETERSON, R. D. A., SOUTH, M. A. & GOOD, R. A. (1966): *J. exp. Med.*, **123**, 75
- 2) GLICK, B. (1971): *Transplantation*, **11**, 433
- 3) GOLDSCHNEIDER, I. & MCGREGOR, D. D. (1968): *J. exp. Med.*, **127**, 155
- 4) GOLDSCHNEIDER, I. & MCGREGOR, D. D. (1973): *Ibid.*, **138**, 1443
- 5) GUTMAN, G. A. & WEISSMAN, I. L. (1972): *Immunology*, **23**, 465
- 6) HASHIMOTO, Y. & SUGIMURA, M. (1976): *Poult. Sci.*, **55**, 1441
- 7) HOSHI, H. (1972): *Tohoku J. exp. Med.*, **106**, 285
- 8) HOSHI, H. & MORI, T. (1973): *Ibid.*, **109**, 97
- 9) HOWARD, J. C., HUNT, S. V. & GOWANS, J. L. (1972): *J. exp. Med.*, **135**, 200
- 10) HUNT, A. C. (1968): *Br. J. exp. Path.*, **49**, 338
- 11) HWANG, J. C., SUGIMURA, M., OHTAISHI, Y. & KUDO, N. (1968): *Jap. J. vet. Res.*, **16**, 49
- 12) ISAKOVIĆ, K. & JANKOVIĆ, B. D. (1964): *Int. Archs Allergy appl. Immun.*, **24**, 296
- 13) JANKOVIĆ, B. D. & ISAKOVIĆ, K. (1964): *Ibid.*, **24**, 278
- 14) JACOBSON, E. B., CAPORALE, L. H. & THORBECKE, G. J. (1974): *Cell. Immun.*, **13**, 416
- 15) KOTANI, M., NAWA, Y., FUJII, H., FUKUMOTO, T., MIYAMOTO, M. & YAMA-

- SHITA, A. (1974): *Acta anat.*, **90**, 585
- 16) LERMAN, S. P. & WEIDANZ, W. P. (1970): *J. Immun.*, **105**, 614
- 17) LINDNER, D. (1961): *Wiss. Z. Humboldt-Univ. Berlin*, **10**, 181
- 18) LINNA, T. J., FROMMEL, D. & GOOD, R. A. (1972): *Int. Archs Allergy appl. Immun.*, **42**, 20
- 19) MANABE, S. (1930): *Acta anat. nippon.*, **3**, 282 (in Japanese)
- 20) MCFARLIN, D. E. & BINNS, R. M. (1973): "Lymph node function and lymphocyte circulation in the pig" Microenvironmental aspects of immunity, Ed. JANKOVIĆ, B. D. & ISAKOVIĆ, K. *Adv. exp. Med. Biol.*, **29**, 87
- 21) MUENTNER, M., GROSCHRTH, P. & KISTLER, G. (1975): *Beitr. Path.*, **155**, 56
- 22) NIEUWENHUIS, P. & FORD, W. L. (1976): *Cell. Immun.*, **23**, 254
- 23) PARROTT, D. M. V. & DE SOUSA, M. (1971): *Clin. exp. Immun.*, **8**, 663
- 24) PARROTT, D. M. V., DE SOUSA, M. & EAST, J. (1966): *J. exp. Med.*, **123**, 191
- 25) SORVARI, T. E. & TOIVANEN, A. (1976): *Scand. J. Immun.*, **5**, 317
- 26) SUGIMURA, M. (1962): *Jap. J. vet. Res.*, **10**, 155
- 27) SUGIMURA, M., HASHIMOTO, Y. & YAMADA, J. (1974): *Igaku no Ayumi*, **91**, 335 (in Japanese)
- 28) SUGIMURA, M. & HASHIMOTO, Y. (1976): *Acta anat. nippon.*, **51**, 320 (in Japanese)
- 29) SUGIMURA, M. & HASHIMOTO, Y. (1976): *J. reticuloendothel. Soc.*, **19**, 201
- 30) WAKSMAN, B. H., ARNASON, B. G. & JANKOVIĆ, B. D. (1962): *J. exp. Med.*, **116**, 187
- 31) WARNER, N. L., SZENBERG, A. & BURNET, F. M. (1962): *Aust. J. exp. Biol. med. Sci.*, **40**, 373

## EXPLANATION OF PLATES

Abbreviation of figures :

AL-Afferent lymphatic vessel, CS-Central sinus, DA-Deep area of lymphatic nodule, FC-Fibrous cord, GC-Germinal center, LC-Lymphatic cord, LN-Lymphatic nodule, PCV-Postcapillary venule, PS-Parasinusoidal area of lymphatic nodule

### PLATE I

- Fig. 1 Low magnification of duck lymph node Each element of duck lymph nodes is clearly distinguished. Note random distribution of the nodules.  
Control lumbar node PAS-hematoxylin × 5
- Fig. 2 Central sinus occasionally has valves.  
Control cervico-thoracal node Hematoxylin-eosin (H-E) × 125
- Fig. 3 Lymphatic nodule comprised mainly of small lymphocytes Note postcapillary venule (arrow).  
Control lumbar node H-E × 500
- Fig. 4 Lymphatic cord consists of small and medium-sized lymphocytes. A part of the germinal center is also found.  
Control lumbar node H-E × 500
- Fig. 5 Fibrous cord is a network of connective tissue stroma without lymphocytes. Control lumbar node H-E × 500
- Fig. 6 A small number of plasma cells are found in the capsule and fibrous cords.  
Control lumbar node Pyronine-methyl green × 500
- Fig. 7 Note a mast cell (arrow) in the fibrous cord. Epon thick section of control lumbar node Toluidine blue × 800

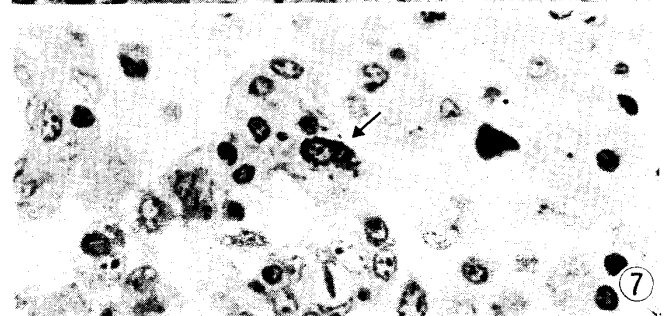
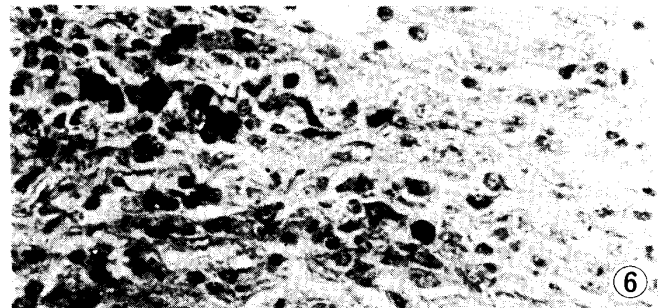
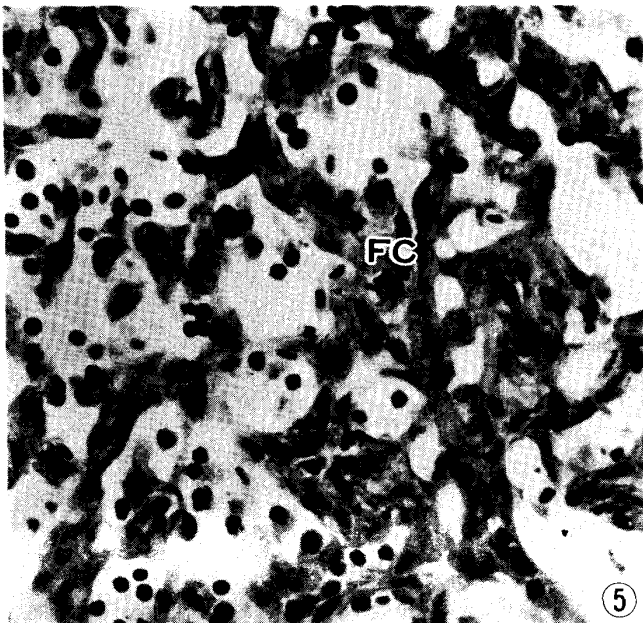
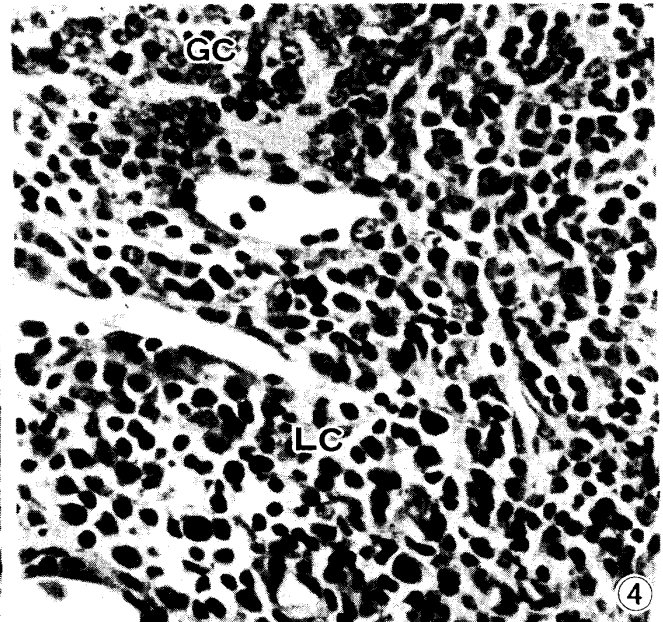
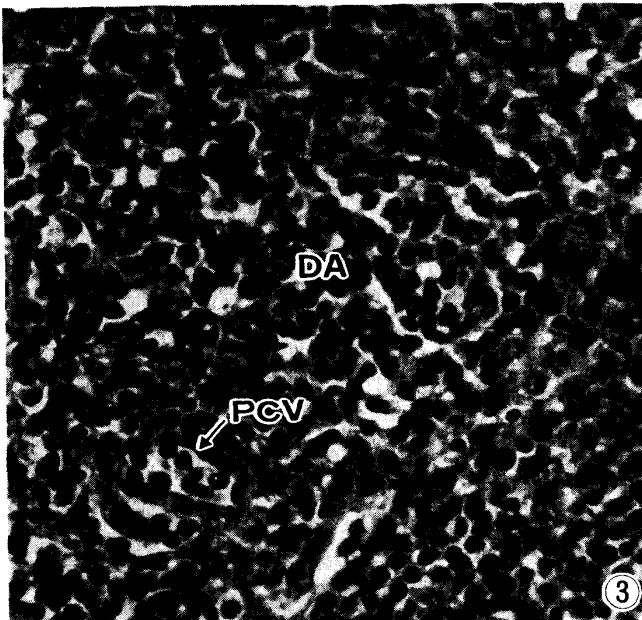
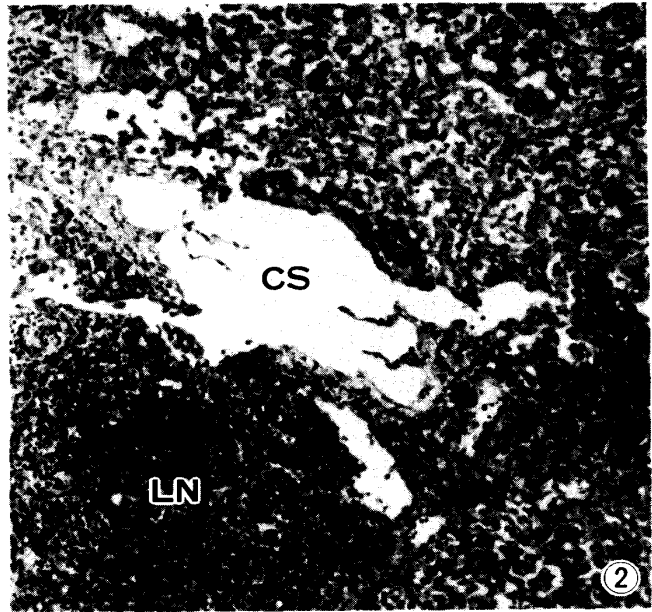
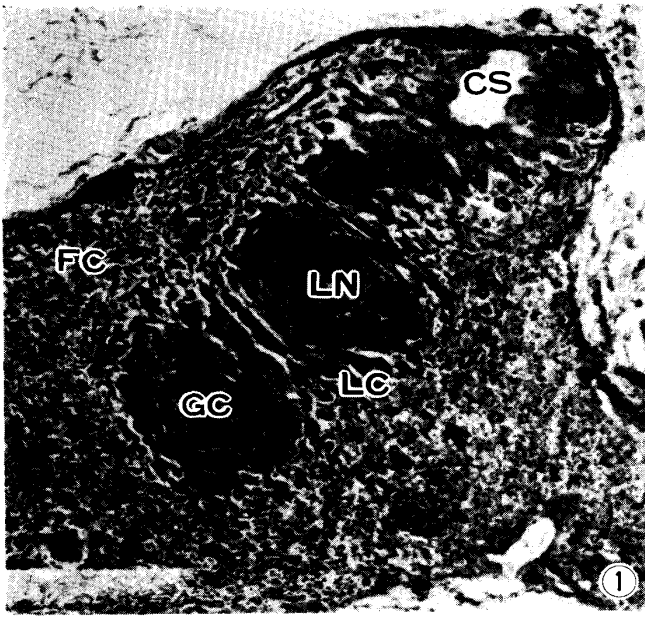


PLATE II

- Fig. 8 Germinal centers and lymphatic cords including plenty of lymphocytes are observed in Tx-duck, too.  
Cervico-thoracal node of Tx-duck H-E × 125
- Fig. 9 In Tx-duck, the lymphocytes of the deep area of lymphatic nodules are eliminated.  
Cervico-thoracal node of Tx-duck H-E × 500
- Fig. 10 In Tx-X-duck, severe elimination of lymphocytes is observed in the deep area of the nodule.  
Lumbar node of Tx-X-duck H-E × 500
- Fig. 11 In cyclophosphamide-treated duck, lymphatic nodules seem to be unchanged, but almost no lymphocytes in the lymphatic cords are found. Cervico-thoracal node of Bx-duck H-E × 125
- Fig. 12 Lymphocytes in the lymphatic cord are eliminated, but lymphatic nodule is unchanged.  
Cervico-thoracal node of Bx-duck H-E × 500
- Fig. 13 In Tx-Bx duck, lymphocytes in the deep area of lymphatic nodule and in the lymphatic cords are severely decreased, but not in the parasinusoidal area of lymphatic nodules facing central sinus. Cervico-thoracal node of Tx-Bx-duck H-E × 500

