



HOKKAIDO UNIVERSITY

Title	DEVELOPMENTAL STUDIES ON EMBRYONIC AND POSTHATCHING SPLEENS IN CHICKENS WITH SPECIAL REFERENCE TO DEVELOPMENT OF WHITE PULP
Author(s)	OGATA, Kenji; SUGIMURA, Makoto; KUDO, Norio
Citation	Japanese Journal of Veterinary Research, 25(3-4), 83-92
Issue Date	1977-10
DOI	https://doi.org/10.14943/jjvr.25.3-4.83
Doc URL	https://hdl.handle.net/2115/2122
Type	departmental bulletin paper
File Information	KJ00002373411.pdf



DEVELOPMENTAL STUDIES ON EMBRYONIC AND
POSTHATCHING SPLEENS IN CHICKENS
WITH SPECIAL REFERENCE
TO DEVELOPMENT OF WHITE PULP

Kenji OGATA, Makoto SUGIMURA and Norio KUDO

*Department of Veterinary Anatomy
Faculty of Veterinary Medicine
Hokkaido University, Sapporo 060, Japan*

(Received for publication, August 1, 1977)

Spleens in chickens from 4 days of incubation to 23 weeks of age were observed by means of quantitative histological methods with special reference to the development of the white pulp. The results obtained were as follows.

The developmental process of the spleen in chickens was distinguished into 7 stages: 3 in the embryonic and 4 in the posthatching spleens. No development of lymphatic tissues was found in the embryonic spleens; however, there were some in the posthatching spleens.

The white pulp was divided into 4 tissue elements: periarterial lymphatic tissue (PAL), perivenous lymphatic tissue (PVL), periellipsoidal lymphatic tissue (PEL), and the germinal center. Out of 4 elements, the appearance time of PVL was the earliest (2 days after hatching). The PAL, PEL, and germinal centers appeared in turn at 4 days, 6 days and 3 weeks old, respectively. The plasma cells appeared at 2 days of age after hatching. The PAL, PVL, and PEL showed different growth curves, and the numbers of germinal centers and plasma cells also showed different growth curves.

INTRODUCTION

It is known that the white pulp of chicken spleen changes quantitatively (HOFFMANN-FEZER, 1973) and qualitatively (TOIVANEN et al., 1974) with age. Many obscure points remain, however, concerning the thymus- or bursa-dependent area of the avian splenic element (JANKOVIĆ & ISAKOVIĆ, 1964; ISAKOVIĆ & JANKOVIĆ, 1964; COOPER et al., 1966; HOSHI, 1972), because there is no strict morphological distinction between the different elements of the white pulp in the above-cited reports. In order to understand the actual function of the white pulp elements, morphological studies, which include the ontogeny of strictly distinguished white pulp elements and plasma cells, are required.

In this report, the differentiations and quantitative changes of splenic elements of chicken from 3 days of incubation to 23 weeks of age are reported and discussed with

This work was supported in part by grants (137003) from the Ministry of Education, Science and Culture, Japan.

special reference to the ontogeny of the different white pulp elements.

MATERIALS AND METHODS

Ninety fertile eggs of white Leghorn Babcock B 300 were incubated in an automatic incubator at 37°C. From 3 to 20 days of incubation 5 embryos were used daily. Eighty-five chickens of the same strain were sacrificed at hatching day, 2, 4, 6, and 10 days of age and 2, 3, 4, 5, 6, 8, 10, 12, 14, 17, 20, and 23 weeks of age

Chick embryos (3 to 14 days of incubation) and spleens (after 15 days of incubation) were fixed in Bouin's fluid or phosphate buffered (pH 7.4) 4% paraformaldehyde. Following fixation, the specimens were weighed and embedded in paraffin, sectioned 5 to 10 μ in thickness, and stained with hematoxylin-eosin, toluidine blue, methyl green-pyronine, Dominici, and Gomori's silver impregnation for reticular fibers.

The number of germinal centers per section cut through the equatorial plane of the spleen was recorded.

The number of plasma cells was determined by counting in 0.625 square mm on the section.

For the quantitative studies of splenic elements, the area of splenic elements was measured in 10 square mm of sections by means of the point counting method and represented by percentage. The relative weights (mg/100 g of body weight) of the splenic elements were then calculated by multiplying the relative weight of the spleen by the percentage of splenic elements.

RESULTS

1. Developmental stage of the spleen

The developmental process of the chicken spleen was distinguished into 7 stages: 3 in the embryonic and 4 in the postnatal spleens.

1) Embryonic spleen

The 1st stages was observed from 4 to 6 days of incubation. A splenic anlage appeared at 4 days of incubation as a slight swelling of mesenchymal tissue in the dorsal mesenterium near the dorsal pancreas. At 5 days of incubation the splenic anlage was observed as a dome (fig. 1). From 4 to 6 days of incubation, the splenic anlage consisted almost totally of mesenchymal cells (fig. 2).

The 2nd stage was found from 7 to 15 days of incubation. The primordium of the trabecular artery, surrounded by 2~3 layers of mesenchymal cells, appeared between 7 and 8 days of incubation (fig. 3). The mesenchymal cells formed the tunica media between 8 and 9 days of incubation. The tunica externa was formed around the artery between 9 and 10 days of incubation. Trabecular tissue appeared around the major arteries between 14 and 15 days of incubation (fig. 4). Major trabecular veins were

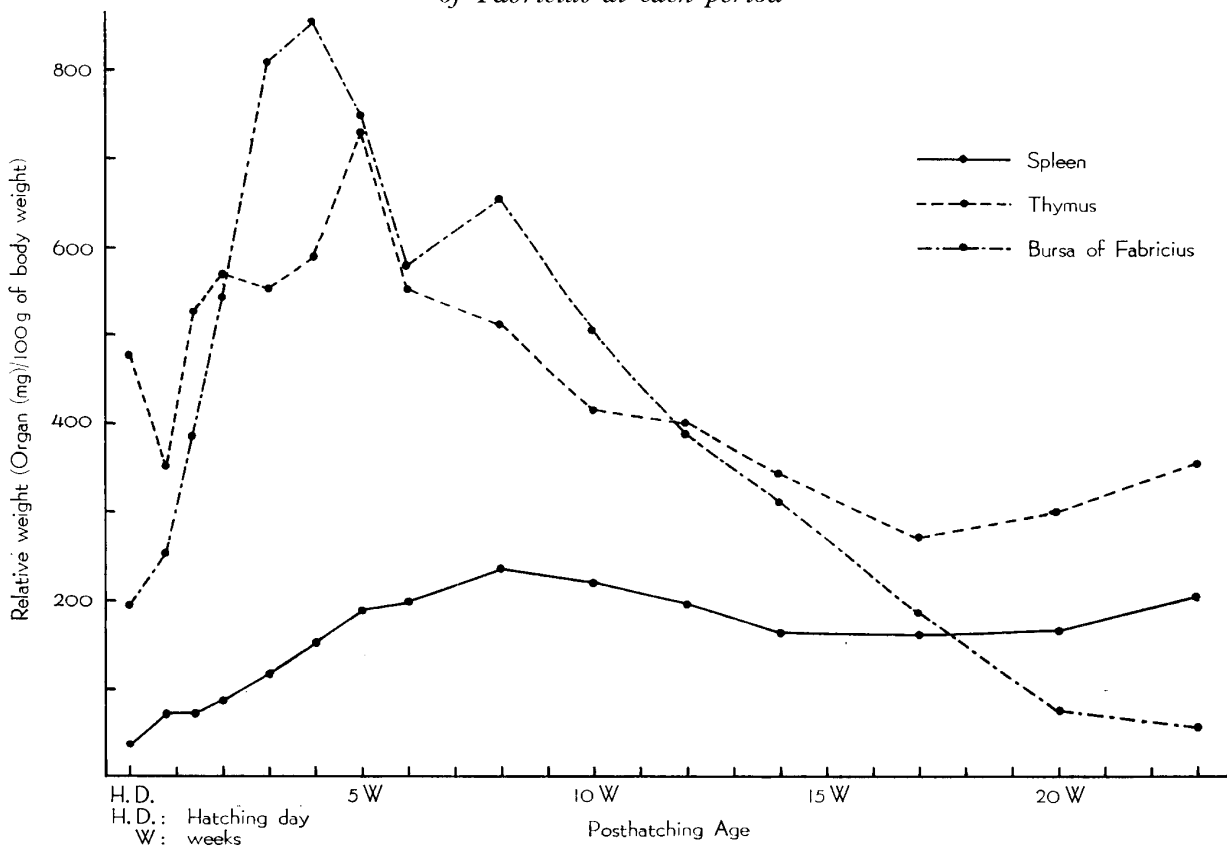
observed at the same time as the arteries (fig. 5).

Hemocytoblasts with a large clear nucleus, 1 or 2 large nucleoli, and a basophilic cytoplasm were observed for the first time at 7 days of incubation in the blood vessels, and also in the mesenchyme at 8 days on incubation. At 10 days of incubation, numerous hemocytoblasts were observed in the mesenchyme and blood vessels, but after 14 days of incubation, the number of hemocytoblasts decreased, and instead of hemocytoblasts, cells of the granulocytic series appeared frequently in the spleen.

The 3rd stage was found from 16 days of incubation to hatching day. The primordium of the sheathed capillaries appeared between 16 and 17 days of incubation (fig. 7). At 18 days of incubation, one or two reticular cell layers were observed (fig. 8). At 20 days of incubation, the large area of the spleen was occupied with sheathed capillaries and their ellipsoidal sheath.

Myelocytes with a large, round or oval nucleus and eosinophilic granules in their cytoplasm were observed for the first time at 9 days of incubation in the stroma of the spleens. The cells of granulocytic series increased rapidly from 12 to 19 days of incubation (fig. 8). After 19 days of incubation, the granulocyte series decreased.

TEXT-FIGURE 1 *Relative weights of spleen, thymus, and bursa of Fabricius at each period*



Small foci of erythropoiesis were observed at 7, 10, 12, and 14 days of incubation.

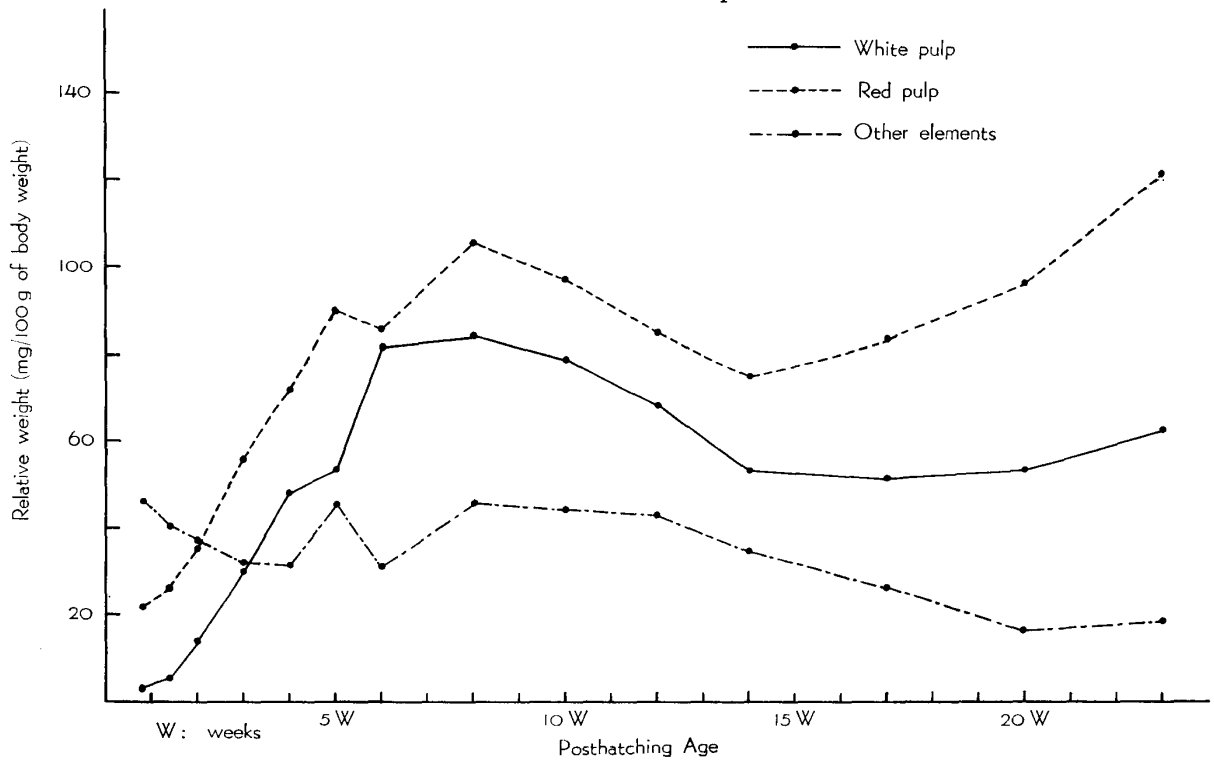
Lymphoid cells were distributed randomly from about 15 days of incubation in the spleens. No accumulation of lymphocytes, however, was observed in the embryonic spleens.

2) Posthatching spleen

The weights of the spleen, thymus and bursa of Fabricius of aged one day to 23 weeks are shown in text-figure 1 in order to define the developmental relationship between the spleen and the central lymphoid organs. The relative weight of the spleen increased gradually from hatching day and reached its maximum at 8 weeks of age. Though it decreased slightly after 8 weeks of age, few changes were observed. The relative weight of the thymus increased rapidly from 6 days of age and reached its maximum at 5 weeks of age. It decreased gradually after 5 weeks of age. The relative weight of the bursa of Fabricius increased rapidly from hatching day and reached its maximum at 4 weeks of age.

The splenic elements were divided into three: white pulp, red pulp and other tissues. Their relative weights are shown in text-figure 2. The ontogeny of the white pulp elements and plasma cells is reported further on in this paper.

TEXT-FIGURE 2 *Relative weights of white pulp, red pulp and other elements at each period*



The 4th stage was observed from hatching day to 3 weeks of age. In this stage the white pulp and plasma cells were observed, and the relative weights of the white pulp and the red pulp increased rapidly after its appearance. The relative weights of the other tissues decreased gradually, however.

The 5th stage was observed from 4 to 8 weeks of age. The relative weight of the white pulp as well as the red pulp and the number of plasma cells continued to increase remarkably in this stage. On the other hand, the relative weight of the other tissues was variable.

The 6th stage was observed from 8 to 14 weeks of age. An involution of white pulp was noted in this stage. The relative weight of the red pulp decreased at the same rate as the white pulp, and the relative weight of the other tissues decreased, gradually.

The 7th stage was observed after 14 weeks of age. In this stage, although no remarkable changes of white pulp were found, the growth of the red pulp was significant. The relative weight of the other tissues decreased gradually.

2. Ontogeny of white pulp and plasma cells

The white pulp was divided into four tissue elements: PAL; PVL; PEL; and germinal centers. The appearances and the quantitative changes of PAL, PVL, PEL are shown in table 1 and text-figure 3, and those of the germinal centers and plasma cells are shown in tables 2 and 3, respectively.

TABLE 1 *Histological evaluation of the lymphatic tissue in the chicken spleen*

AGE	DAYS				: WEEKS	
	1	2	4	6	10	2~23
NO. OF CHICKENS	5	5	5	5	5	5
PAL*	—	5	4			
	+		1	5	5	5
PVL**	—	4				
	+	1	5	5	5	5
PEL***	—	5	5	5	1	
	+			4	5	5

— : absent

+ : present

* : periarterial lymphatic tissue

** : perivenous lymphatic tissue

*** : periellipsoidal lymphatic tissue

TEXT-FIGURE 3 *Relative weights of periarterial (PAL), perivenous (PVL) and periellipsoidal (PEL) lymphatic tissue at each period*

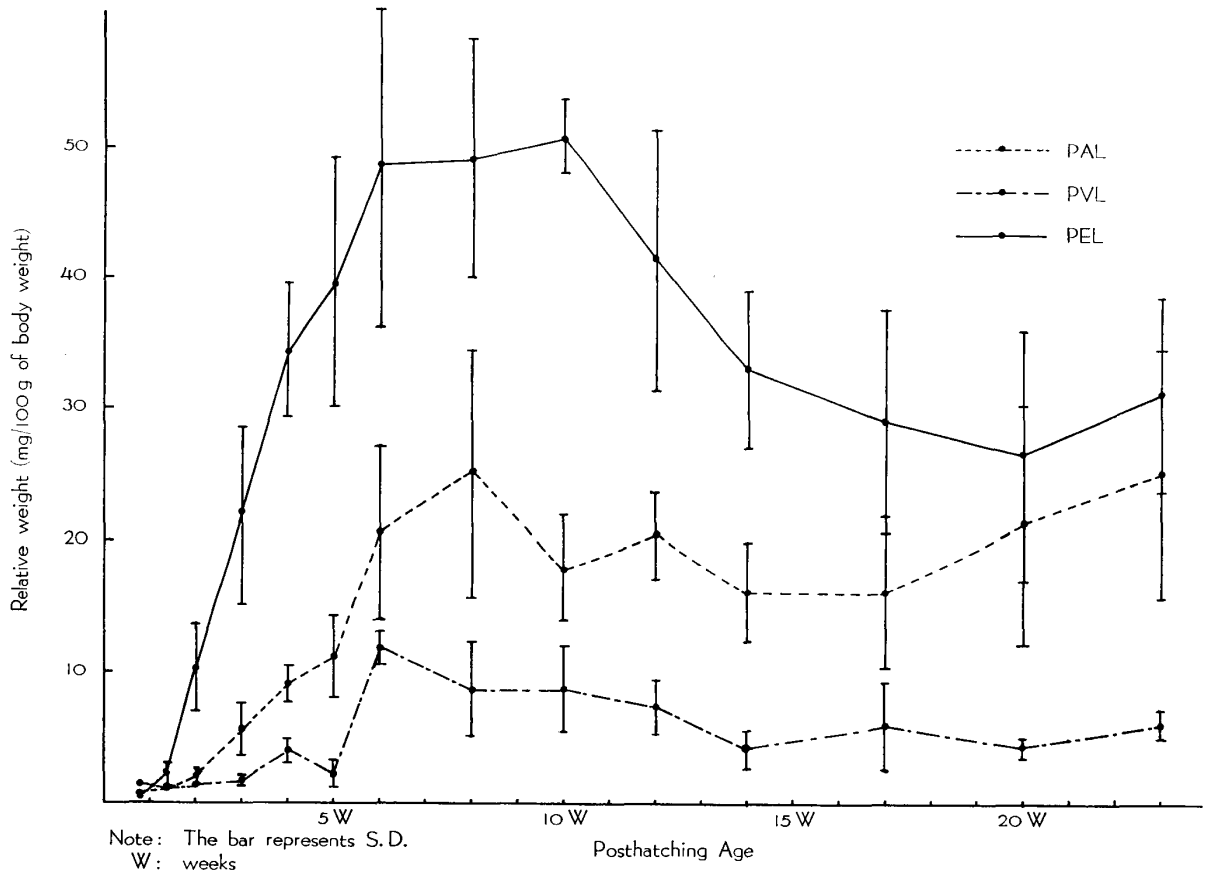


TABLE 2 *Histological evaluation of germinal centers*

AGE	DAYS					WEEKS											
	1	2	4	6	10	2	3	4	5	6	8	10	12	14	17	20	23
NO. OF CHICKENS	5	5	5	5	5	5	5	5	5	5	5	5	5	5	5	5	5
0*	5	5	5	5	4	5	1	1	2								
1~4					1			2						1	3	1	2
5~10								2	3	2	1		3	1	1	1	
11~50							4			3	3	2	2	3	1	2	2
51~100											1	1					1
101~												2				1	

*: the number of germinal centers per section cut through the equatorial plane of the spleen

The PAL was a nodule of small lymphocytes around the arteriolar branch (fig. 9). The PAL was observed for the first time in one chicken at 2 days of age (fig. 10), and in all chicks after 4 days of age. The relative weight of the PAL increased rapidly until 8 weeks of age and reached its maximum at that age. After 8 weeks of age, there was no significant change of the relative weight of the PAL.

The PVL was a nodule of small lymphocytes under the endothelium of the vein (fig. 11). The PVL was observed for the first time in one chick at hatching day (fig. 12), and in all chicks after 2 days of age. The relative weight of the PVL increased gradually until 6 weeks of age, and slightly decreased from 6 to 14 weeks of age. After 14 weeks of age there was no significant change of the relative weight of the PVL.

The PEL consisted of pyroninophilic medium-sized lymphocytes accumulated around the sheathed capillary (fig. 14). A small number of pyroninophilic medium-sized lymphocytes was observed around the sheathed capillaries for the first time in four chickens 6 at days of age (fig. 13). The lymphocytes then increased to form the PEL at 2 weeks of age. The relative weight of the PEL increased rapidly until 10 weeks of age and reached its maximum at 10 weeks of age. After 10 weeks of age it decreased gradually, and there was no significant change of the relative weight of PEL after 14 weeks of age.

The germinal centers were represented as an accumulation of large, medium and small-sized lymphocytes and were surrounded by a fibrous capsule (fig. 15). The germinal center was observed for the first time in one chick at 10 days of age in the PAL. Though there was no germinal center in the spleens at 2 weeks of age, 11 and more germinal centers per section were observed in four chickens at 3 weeks of age. The number of germinal centers increased until 10 weeks of age, and there was a tendency for them to diminish after 10 weeks of age. The germinal centers were found in the PAL in many cases and were found also in the PVL.

TABLE 3 *Histological evaluation of plasma cells*

AGE	DAYS					WEEKS												
	1	2	4	6	10	2	3	4	5	6	8	10	12	14	17	20	23	
NO. OF CHICKENS	5	5	5	5	5	5	5	5	5	5	5	5	5	5	5	5	5	
0*	5	2																
1~10		3	5	1	1													
11~50				4	3	5	5	5	4	3	1	1	2	2				
51~100									1	2		1		2	1	1	1	
101~200					1							3	1	2		3	1	3
201~											1	2	1	1	1	3	1	

*: the number of plasma cells per 0.625 mm² on the section

The plasma cells, which had pyroninophilic cytoplasm, were found in the red pulp (fig. 16). Plasma cells were observed in two chicks at 2 days of age and in all chickens after 4 days of age. The number of plasma cells increased gradually until about 8 weeks of age. There was no significant change of the plasma cell numbers after 8 weeks of age.

DISCUSSION

The results obtained here agree almost fully with the detailed reports of DANCHAKOFF (1916), SANDREUTER (1951), IMAI (1954), DELANNY & EBERT (1962), and MIKI (1965) concerning the embryonic development of the chick spleen.

Although lymphoid cells were observed from about 15 days of incubation in the spleens, which corresponds to reports by DANCHAKOFF (1916) and SANDREUTER (1951), no accumulation of lymphocytes was observed in the embryonic spleens, only in the postembryonic ones.

In the present data, the PVL, PAL, PEL, and germinal centers were found at 2, 4, 6 days old and 3 weeks old, respectively.

It was demonstrated by several investigators that the PAL and PVL were thymus-dependent in chicken spleens (JANKOVIĆ & ISAKOVIĆ, 1964; ISAKOVIĆ & JANKOVIĆ, 1964; COOPER et al., 1966; HOSHI, 1972; MORI, 1975). On the other hand, SUGIMURA & HASHIMOTO¹⁶⁾ (1976) showed that PAL is thymus-dependent but PVL was thymus- and bursa-independent in duck spleens. The PAL and PVL in chicken spleens were reported in the same areas as mentioned in the above-cited reports (HOSHI, 1972). As the PVL appeared earlier than PAL, and the growth curve of PAL was more or less different from that of the PVL in the present data, PAL and PVL may be located in separate areas both in the chicken and in the duck spleens.

The PEL had a characteristic growth curve, which showed a rapid increase in the 5th stage and an involution in the 6th stage. The growth curve of PEL resembled that of the bursa of Fabricius, namely, that when the growth curve of the bursa of Fabricius showed a rapid increase, the PEL did the same, and that when the growth curve of bursa of Fabricius showed involution, the PEL began to show the involution. It seems, therefore, that the growth curve of PEL is consistent with the bursa-dependency of PEL in chicken spleens (HOSHI, 1972; MORI, 1975). SUGIMURA & HASHIMOTO¹⁷⁾ (1976) showed that PEL was bursa-dependent in duck spleens, also: consequently, it must be certain that PEL is bursa-dependent.

The present result on the ontogeny of each element of the white pulp strongly implies that each of them may be different from each other in their functions. It was shown by several investigators that the germinal centers and plasma cells were bursa-dependent, because of the absence of germinal centers and plasma cells in bursectomized chicken spleens (ISAKOVIĆ & JANKOVIĆ, 1964; COOPER et al., 1966; HOSHI, 1972; MORI,

1975). On the other hand, it was suggested by some investigators that the thymus may play a role in the development of the germinal center (JANKOVIĆ & MITROVIĆ, 1967; HOSHI & MORI, 1973). SUGIMURA & HASHIMOTO¹⁷⁾ (1976) reported that the bursal cells did not seem to be an exclusive source of plasma cell precursors in ducks. No evidence showed the functional meaning of the present results in silent morphology. Further studies are needed to ascertain the origins and immunological functions of PVL, germinal centers, and plasma cells.

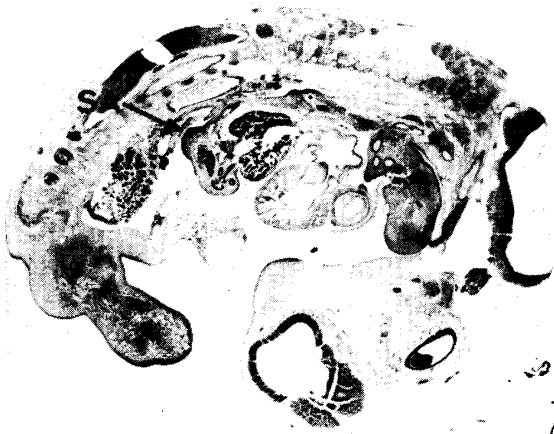REFERENCES

- 1) COOPER, M. D., PETERSON, R. D. A., SOUTH, M. A. & GOOD, R. A. (1966): *J. exp. Med.*, **123**, 75
- 2) DANCHAKOFF, V. (1916): *Am. J. Anat.*, **20**, 255
- 3) DELANNEY, L. B. & EBERT, J. D. (1962): *Contr. Embryol.*, **37**, 57
- 4) HOFFMANN-FEZER, G. (1973): *Z. Zellforsch. mikrosk. Anat.*, **136**, 45
- 5) HOSHI, H. (1972): *Tohoku J. exp. Med.*, **106**, 285
- 6) HOSHI, H. & MORI, T. (1973) *Ibid.*, **109**, 97
- 7) IMAI, T. (1954): "Problems on the vascular ellipsoid of the spleen, with special reference to its morphological findings" *Symposium on Hematology*, **7**, 60-86, Tokyo: Nagai Press (in Japanese)
- 8) ISAKOVIĆ, K. & JANKOVIĆ, B. D. (1964): *Int. Archs Allergy appl. Immun.*, **24**, 296
- 9) JANKOVIĆ, B. D. & ISAKOVIĆ, K. (1964): *Ibid.*, **24**, 278
- 10) JANKOVIĆ, B. D. & MITROVIĆ, K. (1967): "Germinal Centers in the Tonsilla caecalis-Relationship to the Thymus and the Bursa of Fabricius" *Germinal Centers in Immune Responses*, 131-144, Ed. COTTIER, H., ODARTCHENKO, N., SCHINDLER, R. & CONGDON, C. C., New York: Springer-Verlag
- 11) MIKI, S. (1965): *Acta anat. nippon.*, **40**, 329
- 12) MORI, T., HOSHI, H. & ISHIKAWA, H. (1975): "Bursa-dependency of the periellipsoid lymphoid cells in chicken spleen" *10th Int. Congr. Anat., Tokyo*, 384
- 13) NAGY, Z. A. (1970): *Zentbl. VetMed.*, **17**, 422
- 14) OSOGOE, B. (1954): "Phylogenesis of the spleen" *Symposium on Hematology*, **7**, 1-35, Tokyo: Nagai Press (in Japanese)
- 15) SANDREUTER, A. (1951): "Vergleichende Untersuchung über die Blutbildung in der Ontogenese von Haushuhn (*Gallus gallus* L.) und Star (*Sturnus V. vulgaris* S.)" *Acta anat.*, **11**, Suppl. 1-72
- 16) SUGIMURA, M. & HASHIMOTO, Y. (1976): *Acta anat. nippon.*, **51**, 320 (in Japanese)
- 17) SUGIMURA, M. & HASHIMOTO, Y. (1976): *J. Reticuloendothel. Soc.*, **19**, 201
- 18) TALIAFERRO, W. H. & TALIAFERRO, L. G. (1955): *J. infect. Dis.*, **97**, 99
- 19) THORBECKE G. J., GORDON, H. A., WOSTMAN, B., WAGNER, M. & REYNIERS, J. A. (1957): *Ibid.*, **101**, 237
- 20) TOIVANEN, P., TOIVANEN, A. & TAMMINEN, P. (1974): *Eur. J. Immun.*, **4**, 405

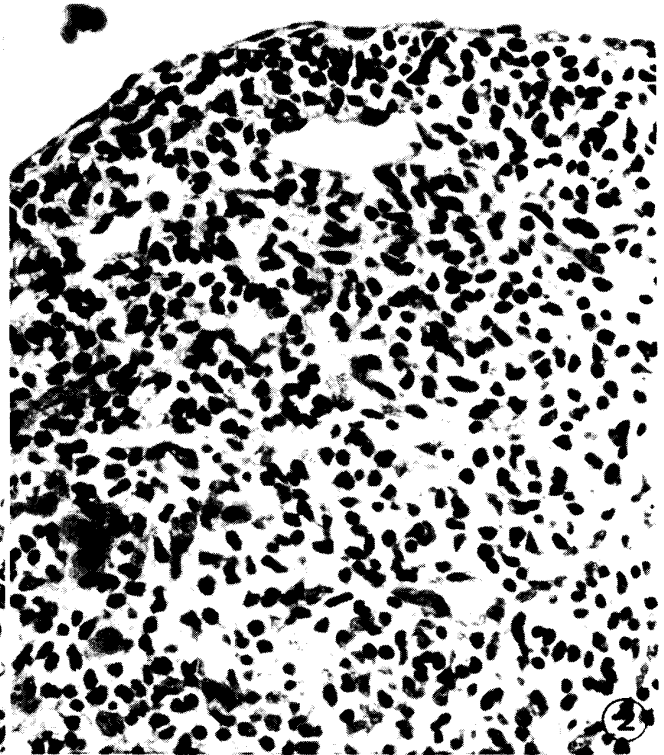
EXPLANATION OF PLATES

PLATE I

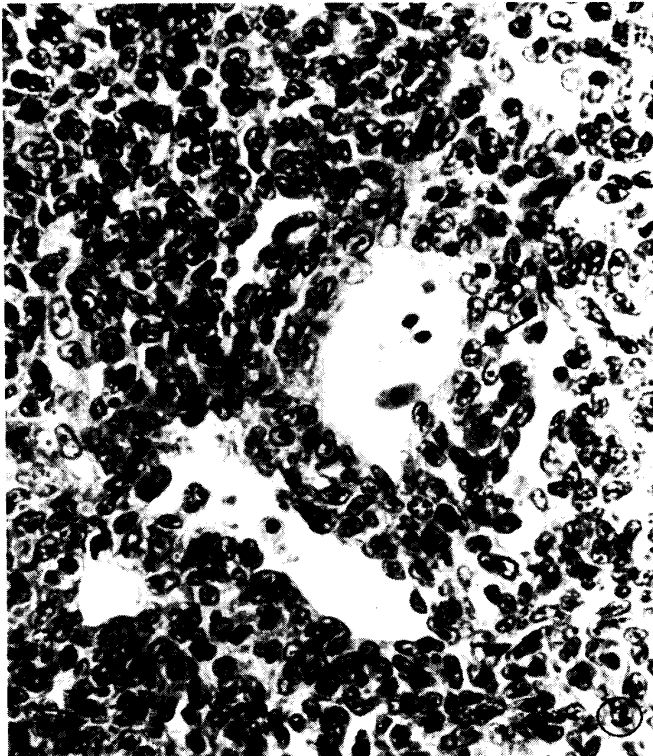
- Fig. 1 The spleen anlage (SA) of the chick embryo at 5 days of incubation was observed as a dome dorsal to the dorsal pancreas.
Hematoxylin-Eosin × 9
- Fig. 2 The spleen anlage at 6 days of incubation
The artery and vein are not identified morphologically.
Hematoxylin-Eosin × 440
- Fig. 3 The primordium of the trabecular artery at 8 days of incubation is surrounded by mesenchymal cells (arrow).
Hematoxylin-Eosin × 440
- Fig. 4 The trabecular artery at 15 days of incubation
The trabecular tissue is already formed.
Hematoxylin-Eosin × 220
- Fig. 5 The trabecular vein at 15 days of incubation
The trabecular tissue is already formed.
Hematoxylin-Eosin × 110
- Fig. 6 The spleen of the chick embryo at 11 days of incubation
Many hemocytoblasts (HB) and myelocytes (MC) were observed.
Dominici stain × 440





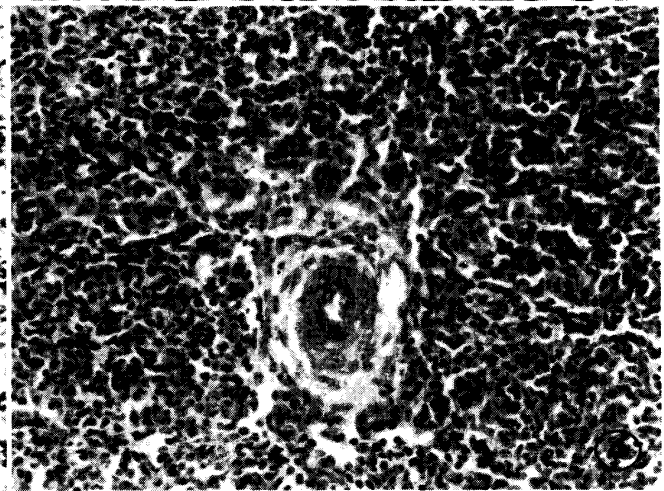
①



②



③



④

PLATE II

- Fig. 7 The primordium of sheathed capillaries (SC) is observed at 16 days of incubation.
Hematoxylin-Eosin × 440
- Fig. 8 The spleen at 19 days of incubation is characterized by well-developed sheathed capillaries (SC) and many granulocytes.
Hematoxylin-Eosin × 440
- Fig. 9 PAL at 10 weeks of age
Hematoxylin-Eosin × 220
- Fig. 10 At 2 days of age, a small nodule of small lymphocytes is observed around the small artery in the chick spleen.
Hematoxylin-Eosin × 440
- Fig. 11 PVL at 10 weeks of age
Hematoxylin-Eosin × 220
- Fig. 12 At hatching day, a cluster of small lymphocytes is observed under the endothelium of the vein in the chick spleen.
Hematoxylin-Eosin × 440

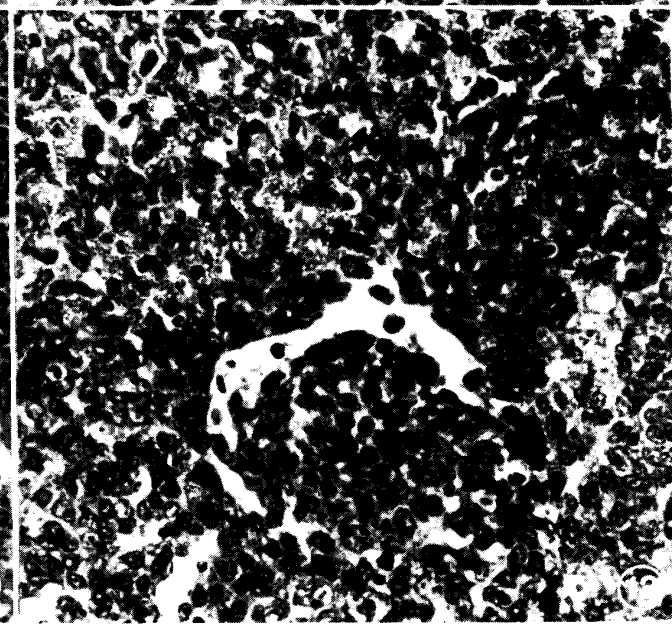
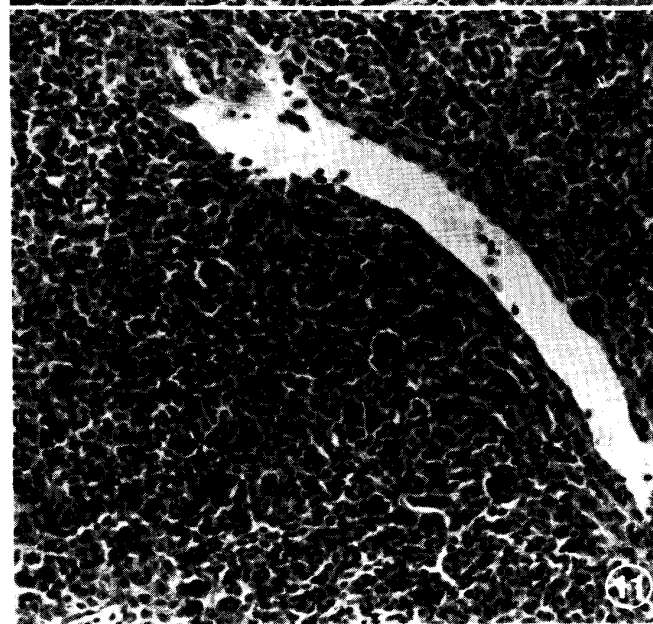
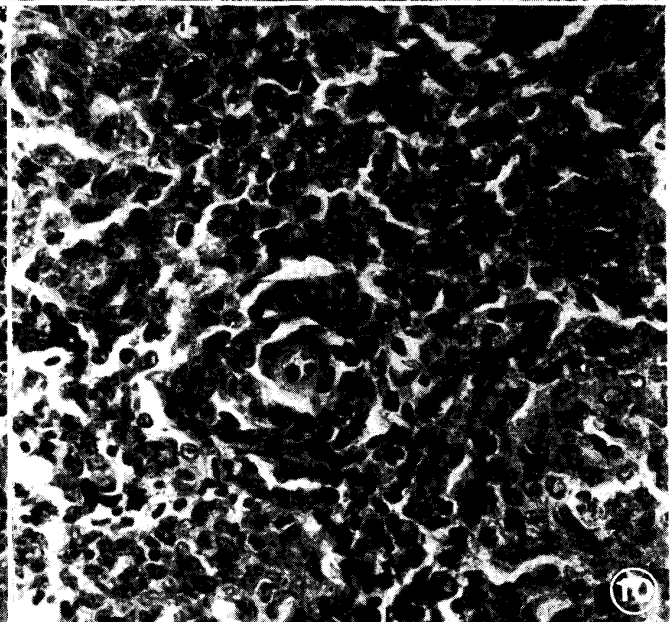
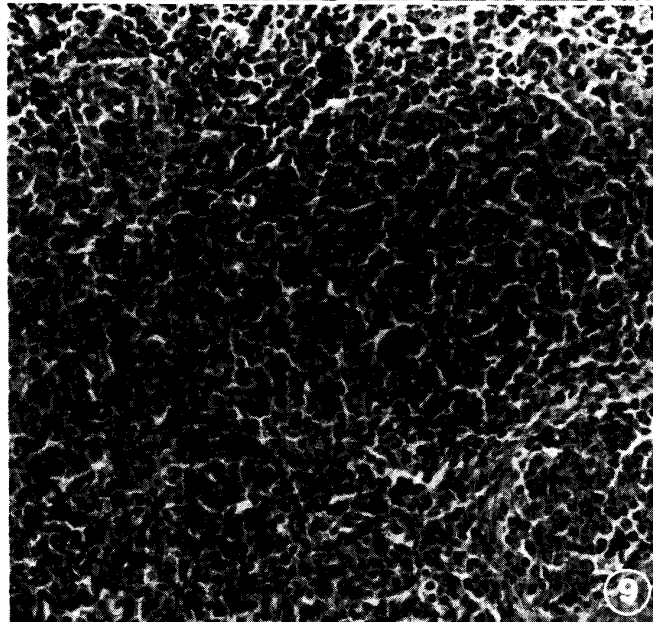
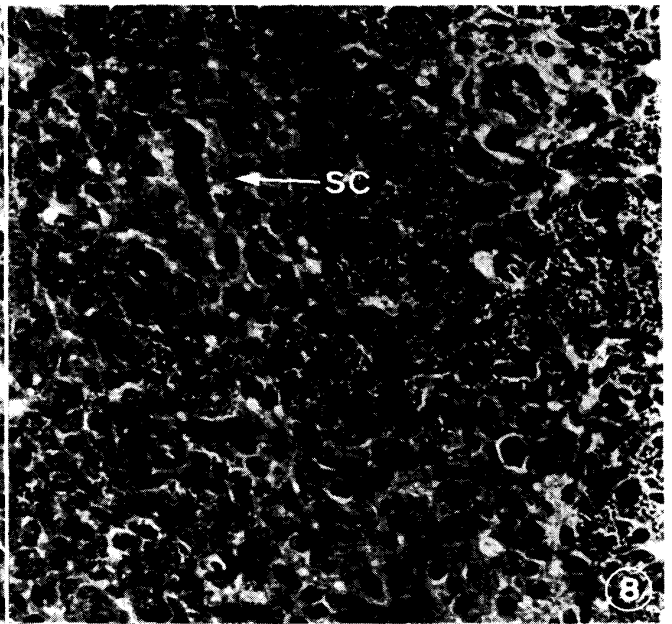
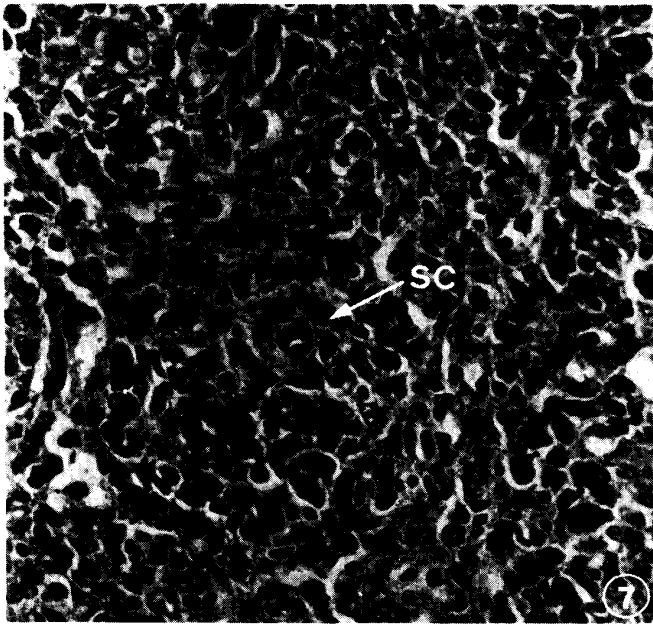


PLATE III

- Fig. 13 At 6 days of age, a small number of medium-sized lymphocytes (ML) are observed around the sheathed capillaries.
Hematoxylin-Eosin × 440
- Fig. 14 PEL at 10 weeks of age
Hematoxylin-Eosin × 220
- Fig. 15 A germinal center in the spleen at 10 weeks of age
Hematoxylin-Eosin × 220
- Fig. 16 The plasma cells in the spleen at 17 weeks of age
Methyl green-Pyronine × 440

