



HOKKAIDO UNIVERSITY

Title	THE LYMPHATIC SYSTEM OF THE CORPUS PARACLOACALIS VASCULARIS AND THE SECOND FOLD IN THE MALE DOMESTIC FOWL
Author(s)	YAMANO, Shuji; SUGIMURA, Makoto; KUDO, Norio
Citation	Japanese Journal of Veterinary Research, 25(3-4), 93-98
Issue Date	1977-10
DOI	https://doi.org/10.14943/jjvr.25.3-4.93
Doc URL	https://hdl.handle.net/2115/2123
Type	departmental bulletin paper
File Information	KJ00002373412.pdf



THE LYMPHATIC SYSTEM OF THE CORPUS
PARACLOACALIS VASCULARIS AND
THE SECOND FOLD IN THE
MALE DOMESTIC FOWL*

Shuji YAMANO, Makoto SUGIMURA and Norio KUDO

*Department of Veterinary Anatomy
Faculty of Veterinary Medicine
Hokkaido University, Sapporo 060, Japan*

(Received for publication, August 5, 1977)

The lymphatic system of the corpus paracloacalis vascularis and the second fold of the cloaca in the male domestic fowl was investigated by means of the Latex-cast specimens.

The lymphatic system of the corpus paracloacalis vascularis (CV) was a complex pear-shaped lymphatic spongy body with a stalk.

The lymphatics of the second fold of both sides were connected and formed an arch-shaped, spongy body. The body was divided into 4 parts: the connecting part; the phallus part; the round fold part; and the lymph fold part.

The spongy body of the CV was closely connected to that of the second fold; it was suggested that both bodies, as a system, play a role in the erection of the copulatory organ. The writers recommend the term "Corpus paracloacalis vascularis-Second fold lymphatic system" for these lymphatic structures.

INTRODUCTION

The role of lymph during the erection of the male avian copulatory organ has been briefly described by ECKHARD (1876), MÜLLER (1908), LIEBE (1914), NISHIYAMA (1955), and KNIGHT (1970). The writers^{9,10} perviously reported on the morphology of the corpus paracloacalis vascularis. In this report, however, the writers were unable to find a description of the lymphatic system of the corpus paracloacalis vascularis-phallus related specifically to the erection apparatus in the chicken.

The purpose of this study is to clarify the role of the lymphatic system of the corpus paracloacalis vascularis and the second fold of the cloaca in the domestic fowl.

MATERIALS AND METHODS

The corpus paracloacalis vascularis was obtained from 41 male domestic fowls (Babcock B-300) from 31 to 413 days old. Neoprene latex 601-A was injected directly into

* This work was presented at the 82nd meeting of the Japanese Society of Veterinary Science in October 11, 1976 and supported, in part, by two grants (Project No. 166127 and 148069, 1976) from the Ministry of Education, Science and Culture, Japan.

the lymphatic vessels of the phallus or the right CV. The latex-filled lymphatic system of the CV and the second fold was removed along with neighboring tissues and macerated with industrial HCl for a few days. The macerated Neoprene cast specimens of the lymphatics were observed macroscopically and microstereographically.

RESULTS

The lymphatic system of the male domestic fowl copulatory organ consisted of a complex lymphatic spongy body of the corpus paraclacalis vascularis, and the second fold of the cloaca.

The lymphatic system of the CV was a complex pear-shaped spongy body with a stalk, in each side. The network of the broad lymphatic spaces was revealed on the surface of the CV. These lymphatic spaces were interconnected to each other in the deep area of the CV, also (figs. 1~3). At the cranial end, or the hilar area of the CV, 13 or 14 small lymphatic vessels originated from these lymphatic spaces (fig. 2). These small lymphatic vessels anastomosed with one another to form 3 or 4 efferent lymphatic vessels, which lay lateral to the A. and V. pudenda interna. Distinct valves were present in the efferent lymphatic vessels, but not in the lymphatic spaces of the CV (fig. 1).

The spongy bodies of the second fold of both sides of the cloaca were connected to form an arch-shaped body consisting of 4 parts: the connecting part, the phallus part, the round fold part, and the lymph fold part. There were no valves in the lymphatics forming these spongy bodies.

The connecting part: This part was a flattened, columnar-shaped lymphatic spongy body, consisting of a complex lymphatic network extending from the stalk of the CV. The parts of both sides connected to the phallus part located in the middle of the second fold, and they were anastomosed with the lymph and round fold parts dorsally by the smaller lymphatic network. The lymphatics forming the network were smaller in size than those of the CV (fig. 3).

The phallus part: This part lay in the middle of the second fold between both connecting parts. The loosely paired lymphatic spongy body of the phallus part was short, cylindrically-shaped (fig. 3).

The round fold part: This part lay caudally to the lymph fold part and dorsally to the connecting part. There was pair of spongy, crescent-shaped bodies which consisted of a smaller and more compact lymphatic network than that of the connecting part on each side. This part was anastomosed with the connecting part by a smaller lymphatic network. There was a distinct deep groove showing the presence of septum between the round and lymph fold parts (fig. 2).

The lymph fold part: This part was also a pair, and was divided into 3 or 4 lobes by the deep grooves in each side (figs. 1 & 2). This part lay cranially to the

round fold part, and dorsally to the connecting part. The lymphatic spongy body of this part was quite prominent and dome-shaped in the erected state, and consisted of the smallest and most compact lymphatic network in all parts of the second fold. It was anastomosed with the round fold part and the connecting part by the smaller lymphatic network, as described in the round fold part. It is characteristic of the lymph fold part that a few lymphatic vessels with valves are connected to the large lymphatic spaces on the surface of the CV (fig. 1). An ejaculating groove was formed along the phallus part and the round fold part of both sides in well-injected cast specimens (fig. 1). In addition, a semicircular vestige was presented between the lymph fold part and the round fold part, showing evidence of the contraction of the *M. sphincter cloacae*.

DISCUSSION

The anatomy and function of the *corpus paracloacalis vascularis*, Nishiyama's vascular body, has been extensively studied by KNIGHT (1970), NISHIYAMA (1955), NISHIYAMA & OGAWA (1961), and the present writers^{8,10}. These reports showed that the erection of the phallus and the temporary swelling of the lymph fold seemed to be caused by lymph-like fluid formed from blood flowing in the capillary cords of the vascular bodies, although LAKE (1957, 1971) emphasized that additional vascular tissue in the wall of the cloaca is engorged with blood during erection. Up to the present time, however, there have been no reports concerning the morphology of the lymphatic system of this area.

The present macroscopical and microstereographical observations of the lymphatic system of the organs show clearly that the CV and the second fold comprised a morphological system of the lymphatic spongy body. The lymphatics of the second fold are neither a simple connecting portion nor a collecting lymph channel, contrary to NISHIYAMA's (1955) and KNIGHT's findings (1970).

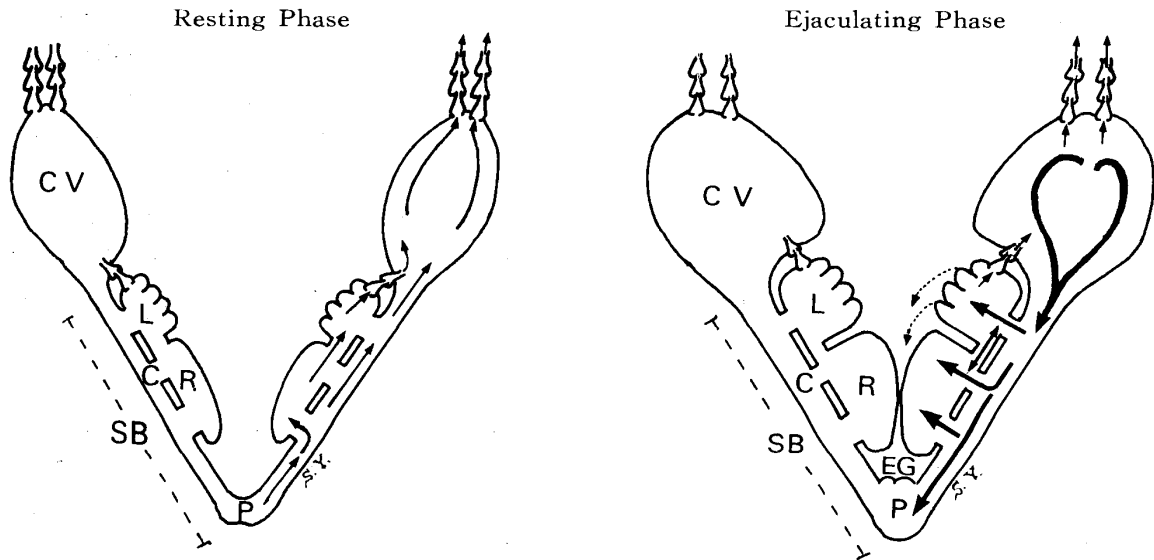
The present and previous morphological findings concerning the CV and the second fold assumed that the erection-dilution mechanism in the male domestic fowl may operate in the following stages (text fig.).

In the first stage, the lymph formed from blood of the CV during sexual excitement transfers into the internal or peripheral lymphatic space^{8,10}. Much of the lymph drainage of the efferent lymphatic vessels is stored mainly in the broad lymphatic space of the CV.

In the second stage, the lymph in the CV overflows into the lymphatic spongy body of the second fold. Some lymph flows from the stalk of the CV to the connecting part, but more flows from the connecting part to the phallus part or to the round fold part and the lymph fold part, according to the present morphological study of the lymphatic system.

In the third stage, the ejaculating phase, the lymph pressure in the second fold

TEXT FIGURE *Lymph flow of corpus paracloacalis vascularis-second fold lymphatic system in the male domestic fowl*



CV: Corpus paracloacalis vascularis

SB: Lymphatic spongy body of second fold

C: Connecting part L: Lymph fold part

P: Phallus part R: Round fold part

EG: Ejaculatory groove

Arrow: Lymph flow in each part

Dotted line: Lymph flow which is expelled from the lymph fold part by NISHIYAMA (1955)

increases greatly, causing the erection of the lymph fold part and the round fold part. As a result of the erection, an ejaculatory groove is formed in the middle of the cloaca, as described by NISHIYAMA (1955).

NISHIYAMA (1955) described that the lymph, which flows into the lymph fold part, is expelled from here. The expelled lymph composes the main part of the transparent fluid or accessory reproductive fluid, which is added to the semen ejaculated from the ductus deferens during sexual excitement. The existence of the densest spongy part of the lymph fold may support NISHIYAMA's finding. The contraction of the M. sphincter cloacae may help to maintain the ejaculatory groove.

After ejaculation, lymph production in the CV ceases, and there is a relaxation of the muscles. The lymph in the second fold runs off quickly through the connecting part, then through the lymphatic vessels between the lymph fold part and the lymphatic space of the CV, and finally into the efferent lymphatic vessels lying along the A. pudenda interna; this is the resting phase.

The writers' findings on the lymphatic system of the corpus paracloacalis vascularis-the second fold of the cloaca involved in the erection-dilution mechanism in the male

domestic fowl support NISHIYAMA's description (1955), which is contrary to LAKE's (1957, 1971). The writers recommended the term "Corpus paracloacalis vascularis-Second fold lymphatic system" for these lymphatic structures in the male domestic fowl.

ACKNOWLEDGMENTS

The writers wish to thank Dr. T. NISHIDA, Department of Veterinary Anatomy, Faculty of Agriculture, University of Tokyo, for his kind help in obtaining literature on this subject. The writers also gratefully acknowledge Hokkaido Chuo Animal Supply Center, Hokkaido, for its kind help in obtaining the materials.

REFERENCES

- 1) ECKHARD, C. (1876): *Beiter. Anat. Physiol.*, **7**, 115
- 2) KNIGHT, C. E. (1970): The anatomy of the structures involved in the erection-dilution mechanism in the male domestic fowl (Diss., East Lansing)
- 3) KUDO, N., SUGIMURA, M. & YAMANO, S. (1975): *Jap. J. vet. Res.*, **23**, 1
- 4) LAKE, P. E. (1957): *J. Anat.*, **91**, 116
- 5) LAKE, P. E. (1971): "The male in reproduction" Physiology and biochemistry of the domestic fowl, **3**, 1411, Ed. BELL, D. J. & FREEMAN, B. M. London and New York: Academic Press
- 6) LIEBE, W. (1914): *Jena. Z. Naturw.*, **51**, 627
- 7) MÜLLER, R. (1908): *Arch. ges. Physiol.*, **122**, 455
- 8) NISHIYAMA, H. (1955): *J. Fac. Agric. Kyushu Univ.*, **10**, 277
- 9) NISHIYAMA, H. & OGAWA, K. (1961): *Jap. J. zootech. Sci.*, **32**, 89
- 10) SUGIMURA, M., KUDO, N. & YAMANO, S. (1975): *Jap. J. vet. Res.*, **23**, 11

EXPLANATION OF PLATE

PLATE

- Fig. 1 Dorsal view of the lymphatic system of the corpus paracloacalis vascularis (CV) and the second fold of the cloaca
In the second fold, the phallus part (P), the round fold part (R), and the lymph fold part (L) are observed. Several efferent lymphatic vessels (EV) are found at the cranial end or hilar area of the corpus paracloacalis vascularis. A few lymphatic vessels (LV) with valves connect between the lymph fold part and the lymphatic space of the corpus paracloacalis vascularis. $\times 7$
- Fig. 2 There is a distinct groove (G) between the round fold part (R) and the lymph fold part (L). $\times 7$
- Fig. 3 Ventral view of the lymphatic space of the corpus paracloacalis vascularis (CV) and the lymphatic network of the connecting part (C). $\times 7$

