



# HOKKAIDO UNIVERSITY

Title	EFFECT OF BURSECTOMY ON THE PATHOGENESIS OF MAREK'S DISEASE
Author(s)	ISOGAI, Hiroshi; FUJIMOTO, Yutaka; OKADA, Kosuke et al.
Citation	Japanese Journal of Veterinary Research, 28(4), 137-148
Issue Date	1981-01-31
DOI	<a href="https://doi.org/10.14943/jjvr.28.4.137">https://doi.org/10.14943/jjvr.28.4.137</a>
Doc URL	<a href="https://hdl.handle.net/2115/2207">https://hdl.handle.net/2115/2207</a>
Type	departmental bulletin paper
File Information	KJ00002374016.pdf



## EFFECT OF BURSECTOMY ON THE PATHOGENESIS OF MAREK'S DISEASE

Hiroshi ISOGAI, Yutaka FUJIMOTO, Kōsuke OKADA  
and Kazuyuki ICHIJO

*Department of Comparative Pathology  
Faculty of Veterinary Medicine  
Hokkaido University, Sapporo 060, Japan*

(Received for publication, September 1, 1980)

The effect of bursectomy on the development of Marek's disease (MD) in chickens was studied histopathologically in two separate experiments in which 2 groups of untreated and bursectomized chickens were used. In experiment I, 16 untreated and 25 bursectomized chickens were examined at 3, 5, 7, 9 and 12 weeks old, and in experiment II, 55 chickens, including 28 bursectomized ones, were inoculated with Marek's disease virus (MDV) at 2 weeks old.

The neonatal bursectomized chickens in experiment I showed the following morphological and functional changes in comparison with the untreated chickens.

- 1 Histopathologically, there was a severe depletion of lymphocytes in the bursa-dependent areas and aplasia of the germinal centers in the spleen.
- 2 There was a lack of antibody synthesis against *Salmonella pullorum*.
- 3 There was no reduction of phytohemagglutinin (PHA) skin reaction.

In experiment II, the chickens were examined at 1, 3, 5, 7 and 10 weeks after inoculation with MDV; the following changes were observed.

- 1 There were no initial cytolytic lesions in the lymphoid tissues of the bursectomized chickens.
- 2 Both the bursectomized and the untreated chickens showed a high and almost identical frequency of MD tumor development in various organs and tissues.

In the lesions of these findings, we concluded that the function of the bursa of Fabricius is not essential for the tumorigenesis of MD.

### INTRODUCTION

Marek's disease (MD) is an infectious and common lymphoproliferative disease in chickens which is caused by a group B herpesvirus, the MD virus (MDV). Chickens infected with MDV usually developed neoplastic lesions in the visceral organs and the peripheral nerves<sup>14</sup>. In chickens lacking maternal antibodies to MDV, MDV infection first causes the so-called "initial cytolytic lesions" which are characterized by severe

The present study was supported in part by grants from the Ministry of Education, Science and Culture, Japan.

lymphoid degeneration and hyperplasia of the reticulum cells and vacuolated macrophages in the lymphoid organs (the thymus, bursa of Fabricius, spleen and cecal tonsils) at about 1 week after MDV infection<sup>1,14)</sup>, followed by lymphoreticular proliferation and gross lymphoma formation at 2-3 weeks after infection.<sup>12,23,24)</sup>

Chickens have two distinct central lymphoid organs, the thymus and the bursa of Fabricius, and it appears that cellular immunity is dependent on the thymus function, whereas humoral immunity depends exclusively on the function of the bursa of Fabricius. Because of these clear functions, chickens are very useful in immuno-suppressive studies in which bursectomy or thymectomy are performed<sup>3,4)</sup>. In such experiments several techniques for bursectomy may be used, ranging from surgery alone, surgical bursectomy plus X-ray irradiation, and chemical bursectomy by hormones or cyclophosphamide; however, the results of these methods have not always been consistent in demonstrating the effect of bursectomy on the pathogenesis of MD.<sup>5,11,29,35,40)</sup> It is probable that problems in technique, such as the fact that chemical bursectomy (cyclophosphamide) inhibits not only the function of the bursa of Fabricius but also that of the thymus<sup>27,42)</sup> are responsible for these discrepancies. Namely, the administration of cyclophosphamide in chickens at hatching suppresses the bursa-dependent immunity permanently, and in addition, it temporarily suppresses thymus-dependent immunity.

In the following two experiments, the chickens were treated with surgical bursectomy plus X-ray irradiation. Chemical bursectomy was not employed in order to avoid the depletion of the thymus. In experiment I the effect of bursectomy was examined functionally and histopathologically in MDV uninoculated chickens, and in the second experiment, the effect of bursectomy on the pathogenesis of MD was examined histopathologically in MDV inoculated chickens.

#### MATERIALS AND METHODS

**Chickens:** White Leghorn SPF chickens lacking maternal antibodies and susceptible to MDV (Line M, Nippon Institute for Biological Science, Tokyo) were used. All birds were kept in isolation.

**Inoculum:** Heparinized blood from birds inoculated with the JM Strain of MDV was used as a source of the virus. The donor birds showed clinical and histopathological lesions of MD. The source of the JM strain of MDV was described previously<sup>31)</sup>. Each chicken was inoculated intra-peritoneally with 0.1 ml of the infected blood.

**Operation and X-ray irradiation:** The chickens were bursectomized at hatching and exposed to 650 R (193.25 R/min, 165 kVp, 20 mA) of total-body X-ray irradiation (half value layer; 4 mm Cu) in the air by the method of COOPER et al.<sup>7)</sup>

**Agar gel precipitin (AGP) test:** The AGP test was performed as described previously<sup>30,32)</sup>; anti-MDV antibody in the sera was detected by using a feather antigen prepared from the MDV infected chickens.

TABLE 1 *Exberimental design*

PART	GROUP	NUMBER OF CHICKENS EXAMINED IN EACH WEEK						
		3	5	7	7.5-8.5	9	10-11	12
Uninoculated	A (untreated)	3	3	3		3		4
	B (bursectomy+ X irradiation)	4	5	6		6		4
Inoculated with MDV	C (untreated)	3	3	3		3 (1)	(3)	11
	D (bursectomy+ X irradiation)	3	3	3	(3)	3 (1)		12

( ) indicates the number of dead chickens before sacrifice.

Experimental design: As shown in table 1, this experiment consisted of two parts; both uninoculated chickens and chickens inoculated intra-peritoneally with the MDV infected blood at 2 weeks of age were used. Several chickens from each group (A, B, C and D) were killed at 3, 5, 7, 9 and 12 weeks of age and examined.

Antibody production: For the evaluation of the bursa-dependent function, the agglutination test against *Salmonella pullorum* (a bacterin commercially produced by the Chiba Serum Institute, Japan) was applied. The sera were prepared from blood collected before injection of the *S. pullorum* antigen and at 10 days after injection of the organisms. The titer was expressed as the highest dilution of a positive reaction.

Phytohemagglutinin (PHA) skin test: For the evaluation of the thymus-dependent function, the PHA skin test was applied as previously described.<sup>18)</sup> Fifteen chickens (7, 9 and 12 weeks of age from the uninoculated group) were injected in the wattles with 75  $\mu$ g of PHA (PHA-p Difco) and assessed 12 and 24 hours after injection. A swelling of more than 0.45 mm was accepted as a positive reaction.

Autopsy: The chickens including those which succumbed before sacrifice were autopsied at 1, 3, 5, 7 and 10 weeks after challenge (tab. 1). All chickens were exsanguinated after observation of clinical signs, with the exception of the dead cases. The sera were stored at  $-20^{\circ}\text{C}$ . Various tissues from all the chickens were fixed in 10% formalin.

Histopathology: The liver, spleen, kidneys, heart, lungs, proventriculus, cecal tonsils, thymus, bursa of Fabricius, Harderian glands, gonads, adrenals, skin, muscles, and the central and peripheral nervous system (the brachial plexus, lumbosacral plexus and spinal ganglia) were embedded in paraffin, sectioned and stained with hematoxylin and eosin (H & E).

## RESULTS

### Effect of Bursectomy in the Uninoculated Group

Each week the bursectomized group B chickens showed body growth failure in

TEXT-FIGURE 1 Comparison of the increase of body weight in each group

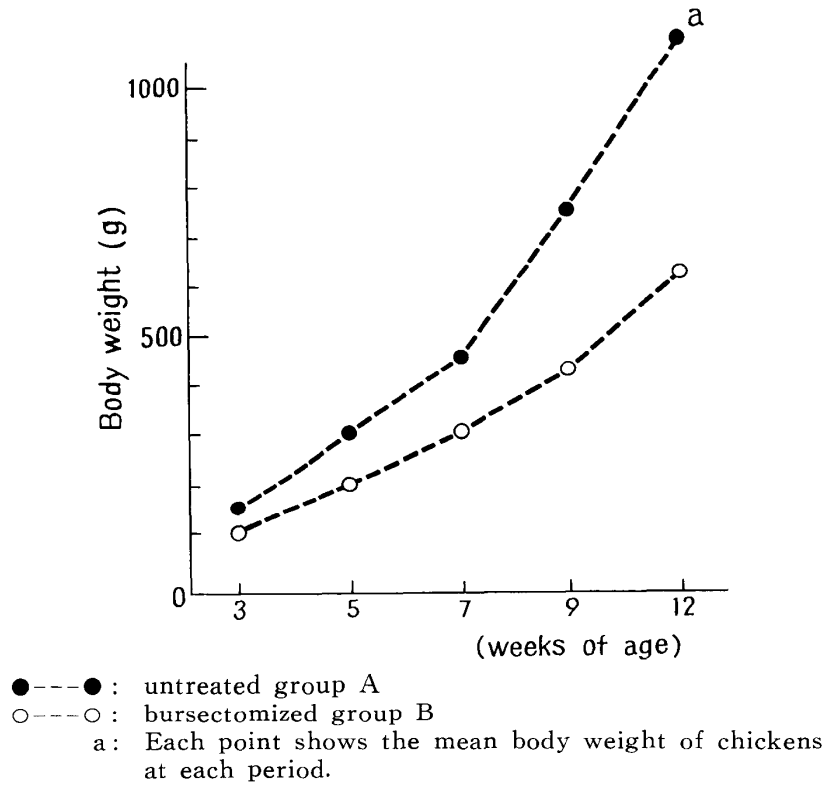


TABLE 2 Effect of bursectomy on the bursa-dependent and thymus-dependent function

GROUP	AGE weeks	NUMBER OF CHICKENS	BURSA-DEPENDENT FUNCTIONS			THYMUS- DEPENDENT FUNCTIONS
			Antibody against <i>S. pullorum</i>	Germinal centers in the spleen		PHA skin test
			*1	*2	*3	
A	3	3	0	3 ( 74)		NT
	5	3	2	3 (102)		NT
	7	3	3	3 (124)		NT
	9	3	3	3 ( 99)		3/3*4
	12	4	3	4 ( 39)		3/3
B	3	4	0	0 ( 0)		TN
	5	5	1	2 ( 13)		TN
	7	6	0	1 ( 6)		3/3
	9	6	0	3 ( 14)		3/3
	12	4	1	2 ( 21)		2/2

\*1: Number of chickens with positive reaction

\*2: Number of chickens with the germinal centers

\*3: Mean number of the germinal centers

\*4: Number of chickens showing positive reaction/number of chickens

NT: Not tested

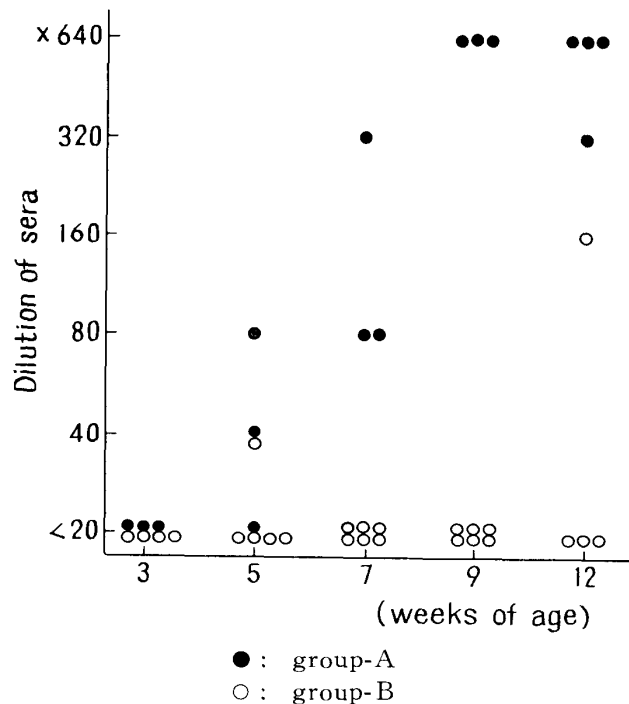
comparison with the untreated group A chickens (text-fig. 1). The lymphoid tissues in the spleen, thymus and cecal tonsils of the group B chickens were smaller than those of group A.

Microscopically, a significant depletion of lymphocytes in the periellipsoidal lymphoid tissues was observed in the spleen of the group B chickens in comparison with those of group A throughout the experimental period (figs. 1 & 2). Germinal centers were observed in all group A chickens; however, they were observed slightly in only 8 of 25 chickens from group B (tab. 2).

Antibody response against *S. pullorum* was compared in groups A and B using the agglutination test. Only 2 out of 25 cases were positive among the bursectomized chickens, whereas 12 out of 16 cases were positive among the untreated chickens (text-fig. 2).

In the PHA test, which was considered to be reliable for judging the thymus-dependent reaction, there were no differences between groups A and B.

TEXT-FIGURE 2 Antibody response against *S. pullorum*



#### Effect to Bursectomy on the Pathogenesis of MD

1 Clinical signs and gross lesions: Ten and 7 cases in groups C and D respectively showed clinical signs such as paralysis and paresis of the legs or wings, and anemia and emaciation during the observation period. Fatalities occurred at 7 (one case), 8 (two cases) and 9 (one case) weeks after inoculation in group C and at 5.5, 6.5 and 7

TABLE 3 *Effect of bursectomy on MD lesions*

GROUP	AFTER INOCULATION	NUMBER OF CHICKENS	Initial cytolytic lesions	MD LESIONS			
				Tumor lesions			
				Gross		Histopathological	
	weeks						
C	1	3	2*1	0*2	0*3	0*2	0*3
	3	3	0	0	0	1	1
	5	3	0	0	0	1	3
	7	4	0	1	4	2	3
	8-9	3	0	2	3	2	2
	10	11	0	6	5	7	4
D	1	3	0	0	0	0	0
	3	3	0	0	2	0	0
	5	3	0	0	2	2	3
	5.5-6.5	3	0	1	2	2	2
	7	4	0	2	3	3	3
	10	12	0	6	5	7	7

\*1: Number of chickens with initial cytolytic lesions

\*2: Number of chickens with MD tumors in the visceral organs

\*3: Number of chickens with MD tumors in the peripheral nerves

(each one case) weeks after inoculation in group D. Gross MD lesions consisted of peripheral nerve enlargement and lymphoid tumor formation were found in both C and D groups (tab. 3).

Neoplastic T-type lesions as described by FUJIMOTO et al.<sup>13)</sup> were observed in the liver, spleen, kidneys, heart, lungs, cecal tonsils, pancreas, gonads, bursa of Fabricius, thymus, muscle, spinal cords and peripheral nerves (figs. 5-8). The lesions were characterized by small, medium and large lymphoid cells and few reticulum cells. Mitosis was frequently observed. The adjacent tissues of the tumor lesions were often pressed and degenerated. Table 3 shows the rate of development of the tumor lesions in the visceral organs and the peripheral nerves. There was no significant difference in the rate of occurrence of MD tumor lesions, between groups C and D.

#### DISCUSSION

In this experiment, the neonatal bursectomized chickens showed a significant suppression of humoral immunity in the various points examined. The bursectomy was first demonstrated by GLICK et al.<sup>17)</sup> COOPER et al.<sup>6,7)</sup> described the bursa-and thymus-dependent areas in the spleen using surgical bursectomy and X-ray irradiation. On the other hand, chemical bursectomy has also been conducted by administration of hormones<sup>17,28,44)</sup> or cyclophosphamide<sup>16,26)</sup>

The above-mentioned studies showed the following results.

- 1 Growth of body weight and lymphoid organs was significantly inhibited<sup>17)</sup>.
- 2 Production of specific antibody and immunoglobulin was decreased or lacking<sup>6,8,15)</sup>.
- 3 Development of germinal centers and peri-ellipsoidal lymphoid tissues in the spleen and the subepithelial zone of the Lamina propria in the cecal tonsils was markedly suppressed<sup>6,20,21,22,25)</sup>.

In the present experiment, the neonatal bursectomized chickens showed inhibited growth body weight and lymphoid organs, and histopathologically, a severe depletion or aplasia of the peri-ellipsoidal lymphoid tissues and the germinal centers, which were considered to be bursa-dependent areas, in comparison with the untreated chickens. In addition, antibody response against *S. pullorum* antigen was significantly lower in group B than in group A. On the other hand, there was almost no effect of bursectomy against the thymus and thymus-dependent areas histopathologically. The reaction of PHA skin test, which was considered to reveal as thymus dependency, was not reduced in the bursectomized chickens. However, the effects of surgical bursectomy plus X-ray irradiation were clear; the bursa-dependent functions were significantly suppressed, whereas the thymus and thymus-dependent function and tissues were not. Surgical bursectomy plus X-ray irradiation was thus found to be useful for examining the immunosuppressive effect of bursa of Fabricius on the pathogenesis of MD.

The results of experiment II were as follows:

1 None of the 3 bursectomized chickens developed the "initial cytolytic lesions" whereas 2 out of 3 untreated chickens developed these lesions at one week after MDV inoculation.

2 There was no significant difference in the rate of occurrence of MD clinical signs such as gross and histopathological lesions between the bursectomized and the untreated chickens.

The initial cytolytic lesions were first described by JAKOWSKI et al.<sup>29)</sup> Characterized by degeneration and necrosis of the lymphocytes and replacement by reticulum cells and vacuolated macrophages in the lymphoid tissues, these lesions have been considered to be initial inflammatory responses to the viral infection because of the presence of intranuclear inclusion bodies, unenveloped herpesvirus particles, and immunofluorescent MDV antigen and precipitin MDV antigen in the lymphoid tissues<sup>1,14,36)</sup>. FRAZIER and PAYNE & RENNIE<sup>36)</sup> found that chickens with maternal antibodies against MDV developed lighter lymphoid destruction than chickens without these antibodies. PAYNE et al.<sup>33)</sup> reported that the so-called "initial cytolytic lesions" developed as an acute cytolytic infection with MDV in the lymphoid tissues about one week after challenge. In the present experiment, the initial cytolytic lesions were found in the untreated chickens but not in the neonatal bursectomized chickens, which suggested that the development of these lesions may be mediated through the bursa-dependent tissues and humoral

immune functions. On the other hand, GOTO et al.<sup>18)</sup> reported that the initial cytolytic lesions might be mediated through the thymus-dependent immune functions, because of the lesions were not found in the neonatal thymectomy plus X-ray irradiation in their experiment. From this view it may be thought that the thymectomy suppressed the helper-function for humoral immunity. This explanation may not be contradicted by the above described two results. Recent studies<sup>41)</sup> demonstrated that the cytotoxicity of spleen cells in vitro against the cells with Marek's disease tumor associated surface antigen (MATSA) increased in the initial period post MDV inoculation. The direct relationship between the in vitro cytotoxicity and the initial cytolytic lesions in MD was not confirmed. However, facts such as the occurrence time of the initial cytolytic lesions, the degeneration and depletion of lymphocytes, and the immunological suppressive effects suggested the existence of a relationship between the initial cytolytic lesions and the in vitro cytotoxicity.

In the present investigation, the development of tumor formation in the visceral organs and the peripheral nerves was hardly effected by bursectomy, a result which corresponded well with the results of PAYNE & RENNIE<sup>35)</sup> and FERNANDO & CALNEK. Our results also accorded well with those of SHARMA who showed that hereditary resistance against MD was not effective, and those of SHARMA & WITTER who demonstrated that age-related resistance was not influenced by chemical bursectomy of cyclophosphamide. Many studies on the effect of bursectomy to MD, however, have shown contradictory results. MORIS et al. reported that surgical bursectomy increased MD incidence and mortality. Conversely, bursectomy by hormone<sup>11)</sup> and cyclophosphamide<sup>38)</sup> resulted in a decrease of MD incidence and mortality. These differences may have been caused by the virus dosage used, the strain of chickens, or the methods of bursectomy. In particular, it should be noted that hormones and cyclophosphamide have been shown to suppress not only the bursa-dependent functions but also the thymus-dependent functions. In regard to the thymus and thymus-dependent functions, several workers have shown that thymectomy suppressed the age-related resistance<sup>19,43)</sup>, that the administration of cyclophosphamide suppressed the resistance obtained by herpesvirus of turkey (HVT) vaccination<sup>9)</sup> which did not influence by surgical bursectomy, that MD tumor cells were positive against anti-thymus sera by immunofluorescent, and that Line cells which originated from the MD tumor had the T-cell surface markers<sup>2,37)</sup>.

In this study, surgical bursectomy plus X-ray irradiation at hatching caused the depletion of the bursa-dependent function and tissues without depletion of the thymus-dependent function and tissues. We concluded that the function of the bursa of Fabricius was not essential for the tumorigenesis of MD but that it was responsible for the occurrence of the initial cytolytic lesions.

## ACKNOWLEDGEMENTS

The authors wish to thank Drs. Y. H. NAKANISHI, T. MIKAMI (Faculty of Veterinary Medicine, Hokkaido University, Sapporo, Japan) and M. SUGIMURA (Faculty of Agriculture, Gifu University, Gifu, Japan) for their valuable advice.

## REFERENCES

- 1) ADLDINGER, H. K. & CALNEK, B. W. (1973): Pathogenesis of Marek's disease: Early distribution of virus and viral antigens in infected chickens *J. Natl. Cancer Inst.*, **50**, 1287-1298
- 2) AKIYAMA, Y. & KATO, S. (1974): Two cell lines from lymphomas of Marek's disease *Biken J.*, **17**, 105-116
- 3) CHEVILLE, N. F. & BEARD, C. W. (1972): Cytopathology of Newcastle disease: The influence of bursal and thymic lymphoid systems in the chickens *Lab. Invest.*, **27**, 129-143
- 4) CHEVILLE, N. F. & RICHARDS, W. D. (1971): The influence of thymic and bursal lymphoid system in avian tuberculosis *Am. J. Pathol.*, **64**, 97-122
- 5) CHO, B. R. (1970): Experimental dual infections of chickens with infectious bursal and Marek's disease agents. I. Preliminary observation on the effect of infectious bursal agent on Marek's disease *Avian Dis.*, **14**, 665-675
- 6) COOPER, M. D., PETERSON, R. D. A. & GOOD, R. A. (1965): Delineation of the thymic and bursal lymphoid systems in the chickens *Nature (Lond.)*, **205**, 143-146
- 7) COOPER, M. D., PETERSON, R. D. A., SOUTH, M. A. & GOOD, R. A. (1966): The functions of the thymus system and bursa system in the chicken *J. Exp. Med.*, **123**, 75-102
- 8) DURKIN, H. G., THEIS, G. A. & THORBECKE, G. J. (1972): Bursa of Fabricius as site of origin of germinal center cells *Nature (Lond.)*, **235**, 118-119
- 9) ELSE, R. W. (1974): Vaccinal immunity to Marek's disease in burssectomized chickens *Vet. Rec.*, **95**, 182-187
- 10) FERNANDO, W. W. D. & CALNEK, B. W. (1971): Influence of bursa of Fabricius on infection and pathological response of chickens exposed to Marek's disease herpesvirus *Avian Dis.*, **15**, 467-476
- 11) FOSTER, A. G. & MOLL, T. (1958): Effect of immunosuppression on clinical and pathologic manifestations of Marek's disease in chickens *Am. J. Vet. Res.*, **29**, 1831-1835
- 12) FRAZIER, J. A. (1974): Ultrastructure of lymphoid tissue from chicks infected with Marek's disease virus *J. Natl. Cancer Inst.*, **52**, 829-837
- 13) FUJIMOTO, Y., NAKAGAWA, M., OKADA, K., OKADA, M. & MATSUKAWA, K. (1971): Pathological studies of Marek's disease. I. The histopathology on field cases in Japan *Jpn. J. Vet. Res.*, **19**, 7-26
- 14) FUJIMOTO, Y., OKADA, K., KAKIHATA, K., MATSUI, T., NARITA, M., ONUMA, M. & MIKAMI, T. (1974): Initial lesions in chickens infected with JM strain of Marek's disease virus *Ibid.*, **22**, 80-94

- 15) GLICK, B. (1956): Experimental modification of the growth of the bursa of Fabricius *Poult. Sci.*, **36**, 18-23
- 16) GLICK, B. (1971): Morphological changes and humoral immunity in cyclophosphamide-treated chicks *Transplantation*, **11**, 433-439
- 17) GLICK, B., CHANG, T. S. & JAAP, R. G. (1956): The bursa of Fabricius and antibody production in the domestic fowl *Poult. Sci.*, **35**, 224-226
- 18) GOTO, N., FUJIMOTO, Y., OKADA, K., MIKAMI, T., KODAMA, H. & ICHIJO, K. (1979): Effect of thymectomy on the initial cytolytic lesions and nerve demyelination of Marek's disease *Zentralbl. Veterinaermed.*, B, **26**, 61-72
- 19) GOTO, N., KODAMA, H., OKADA, K. & FUJIMOTO, Y. (1978): Suppression of phytohemagglutinin skin response in thymectomized chickens *Poult. Sci.*, **57**, 246-250
- 20) HOSHI, H. (1972): On the nature of the periellipsoidal lymphoid tissue of chick spleen *Tohoku J. Exp. Med.*, **106**, 285-305
- 21) HOSHI, H. & MORI, T. (1973): Inhibition of the germinal center formation in the spleen by X-irradiations of the thymus in chickens *Ibid.*, **109**, 97-111
- 22) HOSHI, H. & MORI, T. (1973): Identification of the bursa-dependent and thymus-dependent areas in the Tonsilla caecalis of chickens *Ibid.*, **111**, 309-322
- 23) JAKOESKI, R. E., FREDRICKSON, T. N., CHOMIAK, T. W. & LUGINBUHL, R. E. (1970): Hematopoietic destruction of Marek's disease *Avian Dis.*, **14**, 374-385
- 24) JAKOWSKI, R. M., FREDRICKSON, T. N., LUGINBUHL, R. E. & HELMBOLDT, C. F. (1969): Early changes in bursa of Fabricius from Marek's disease *Ibid.*, **13**, 215-222
- 25) JANKOVIC, B. D. & ISAKOVIC, K. (1964): Role of the thymus and the bursa of Fabricius in immune reactions in chickens. I. Changes in lymphoid tissues of chickens surgically thymectomized at hatching *Int. Arch. Allergy Appl. Immunol.*, **24**, 278-295
- 26) LERMAN, S. P. & WEIDANZ, W. P. (1970): The effect of cyclophosphamide on the ontogeny of the humoral immune response in chickens *J. Immunol.*, **105**, 614-619
- 27) LINNA, T. J., FROMMEL, D. & GOOD, R. A. (1972): Effects of early cyclophosphamide treatment on the development of lymphoid organs and immunological functions in the chicken *Int. Arch. Allergy Appl. Immunol.*, **42**, 20-39
- 28) METER, R. K., RAO, M. A. & ASPINALL, R. L. (1959): Inhibition of the development of the bursa of Fabricius in the embryos of common fowl by 19-nortestosterone *Endocrinology*, **64**, 890-897
- 29) MIKAMI, T. & BANKOWSKI, R. A. (1971): Pathogenetic and serologic studies of type 1 and 2 plaque-producing agents derived from Cal-1 strain of Marek's disease virus *Am. J. Vet. Res.*, **32**, 303-317
- 30) MORRIS, J. R., JEROME, F. N. & REINHART, B. S. (1969): Surgical bursectomy and the incidence of Marek's disease (MD) in domestic chickens *Poult. Sci.*, **48**, 1513-1515
- 31) OKADA, K., FUJIMOTO, Y., MIKAMI, T. & YONEHARA, K. (1972): The fine struc-

- ture of Marek's disease virus and herpesvirus of turkey in cell culture *Jpn. J. Vet. Res.*, **20**, 57-68
- 32) ONUMA, M., MIKAMI, T. & HAYASHI, T. T. A. (1974): Properties of common antigen associated with Marek's disease herpesvirus and turkey herpesvirus infections *J. Natl. Cancer Inst.*, **52**, 805-813
  - 33) PAYNE, L. N., FRAZIER, J. A. & POWELL, P. C. (1976): Pathogenesis of Marek's disease *Int. Rev. Exp. Pathol.*, **16**, 59-153
  - 34) PAYNE, L. N., POWELL, P. C. & RENNIE, M. (1974): Response of B and T lymphocytes and other blood leukocytes in chickens with Marek's disease *Cold Spring Harbor Symposia on Quantitative Biology*, **39**, 2, 817-826
  - 35) PAYNE, L. N. & RENNIE, M. (1970): Lack of effect of bursectomy on Marek's disease *J. Natl. Cancer Inst.*, **45**, 387-397
  - 36) PAYNE, L. N. & RENNIE, M. (1973): Pathogenesis of Marek's disease in chicken with and without maternal antibody *Ibid.*, **51**, 1559-1572
  - 37) PAYNE, L. N. & RENNIE, M. (1976): The proportions of B and T lymphocytes in lymphomas, peripheral nerves and lymphoid organs in Marek's disease *Avian Pathol.*, **5**, 147-154
  - 38) PURCHASE, H. G. & SHARMA, J. M. (1974): Amelioration of Marek's disease and absence of vaccine protection in immunologically deficient chickens *Nature (Lond.)*, **248**, 419-421
  - 39) ROUSE, B. T., WELLS, R. J. H. & WARNER, N. L. (1973): Proportion of T and B lymphocytes in lesions of Marek's disease: Theoretical implication for pathogenesis *J. Immunol.*, **110**, 534-539
  - 40) SHARMA, J. M. (1974): Resistance to Marek's disease in immunologically deficient chickens *Nature (Lond.)*, **247**, 117-118
  - 41) SHARMA, J. M. & COULSON, B. D. (1977): Cell-mediated cytotoxic response to cells bearing Marek's disease tumor-associated surface antigen in chickens infected with Marek's disease virus *J. Natl. Cancer Inst.*, **58**, 1647-1651
  - 42) SHARMA, J. M. & WITTER, R. L. (1975): The effect of B-cell immunosuppression on age-related resistance of chickens to Marek's disease *Cancer Res.*, **35**, 711-717
  - 43) SHARMA, J. M., WITTER, R. L. & PURCHASE, H. G. (1975): Absence of age-resistance in neonatally thymectomized chickens as evidence for cell-mediated immune surveillance in Marek's disease *Nature (Lond.)*, **253**, 477-479
  - 44) SZENBERG, A. & WANER, N. L. (1962): Dissociation of immunological responsiveness in fowls with a hormonally arrested development of lymphoid tissue *Ibid.*, **194**, 146-147

## EXPLANATION OF PLATE

### PLATE I

- Fig. 1 Formation of the germinal center and accumulation of the lymphocytes in the periellipsoidal lymphoid tissues of the spleen from 12-week-old group A chicken Hematoxylin and eosin stain (H & E)  $\times 290$
- Fig. 2 Absence of the lymphocyte and replacement of the reticulum cells in the peri-ellipsoidal lymphoid tissues of the spleen from 12-week-old group B chicken H & E  $\times 290$
- Fig. 3 Initial cytolytic lesions in the cecal tonsils from group C chicken 1 week after inoculation with MDV H & E  $\times 168$
- Fig. 4 Absence of the initial cytolytic lesions in the thymus from group D chicken 1 week after inoculation with MDV H & E  $\times 82$

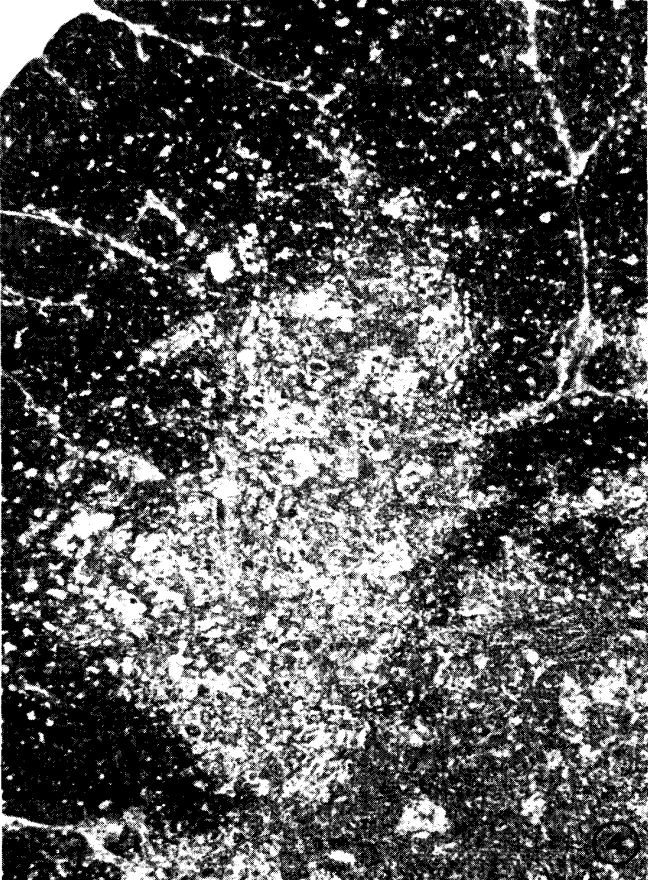
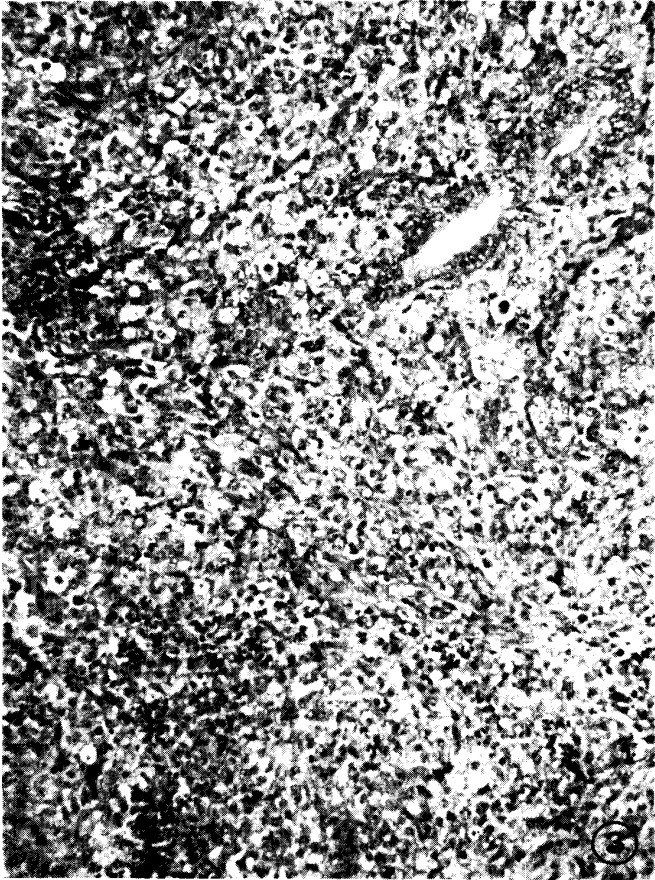

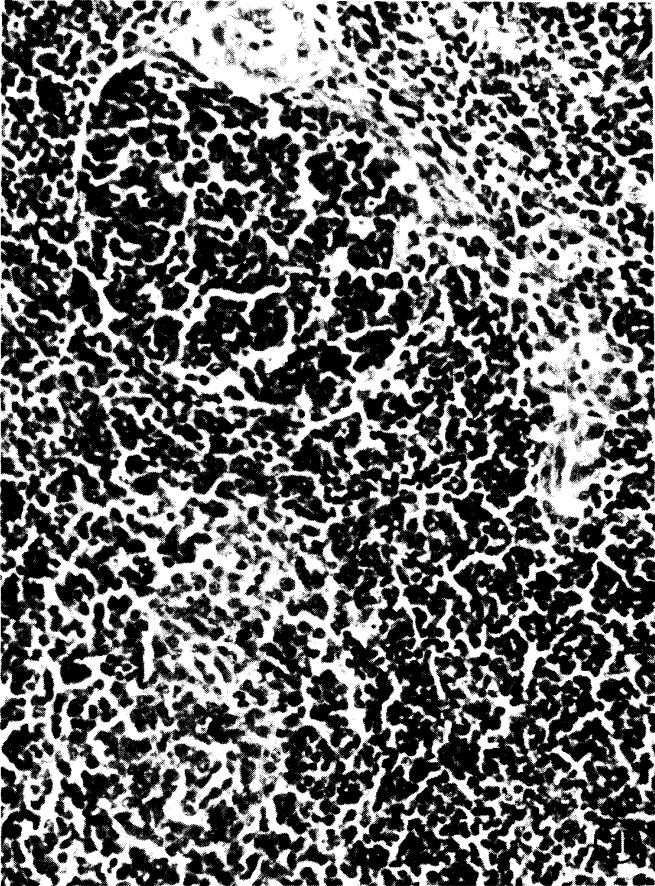


PLATE II

- Fig. 5 Tumorous lesion in the liver from group C chicken 10 weeks after inoculation with MDV. Notes severe lymphoid proliferation H & E  $\times 173$
- Fig. 6 Tumorous lesion in the heart from group D chicken 10 weeks after inoculation with MDV H & E  $\times 173$
- Fig. 7 Severe lymphoid cell proliferation in the peripheral nerve (N. Ishiadicus) from group D chicken 10 weeks after inoculation with MDV H & E  $\times 173$
- Fig. 8 Marked enlargement of the peripheral nerve (N. medianus) Group C chicken 10 weeks after inoculation with MDV H & E  $\times 71$

